



Cirugía Española



www.elsevier.es/cirugia

P-668 - "TARGET SIGN" REGARDING BOWEL INTUSSUSCEPTION

Curbelo Peña, Yuhamy; Saavedra Pérez, David; Stickar, Tomás; Saladich Cubero, María; Molinas Bruguera, Joan; de Cozar Duch, Jordi; Quer Vall, Xavier; Vallverdú Cartie, Helena

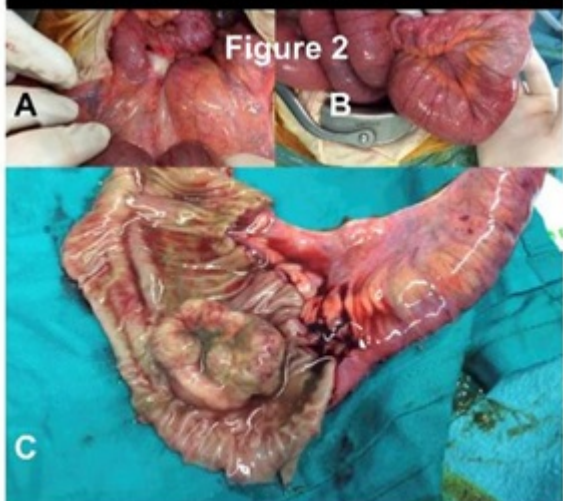
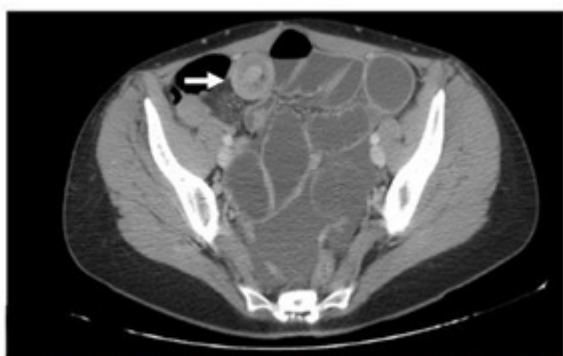Hospital Universitario de Vic, Vic.

Resumen

Introduction: Small Bowel Adenocarcinoma (SBA) is a rare malignant neoplasm without specific signs and symptoms, and associated with late stage disease presentations. After a successful removal of a carcinoma in the large bowel, there is a higher risk for developing a further primary (metachronous) large bowel tumor. However metachronous carcinomas affecting small bowel are rarer.

Case report: A 46-year-old female patient with previous emergent Hartmann intervention two years ago and three lines of adjuvant chemotherapy for treatment adenocarcinoma of sigmoid colon at stage IIB and loco-regional recurrence. The patient had bowel obstruction secondary to a small bowel intussusception (as reported by computed tomography, see marked "Target sign"). An emergent exploratory laparotomy was conducted and was confirmative of an ileal tumor as the cause of small bowel intussusception and clinical bowel obstruction. Pathologic anatomy confirmed a primary small bowel mucinous adenocarcinoma with node metastasis (T3N1M0, stage IIIB).

Figure 1



Discussion: Patients who develop a small or large bowel adenocarcinoma are at high risk for a second cancer at both sites. However data available to guide therapeutic decisions for those presenting one at small bowel are scarce, and the role of adjuvant therapy in patients who undergo curative resection is unclear. We present a case of a small bowel adenocarcinoma at an advanced stage, following surgery and adjuvant therapy for colorectal adenocarcinoma, with an atypical presentation at the emergency room, as a rare cause of obstructive small bowel intussusception. Regarding diagnosis at emergency room it is important to keep in mind the "Target sign", avoiding delayed treatments. Studies about strategies for detection at an earlier stage, optimal treatment and prognosis are mandatory for this disease.