

## CLINICAL CASE

# Piroxicam-induced photodermatitis. Cross-reactivity among oxicams. A case report

M.J. Trujillo, M. de Barrio, A. Rodríguez, M. Moreno-Zazo, I. Sánchez, R. Pelta, P. Tornero, and T. Herrero

Gregorio Marañón Hospital, Madrid, Spain.

---

### SUMMARY

*Background:* there is a group of patients with contact allergy to thimerosal (thiosalicylic acid and ethylmercuric chloride), thiosalicylic acid sensitized, who develop photodermatitis to piroxicam. We present a case which we have investigated cross-reactivity among different oxicams.

*Methods and results:* a 44-year-old man with contact allergy to thimerosal. A few hours after the intake of Feldene™ (piroxicam) while running outside, developed a papuloerithematosus exanthema in the neck, knees and forearms, and microvesicles on the finger webs, that became descamative a few days later. Oclusive patch tests with thiosalicylic acid, mercury, piroxicam, tenoxicam, droxicam and meloxicam and photopatch test with the oxicams were performed. Patch tests with thiosalicylic acid and piroxicam were positive and negative with the others. All the oxicams photopatch tests were positive.

*Conclusions:* we present a case of photodermatitis and dermatitis to piroxicam, in a patient with contact allergy to the thiosalicylic moiety of thimerosal, in which cross-reactivity with the other oxicams have been demonstrated. In cases of oxicams-induced photodermatitis, all oxicams should be avoided, to elude posible cross-reactions.

**Key words:** Cross-reactivity. Dermatitis. Droxicam. Meloxicam. Oxicams. Photodermatitis. Piroxicam. Tenoxicam. Thiosalicylic acid.

*Allergol et Immunopathol* 2001; 29(4): 133-136.

---

### INTRODUCTION

Oxicams are nonsteroidal antiinflammatory drugs widely used in reumathologic diseases treatment. Among the different drugs of this family available in our country, piroxicam is the most frequently used. 1-3% of patients taking this drug develop cutaneous adverse reactions, the second most frequent after the gastrointestinal ones. Photosensitivity and dyshidrotic eczema are the most typical piroxicam-induced cutaneous reactions (1).

Thimerosal, synthesized from ethylmercuric chloride and thiosalicylic acid, is a preservative used mainly in vaccines, ear, eye and nose drops, and as a topical antiseptic. Allergy to thimerosal is due either to the mercurial moiety, to thiosalicylic acid or to both.

According to different studies, between 75 and 83% of patients with contact allergy to thimerosal, thiosalicylic acid sensitized, can develop photodermatitis to piroxicam (2-5). A photoproduct of piroxicam, with chemical similarity to thiosalicylic acid, could be responsible for the cross-reaction with this molecule (3, 6).

Photosensitivity reactions with other oxicams are uncommon, although a case of droxicam-induced photodermatitis, with positive photopatch test to piroxicam, has been reported (7). Therefore, in patients with a history of piroxicam-induced photoallergy, tenoxicam may be used safely because it does not cross-react with piroxicam (3, 7).

We report a case of piroxicam-induced photodermatitis and dermatitis in a patient with contact allergy to thimerosal, thiosalicylic acid sensitized, in which we have investigate cross-reactivity among different oxicams.




Figure 1.—Photopatch test with piroxicam, tenoxicam and droxicam 49 hours after irradiation.

## CASE REPORT

A 44-year-old man with contact allergy to thimerosal. A few hours after the intake of Feldene™ (piroxicam) while running outside, developed a papuloerithematosus exanthema in the neck, knees and forearms, and microvesicles on the finger webs, that became descamative a few days later. Previously, he had developed a similar incident, outdoors, a few hours after the oral intake of Feldene™ and local use of Sasulen™ (topical piroxicam).

## Allergologic study

Patch tests with thiosalicylic acid (0.1 % pet.) and mercury (1 % pet.), with readings at 48 and 96 hours, were performed. Duplicate patch tests with piroxicam (0.1 %, 1 % pet.) and (1 % in dimethyl-sulfoxide [DMSO]), droxicam (1 % pet.), tenoxicam (1 %, 10 % pet.) and meloxicam (1 % pet.) and (1 % DMSO) were applied. Tests were

removed after 48 hours and then, while one set of tests was protected from light, the other was irradiated with 5.0 J/cm<sup>2</sup> of UVA light. Readings were made just before irradiation and 48 hours thereafter. Control patch test with DMSO was included. Only (+ +) or more reactions were considered positive.

The study was also performed in a group control of ten healthy subjects without history of contact allergy.

## RESULTS

Patch tests with thiosalicylic acid (0.1 % pet.) was positive and negative with mercury. Among the occlusive patch tests, only piroxicam (1 % DMSO) was positive and negative for the rest of oxicams and DMSO. Photopatch tests with piroxicam (1 % DMSO) and (0.1 %, 1 % pet.), droxicam (1 % pet.) tenoxicam (10 % pet.) and meloxicam (1 % DMSO and pet.) were positive (fig. 1). Photopatch test with piroxicam was far more intense than occlusive one.

Control group study was negative.

## DISCUSSION

Photoallergic contact dermatitis is a form of delayed allergic hypersensitivity reaction due to a specifically altered immunologic state. By definition, light energy is required, along with exposure to the responsible allergen, to produce the reaction. However, some photoallergens can also produce ordinary allergic contact dermatitis in the absence of light (8).

The presence of dermatitis and photodermatitis shows a positive reaction in the photopatch tests as well as in the occlusive ones, but the reaction is more intense or persists more time in the irradiated set of tests. We report a case of piroxicam-induced photodermatitis and dermatitis in a patient with contact allergy to the thiosalicylate moiety of thimerosal.

Cross-reactivity between piroxicam and thiosalicylic acid has been widely studied. Cirne de Castro et al (4) concluded that photoproducts formed from piroxicam and L-cysteine (abundant amino acid in the skin), with chemical similarity to thiosalicylic acid, could be responsible for the cross-reactivity between this acid and piroxicam.

Two epitopes formed from irradiated piroxicam have been experimentally described. One of them with cross-reactivity to thiosalicylic acid patch test, previously mentioned, and the other one with

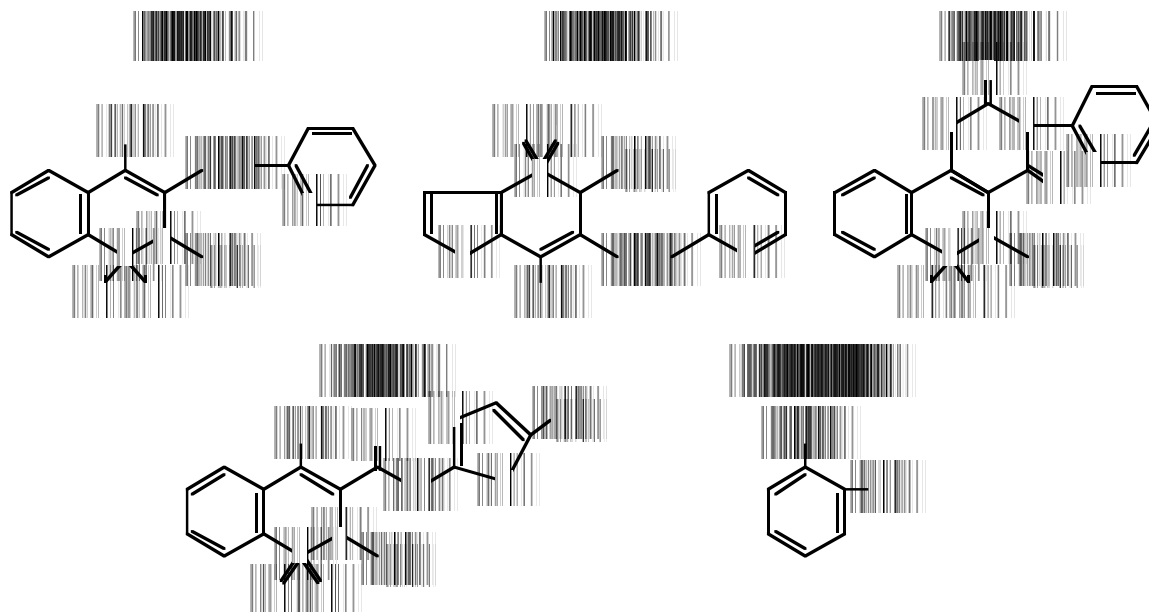


Figure 2.—Chemical structures of piroxicam, tenoxicam, droxicam, meloxicam and thiosalicylic acid.

cross-reactivity to tenoxicam photopatch test, but without reactivity to thiosalicylic acid (9).

Serrano et al (7) reported the first case of droxicam-induced systemic photosensitivity in a patient with positive piroxicam photopatch test and negative tenoxicam one. Droxicam is a pro-drug of piroxicam, to which it is rapidly converted by hydrolysis in the gastrointestinal tract, and theoretically, a similar process may occur in the skin. This might explain the cross-sensitivity between these two different drugs. When we examine their chemical structures, we observed that piroxicam and droxicam have a common structural area composed of a benzothiazidic nucleus, while tenoxicam have a tienothiazidic one (fig. 2). This gives tenoxicam a more hydrophilic character and, thus, a lower penetration into tissues, explaining the lower incidence of adverse reactions. For these reasons, until now, tenoxicam was considered a safely drug in patients with history of piroxicam-induced photoallergy (3, 7).

Until now, cross-reactivity between piroxicam and meloxicam has not been reported. Meloxicam undergoes extensive hepatic and oxidative metabolism and, at least, 4 metabolites of meloxicam have been detected all of which are inactive (10).

However, in cases of piroxicam-induced fixed drug eruption, cross-reactivity among piroxicam, droxicam and tenoxicam have been demonstrated (11, 12). Therefore, these patients should avoided all oxicams.

Piroxicam antigenic determinant responsible of these reactions could be common to all oxicams, and different from the ones responsables of photosensitivity reactions.

Our patient suffered an allergic photodermatitis elicited by piroxicam, with the peculiarity that he presented not only a positive piroxicam photopatch test but also a positive patch one. This facts supports an extreme sensitization. Concerning to cross-reactivity with the rest of oxicams photopatch tests, we consider that two different piroxicam antigenic determinants may be implicated: one non-shared for the rest of oxicams with cross-reactivity to thiosalicylic acid, and other oxicams common antigenic determinant without cross-reactivity to thiosalicylic acid.

Therefore, we concluded that in cases of oxicams-induced photodermatitis, all oxicams should be avoided, to elude posible cross-ractions.

## RESUMEN

*Fundamento:* existe un grupo de pacientes con alergia de contacto al tимерosal (ácido tiosalicílico y cloruro de etilmercurio), sensibilizados al ácido tiosalicílico, que desarrollan fotodermatitis a piroxicam. Se presenta un caso en el que se ha investigado la reactividad cruzada entre diferentes oxicams.

*Métodos y resultados:* varón de 44 años de edad con alergia de contacto al timerosal. Algunas horas después de la ingesta de Feldene™ (piroxicam) mientras corría al aire libre, desarrolló un exantema papuloeritematoso en el cuello, rodillas y antebrazos, y microvesículas en los espacios interdigitales, que se hizo descamativo unos pocos días más tarde. Se llevaron a cabo pruebas oclusivas del parche con ácido tiosalicílico, mercurio, piroxicam, tenoxicam, droxicam y meloxicam y pruebas del fotoparche con oxicams. Las pruebas del parche con ácido tiosalicílico y piroxicam fueron positivas y negativas con las otras. Todas las pruebas de fotoparche con oxicams fueron positivas.

*Conclusiones:* se presenta un caso de fotodermatitis y dermatitis a piroxicam en un paciente con una alergia de contacto a la mitad tiosalicílico del timerosal, en el que se ha demostrado una reactividad cruzada con el resto de oxicams. En los casos de fotodermatitis inducida

por oxicams, es preciso evitarlos todos, debido a una posible reacción cruzada.

**Palabras clave:** Reactividad cruzada. Dermatitis. Droxicam. Oxicams. Fotodermatitis. Piroxicam. Tenoxicam. Ácido tiosalicílico.

## REFERENCES

1. Youn JI, Lee HG, Yeo UC, Leo YS. Piroxicam photosensitivity associated vesicular hand dermatitis. *Clin Expt Dermatol* 1993; 18: 52-4.
2. Serrano G, Bonillo J, Aliaga A, Cuadra J, Pujol C, Pelufo C, Cervera P, Miranda MA. Piroxicam induce photosensitivity and contact sensitivity to thiosalicylic acid. *J Am Acad Dermatol* 1990 Sept 23 (3 Pt 1): 479-83.
3. Gonçalo M, Figueiredo A, Tavares P, Fontes Ribeiro CA, Teixeira F, Baptista Polares A. Photosensitivity to piroxicam: absence of cross-reaction with tenoxicam. *Contact Dermat* 1992; 27: 287-90.
4. Cirne de Castro JL, Freitas JP, Menezes Brandao F, Themido R. Sensitivity of thimerosal and photosensitivity to piroxicam. *Contact Dermat* 1991; 24: 187-92.
5. Gonçalo M, Figueiredo A, Gonçalo S. Hipersensitivity to thimerosal: the sensitizing moiety. *Contact Dermat* 1996; 34: 201-3.
6. Miranda MA, Vargas F, Serrano G. Photodegradation of piroxicam under aerobic conditions: The photochemical keys of the piroxicam enigma? *J Photochem Photobiol* 1991; 8: 199-201.
7. Serrano G, Fortea JM, Latasa JM, SanMartín O, Bonillo J, Miranda MA. Oxidation induce photosensitivity. *J Am Acad Dermatol* 1992; 26: 545-8.
8. Rietschel R, Fowler J, Fisher's Contact Dermatitis. Fourth ed. Baltimore: Williams and Wilkins, 1995.
9. Takeshi, H et al. Piroxicam has at least two epitopes for contact photoallergy. *J Dermatol Sci* 1993; 6: 219-24.
10. Noble S, Balfour JA. Meloxicam. *Drugs* 1996; 3: 424-30.
11. Gastamiza A, Echechipia S, Navarro JA, Fernandez de Corres L. Fixed drug eruption from piroxicam. *Contact Dermat* 1993; 28: 43-4.
12. Ordoqui E, De Barrio M, Rodriguez VM, Herrero T, Gil PJ, Baeza ML. Cross-sensitivity among oxicams in piroxicam-caused fixed drug eruption: two case reports. *Allergy* 1995; 50: 741-44.

### Correspondence:

M.ªJ. Trujillo Trujillo  
Ventura Rodríguez, 12. Chalet 39  
28660 Boadilla del Monte. Madrid, Spain  
Tels.: 916 337 751/696 980 523  
Fax: 916 324 921