

REVIEW ARTICLE

Is magnetic resonance imaging teratogenic during pregnancy? Literature review



Danielle Bastidas Rosas^{a,*}, Hugo López^b, Nicolás Fernández^c

^a Facultad de Medicina, Pontificia Universidad Javeriana, Hospital Universitario San Ignacio, Bogotá, Colombia

^b Especialista en urología y epidemiología clínica, Pontificia Universidad Javeriana, Departamento de Urología, Hospital Universitario San Ignacio, Bogotá, Colombia

^c Especialista en urología y genética, Fellow urología pediátrica, University of Toronto, Hospital for sick kids, Toronto, Canada

Received 17 October 2016; accepted 24 April 2017

Available online 14 October 2017

KEYWORDS

Magnetic resonance imaging;
Pregnancy;
Teratogen;
DNA damage;
Congenital abnormalities

Abstract Magnetic resonance imaging is a diagnostic tool used for obtaining an image through the combination of electromagnetic fields and radiofrequency. Given its properties and safety, it is the imaging modality of choice in pregnant women. However, little is known about the effects of MRI on the developing foetus.

Objectives: To identify the effects of the use of magnetic resonance imaging on the foetus when used as a diagnostic tool during pregnancy.

Materials and methods: A literature search was performed in PubMed, Embase, and LILACS. Clinical guidelines and the grey literature were also reviewed. An analysis was made based on the findings.

Results: Four potentially adverse effects were found: (1) The impact on the auditory development due to the acoustic sound made by the resonator. (2) Teratogenic effects on DNA. (3) Physical deformities secondary to temperature increase. (4) Teratogenic effects due to the use of gadolinium as a contrast agent.

Conclusion: The risk assessment on the use of magnetic resonance imaging on the foetus is complex, owing to the multiple differences in field strength, force gradients, and radiofrequency pulses used. Although the adverse effects of using this method are not very clear, there are studies that describe the possible outcomes that can result from the use of this imaging modality. It is recommended to use MRI with caution, as long as the benefits outweigh the risk in pregnant patients.

© 2017 Sociedad Colombiana de Urología. Published by Elsevier España, S.L.U. All rights reserved.

DOI of original article: <http://dx.doi.org/10.1016/j.uroco.2017.04.009>

* Corresponding author.

E-mail address: dbastidas@javeriana.edu.co (D.B. Rosas).

<http://dx.doi.org/10.1016/j.uroco.2017.09.007>

0120-789X/© 2017 Sociedad Colombiana de Urología. Published by Elsevier España, S.L.U. All rights reserved.

PALABRAS CLAVE

Resonancia magnética;
Embarazo;
Teratógeno;
Daño de ADN;
Anomalías congénitas

¿Es teratogénica la resonancia magnética durante el embarazo? Revisión de la literatura

Resumen La resonancia magnética nuclear es una herramienta diagnóstica que actúa mediante la obtención de imágenes por campos electromagnéticos en combinación con radiofrecuencia. Dadas sus propiedades y seguridad es el estudio de elección en mujeres en estado de embarazo. Sin embargo, poco se sabe acerca de las consecuencias que la exposición a la resonancia magnética nuclear tiene sobre los fetos en gestación.

Objetivos: Identificar los efectos que tiene la resonancia magnética sobre el feto cuando se utiliza como método diagnóstico durante el embarazo.

Materiales y métodos: Se realizó una búsqueda de la literatura en PubMed, Embase y LILACS. Se revisaron además guías de práctica clínica, literatura gris y se hizo un análisis en función de los hallazgos.

Resultados: Se encontraron 4 efectos potencialmente adversos: 1) El impacto en el desarrollo auditivo por el sonido acústico que genera el resonador, 2) Efectos teratogénicos sobre el ADN, 3) Deformaciones físicas por aumento de temperatura, y 4) Efectos teratogénicos por el uso de gadolinio como medio de contraste.

Conclusión: La evaluación del riesgo que genera el uso de resonancia magnética nuclear sobre el feto es compleja debido a las múltiples diferencias entre las fuerzas de los campos, gradientes de fuerza y pulsos de radiofrecuencia utilizados. Consecuentemente los efectos adversos del uso de este método no son muy claros, sin embargo sí hay estudios que describen los posibles desenlaces que puede tener su utilización por lo que se sugiere usar este método con cautela, siempre y cuando los beneficios sobrepasen los riesgos en las pacientes embarazadas.

© 2017 Sociedad Colombiana de Urología. Publicado por Elsevier España, S.L.U. Todos los derechos reservados.

Introduction

All living things are constantly exposed to natural electromagnetic fields; these are, however, weak and non-ionizing fields, so most people are unaware of their existence.¹ Magnetic resonance imaging (MRI) has been established as an essential tool in the study of various diseases. Its use during pregnancy has increased and it is even used to diagnose alterations of prenatal development that cannot be properly studied with ultrasound.²⁻⁷ Little is known, however, about the consequences of exposure to magnetic fields on the developing fetus.⁸ It is difficult to assess the risks due to the many variables involved.^{3,9} Nevertheless, there are guidelines that aim to limit the use of this method despite the lack of information. The main objective of this systematic review is to find basic information about the effects of MRI on the fetus.

Materials and methods

A systematic literature review was carried out on the teratogenic effects of magnetic resonance imaging in the Embase and PubMed databases, as well as in clinical practice guidelines. The following MeSH terms and their respective cross-references were used: "magnetic resonance imaging," "pregnancy," "teratogen," "DNA damage," and "congenital abnormalities." The filters used were: observational study, clinical study, systematic reviews, humans, other animals. No language restriction was established. A total of 597 articles were found, 42 of which were selected: one prospective cohort study, 9 narrative reviews, 15 exper-

imental studies in animals, 2 experimental studies *in vitro*, 5 experimental studies in humans, and 10 clinical practice guidelines.

Gray literature was searched using the "open grey" portal, looking for papers presented at important international conferences; this search gave only one result, which was not useful for our study, since magnetic resonance was not used.

For Latin American studies, the LILACS database was searched without obtaining any results.

Only those studies were included that related magnetic resonance imaging, either positively or negatively, with teratogenic effects; these were narrative-type, observational, and clinical studies, as well as systematic literature reviews. Articles were discarded if they did not evaluate the outcomes of interest, comparing the implementation of the proposed interventions. After an initial selection based on a review of titles and abstracts, the remaining articles were read in their totality and an analysis of the findings was carried out. This process was completed by multiple investigators (Fig. 1 and Table 1, Appendix 1).

Magnetic resonance imaging as a diagnostic method**Generalities**

Magnetic resonance images are generated by manipulating the polarity of the protons in the tissues, using electromagnetic fields and radio frequency.^{1,9,10} The image is projected after the body is exposed to a static magnetic field stimulated by an oscillating field, which results in the emission of

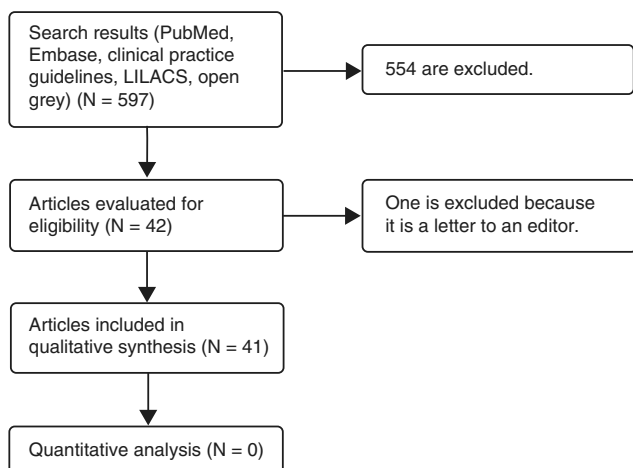


Figure 1 Article selection process.

Table 1 Summary and classification of reviewed articles.

Study type	Number of articles: 41
Narrative review	9
Experimental study in humans	5
Experimental study <i>in vitro</i>	2
Experimental study in animals	15
Prospective cohort study	1
Clinical practice guidelines	10

the energy absorbed by the nuclei (also called echo) in the form of radio frequency waves. Its quantification generates an image in two sequences: T1 and T2, where both depend on the relaxation time of tissues after a 180-degree radio frequency pulse, with T1 being the longitudinal relaxation time and T2 the transverse relaxation time.^{10–12}

Magnets are the main element for the generation of images, since they provide the “external” magnetic field to which the patient is subjected. The force generated by the magnet will determine the strength of the field, which is measured in Tesla (T) or Gauss (G); a Tesla unit is equivalent to 10,000 Gauss units. Magnetic field strength may vary between mild (0.1–0.5 T), medium (0.5–1.2 T), high (1.5 T), and ultrahigh (3 and more).^{10,11} In daily clinical practice, frequencies between 0.2 T and 2 T are more commonly used; however, there are places where up to 3 T is used and in research centers there are resonators that use up to 8 T.³ Each exposure type has its risks for both the mother and the fetus.

Gadolinium as a contrast agent

Gadolinium belongs to a series of elements called lanthanides, which are chemically unpredictable and usually found in oxidation state +3 (Gd³⁺). Given that its ionic radius is very similar to that of calcium, gadolinium can compete with calcium in all the systems that require it for its operation. Since gadolinium is so similar to calcium, it can alter the kinetics of the biological processes of which calcium form part.^{13,14} Nevertheless, Gd³⁺ can form stable complexes with a variety of organic ligands, preventing the cell consumption of free gadolinium.¹⁵

Gadolinium-based contrast agents act as extracellular space markers, since they are highly paramagnetic due to their 7 unpaired electrons; thus, they can reduce T1 and T2 relaxation times, which leads to an improved signal in T1.¹³ There are several types: (1) Extracellular: They are the most used ones due to their safety profile, complete renal elimination of up to 98% in 24 h, and usefulness in a variety of tumor, inflammatory and angiographic studies.^{10,13,15} (2) Hepatobiliary: They are widely used to study liver injuries due to their biliary excretion. (3) Intravascular: They are used almost exclusively in angiography due to their longer intravascular half-life, which allows the extension of the study beyond the arterial phase.¹⁰

Safety profile in pregnant women

Many international guidelines present MRI as a relatively safe diagnostic method during pregnancy, which must meet the following criteria: (1) Images must be taken immediately; they cannot wait until after pregnancy is over. (2) It must provide key information that cannot be obtained by any other diagnostic method. (3) The benefits must outweigh the possible risks.^{8,16–20}

Gadolinium is able to cross the placental barrier where it is filtered by the fetal kidney and later is excreted in the amniotic fluid, where it remains for indeterminate time.^{5,8,16,17,19,21} Since the fetus may be at risk for developing conditions such as nephrogenic systemic fibrosis, it is recommended not to use it routinely.⁹ If needed, it should be administered in the lowest possible doses to achieve the desired effect and its use should be avoided during breastfeeding (although only a very small quantity will pass into milk).^{22,24}

If it is necessary to use MRI, several recommendations must be followed to improve safety profile, such as reducing the sound exposure of the fetus,^{17,18} using the scanner in normal mode when possible, and using the controlled mode only if the benefits outweigh the risks.^{9,18,22}

Regarding when to perform the procedure, according to the UK radiation protection group, it is “prudent” to exclude patients during the first trimester of pregnancy. However, the American College of Radiologists considers it to be a safe method in any quarter.^{16,23,24} In general, the use of MRI up to 3 T is considered safe during the second and third trimesters.^{5,24}

There are few studies on the exposure of pregnant workers to MRI scanners; it is recommended, however, that they remain outside the area at the time of imaging.^{9,16}

Results

Acoustic damage

When performing an MRI, it is necessary for both the staff and patients to wear hearing protection devices when the sound range is more than 85 dB in 8 h or 100 dB in 15 min, since magnetic resonators produce high noise levels.²⁵ The sound is due to the vibration produced by magnetic field combination and the rapid change of current in the coil; sound intensity, however, changes according to the intensity used for the scanner.^{3,9,21,25}

There are studies that suggest a possible risk of exposing the fetus to MRI scanners. One of the studies followed a group of children who underwent magnetic resonance imaging in echo-planar sequence while in the uterus. Two of the 18 patients did not get satisfactory hearing tests at 8 months after birth.²⁶ Nevertheless, the sample is considered too small to draw reliable conclusions. In another study, a microphone was placed in a fluid-filled stomach, which intended to simulate the acoustic environment of the gravid uterus, and sound intensity was measured while performing an MRI, evidencing sound attenuation greater than 30 dB.²⁷ Although the experimental conditions were not exactly the same as the environment of the fetus, this study indirectly shows that the risk of acoustic damage is lower in the fetus than in the mother. To date, reports of acoustic damage when using magnetic resonance imaging during pregnancy are scarce and inconclusive. However, it is not possible to rule out its potential harmfulness.

Teratogenic effects

In general, the effects of electromagnetic fields depend on several factors, such as cell type, efficiency of the DNA repair, mode of exposure, radio frequency pulses, intensity and duration of exposure, and the use of contrast agents.²⁸ There have been found multiple effects of MRI on different cell lines. For example, a study using a 4.7T static magnetic field in rabbits found that this possibly stimulated fetal endochondral ossification by boosting cell differentiation, not at the level of DNA synthesis, but by increasing vascular endothelial growth factor.²⁹ Another possible effect may be the activation of cascades associated with cellular differentiation and proliferation of second messengers.³⁰

Most studies of teratogenic effects are based on animal models and are difficult to extrapolate to humans; however, there have been reports of malformations secondary to MRI exposure. For example, one study described a reduction in crown-rump length when exposing pregnant mice to magnetic fields for 16 h on day 9 of gestation.³¹

Another study found a higher rate of ocular malformations in litters of mice exposed to magnetic fields of 1.5 T.³² Finally, a study exposed chick embryos at different stages of development to a static magnetic field of 1.5 T for 6 h and found that the group in the period of organogenesis (6th day of incubation) showed more physical abnormalities.³³

When talking about tissue exposure to the effects of an MRI scanner the main problem is not cell death *per se*, but the process of DNA repair; given its complexity, it may result in mutations and carcinogenesis, especially in the long term due to a cumulative effect on the cells.³⁴ A group of researchers found that prolonged exposure to magnetic fields causes DNA strand breaks, leading to apoptosis and cell necrosis in the brain of mice. They proposed a possible explanation for this phenomenon, which happens in two steps. First, exposure to magnetic fields alters cellular homeostasis, leading to increased free cellular iron in cytoplasm and nucleus, which increases the number of free radicals and induces DNA, lipid and protein damage, by inducing calcium escape from intracellular storage sites. The second step consists of an increased synthesis of nitric oxide due to an increase in calcium levels, which results in the

exponential formation of free radicals by directly influencing iron metabolism.³⁵

Another study attempted to replicate the conditions of the previous study and found no evidence that exposure to magnetic fields would cause damage to the adult or immature brain cells of rats.³⁶ However, a group of researchers, after studying human blood cells following a 1.5 T exposure, found an increase in DNA double-strand breaks in lymphocytes; although the damage was minimal and did not lead to lymphocyte apoptosis or activation, the effect lasted up to one month after exposure, even though some level of DNA repair appeared to happen in 24 h.^{7,9} These results on DNA damage are shared by multiple studies.^{34,37,38} They are also discussed by many others that did not find DNA alterations when studying blood cells^{39,40} or other cell types.⁴¹

Physical deformations due to temperature increase

The most frequently reported accident due to MRI exposure in the general population are burns.³ Most of the radio frequency energy transmitted by the scanner is absorbed by the tissue and transformed into heat; the term "specific absorption rate" refers to the amount of heat absorbed by the tissue, which is influenced by different environmental factors.^{2,5,10,42} Manufacturers of MRI scanners must comply with an international standard (IEC 60601-2-33:2010), according to which none of the sequences can cause a temperature increase of more than 0.5 °C for normal mode, 1 °C for controlled mode, or more than 1 °C for experimental modes. To achieve this, explicit limits are established for specific absorption rate at a room temperature of <24 °C with a humidity of <60%.³

Fetal temperature is linked to maternal temperature, since the fetus has almost no ability to control heat⁴³; in mammals, prenatal growth is the result of highly organized sequences of proliferation, differentiation, migration and apoptosis that are sensitive to changes in temperature. Several windows of vulnerability to temperature have been discovered, particularly during organogenesis, when the central nervous system is more vulnerable to an increase in temperature. In humans, an increase of up to 2 °C in 24 h has been showed to cause a range of neural tube and craniofacial defects.^{3,43} In other mammals, an increase in temperature may result in microencephaly, reduced cerebral cortex thickness, and learning deficiencies.⁴³ However, there is not enough information on exactly what happens in shorter periods of exposure that more closely resemble MRI exposure. In addition, it is believed that heat is concentrated on the maternal surface, so no heat damage occurs in the fetus.^{6,44} However, a study in anesthetized dogs reported a significant increase in the temperature of their internal organs; although the study does not correspond completely to the scenario proposed by this article, it does raise concerns.⁴⁵

Risks associated with the use of gadolinium as a contrast agent

As previously mentioned, gadolinium can be detected in the fetus as early as 60 min after being administered intravenously to the mother. In its free form, gadolinium can

interfere with calcium-dependent physiological processes; it can also inhibit some enzymes, depress the reticuloendothelial system, increase the expression of hepatic cytokines, induce neuronal apoptosis secondary to mitochondrial dysfunction even at low concentrations, and induce diseases such as nephrogenic systemic fibrosis in patients with advanced kidney disease.^{13,46,47} Multiple studies have attempted to test the safety of gadolinium during pregnancy; for example, a study of 26 pregnant women exposed to gadopentetate in the periconceptional period and first trimester of gestation reported 2 miscarriages and one baby was born with genetic disorder. However, these numbers were not representative of the general population and therefore the results were not attributed to the use of this contrast agent.⁴⁸ Another study exposed rabbits to gadobenate dimeglumine at doses of 0.3, 0.9 and 2 mmol/kg, and reported anorexia and slight weight loss at a dose of 0.9 mmol/kg/day, and weight loss and marked anorexia, irregularities in the retina, microphthalmia, endochondral ossification of segments of the sternum, and/or thoracolumbar vertebrae at a dose of 2 mmol/kg/day.⁴⁹ Another study in mice that used anaphase bridges as markers of chromosomal defects failed to demonstrate an increase in morphological changes, early abortions, fetal deaths or unstable chromosomal changes when using gadopentetate dimeglumine in magnetic resonance imaging.⁵⁰

Much information is needed regarding the effects and safety of gadolinium during pregnancy due to the lack of conclusive studies in this regard; however, it is advisable to avoid the use of gadolinium during the first trimester.¹³

Discussion

Magnetic resonance imaging is widely used for the study of various diseases, since it has a good safety profile compared to other diagnostic methods, which expose the patient to risks associated with radiation. To date, there is little information about the real risks that MRI resonators might have on the general population and pregnant women, with most studies being done on animal models that are difficult to extrapolate to the human species.

Magnetic fields may exert influence on biological systems by generating electric fields, changing their properties and catalyzing reactions that involve free radicals. This review examined the four main possible effects of magnetic resonance imaging on the fetus, with the first one being acoustic damage, which, due to the lack of recent studies, is considered more a theoretical risk than a practical one, a problem which warrants further study. The second effect explored in the article was the risk of physical deformities in the fetus due to temperature increase, which seems to be one of the most real dangers, since heat damage is evidenced in both animal and human models.^{3,43} Consequently, MRI resonators have to comply with quality standards. It is assumed that if manufacturer recommendations and safety guidelines are followed, the risk of this type of complications, although real, is low.³ The third aspect was the effects of gadolinium as a contrast agent, and this study found that despite the considerable number of studies that aim to demonstrate the

harmful effects of this compound in animals, especially in the period of organogenesis, there is no conclusive information on this subject. Nevertheless, as a precautionary measure, it is advisable to avoid the use of gadolinium during the first trimester.¹³ The fourth and last point explored in the article was teratogenesis and DNA damage. It was found that the use of magnetic resonance imaging causes single- and double-strand DNA damage and these effects can last up to one month.^{1,28}

It is pertinent to clarify that there are parameters able to influence the results of these studies, such as temperature, field strength, and time of exposure.^{8,9} Before arriving at any conclusions, it is important to carry out further studies to examine the interaction among the three types of electromagnetic fields generated by scanners, taking into account that MRI exposure can enhance the damage produced by other genotoxic agents, such as epigenetic factors.¹

Conclusions

The greatest limitation found in this study was the lack of information on the effects of magnetic resonance imaging on the fetus; in addition, it was found that most studies use animal models that are difficult to extrapolate to humans.

The main finding and what causes more concern is DNA damage, which would require further studies that review the long-term implications of genetic mutations and carcinogenesis.

Regarding recommendations, it is advised that the benefits always outweigh the risks when performing this type of interventions and even more when studies do not completely endorse its safety. Professionals must make the decision they consider appropriate after consulting with the patient, using the informed consent as a measure of mutual protection.

Financing

No funding was received from any private or public institution.

Conflict of interests

Authors have no conflict of interests to declare.

Appendix 1. Distribution of the reviewed articles by topics

Descriptive table of articles on DNA damage and/or teratogenic effects.

Descriptive table of articles on general effects and patient safety.

Descriptive table of articles on the effects of gadolinium.

Descriptive table of articles on effects on the hearing system.

Descriptive table of articles on heat-induced effects.

No.	Title	Author	Journal	Topic	Type of study
1	Magnetic resonance imaging (MRI): A review of genetic damage investigations	Vijayalaxmi et al., 2015	Mutation Research	DNA damage and/or teratogenic effects	Narrative review
2	Impact of cardiac magnetic resonance imaging on human lymphocyte DNA integrity	Fiechter et al., 2013 ³⁷	European Heart Journal	DNA damage and/or teratogenic effects	Experimental study in humans
3	Biological effects of cardiac magnetic resonance on human blood cells	Lancellotti et al., 2015 ²⁸	Circulation: Cardiovascular Imaging	DNA damage and/or teratogenic effects	Experimental study in humans
4	Genotoxic effects of 3 T magnetic resonance imaging in cultured human lymphocytes	Lee et al., 2011 ³⁸	Bioelectromagnetics	DNA damage and/or teratogenic effects	Experimental study <i>in vitro</i>
5	Is the genotoxic effect of magnetic resonance negligible? Low persistence of micronucleus frequency in lymphocytes of individuals after cardiac scan	Simi et al., 2008 ³⁴	Mutation Research	DNA damage and/or teratogenic effects	Experimental study <i>in vitro</i>
6	Effects of a 4.7T static magnetic field on fetal development in ICR mice	Okazaki et al., 2001 ²⁹	Journal of Radiation Research	DNA damage and/or teratogenic effects	Experimental study in animals
7	Influence of strong static magnetic fields on primary cortical neurons	Prina-Mello et al., 2006 ³⁰	Bioelectromagnetics	DNA damage and/or teratogenic effects	Experimental study in animals
8	Midgestational exposure of pregnant BALB/c mice to magnetic resonance imaging conditions	Heinrichs et al., 1988 ³¹	Journal of Magnetic Resonance Imaging	DNA damage and/or teratogenic effects	Experimental study in animals
9	Effects of magnetic resonance imaging on eye development in the C57BL/6 J mouse	Tyndall and Sulik, 1991 ³²	Teratology	DNA damage and/or teratogenic effects	Experimental study in animals
10	Effects of MR exposure at 1.5 T on early embryonic development of the chick	Yip et al., 1994 ³³	Journal of Magnetic Resonance Imaging	DNA damage and/or teratogenic effects	Experimental study in animals
11	Magnetic field-induced DNA strand breaks in brain cells of the rat	Lai and Singh, 2004 ³⁵	Environmental Health Perspectives	DNA damage and/or teratogenic effects	Experimental study in animals
12	Evaluating DNA damage in rodent brain after acute 60 Hz magnetic-field exposure	McNamee et al., 2005 ³⁶	Radiation Research	DNA damage and/or teratogenic effects	Experimental study in animals
13	DNA double-strand breaks and micronuclei in human blood lymphocytes after repeated whole body exposures to 7 T Magnetic Resonance Imaging	Fatahi et al., 2016 ³⁹	NeuroImage	DNA damage and/or teratogenic effects	Experimental study in humans
14	Influence of Cardiac MR Imaging on DNA Double-Strand breaks in human blood lymphocytes	Brand et al., 2015 ⁴⁰	Radiology	DNA damage and/or teratogenic effects	Experimental study in humans
15	Repeated exposure of the developing rat brain to magnetic resonance imaging did not affect neurogenesis, cell death or memory function	Zhu et al., 2011 ⁴¹	Biochemical and Biophysical Research Communications	DNA damage and/or teratogenic effects	Experimental study in animals

16	Dealing with pregnancy in radiology: a thin line between science, social and regulatory aspects	Buls et al., 2009 ⁹	Journal of the Belgian Society of Radiology	General effects and patient safety	Narrative review
17	ACR Practice Guideline for Imaging Pregnant or Potentially Pregnant Adolescents and Women With Ionizing Radiation	Guenin et al., 2008 ⁵¹	The American College of Radiology	General effects and patient safety	Clinical practice guidelines
18	SOGC clinical practice guideline for the use of magnetic resonance imaging in the obstetric patient	Patenaude et al., 2014 ⁵	Journal of the Society of Obstetricians and Gynecologists of Canada	General effects and patient safety	Clinical practice guidelines
19	What are the risks of ultrasound and MRI to the fetus?	Wozniak, 2009 ⁶	Future Science Group	General effects and patient safety	Narrative review
20	Magnetic resonance imaging in fetal medicine: a pictorial review of current and developing indications	Weston, 2012 ⁴	British Medical Journal	General effects and patient safety	Clinical practice guidelines
21	ACR Guidance Document on MR Safe Practices: 2013	Kanal et al., 2013 ¹⁶	Journal of Magnetic Resonance Imaging	General effects and patient safety	Clinical practice guideline
22	RANZCR MRI Safety Guidelines	The Royal Australian and New Zealand College of Radiologists, 2007 ¹⁷	The Royal Australian and New Zealand College of Radiologists	General effects and patient safety	Clinical practice guidelines
23	Safety in Magnetic Resonance Imaging	Lipton, 2013 ¹⁸	Society of Radiographers	General effects and patient safety	Clinical practice guidelines
24	Guidelines for Computed Tomography and Magnetic Resonance Imaging Use During Pregnancy and Lactation	Chen et al., 2008 ²¹	Obstetrics & Gynecology	General effects and patient safety	Clinical practice guidelines
25	Safety guidelines for magnetic resonance imaging equipment in clinical use	Medicines and Healthcare Products Regulatory Agency, 2014 ²²	MHRA Guidelines	General effects and patient safety	Clinical practice guidelines
26	MRI: a developing technique for the developing patient	Coackley et al., 2004 ²⁴	Journal of Magnetic Resonance Imaging	General effects and patient safety	Narrative review
27	Safety considerations in MR imaging	Kanal et al., 1990 ⁴⁴	Radiology	General effects and patient safety	Narrative review
28	MR procedures: biologic effects, safety, and patient care	Shellock and Crues, 2004 ²⁰	Radiology	General effects and patient safety	Clinical practice guidelines

29	Extracellular gadolinium-based contrast media: an overview	Bellin et al., 2008 ¹³	European Journal of Radiology	Effects of gadolinium	Narrative review
30	Contrast-enhanced peripheral MRA: technique and contrast agents	Nielsen and Thomsen, 2012 ¹⁵	Acta Radiologica	Effects of gadolinium	Narrative review
31	ACR Manual on Contrast Media Version 10.2	ACR Committee on Drugs and Contrast Media, 2016 ¹⁹	American College of Radiology	Effects of gadolinium	Clinical practice guidelines
32	Effect of magnetic resonance exposure combined with gadopentetate dimeglumine on chromosomes in animal specimens	Rofsky et al., 1995 ⁵⁰	Academic Radiology	Effects of gadolinium and patient security	Experimental study in animals
33	Reproductive and developmental toxicity study of gadobenate dimeglumine formulation (E7155). Study of embryo-fetal toxicity in rabbits by intravenous administration	Okuda et al., 1999 ⁴⁹	Journal of Toxicological Sciences	Effects of gadolinium	Experimental study in animals
34	Impaired mitochondrial function and oxidative stress in rat cortical neurons: Implications for gadolinium-induced neurotoxicity	Feng et al., 2010 ⁴⁶	NeuroToxicology	Effects of gadolinium	Experimental study in animals
35	Gadolinio y fibrosis sistémica nefrogénica [Gadolinium and nephrogenic systemic fibrosis]	Cejas and Acuna, 2012 ⁴⁷	Imagen Diagnóstica	Effects of gadolinium	Narrative review
36	Gadolinium periconceptional exposure: pregnancy and neonatal outcome	De Santis et al., 2007 ⁴⁸	Acta Obstetrica et Gynecologica Scandinavica	Effects of gadolinium	Experimental study in humans
37	An assessment of the intrauterine sound intensity level during obstetric echo-planar magnetic resonance imaging	Glover et al., 1995 ²⁷	The British Journal of Radiology	Effects on the hearing system	Experimental study in humans
38	A three year follow-up of children imaged <i>in utero</i> with echo-planar magnetic resonance	Baker et al., 1994 ²⁶	American Journal of Obstetrics and Gynecology	Effects on the hearing system	Prospective cohort study
39	Radiofrequency energy-induced heating during MR procedures: a review	Shellock, 2000 ⁵²	Journal of Magnetic Resonance Imaging	Heat-induced effects	Narrative review
40	Effects of heat in embryos and fetuses	Edwards et al., 2003 ⁵³	International Journal of Hyperthermia	Heat-induced effects	Experimental study in animals
41	Superficial and deep-tissue increases in anesthetized dogs during exposure to high specific absorption rates in a 1.5 T MR imager	Shuman et al., 1988 ⁴⁵	Radiology	Heat-induced effects	Experimental study in animals

References

1. Fatahi M, Speck O. Magnetic resonance imaging (MRI): a review of genetic damage investigations. *Mutat Res Rev Mutat Res.* 2015;764:51–63. Available from: [doi:10.1016/j.mrrev.2015.02.002](https://doi.org/10.1016/j.mrrev.2015.02.002) [accessed 24.03.16].
2. Santos X, Papanna R, Johnson A, Cass D, Oluyinka O, Moise K, et al. The use of combined ultrasound and magnetic resonance imaging in the detection of fetal anomalies. *Prenat Diagn.* 2010;26:980–4.
3. De Wilde JP, Rivers AW, Price DL. A review of the current use of magnetic resonance imaging in pregnancy and safety implications for the fetus. *Prog Biophys Mol Biol.* 2005;87:335–53 [2–3 special issue].
4. Weston MJ. Magnetic resonance imaging in fetal medicine: a pictorial review of current and developing indications. *Postgrad Med J.* 2010;1011:42–51.
5. Patenaude Y, Pugash D, Lim K, Morin L, Diagnostic Imaging Committee, Lim K, et al. The use of magnetic resonance imaging in the obstetric patient. *J Obstet Gynaecol Can.* 2014;36:349–63. Available from: <http://www.ncbi.nlm.nih.gov/pubmed/24798674> [accessed 24.03.16].
6. Wozniak M. What are the risks of ultrasound and MRI to the fetus? *Futur Sci Gr.* 2012;4:565–72.
7. Verburg B, Fink AM, Reidy K, Palma-Dias R. The contribution of MRI after fetal anomalies have been diagnosed by ultrasound: correlation with postnatal outcomes. *Fetal Diagn Ther.* 2015;38:186–94.
8. Brown J, Owen R, Brink J, American College of Radiology. ACR practice parameter for performing and interpreting magnetic resonance imaging (MRI). *Am Coll Radiol.* 2014;1076:1–8.
9. Buls N, Covens P, Nieboer K, van Schuerbeek P, Devacht P, Eloot L, et al. Dealing with pregnancy in radiology: a thin line between science, social and regulatory aspects. *JBR-BTR.* 2009;92:271–9.
10. Zaer NF, Amini B, Elsayes KM. Overview of diagnostic modalities and contrast agents. In: Elsayes KM, Oldham SAA, editors. *Introduction to diagnostic radiology.* New York, NY: McGraw-Hill Education; 2015. Available from: <http://mhmedical.com/content.aspx?aid=1115257266>
11. Jacobs MA, Ibrahim TS, Ouwkerk R. AAPM/RSNA physics tutorial for residents: MR imaging: brief overview and emerging applications. *Radiographics.* 2007;27:1213–29.
12. Bottomley PA, Foster TH, Argersinger RE, Pfeifer LM. A review of normal tissue hydrogen NMR relaxation times and relaxation mechanisms from 1–100 MHz: dependence on tissue type, NMR frequency, temperature, species, excision, and age. *Med Phys.* 1984;11:425. Available from: <http://scitation.aip.org/content/aapm/journal/medphys/11/4/10.1118/1.595535> [accessed 24.03.16].
13. Bellin MF, van der Molen AJ. Extracellular gadolinium-based contrast media: an overview. *Eur J Radiol.* 2008;66:160–7.
14. Sherry DA. A primer on gadolinium chemistry. *J Magn Reson Imaging.* 2010;30:1240–8.
15. Nielsen YW, Thomsen HS. Contrast-enhanced peripheral MRA: technique and contrast agents. *Acta Radiol.* 2012;53:769–77. Available from: <http://www.ncbi.nlm.nih.gov/pubmed/22843836> [accessed 24.03.16].
16. Kanal E, Barkovich AJ, Bell C, Borgstede JP, Bradley WG, Froelich JW, et al. ACR guidance document on MR safe practices: 2013. *J Magn Reson Imaging.* 2013;37:501–30.
17. The Royal Australian and New Zealand College of Radiologists. RANZCR MRI safety guidelines; 2007. p. 3030.
18. Lipton A. Safety in magnetic resonance imaging. *Soc Radiogr.* 2013;1–26.
19. ACR Committee on Drugs and Contrast Media. ACR manual on contrast media, version 10.2. ACR Committee on Drugs and Contrast Media; 2013.
20. Shellock FG, Crues JV. MR procedures: biologic effects, safety, and patient care. *Radiology.* 2004;232:635–52.
21. Chen MM, Coakley FV, Kaimal A, Laros RKJ. Guidelines for computed tomography and magnetic resonance imaging use during pregnancy and lactation. *Obstet Gynecol.* 2008;112(Part 1):333–40. <http://dx.doi.org/10.1097/AOG.0b013e318180a505>. Available from: http://journals.lww.com/greenjournal/Fulltext/2008/08000/Guidelines_for_Computed_Tomography_and_Magnetic.22.aspx [accessed 24.03.16].
22. Medicines and Healthcare products Regulatory Agency. Safety guidelines for magnetic resonance imaging equipment in clinical use. MHRA Guidel. 2014;2014:104.
23. Kanal E, Barkovich AJ, Bell C, Borgstede JP, Bradley WG, Froelich JW, et al. ACR guidance document for safe MR practices: 2007. *Am J Roentgenol.* 2007;188:1447–74.
24. Coakley FV, Glenn OA, Qayyum A, Barkovich AJ, Goldstein R, Filly RA. Fetal MRI: a developing technique for the developing patient. *Am J Roentgenol.* 2004;182:243–52.
25. Price DL, Wilde JPde, Papadaki AM, Curran JS, Kitney RI. Investigation of acoustic noise on 15 MRI scanners from 0.2 T to 3 T. *J Magn Reson Imaging.* 2001;293:288–93.
26. Baker P, Johnson I, Gowland P, Mansfield P. A three year follow-up of children imaged in utero with echo-planar magnetic resonance. *Am J Obstet Gynecol.* 1994;170:33.
27. Glover P, Hykin J, Gowland P, Wright J, Johnson I, Mansfield P. An assessment of the intrauterine sound intensity level during obstetric echo-planar magnetic resonance imaging. *Br J Radiol.* 1995;68:1090–4.
28. Lancellotti P, Nchimi A, Delierneux C, Hego A, Gosset C, Gothot A, et al. Biological effects of cardiac magnetic resonance on human blood cells. *Circ Cardiovasc Imaging.* 2015;8:e003697. Available from: <http://circimaging.ahajournals.org/lookup/doi/10.1161/CIRCIMAGING.115.003697%5Cnhttp://www.ncbi.nlm.nih.gov/pubmed/26338876> [accessed 24.03.16].
29. Okazaki R, Ootsuyama A, Uchida S, Norimura T. Effects of a 4.7 T static magnetic field on fetal development in ICR mice. *J Radiat Res.* 2001;42:273–83.
30. Prina-Mello A, Farrell E, Prendergast PJ, Campbell V, Coey JMD. Influence of strong static magnetic fields on primary cortical neurons. *Bioelectromagnetics.* 2006;27:35–42.
31. Heinricks WL, Fong P, Flannery S, Heinricks LE, Crooks A, Spindle A, et al. Midgestational exposure of pregnant BALB/c mice to magnetic resonance imaging conditions. *Magn Reson Imaging.* 1988:305–14.
32. Tyndall Da, Sulik KK. Effects of magnetic resonance imaging on eye development in the C57BL/6 J mouse. *Teratology.* 1991;43:263–75.
33. Yip Y, Capriotti C, Talagala S, Yip J. Effects of MR exposure at 1.5 T on early embryonic development of the chick. *J Magn Reson Imaging.* 1994;4:742–8.
34. Simi S, Ballardini M, Casella M, de Marchi D, Hartwig V, Giovannetti G, et al. Is the genotoxic effect of magnetic resonance negligible? Low persistence of micronucleus frequency in lymphocytes of individuals after cardiac scan. *Mutat Res Fundam Mol Mech Mutagen.* 2008;645:39–43.
35. Lai H, Singh NP. Magnetic field-induced DNA strand breaks in brain cells of the rat. *Environ Health Perspect.* 2004;112:687–94.
36. McNamee J, Bellier P, Chauhan V, Gajda G, Lemay E, Thansandote A. Evaluating DNA damage in rodent brain after acute 60 Hz magnetic-field exposure. *Radiat Res.* 2005;164:791–7. Available from: <http://www.ncbi.nlm.nih.gov/pubmed/16296885>

37. Fiechter M, Stehli J, Fuchs TA, Dougoud S, Gaemperli O, Kaufmann PA. Impact of cardiac magnetic resonance imaging on human lymphocyte DNA integrity. *Eur Heart J*. 2013;34:2340–5.
38. Lee JW, Kim MS, Kim YJ, Choi YJ, Lee Y, Chung HW. Genotoxic effects of 3T magnetic resonance imaging in cultured human lymphocytes. *Bioelectromagnetics*. 2011;32:535–42.
39. Fatahi M, Reddig A, Friebe B, Hartig R, Prihoda TJ, et al. DNA double-strand breaks and micronuclei in human blood lymphocytes after repeated whole body exposures to 7T magnetic resonance imaging. *Neuroimage*. 2016. Available from: <http://linkinghub.elsevier.com/retrieve/pii/S1053811916002287> [accessed 24.03.16].
40. Brand M, Ellmann S, Sommer M, May MS, Eller A, Wuest W, et al. Influence of cardiac MR imaging on DNA double-strand breaks in human blood lymphocytes. *Radiology*. 2015;277:406–12.
41. Zhu C, Gao J, Li Q, Huang Z, Zhang Y, Li H, et al. Repeated exposure of the developing rat brain to magnetic resonance imaging did not affect neurogenesis, cell death or memory function. *Biochem Biophys Res Commun*. 2011;404:291–6. Available from: [doi:10.1016/j.bbrc.2010.11.109](https://doi.org/10.1016/j.bbrc.2010.11.109) [accessed 24.03.16].
42. Knuuti J, Saraste A, Kallio M, Minn H. Is cardiac magnetic resonance imaging causing DNA damage? *Eur Heart J*. 2013;34:2337–9.
43. Edwards MJ, Saunders RD, Shiota K. Effects of heat on embryos and fetuses. *Int J Hyperther*. 2006;3:295–324.
44. Kanal E, Shellock FG, Talagala L. Safety considerations in MR imaging. *Radiology*. 1990;176:593–606.
45. Shuman W, Haynor D, Guy A, Websy G, Schaefer DJ, Moss A. Superficial and deep-tissue increases in anesthetized dogs during exposure to high specific absorption rates in a 1.5T MR imager. *Radiology*. 1988;167:551–4.
46. Feng X, Xia Q, Yuan L, Yang X, Wang K. Impaired mitochondrial function and oxidative stress in rat cortical neurons: implications for gadolinium-induced neurotoxicity. *Neurotoxicology*. 2010;31:391–8. Available from: [doi:10.1016/j.neuro.2010.04.003](https://doi.org/10.1016/j.neuro.2010.04.003) [accessed 24.03.16].
47. Cejas C, Acuña C. Gadolinio y fibrosis sistémica nefrogénica. *Rev Arg Radiol*. 2012;76:145–9.
48. De Santis M, Straface G, Cavaliere AF, Carducci B, Caruso A. Gadolinium periconceptual exposure: pregnancy and neonatal outcome. *Acta Obstet Gynecol Scand*. 2007;86:99–101.
49. Okuda Y, Sagami F, Tirone P, Morisetti A, Bussi S, Masters R. Reproductive and developmental toxicity study of gadobenate dimeglumine formulation (E7155) – study of embryo-fetal toxicity in rabbits by intravenous administration. *J Toxicol Sci*. 1999;24.
50. Rofsky NM, Pizzarello DJ, Duhaney MO, Falick AK, Prendergast N, Weinreb JC. Effect of magnetic resonance exposure combined with gadopentetate dimeglumine on chromosomes in animal specimens. *Acad Radiol*. 1995;2:492–6.
51. Guenin MA, Brody AS, Wagner LK, Robert P, Guillerman TC. ACR practice guideline for imaging pregnant or potentially pregnant adolescents and women with ionizing radiation. 2008 (revised 2008); 1076: 23–37.
52. Shellock FG. Radiofrequency energy-induced heating during MR procedures: a review. *J Magn Reson Imaging*. 2000;12:30–6.
53. Edwards MJ, Saunders RD, Shiota K. Effects of heat in embryos and fetuses. *Int J Hyperther*. 2003;295–324.