



Case Report

Renal amyloidosis in ankylosing spondylitis: A case report



Juan David Romero-Marín^a, Yeison Cantor^b, Esteban Prieto-Bravo^c,
Reinaldo Sierra-Rosales^d, Adriana Flórez-Vargas^e, Miguel Antonio Mesa-Navas^f,
Carlos Jaime Velásquez-Franco^{f,*}

^a Internal Medicine Department, IPS Universitaria, Medellín, Colombia

^b School of Health Sciences, Universidad Pontificia Bolivariana, Medellín, Colombia

^c Orthopedics Department, Universidad Pontificia Bolivariana, Medellín, Colombia

^d Nephrology Department, SURA EPS, Medellín, Colombia

^e Pathology Department, Hospital Universitario Fundación Santa Fe de Bogotá, Bogotá, Colombia

^f Rheumatology Department, Clínica Universitaria Bolivariana, School of Health Sciences Universidad Pontificia Bolivariana, Medellín, Colombia

ARTICLE INFO

Article history:

Received 28 December 2018

Accepted 2 April 2019

Available online 17 February 2020

Keywords:

Amyloidosis

Kidney

Ankylosing Spondylitis

ABSTRACT

Renal manifestations of spondyloarthritis are rare. The case is presented of a patient with ankylosing spondylitis of nine years of evolution. He had intense inflammation, as well as articular sequelae, with a significant deterioration in his quality of life. At the initial evaluation, the patient had a serum creatinine of 1.44 mg/dL and a 24-h urine protein in the sub-nephrotic range (1.44 g). Renal biopsy showed the presence of Congoophilic material, confirming the diagnosis of AA amyloidosis. Treatment with a TNF blocking agent was initiated with clinical improvement, especially regarding articular disease.

© 2020 Asociación Colombiana de Reumatología. Published by Elsevier España, S.L.U. All rights reserved.

Amiloidosis renal en espondilitis anquilosante: un reporte de caso

RESUMEN

Las manifestaciones renales de la espondiloartritis son poco comunes. Se presenta el caso de un paciente con espondilitis anquilosante de 9 años de evolución, con intensa inflamación y secuelas articulares y con un deterioro significativo en su calidad de vida. En la evaluación inicial, el paciente tenía una creatinina sérica de 1,44 mg/dL y una proteína en orina de 24 horas en un rango subnefrótico (1,44 g). La biopsia renal mostró la presencia de material

Palabras clave:

Amiloidosis

Riñón

Espondilitis anquilosante

* Corresponding author.

E-mail address: carjaivel@gmail.com (C.J. Velásquez-Franco).

<https://doi.org/10.1016/j.rcreu.2019.04.004>

0121-8123/© 2020 Asociación Colombiana de Reumatología. Published by Elsevier España, S.L.U. All rights reserved.

congofílico que confirmaba el diagnóstico de amiloidosis AA. Se inició tratamiento con un anti-TNF, con mejoría clínica, especialmente con respecto al componente articular.

© 2020 Asociación Colombiana de Reumatología. Publicado por Elsevier España, S.L.U. Todos los derechos reservados.

INTRODUCTION

The prevalence of ankylosing spondylitis is up to 1.5% in the general population.¹ When reviewing its visceral involvement,^{2,3} the kidney is rarely affected. In a series of 681 patients, abnormal findings in the urinalysis were found in 8%. Six of these patients underwent renal biopsy due to 24-h urine protein greater than 1 g with only one case of amyloidosis detected. After reviewing the literature, few case reports of this manifestation were found, with two case series of 13 subjects as the largest reports.^{4,5}

Case report

Patient information

A 29-year-old man, from Northwestern Colombia, who since the age of 20 years referred inflammatory back pain, arthritis and morning stiffness in knees and ankles. The symptoms did not respond to non-steroidal anti-inflammatory drugs, and the clinical picture had been classified as rheumatoid arthritis and treated with prednisone 10–15 mg/day since then. Due to deterioration in his general condition, considerable weight loss and difficulties in the control of his musculoskeletal symptoms, the patient was admitted to our hospital. Aside from his rheumatological disease, his medical, family and psychosocial history did not have any relevant findings.

Clinical findings

Physical examination revealed an emaciated patient, with bilateral synovitis on knees and ankles. Additionally, the patient had a limitation on spinal movement with a modified Schober test of 1 cm and lateral inclination of 5 cm (height: 150 cm).

Diagnostic approach

Due to inflammatory back pain, pelvic X-rays were requested, with evidence of bilateral grade III sacroiliitis (Fig. 1).

Blood chemistry evidenced systemic inflammation and creatinine elevation, of unknown duration due to the absence of previous results (Table 1). In subsequent studies, progressive deterioration in the glomerular filtration rate was evidenced (raising of serum creatine from 1.44 to 1.68 mg/dL in 48 h). Therefore, it was concluded that there was an acute intrarenal component with subnephrotic proteinuria and renal biopsy was obtained.

The renal biopsy showed intraglomerular congophilic deposits, in the absence of immunoglobulins or other

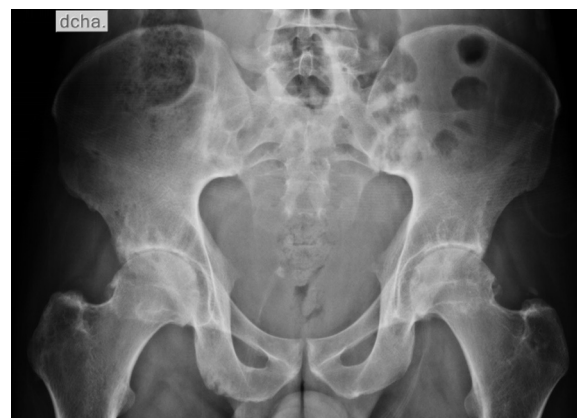

Fig. 1 – Anteroposterior projection of the pelvis showing changes of enthesopathy and bilateral grade III sacroiliitis, confirming the diagnosis of ankylosing spondylitis.

Table 1 – Lab tests.

Parameter	Value	Range
Creatinine (mg/dL)	1.44	0.7–1.3
Blood urea nitrogen (mg/dL)	17	6–20
24-h urine protein (milligrams)	1460	<100 mg
Transferrin saturation (%)	6	20–50
Ferritin (ng/mL)	153	12–330
Vitamin B12 (pg/mL)	852	200–900
Folic acid (ng/mL)	8.3	2.7–17
C-reactive protein (mg/dL)	17	<1
Erythrocytation rate (mm/h)	120	<15
Albumin (g/dL)	2.13	3.4–5.4
Hemoglobin (g/dL)	8.6	13.8–17.2
Mean corpuscular volume (fL)	79	80–100
Platelets (mm ³)	555,000	150,000–450,000
Human immunodeficiency virus	Negative	Negative
Hepatitis B virus	Negative	Negative
Hepatitis C virus	Negative	Negative
HLA-B27	Positive	Negative

immune deposits and the amyloid found was typified as AA, thus confirming the diagnosis of renal amyloidosis (Fig. 2A–D). Additional studies for plasma cell diseases were negative.

Therapeutic intervention and follow-up

Due to axial and peripheral inflammatory involvement, adalimumab was started at a dosage of 40 mg every other week, with renal function improvement at 72 h (creatinine from 1.56 mg% to 1.07 mg%)

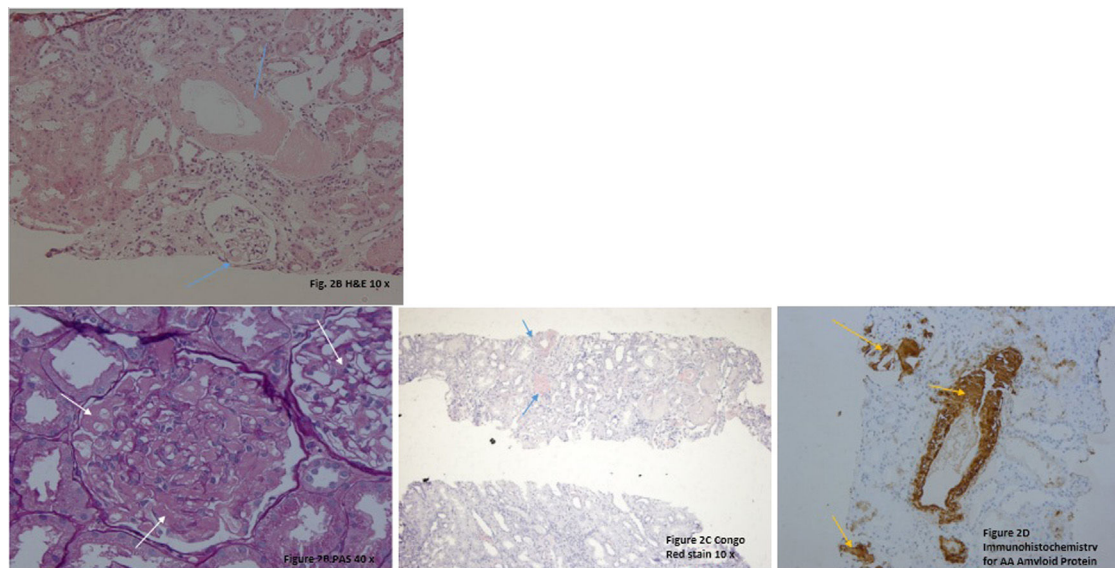


Fig. 2 – A. H&E 20x. There are some glomeruli and vessels with a material deposited mainly in the mesangial areas and vascular wall (blue arrows). **B. PAS 40x.** Note in this glomerulus the PAS negative material filling the mesangial areas and spreading through the subendothelial aspect of the glomerular basement membranes (white arrows). **C. Congo Red Stain demonstrating the congophilia of the deposited material (blue arrows).** Polarization was performed, and an apple green birefringence was obtained (not shown). **D. Immunohistochemistry for AA Amyloid Protein showing positivity in the glomeruli and in vascular walls (yellow arrows).**

Discussion

Renal involvement in ankylosing spondylitis is rare and often overlooked, due to the tendency to appear late in the natural evolution of the disease and a decrease in its incidence secondary to better control of inflammation, as well as a reduction in the use of non-steroidal antiinflammatory drugs (NSAIDs) after the introduction of biological therapy.⁶ In a cohort of 8616 patients, it was found that the risk of renal disease is 70% higher than in the general population, being much more common in individuals aged between 20 and 39 years, with a prevalence of 3.4% in men and 2.1% in women, much lower than those described in the previous literature.³ Likewise, in a cohort in whom kidney disease was actively sought, laboratory alterations were documented in 8% of the patients: proteinuria (5.9%), hematuria (2.8%), and both (0.7%).⁷ In Colombia, there are two published cohorts: Londoño et al.,⁸ and Márquez et al.⁹; in the first one, there is no description of extraarticular involvement⁸; in the second, they described five patients with renal involvement, yet it was not discriminated.⁹

The three etiologies to be differentiated in these subjects are: IgA nephropathy, tubulointerstitial nephritis due to NSAIDs and AA amyloidosis, entities with important differences in their management and prognosis. There are few data on their distribution due to the low prevalence. In the literature, 90% of the cases are explained by amyloidosis (60%) and IgA nephropathy (30%).¹⁰⁻¹²

It should be noted that this protein deposit does not always cause clinical manifestations, which is illustrated by Gratacos et al., in which 137 patients with a disease of more than five years of evolution underwent biopsy of subcutaneous fat with

successive studies for organ involvement in those with positive Congo red stain. It was found that 7% of the subjects had deposits of amyloid material in the subcutaneous fat, yet only 20% had any clinical findings. It is unknown whether this sub-clinical amyloidosis is a pre-pathogenic phase, with invariably adverse outcomes, or if it corresponds, in some individuals, to a finding with no prognostic or clinical value.¹³

The renal lesion is triggered both by the physical distortion of the glomerular structures and by direct cytotoxicity of the amyloid precursor, after the interaction with membrane receptors and endocytosis, and is usually manifest as proteinuria, which can range from subnephrotic to massive. Kidney injury with proteinuria is the earliest manifestation of AA amyloidosis.¹⁴

The history of our patient was characterized by a progressive evolution influenced by uneven monitoring and lack of access to health services, which allowed inflammation to remain unchecked. This is compatible with what has been previously reported, in which amyloidosis is a late complication appearing as late as ten years after diagnosis, but with cases that present such short intervals as four or five years, especially in those cases with severe and persistent inflammation.¹⁵

Therapeutic strategies for AA amyloidosis are based on the management of the underlying cause; good results have been described with anti-TNF agents in the case of subjects with ankylosing spondylitis. In a case series of patients with AA amyloidosis secondary to rheumatic diseases, six individuals underwent treatment with infliximab, stabilizing creatinine and substantially reducing proteinuria in three of them in a 28-month follow-up.⁶ It is believed that the effect of anti-TNF agents goes beyond the suppression of inflammatory

cytokines and is postulated to be secondary to a decrease in the receptor expression of advanced glycation end products (AGEs), potential mediators for cell toxicity of amyloid precursors.¹⁶⁻²¹

There are few data on the prognosis of these patients; nevertheless, Ahabap et al. reported that the mean renal survival was 64.7 months and the mortality at five years was 48.7%, indicating that a high proportion of patients will progress to end-stage renal disease if untreated. This was associated with high mortality, especially among those presenting with massive proteinuria and hypoalbuminemia.²²

Funding source

Own resources.

Conflict of interests

All authors declare absence of any conflict of interest.

Acknowledgments

Clínica Universitaria Bolivariana and Hospital Universitario Fundación. Santafé de Bogotá.

REFERENCES

- Garg N, van den Bosch F, Deodhar A. The concept of spondyloarthritis: where are we now? *Best Pract Res Clin Rheumatol*. 2014;28:663-72.
- El Maghraoui A. Extra-articular manifestations of ankylosing spondylitis: prevalence, characteristics and therapeutic implications. *Eur J Intern Med*. 2011;22:554-60.
- Levy AR, Szabo SM, Rao SR, Cifaldi M, Maksymowych WP. Estimating the occurrence of renal complications among persons with ankylosing spondylitis. *Arthritis Care Res (Hoboken)*. 2014;66:440-5.
- Dönmez S, Pamuk ÖN, Pamuk GE, Aydoğdu E, Inman R. Secondary amyloidosis in ankylosing spondylitis. *Rheumatol Int*. 2013;33:1725-9.
- Barbouch S, Hajji M, Jaziri F, Aoudia R, Fellah E, Hedri H, et al. Renal amyloidosis in ankylosing spondylitis: a monocentric study and review of literature. *Saudi J Kidney Dis Transpl*. 2018;29:386-91.
- Lee SH, Lee EJ, Chung SW, Song R, Moon JY, Lee SH, et al. Renal involvement in ankylosing spondylitis: prevalence, pathology, response to TNF- α blocker. *Rheumatol Int*. 2013;33:1689-92.
- Samia B, Hazgui F, Abdelghani KB, Hamida FB, Goucha R, Hedri H, et al. Renal abnormalities in ankylosing spondylitis. *Nephrol Ther*. 2012;8:220-5.
- Londoño JD, González LA, Ramírez LA, Santos P, Ávila M, Santos AM, et al. Caracterización de las espondiloartropatías y determinación de factores de mal pronóstico en una población de pacientes colombianos. *Rev Colomb Reumatol*. 2005;12:195-207.
- Márquez J, Pinto LF, Candia DL, Restrepo M, Uribe E, Rincón O, et al. Espondiloartritis en el Hospital Pablo Tobón Uribe Descripción de una cohort. *Rev Colomb Reumatol*. 2010;17:80-5.
- Strobel ES, Fritschka E. Renal diseases in ankylosing spondylitis: review of the literature illustrated by case reports. *Clin Rheumatol*. 1998;17:524-30.
- De Beer FC, Mallya RK, Fagan EA, Lanham JG, Hughes GR, Pepys MB. Serum amyloid-A protein concentration in inflammatory diseases and its relationship to the incidence of reactive systemic amyloidosis. *Lancet Lond Engl*. 1982;2:231-4.
- Real de Asúa D, Costa R, Galván JM, Filigghedu MT, Trujillo D, Cadiñanos J. Systemic AA amyloidosis: epidemiology, diagnosis, and management. *Clin Epidemiol*. 2014;6:369-77.
- Gratacos J, Orellana C, Sanmarti R, Filigheddu MT, Trujillo D, Cadiñanos J. Secondary amyloidosis in ankylosing spondylitis. A systematic survey of 137 patients. *J Rheumatol*. 1997;24:912-5.
- Dember LM. Amyloidosis-associated kidney disease. *J Am Soc Nephrol*. 2006;17:3458-71.
- Rodríguez-Muguruza S, Martínez-Morillo M, Holgado S, Saenz-Sarda X, Mateo L, Tena X, et al. Amyloidosis complicating spondyloarthropathies: study of 15 cases. *Med Clin (Barc)*. 2015;145:327-31.
- Ortiz-Santamaria V. Anti-TNF treatment in secondary amyloidosis. *Rheumatology*. 2003;42:1425-6.
- Fikri-Benbrahim O, Rivera-Hernández F, Martínez-Calero A, Cazalla-Cadenas F, García-Agudo R, Mancha-Ramos J. Treatment with adalimumab in amyloidosis secondary to rheumatoid arthritis: two case reports. *Nefrología*. 2013;33:404-9.
- Lee YH, Kim EY, Jeong DW, Kim YG, Lee SH, Song R, et al. Complete remission of nephrotic syndrome without resolution of amyloid deposit after anti-tumor necrosis factor α therapy in a patient with ankylosing spondylitis. *J Clin Rheumatol*. 2016;22:86-8.
- Yilmaz H, Kocabas H, Erkin G. The effect of etanercept on a case of amyloidosis secondary to ankylosing spondylitis: results of 2-year follow-up. *Acta Reumatol Port*. 2013;38:299-301.
- Bellissimo S, Ferrucci MG, Gallo A, Stisi S. Response to anti-TNF- α treatment for secondary renal amyloidosis in a patient with ankylosing spondylitis. *Reumatismo*. 2007;59:240-3.
- Kobak S, Oksel F, Kabasakal Y, Doganavsargil E. Ankylosing spondylitis-related secondary amyloidosis responded well to etanercept: a report of three patients. *Clin Rheumatol*. 2007;26:2191-4.
- Ahabap E, Kara E, Sahutoglu T, Basturk T, Koc Y, Sakaci T, et al. Outcome of 121 patients with renal amyloid amyloidosis. *J Res Med Sci*. 2014;19:644-9.