
Case Report
Atlantoaxial subluxation revealing rheumatoid arthritis. Case report


Soumaya Boussaid^{a,b,*}, Tebini Houcem^{a,b}, Samia Jammali^{a,b}, Sonia Rekik^{a,b}, Hela Sahli^{a,b}, Elhem Cheour^{b,c}, Mohamed Elleuch^{a,b}

^a Rheumatology Department, Rabta Hospital, Tunis, Tunisia

^b Faculty of Medicine of Tunis, University Tunis el Manar, Tunis, Tunisia

^c Pain Treatment Department, University Tunis el Manar, Tunis, Tunisia

A R T I C L E I N F O
Article history:

Received 1 November 2020

Accepted 23 June 2021

Available online 21 August 2021

Keywords:

Neck pain

Arthritis rheumatoid

Atlantoaxial subluxation

A B S T R A C T

Introduction: Involvement of the cervical spine in rheumatoid arthritis (RA) is frequent and it usually occurs in longstanding disease. Cervical spine involvement as an initial manifestation of the disease is rarely described.

Case description: A 64-year-old patient complaining of inflammatory neck pain. The physical examination was normal apart from pressure pain at the cervical spine. MRI showed an atlantoaxial subluxation and odontoid process inflammatory pannus. Rheumatoid factor and anti-citrullinated peptide antibody were positive. RA was therefore suspected. Ultrasound of the hands confirmed the diagnosis.

Conclusions: The physician must be aware of atypical presentations of RA because of their potential risk.

© 2021 Asociación Colombiana de Reumatología. Published by Elsevier España, S.L.U. All rights reserved.

Subluxación atlantoaxial que revela artritis reumatoide. Reporte de caso
R E S U M E N

Introducción: La afectación de la columna cervical en la artritis reumatoide (AR) es frecuente y suele ocurrir en la enfermedad de larga evolución. Rara vez se describe la afectación de la columna cervical como manifestación inicial de la enfermedad.

Descripción del caso: Paciente de 64 años con dolor de cuello inflamatorio. El examen físico fue normal, salvo dolor por presión en la columna cervical. La resonancia magnética mostró subluxación atlantoaxial y pannus inflamatorio del proceso odontóideo. El factor reumatoide y el anticuerpo antipeptido citrulinado fueron positivos; por tanto, se sospechó AR. La ecografía de las manos confirmó el diagnóstico.

Palabras clave:

Dolor de cuello

Artritis reumatoide

Subluxación atlantoaxial

* Corresponding author.

E-mail address: soumayaboussaid@hotmail.com (S. Boussaid).

<https://doi.org/10.1016/j.rcreu.2021.06.004>

0121-8123/© 2021 Asociación Colombiana de Reumatología. Published by Elsevier España, S.L.U. All rights reserved.

Conclusiones: El médico debe estar atento a las presentaciones atípicas de la AR debido a su riesgo potencial.

© 2021 Asociación Colombiana de Reumatología. Publicado por Elsevier España, S.L.U. Todos los derechos reservados.

Introduction

Rheumatoid arthritis (RA) is the most common inflammatory rheumatism, with a prevalence of up to one percent worldwide.¹ Indeed, the classical presentation of the disease is generally a bilateral and symmetrical polyarticular involvement affecting small joints of the hand as well as the forefoot.¹

Spinal involvement could be observed in RA, particularly after an average of 10 years of disease duration. It is a common event with a prevalence of 14–88%.^{2,3} This involvement is the third most frequent after that of hands and feet^{2,3}; However it is a very unusual form of RA presentation.⁴ Atlantoaxial subluxations dominates damage of the upper cervical spine, mainly related to the C1–C2 pannus and the rupture of the transverse ligament. Silent forms are common, but the clinical presentation is very polymorphic and can range from neck pain neglected by the patient to spinal cord compression.³

We underline in this case a cervical spine involvement as a first manifestation in a patient diagnosed with RA. We obtained the patient's consent for the publication of his personal data for scientific purposes.

Case description

A 64-year-old man with a history of urolithiasis and with no family history of inflammatory rheumatism, was followed in pneumology department for a chronic cough and recurrent bronchitis, diagnosed as diffuse infiltrating pneumopathy. The patient also complained of an eight-year history of isolated inflammatory neck pain which is not improved by paracetamol or rest, but partially improved by non-steroidal drugs. He denied additional musculoskeletal manifestations. Vital signs

were normal as well as chest, abdomen and limb examinations. The neck examination was normal apart from pressure pain in the cervical spine. The musculoskeletal examination was without any abnormalities in particular, there were neither synovitis nor pain at the joints pressure. The neurological examination was normal. X ray of the cervical spine showed C1–C2 diastasis and magnetic resonance imaging (MRI) showed a C1–C2 arthritis, an edematous pannus, an atlantoaxial subluxation with a C1–C2 distance at 4.6 mm, the absence of basilar impression and the absence of morphological or spinal cord signal abnormality (Fig. 1).

C-reactive protein was 11.1 mg/L, rheumatoid factor (RF) and anti-CCP antibodies were strongly positive (318 IU/ml and 200 U/ml, respectively). The diagnosis of RA was therefore suspected and we performed an ultrasound of the hands and feet which revealed an effusion of the right ankle and a synovial hypertrophy of the metatarsal–tarsal joints of the 1st, 2nd, 3rd and 4th range of the foot. The ultrasound study of the hands did not show synovial involvement.

The patient received intravenous methylprednisolone during the first three days at the dose of 500 mg a day. He received methotrexate at a dose of 15 mg per week. A suitable cervical collar has been indicated.

A follow-up by MRI after six months showed a steady state of the cervical involvement. The outcome was favourable and the patient reported a decrease in neck pain.

Discussion

This case represented a diagnostic challenge because the inflammatory pattern of the patient's axial symptoms resembled a spondyloarthritis and his serum inflammatory markers were negative. However, the symmetric involvement of

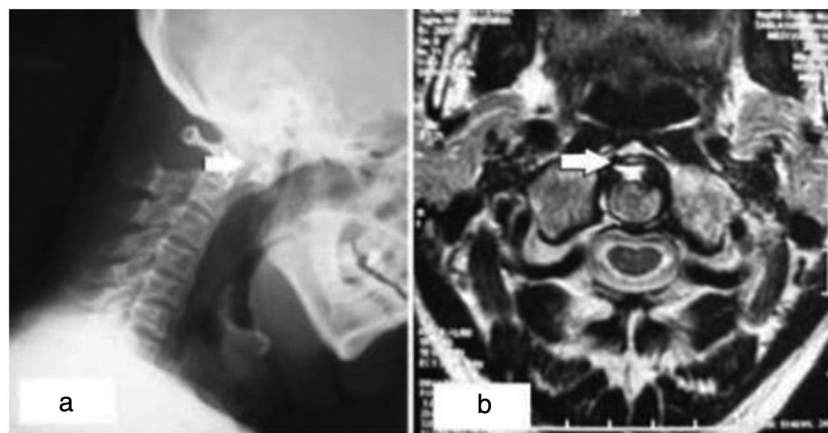


Fig. 1 – (a) Lateral X-ray of the cervical spine in hyperflexion showing a C1–C2 diastasis. (b) Axial section of MRI showing C1–C2 arthritis, the presence of an edematous pannus, atlantoaxial subluxation.

Table 1 – Characteristics of the different cases of cervical spine involvement reported in the literature.

Case/date	Age/gender	Initial symptoms	Peripheral joint involvement	Delay of PJI	Immunological assessment	Treatment	Evolution
Guilpain 2003 ⁸	61/female	Neck pain, paresthesia in extremities	Yes	1 year later	Negative RF	Spinal fusion surgery HCQ/ corticosteroid	Improvement of joint signs and partial recovery of sensory deficit
Jimenez Cabbalero 2010 ⁷	51/female	Numbness in hands Tetra paresis	No	–	Positive RF	Spinal fusion surgery	All neurological signs disappeared
Jimenez Cabbalero 2010 ⁷	47/female	Neck pain, spasticity in extremities	No	–	Positive RF	Spinal fusion surgery	Improvement of the spasticity and the neck pain
Haeusler 2010 ⁹	68/female	Neck limitation and pain	Yes	Simultaneous	Negative RF and anti-CCP	MTX/ corticosteroid	Regression of the cervical symptoms/MRI: regression of the bone marrow oedema
Del Grande 2014 ⁶	80/male	Numbness of his entire hands and bilateral distal weakness, reduced finger pinch and grip	Yes	6 months later	Negative RF, low positive anti-CCP	Spinal fusion surgery MTX	Partial improvement of hand strength/ improvement of the joint signs
Del Grande 2014 ⁶	63/female	Wrist pain and swelling of the left hand	Yes	Simultaneous	Negative RF and anti-CCP	MTX/ corticosteroid	Decrease in joint pain
Araújo 2015 ¹²	35/male	Neck limitation and pain	Yes	2 years later	Positive RF and anti-CCP	MTX/ corticosteroid	Not defined
Bodakçi 2018 ¹⁰	55/male	Neck limitation and pain	No		Negative RF, positive anti-CCP	MTX/HCQ/ corticosteroid	Regression of neck pain/no peripheral joint involvement MRI: regression of pannus tissue
Castano-Quintero 2020 ¹¹	80/male	Paresthesia, hypoesthesia of the fingers and forearms, dysesthesia of the lower extremities	No		Positive RF, negative anti-CCP	Spinal fusion surgery/ prednisolone, sulfasalazine, leflunomide	Clinical improvement
Our patient	64/male	Isolated neck pain	No		Positive RF and anti-CCP	Methylprednisolone, MTX	Regression of neck pain/MRI: steady state of the cervical involvement

PJI: peripheral joint involvement; PIP: proximal interphalangeal joint; MCP: metacarpophalangeal joint; MTP: metatarsophalangeal joint; RF: rheumatoid factor, anti-CCP anti-cyclic citrullinated peptide; MTX: methotrexate; HCQ: hydroxychloroquine; CT: computerized tomography; MRI: magnetic resonance imaging.

peripheral joints as well as the incomplete response to NSAIDs, the positive RF and anti-CCP raised the suspicion of RA. The earliest and most frequent symptom of cervical involvement in RA is neck pain radiating to the occiput.

Although cervical spine involvement is a common feature in RA,^{2,5} it is a very unusual form of presentation of this affection. To our knowledge there are only nine reported cases of cervical involvement as a presenting feature of the disease.⁶⁻¹² See Table 1.

Described cases were six women and four men. Their average age was 57.39 years [35–80]. The main symptom of onset neck pain was reported in six cases. Other symptoms such as tetra paresis, paresthesia, spasticity and numbness of the hands were described. Peripheral joint involvement was present in three cases and immunological assessment was positive in six cases. In all reported cases, MRI was the gold standard for diagnosis. Five patients underwent surgery. Methotrexate, sulfasalazine, hydroxychloroquine,

leflunomide and corticosteroid therapy were prescribed with good response.⁶⁻¹²

The involvement of the upper cervical spine, being more frequent than the involvement of the lower cervical vertebrae is dominated by atlantoaxial subluxation. This subluxation can be anterior, lateral, rotatory or posterior. The literature data estimates its prevalence between 52 and 75%.^{3,13} Among atlantoaxial subluxations, anterior subluxations are the most frequent with a prevalence ranging from 10 to 55%.¹³

The majority of studies link the occurrence of cervical involvement, especially atlantoaxial subluxation, to a long history of RA.^{13,14} Its onset mainly occurs after at least 5–10 years of evolution of RA.¹³ Several factors favouring rheumatoid cervical involvement have been reported in the literature, such as advanced age and duration of disease progression,¹⁵ polyarticular involvement¹³ and deformities.¹³⁻¹⁵

However, some authors have described earlier cervical involvement.^{10,16,17} Paimela¹⁸ has shown that cervical involvement can begin within the first 2 years of the course of RA. Del Grande has described a 20% prevalence of early cervical involvement.⁶ Rare case reports have described cases of cervical involvement revealing or preceding peripheral involvement in RA.^{10,11}

A study published in 2020 investigated the link between the Simple Erosion Narrowing Score (SENS score) and cervical injury. SENS score (hand) was used. A total of 32 joints were scored for erosions and 30 for joint space narrowing. A total of 56 patients with RA were evaluated. A correlation between the SENS score of hands and the prevalence of cervical spine subluxation was confirmed. A higher prevalence of cervical spine subluxation correlated with an increase in the SENS score of hands. The erosion and joint space narrowing scores of the hands also correlated with the prevalence of cervical spine subluxation. These scores may be used as a predictor of cervical spine subluxation in RA patients.¹⁹

The coexistence of extra-articular manifestations^{20,21} as well as the presence of clinical and biological activity elements of the disease²¹ would favour cervical involvement of RA. There is also a relationship between RF and cervical involvement.²² Our patient had no extra-articular manifestations but his RF was strongly positive.

Treatment at an early stage is very important and there is a low incidence of cervical involvement in this case,³ more marked if several DMARDs are combined. A study published in 2000 showed that the combination of several DMARDs (methotrexate, sulfasalazine, nivaquine) reduced the development of rheumatoid cervical damage compared to monotherapy.²³

We described the experience of a male patient presenting a vertebral joint inflammatory compromise as the debut manifestation of RA, which is not common. We also summarized cases reported with cervical involvement as presenting manifestation of RA. This may motivate the development of further research aiming to determine the real frequency of this situation and raise awareness to suspect this condition.

Nevertheless, faced to inflammatory neck pain, investigations must be carried out in order to rule out other etiologies, in particular spondyloarthritis, since C1–C2 involvement could occur during this disease.

Conclusion

The reported case of cervical arthritis, as a presenting feature of RA, corroborates that this is a heterogeneous disease. This suggests that RA may have atypical presentations for which the physician must be aware. Thus, they must investigate any isolated inflammatory cervical spine pain with MRI.

Informed consent

An informed consent was signed by the patient for the publication of his data and images.

Ethical approval

This manuscript was approved by the ethical committee.

Funding

This research did not receive any specific grant from funding agencies in the public, commercial, or not-for-profit sectors.

Conflict of interest

Authors declare having no conflict of interest.

REFERENCES

1. Ngian GS. Rheumatoid arthritis. *Aust Fam Physician*. 2010;39:626–8.
2. Zikou AK, Alamanos Y, Argyropoulou MI, Tsifetaki N, Tsampoulas C, Voulgari PV, et al. Radiological cervical spine involvement in patients with rheumatoid arthritis: a cross-sectional study. *J Rheumatol*. 2005;32:801–6.
3. Nguyen HV, Ludwig SC, Silber J, Gelb DE, Anderson PA, Frank L, et al. Rheumatoid arthritis of the cervical spine. *Spine J*. 2004;4:329–34. <http://dx.doi.org/10.1016/j.spinee.2003.10.006>.
4. DeQuattro K, Imboden JB. Neurologic manifestations of rheumatoid arthritis. *Rheum Dis Clin North Am*. 2017;43:561–71. <http://dx.doi.org/10.1016/j.rdc.2017.06.005>.
5. Yang SY, Boniello AJ, Poorman CE, Chang AL, Wang S, Passias PG. A review of the diagnosis and treatment of atlantoaxial dislocations. *Glob Spine J*. 2014;4:197–210. <http://dx.doi.org/10.1055/s-0034-1376371>.
6. Del Grande M, Del Grande F, Carrino J, Bingham CO, Louie GH. Cervical spine involvement early in the course of rheumatoid arthritis. *Semin Arthritis Rheum*. 2014;43:738–44. <http://dx.doi.org/10.1016/j.semarthrit.2013.12.001>.
7. Jiménez Caballero PE, Ayuga Loro F, Muñoz Escudero F, Lobato Casado P. Mielopatía cervical por pannus reumatoide como forma de la artritis reumatoide. *Med Clin (Barc)*. 2010;135:432–3. <http://dx.doi.org/10.1016/j.medcli.2009.06.054>.
8. Guilpain P, Kettaneh A, Chamouard JM, Stirnemann J, Thomas M, Fain O. Compression of the spinal cord revealing a seronegative rheumatoid arthritis. *Rev Med Interne*. 2003;24:59–62. [http://dx.doi.org/10.1016/s0248-8663\(02\)00007-3](http://dx.doi.org/10.1016/s0248-8663(02)00007-3).
9. Haeusler U, Dybowski F, Wittkaemper TA, Kisters K, Godolias G, Braun J. Atlantoaxiale Arthritis mit entzündlichem

- Nackenschmerz als Erstmanifestation einer seronegativen rheumatoiden Arthritis. *Dtsch Med Wochenschr.* 2010;135:1729-32, <http://dx.doi.org/10.1055/s-0030-1263307> [in German].
10. Bodakçi E, Üsküdar Cansu D, Ertürk A, Çalışır C, Korkmaz C. Can neck pain be an initial symptom of rheumatoid arthritis? A case report and literature review. *Rheumatol Int.* 2018;38:925-31, <http://dx.doi.org/10.1007/s00296-018-4019-z>.
 11. Castaño-Quintero S, Rivillas J-A, Santos VA, Echeverri A. Compressive myelopathy due to pannus in the atlanto-axoid joint as the first manifestation of rheumatoid arthritis. Case report. *Rev Colomb Reumatol (Engl Ed).* 2020;27:112-5, <http://dx.doi.org/10.1016/j.rcree.2019.04.009>.
 12. Araújo F, Silva I, Sepriano A, Reizinho C, Marques L, Nero P, et al. Cervical spine involvement as initial manifestation of rheumatoid arthritis: a case report. *Acta Reumatol Port.* 2015;40:64-7.
 13. Al-daoseri HA, Mohammed Saeed MA, Ahmed RA. Prevalence of cervical spine instability among rheumatoid arthritis patients in South Iraq. *J Clin Orthop Trauma.* 2020;11:876-82, <http://dx.doi.org/10.1016/j.jcot.2019.06.013>.
 14. Neva MH, Häkkinen A, Mäkinen H, Hannonen P, Kauppi M, Sokka T. High prevalence of asymptomatic cervical spine subluxation in patients with rheumatoid arthritis waiting for orthopaedic surgery. *Ann Rheum Dis.* 2006;65:884-8, <http://dx.doi.org/10.1136/ard.2005.042135>.
 15. Wasserman BR, Moskovich R, Razi AE. Rheumatoid arthritis of the cervical spine – clinical considerations. *Bull NYU Hosp Jt Dis.* 2011;69:136-48.
 16. Joaquim AF, Appenzeller S. Cervical spine involvement in rheumatoid arthritis – a systematic review. *Autoimmun Rev.* 2014;13:1195-202, <http://dx.doi.org/10.1016/j.autrev.2014.08.014>.
 17. Dhakad U, Sahoo RR, Bhadu D, Tripathy SR, Srivastava D, Das SK. An early presentation of cervical myelopathy in rheumatoid arthritis. *Indian J Rheumatol.* 2018;13:60-1, <http://dx.doi.org/10.4103/injr.injr.68.17>.
 18. Paimela L, Laasonen L, Kankaanpää E, Leirisalo-Repo M. Progression of cervical spine changes in patients with early rheumatoid arthritis. *J Rheumatol.* 1997;24:1280-4.
 19. Gous E, Ally M, Meyer P, Suleman F. Simple erosion narrowing score of the hands as a predictor of cervical spine subluxation in rheumatoid arthritis. *S Afr J Rad.* 2020;24:1876, <http://dx.doi.org/10.4102/sajr.v24i1.1876.eCollection.2020>.
 20. Bouchaud-Chabot A, Lioté F. Cervical spine involvement in rheumatoid arthritis. A review. *Joint Bone Spine.* 2002;69:141-54, <http://dx.doi.org/10.4102/sajr.v24i1.1876>.
 21. Neva MH, Isomäki P, Hannonen P, Kauppi M, Krishnan E, Sokka T. Early and extensive erosiveness in peripheral joints predicts atlantoaxial subluxations in patients with rheumatoid arthritis. *Arthritis Rheum.* 2003;48:1808-13, <http://dx.doi.org/10.1002/art.11086>.
 22. De Rycke L, Peene I, Hoffman IEA, Kruithof E, Union A, Meheus L, et al. Rheumatoid factor and anticitrullinated protein antibodies in rheumatoid arthritis: diagnostic value, associations with radiological progression rate, and extra-articular manifestations. *Ann Rheum Dis.* 2004;63:1587-93, <http://dx.doi.org/10.1136/ard.2003.017574>.
 23. Kaito T, Ohshima S, Fujiwara H, Makino T, Yonenobu K. Predictors for the progression of cervical lesion in rheumatoid arthritis under the treatment of biological agents. *Spine.* 2013;38:2258-63, <http://dx.doi.org/10.1097/BRS.000000000000066>.