




Asociación
Colombiana de
Reumatología®

Revista Colombiana de
REUMATOLOGÍA

www.elsevier.es/rcreuma



Case report

Common variable immune deficiency complicating proliferative lupus nephropathy: A diagnostic and therapeutic challenge

Lamia Bengherbia, Said Taharboucht*, Oussama Souas, Hassina Chicha, Ahcene Chibane

Department of Internal Medicine, Faculty of Medicine, Saad Dahleb University, Blida, Algeria

ARTICLE INFO

Article history:

Received 26 October 2023

Accepted 21 February 2024

Available online xxx

Keywords:

Systemic lupus

Lupus nephropathy

Common variable

immunodeficiency

Hypogammaglobulinaemia

ABSTRACT

Introduction: Common variable immunodeficiency (CVID) is a rare condition characterized by a constitutional humoral immune deficiency. Its association with systemic lupus is extremely rare.

Case presentation: In this case report, we present a 21-year-old woman with a history of Hashimoto's thyroiditis, who, following the onset of nephrotic syndrome revealing her lupus disease, subsequently developed clinical and laboratory features consistent with CVID, alongside recurrent lupus flares. Her initial therapeutic management was intricate, ultimately resulting in stable remission achieved through monthly immunoglobulin infusions.

Conclusion: This case illustrates the diagnostic and therapeutic difficulty of lupus disease and a common variable immune deficiency.

© 2024 Asociación Colombiana de Reumatología. Published by Elsevier España, S.L.U. All rights reserved.

Inmunodeficiencia común variable que complica la nefropatía lúpica proliferativa: un desafío diagnóstico y terapéutico

RESUMEN

Introducción: La inmunodeficiencia común variable es una enfermedad rara, caracterizada por una deficiencia inmunológica humoral constitucional. Su asociación con el lupus eritematoso sistémico es extremadamente infrecuente.

Presentación del caso: Presentamos el caso de una mujer de 21 años con antecedentes de tiroiditis de Hashimoto, quien después de desarrollar síndrome nefrótico que reveló la presencia de su enfermedad lúpica, manifestó características clínicas y de laboratorio compatibles con inmunodeficiencia común variable, además de recaídas recurrentes de lupus. El manejo terapéutico inicial fue complejo y finalmente resultó en una remisión estable lograda mediante infusiones mensuales de inmunoglobulina.

Palabras clave:

Lupus eritematoso sistémico

Nefritis lúpica

Inmunodeficiencia común variable

Hipogammaglobulinemia

* Corresponding author.

E-mail address: staharboucht@yahoo.fr (S. Taharboucht).

<https://doi.org/10.1016/j.rcreu.2024.02.002>

0121-8123/© 2024 Asociación Colombiana de Reumatología. Published by Elsevier España, S.L.U. All rights reserved.

Conclusión: Este caso ilustra la dificultad en el diagnóstico y manejo de una enfermedad lúpica y una inmunodeficiencia común variable.

© 2024 Asociación Colombiana de Reumatología. Publicado por Elsevier España, S.L.U. Todos los derechos reservados.

Introduction

Systemic lupus erythematosus (SLE) is a systemic autoimmune disease characterized by a breakdown of immune tolerance to self-antigens, particularly nuclear antigens. This leads to the production of autoantibodies and immune complexes which in turn provoke inflammation and damage in various organs.¹ Paradoxically, lupus patients experience immunosuppression, making them more susceptible to infection. This susceptibility is due to several mechanisms, including certain genetic factors, disease-related dysfunction of cellular immune effectors, and the effects of immunosuppressive treatments.¹

Rarely, lupus may be associated with common variable immunodeficiency (CVID),^{1,2} a rare condition associated with a constitutional humoral immune deficiency. Clinically, CVID presents with a diverse range of symptoms and variable hypogammaglobulinemia levels. This exceptional situation can significantly impact the prognosis of lupus patients, presenting both diagnostic challenges and therapeutic challenges.

Case presentation

A 21-year-old woman was admitted to the internal medicine department in January 2021 for investigation of a nephrotic syndrome evolving over several weeks. Her medical history included Hashimoto's thyroiditis for the past 6 years under opotherapy (Levothyrox[®]), and her deceased mother suffered from antiphospholipid syndrome secondary to systemic lupus erythematosus (SLE).

Clinical examination revealed an impure nephrotic syndrome characterized by arterial hypertension associated with a state of anasarca (perigrine edema, edema of the lower limbs, pericardial, pleural and peritoneal effusions), proteinuria at 3 g/24 h and hypoalbuminemia at 27 g/L. The patient also presented with a vesperilio rash, non-scarring alopecia and inflammatory arthralgias. On protein electrophoresis, the gamma globulin level was normal at 15 g/L, as were the other globulin fractions. HEp-2 IFA tests revealed the presence of AC-4/5 pattern (speckled Anti-Cell) at 1/640. The semi-quantitative interpretation showed anti-nucleosome antibodies ++, anti-native DNA ++, anti-Sm +++, anti-nRNP: Sm +++, anti-U1-RNP +++, and anti-SSA+. Immunologic tests show Low C3 AND low C4. A renal biopsy confirmed the diagnosis of class IV and V lupus nephropathy according to the International Society of Nephrology/Renal Pathology Society (ISN/RPS) classification revised in 2018.³ This clinical-biological presentation fulfilled 41 points of the European League Against Rheumatism/American College of

Rheumatology (EULAR/ACR) 2019 classification⁴ and evoked high disease activity with a SLEDAI score of 24 points.

The patient's treatment regimen included three doses of methylprednisolone at 500 mg each, followed by oral prednisone at 1 mg/kg per day. This was supplemented by an intravenous bolus of cyclophosphamide at 500 mg according to the EUROLUPUS protocol,⁵ in addition to hydroxychloroquine at a daily dose of 400 mg and an angiotensin II receptor antagonist.

However, one week after the start of this treatment, the patient developed sepsis complicated by acute anuric renal failure requiring emergency dialysis. The infectious presentation included an abscessing pyogenic multilobar excavated infectious pneumopathy, bilateral pyelitis, and unilateral right endophthalmitis caused by three pathogens (Staphylococcus, cytomegalovirus, and aspergillosis).

In response to this severe infectious complication, the immunosuppressive therapy was promptly discontinued, and there was a rapid reduction in corticosteroid dosage. Antibiotic therapy was initiated, comprising Imipenem/Cilastatin, ciprofloxacin, valganciclovir, and voriconazole. Managing this situation required three months of hospitalization with daily dialysis sessions until renal function was restored. Although the infection was successfully managed, the endophthalmitis resulted in corneal perforation, requiring evisceration and an ocular prosthesis.

The introduction of an immunosuppressive agent to treat the proliferative nephropathy was a challenge due to the appearance of persistent hypogammaglobulinemia during the second month of hospitalization, suggesting a potentially multifactorial immune deficiency related to the initial nephrotic syndrome and the use of immunosuppressive agents. It was finally decided to treat the patient with mycophenolate mofetil 1 g/day, which was discontinued after three weeks due to persistent profound hypogammaglobulinemia of 1.2 g/dl.

After three months of remission, the patient was hospitalized for a flare of cutaneous and renal lupus. She presented with progressive skin lesions of epidermal necrolysis type associated with bacterial superinfection in addition to proteinuria at 5 g/24 h. Local antibiotic treatment was combined with systemic and local corticosteroid therapy, while antiviral therapy (valganciclovir and voriconazole) and hydroxychloroquine were maintained. This episode was concomitant with a mild COVID-19 infection. The clinical-biological evolution was favorable.

At this stage, the diagnosis of variable common immunodeficiency was retained according to the 2015 revised criteria of the European Society for Immune Deficiencies (ESID).⁶ Indeed, elements such as persistent pan-hypogammaglobulinemia after cessation of all immunosuppressive treatments and after

Table 1 – Patient flow cytometry results.

Cells/ μ L	March-21	May-21	August-2021	March-22
NK	59	240	73	72
TCD3+	1456	3415	1238	795
TCD4+	457	720	341	193
TCD8+	948	2560	896	582
BCD19+	178	204	168	20
Memory B cells				6
Naive B cells				7

Table 2 – Diagnostic arguments for CVID in the patient according to the revised ESID 2015 criteria.

- Evocative situation:
 - Increased susceptibility to infection
 - Autoimmune manifestation
- Humoral immunity deficiency controlled on more than 2 times:
 - Marked decrease in IgG (often ≤ 5 g/L)
 - Marked decrease in IgA
 - Decrease in IgM
 - Low vaccine response
 - Decrease in switched memory B cells (LB smB).
- Exclusion of causes of secondary hypogammaglobulinemia.
- Absence of profound T cell deficiency.

CVID: common variable immunodeficiency; ESID: European Society of Immune Deficiencies.

the disappearance of the nephrotic syndrome, an impairment affecting all lineages with a marked decrease in IgA and IgM, poor vaccine response was demonstrated by post-vaccination serology showing the presence of protective IgG tetanus anti-toxin antibodies at low titer, and absence of protective IgG antibody to diphtheria toxoid, and a decrease in switched memory B cells is noted by the reduction of all antibody classes (IgM 0.20 g/L, IgG 0.64 g/L, IgA 0.43 g/L), as well as the collapse of B cell counts (CD19+ B cells 20 cells/ μ L [110–570], memory B cells 7 cells/ μ L [10–31], naive B cells 6 cells/ μ L [92–199]), in the absence of a profound T-cell deficit (CD3+ T cells 795 cells/ μ L [1000–2200], CD8+ T cells 582 cells/ μ L [330–920], CD4+ T cells 193 cells/ μ L [530–1300]) (Table 1), these findings argue for this diagnosis (Table 2).

Treatment with intravenous polyvalent immunoglobulin (IVIG) replacement therapy was initiated. Currently, the patient has been in complete remission for two years, following a regimen that includes hydroxychloroquine at a daily dose of 400 mg, prednisone at 5 mg/day, an angiotensin II receptor antagonist, monthly IVIG infusions, and opotherapy. Fig. 1 shows the temporal changes in proteinuria and gamma globulin levels. Fig. 2 presents the immunoglobulin weight distribution.

Discussion

The association between systemic lupus erythematosus (SLE) and CVID remains extremely rare. Only 15 cases were reported in a recent review.⁷ Common variable immunodeficiency (CVID) is a heterogeneous group of disorders characterized by hypogammaglobulinemia. It presents in two distinct clinical forms: one is mainly limited to

infections, while the other includes a variety of non-infectious, autoimmune, inflammatory, granulomatous and/or lymphoproliferative manifestations. The latter form, which is the most common in internal medicine, often reveals the disease.⁶

In this association, the diagnosis of SLE most often precedes that of CVID, with an average delay of nine years between the two diagnoses.⁷ In our case, CVID manifested early, at the same time as SLE. Nevertheless, establishing the diagnosis of this co-occurrence necessitated six months of rigorous investigation and vigilant immune status monitoring after renal remission and the discontinuation of immunosuppressive treatment.

In documented cases, the onset of CVID was generally marked by recurrent infections, mainly of sinonasal or pulmonary origin. Isolated cases of enteritis, urinary tract infection, meningitis and cellulitis have also been reported.⁷ In our case, the severe clinical presentation of sepsis can be partly attributed to the immunosuppression resulting from the relapse of proliferative lupus nephropathy and the immunosuppressive therapy (high-dose corticosteroids and cyclophosphamide). These two factors have been identified as predictors of infection in several studies.^{8,9} However, it is important to note that a second clinical presentation without signs of infection is possible. In this context, lupus itself is an expression of CVID, and it is the presence of hypogammaglobulinemia that evokes this association, as noted by Geneviève et al.¹⁰ These observations highlight the importance of monitoring immunoglobulin levels in SLE patients. Furthermore, the presence of recurrent infections in such a patient, regardless of SLE activity and/or immunosuppressive treatment, should alert the clinician to the possibility of a potential CVID.

The diagnosis of CVID is currently well codified thanks to the International Diagnostic Criteria (ICON) for CVID, revised in 2016.⁶ In addition to the need to exclude a secondary cause of hypogammaglobulinemia, the evaluation of CVID must include several elements for a complete characterization of the disease. These include a quantitative immunoglobulin test, an assessment of the vaccine response, a detailed analysis of the B and T lymphocyte phenotype, and eventually a search for mutations associated with severe combined immunodeficiency.^{6,11} Although these criteria have high sensitivity and specificity, they remain difficult to perform, especially in developing countries or in centers without immunology laboratories. In our opinion, this situation may underestimate the frequency of CVID in SLE patients.

The association of lupus with CVID presents a significant treatment challenge. In our patient's case, the situation was particularly complex. Despite the severity of the renal impairment, the uncontrollable infectious state led to the discontinuation of immunosuppressive therapy. The subsequent decision to reintroduce it proved difficult given the increased risk of infection. This problem was solved by the maintenance of renal remission after the introduction of intravenous immunoglobulin (IVIG) substitution with low-dose corticosteroids and a synthetic antimalarial.

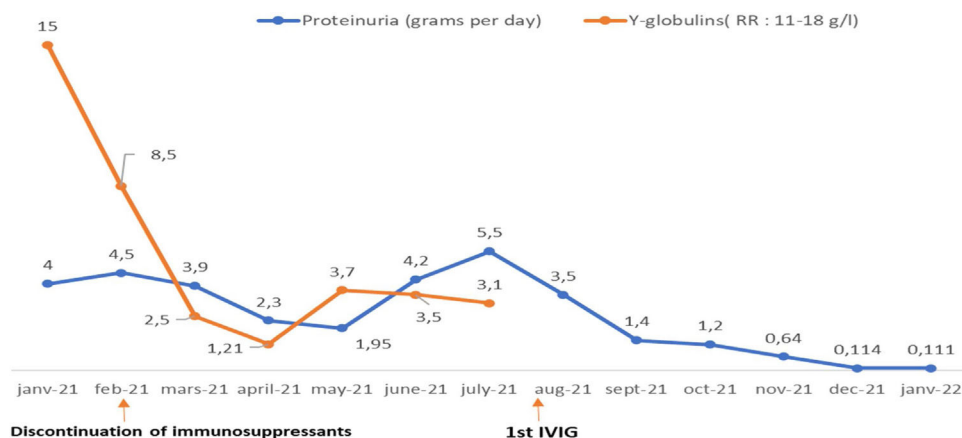


Fig. 1 – Course of proteinuria and gamma globulins in the patient since her first admission to the department. RR: references ranges.

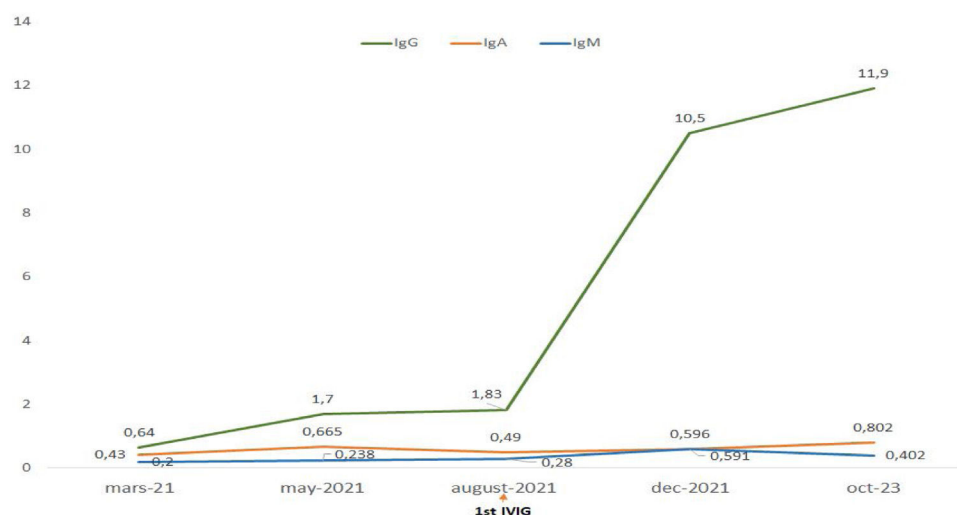


Fig. 2 – Immunoglobulin weight distribution curve. IgG (RR: 6.6–12.8) IgA (RR: 0.7–4.3) IgM (RR: 0.5–2.1).

The favorable evolution of SLE after the development of CVID has been documented and explained by the hypothesis that if a patient with SLE is no longer able to secrete antibodies, it would be conceivable that aspects of the disease generally attributed to the production of pathogenic autoantibodies might improve.^{7,12} However, contrary to expectations, this trend is not systematic. In fact, cases of unfavorable course of lupus have been reported.¹³ This raises important questions about the long-term management of patients with these two comorbidities. Finding the right balance between controlling autoimmunity and preserving the immune response against infection is a complex challenge.

Conclusion

The association between systemic lupus erythematosus (SLE) and common variable immunodeficiency (CVID) is rare and often poorly known. It is important to make physicians aware of the need for clinical surveillance for infectious warning signs and regular monitoring of gamma globulin levels in patients with SLE. This would help to better

identify and manage this association. Further research is needed to better understand the mechanisms underlying this association and to develop more effective therapeutic strategies.

Ethical considerations

The patient signed and approved the informed consent for publication of the clinical case report. The authors state that this article does not contain any personally identifiable information about patients.

Financing

None.

Conflicts of interest

None.

REFERENCES

1. Sawada T, Fujimori D, Yamamoto Y. Systemic lupus erythematosus and immunodeficiency. *Immunol Med.* 2019;42:1–9, <http://dx.doi.org/10.1080/25785826.2019.1628466>.
2. Grammatikos AP, Tsokos GC. Immunodeficiency and autoimmunity: lessons from systemic lupus erythematosus. *Trends Mol Med.* 2012;18:101–8, <http://dx.doi.org/10.1016/j.molmed.2011.10.005>.
3. Bajema IM, Wilhelmus S, Alpers CE, Bruijn JA, Colvin RB, Cook HT, et al. Revision of the International Society of Nephrology/Renal Pathology Society classification for lupus nephritis: clarification of definitions, and modified National Institutes of Health activity and chronicity indices. *Kidney Int.* 2018;93:789–96, <http://dx.doi.org/10.1016/j.kint.2017.11.023>.
4. Aringer M. editor EULAR/ACR classification criteria for SLE. *Seminars in arthritis and rheumatism.* Elsevier; 2019, <http://dx.doi.org/10.1016/j.semarthrit.2019.09.009>.
5. D'cruz D, Houssiau F. The Euro-Lupus Nephritis Trial: the development of the sequential treatment protocol. *Lupus.* 2009;18:875–7, <http://dx.doi.org/10.1177/0961203309106892>.
6. Fieschi C, Viallard J-F. Les déficits immunitaires communs variables (DICV): Partie 1: Évolution des critères diagnostiques et des connaissances génétiques. *Rev Med Int.* 2021;42:465–72, <http://dx.doi.org/10.1016/j.revmed.2021.03.328>.
7. Mucke J, Cornet A, Witte T, Schneider M. Association of common variable immunodeficiency and rare and complex connective tissue and musculoskeletal diseases. A systematic literature review. *Clin Exp Rheumatol.* 2022;40:S40–5, <http://dx.doi.org/10.55563/clinexprheumatol/bbuvih>.
8. Teh CL, Wan SA, Ling GR. Severe infections in systemic lupus erythematosus: disease pattern and predictors of infection-related mortality. *Clin Rheumatol.* 2018;37:2081–6, <http://dx.doi.org/10.1007/s10067-018-4102-6>.
9. Thong KM, Chan TM. Infectious complications in lupus nephritis treatment: a systematic review and meta-analysis. *Lupus.* 2019;28:334–46, <http://dx.doi.org/10.1177/0961203319829817>.
10. Geneviève M, Bonnet F, Michaux C, Geffroy C-E, Vandenhende M-A, Combe C, et al. Néphropathie lupique liée à un déficit immunitaire commun variable d'évolution favorable sous immunoglobulines intraveineuses. *Rev Med Int.* 2012;33:e31–3, <http://dx.doi.org/10.1016/j.revmed.2011.05.002>.
11. Bonilla FA, Barlan I, Chapel H, Costa-Carvalho BT, Cunningham-Rundles C, de la Morena MT, et al. International Consensus Document (ICON): common variable immunodeficiency disorders. *J Allergy Clin Immunol.* 2016;4:38–59, <http://dx.doi.org/10.1016/j.jaip.2015.07.025>.
12. Fernández-Castro M, Mellor-Pita S, Citores MJ, Muñoz P, Tutor-Ureta P, Silva L, et al. Common variable immunodeficiency in systemic lupus erythematosus. *Semin Arthritis Rheum.* 2007;36:238–45, <http://dx.doi.org/10.1016/j.semarthrit.2006.09.005>.
13. Tsokos GC, Smith PL, Balow JE. Development of hypogammaglobulinemia in a patient with systemic lupus erythematosus. *Am J Med.* 1986;81:1081–4, [http://dx.doi.org/10.1016/0002-9343\(86\)90413-4](http://dx.doi.org/10.1016/0002-9343(86)90413-4).