

Infectio

Asociación Colombiana de Infectología

www.elsevier.es/infectio



REVISIÓN

Fusarium Infections

Carol A. Kauffman

Division of Infectious Diseases, Department of Internal Medicine, University of Michigan Medical School, Veterans Affairs Ann Arbor Healthcare System, Ann Arbor, Michigan, Estados Unidos

KEYWORDS

Fusariosis;
Fusarium species;
Keratitis;
Voriconazole;
Amphotericin B

Abstract

Fusarium species are primarily plant pathogens that occasionally cause human disease. Several members of this genus of molds have caused widespread destruction of food crops. *Fusarium* species are found primarily in soil and on decaying vegetable matter, but also occur in water. Localized infections, such as keratitis, sinusitis, and skin and nail infections, occur in immunocompetent persons. However, invasive sinusitis and pulmonary infection, as well as widespread dissemination, are the rule in markedly immunosuppressed patients, especially those who are profoundly neutropenic. The acute onset of painful skin lesions and the growth of a mold in blood cultures are clues to disseminated fusariosis in immunosuppressed patients. The organism grows readily in the laboratory, but identification to the species level is difficult. Biopsy of infected tissues shows acutely branching septate hyphae that are often indistinguishable from those of *Aspergillus* species. Localized lesions respond reasonably well to antifungal agents and surgical excision. Invasive pulmonary and disseminated infection respond poorly to antifungal therapy, in part because of the resistance of most species to many antifungal agents, but more importantly, to the absence of an effective host response. Most patients who have disseminated or invasive pulmonary infection are treated with a combination of voriconazole and a lipid formulation of amphotericin B, with the hope that at least one drug may have activity against the organism, and perhaps better killing can be achieved using two drugs. Unfortunately, patients who have disseminated fusariosis and who remain neutropenic rarely survive the infection, regardless of the therapy used.

© 2012 ACIN. Published by Elsevier España, S.L. All rights reserved.

*Corresponding author:

VA Ann Arbor Healthcare System
2215 Fuller Road, Ann Arbor, MI 48105
Phone: 734-845-3460, fax: 734-845-3290
E-mail: ckauff@umich.edu (C. A. Kauffman).

PALABRAS CLAVE

Fusariosis;
Especies *Fusarium*;
Queratitis;
Voriconazol;
Anfotericina B

Infecciones por *Fusarium***Resumen**

Las distintas especies de *Fusarium* son principalmente patógenos de plantas que ocasionalmente pueden originar enfermedades en humanos. Varios miembros de este género de hongos han causado una gran destrucción de cultivos alimentarios. Suelen haber especies de *Fusarium* en el suelo y en la materia vegetal en descomposición, pero también se pueden hallar en el agua. Algunas infecciones localizadas, como queratitis, sinusitis e infecciones en piel y uñas pueden afectar a personas inmunocompetentes. Sin embargo, las sinusitis invasoras y las infecciones pulmonares, de rápida diseminación, son habituales en pacientes muy inmunodeprimidos, especialmente en aquellos que son profundamente neutropénicos. El inicio agudo de lesiones dolorosas en la piel y el crecimiento de moho en cultivos sanguíneos son indicadores de una fusariosis diseminada en pacientes inmunodeprimidos. El organismo crece fácilmente en laboratorio, pero la identificación de la especie es complicada. Las biopsias de tejidos infectados muestran hifas septadas extremadamente ramificadas que a menudo son indistinguibles de las que presentan las especies de *Aspergillus*. Las lesiones localizadas responden razonablemente bien a agentes antifúngicos y a la cirugía. Las infecciones pulmonares invasoras y extendidas responden de manera deficitaria a la terapia antifúngica, en parte debido a la resistencia que presentan la mayoría de especies a muchos agentes antifúngicos, pero principalmente por la ausencia de una respuesta efectiva del huésped. La mayoría de los pacientes que tienen infección pulmonar invasora o diseminada son tratados con una combinación de voriconazol y una formulación lipídica de anfotericina B, con la esperanza de que al menos un fármaco actúe contra el patógeno y se alcancen mejores resultados con el uso de dos fármacos. Desgraciadamente, los pacientes que padecen una fusariosis diseminada y aquellos que permanecen neutropénicos, rara vez sobreviven a la infección, independientemente de la terapia utilizada.

© 2012 ACIN. Publicado por Elsevier España, S.L. Todos los derechos reservados.

Introduction

Fusarium species are known primarily for their role as important plant pathogens that have caused devastating destruction of many fruits and vegetables. Human fusariosis varies in its manifestations from localized infections, such as keratitis, to intoxications that can occur with ingestion of contaminated foods, to devastating disseminated infections that are seen primarily in markedly immunosuppressed patients. The organism exists world wide, with different species occupying different ecological niches. A hallmark of *Fusarium* species is their marked resistance to currently available antifungal agents. We will review the epidemiology, clinical manifestations, and treatment options for fusariosis.

Organism

The genus *Fusarium* includes over a 100 species, very few of which are human pathogens. The most common species that infect humans are *F. solani*, *F. oxysporum*, *F. moniliforme* (*F. verticillioides*), and *F. proliferatum*. *F. solani* causes approximately 50% of human cases of fusariosis. *Fusarium* species are predominantly plant pathogens. Several of the species of *Fusarium* have destroyed certain varieties of food producing plants, such as bananas. They grow well in the soil and are found abundantly on decaying organic material.

These molds are also present in water and cause infections of the gills, skin, and shells, of sharks, seals, and marine turtles, respectively.

Fusarium species have small microconidia and large fusiform or banana-shaped macroconidia, explaining the genus name¹. The macroconidia are distinctive and allow clinical laboratories to define the genus as *Fusarium*, but further identification to the species level is difficult and is often not routinely performed. Species identification is important for surveillance studies and for defining species-dependent antifungal susceptibility patterns. Although antifungal susceptibility testing gives broad guidance to the choice of drugs, it is not standardized for this genus². For patients with disseminated infection, correlation of *in vitro* susceptibility results with clinical outcomes is poor, most likely reflecting the poor immune status of patients with disseminated fusariosis.

Epidemiology

Fusarium species occur world wide but, at least for disseminated infection, most cases are reported from large cancer centers in warmer climates in the U.S. and Europe. In the last several decades, increasing reports of disseminated fusariosis have emerged among highly immunosuppressed patients, among whom the highest rates are in those who have a hematological malignancy.

nancy and are neutropenic or have received an allogeneic hematopoietic cell transplant³⁻⁷. Reports from the U.S. have noted the highest concentrations of *Fusarium* species in the outside air during hotter, more humid months². Although most cases of disseminated fusariosis are acquired from the outside environment, nosocomial acquisition of this organism related to construction has been documented⁸. Plants also have been implicated as a source for hospital-acquired infection, and for this reason, live plants are restricted on units in which immunosuppressed patients are cared for. Additionally, there have been reports of hospital water sources, especially showers, yielding *Fusarium* species on culture⁹. Although firm proof that showers have been the source of the organism in specific patients is lacking, many transplant units do not allow patients to take showers.

Localized disease is most often related to direct inoculation. This occurs in outdoor workers who experience inoculation of soil containing the organism into skin and subcutaneous tissues. Fusarial onychomycoses are presumably also initiated by local inoculation of organisms from either water or soil. One of the most devastating localized infections results from corneal inoculation by contaminated contact lenses, resulting in severe keratitis.

An outbreak of *Fusarium* keratitis among soft contact lens wearers in the U.S., Singapore, and Hong Kong from 2004 to 2006 was traced back to a specific contact lens solution (ReNu with MoistureLoc) that was subsequently removed from the market¹⁰. The contact lens solution was not intrinsically contaminated, but had lost its usual antimicrobial properties and allowed the growth of several different species of *Fusarium* in the contact lens cases¹¹. The organisms were introduced by the users themselves, presumably from their hands, and then persisted, most likely in a biofilm in the case and on the contact lens. Introduction of the contaminated lens onto the eye led to destructive keratitis, anterior chamber infection, extension into the vitreous in many cases, and loss of vision.

Pathogenesis

Fusarium species are angioinvasive, a property shared with *Aspergillus* species and the Mucorales. With invasion through blood vessels, hemorrhagic infarction and necrosis occur. When the conidia are inhaled from the environment, the lungs and the sinuses are primarily affected. This occurs almost entirely in markedly immunosuppressed patients who usually are neutropenic. The depth and length of the neutropenia are important predictors for the development of disseminated infection^{5,6}. Neutrophils are essential for inhibiting hyphal growth, and macrophages can both phagocytize conidia and also attack hyphae. The use of corticosteroids is also a risk factor for development of disseminated infection.

Toxin-induced disease is now rare, but outbreaks have been described in the past in which persons ingesting grain contaminated with toxin-producing *Fusarium* species developed bone marrow suppression and death, so-called alimentary toxic aleukia. There is no evidence that the mycotoxins produced by *Fusarium* species contaminating grains play any role in invasive fusariosis.

Clinical manifestations

Localized Infections

Skin and Skin Structure Infections

Localized infection can follow after local inoculation of *Fusarium* species into skin or subcutaneous tissues¹². In the tropics, eumycetoma has been reported due to *F. solani* or *F. moniliforme*, but overall, *Fusarium* species are not among the most common causes of eumycetoma. In immunocompetent persons who have experienced trauma or who have burn wounds, cellulitis, ulcerative lesions, and abscesses due to fusariosis can occur. Solid organ transplant recipients tend to develop localized nodular or ulcerative lesions of the extremities, likely related to trauma, and not accompanied by dissemination⁴. There are no specific features in these skin and soft tissue infections that are distinctive for fusariosis.

Although *Fusarium* species are a less common cause of onychomycosis than dermatophytes, they are an increasingly important cause of infection in immunosuppressed patients, especially those who are neutropenic^{13,14}. In this population, onychomycosis may be the prelude to a painful paronychia infection and resultant cellulitis. Disseminated fusariosis has been reported secondary to *Fusarium* paronychia in neutropenic patients¹².

Keratitis

Corneal infection following trauma with introduction of plant material or soil or contamination of contact lenses, presents with pain, photophobia, tearing, and decreased visual acuity. The cornea becomes cloudy and may perforate. The infection often spreads into the anterior chamber, and a hypopyon may be seen. In some cases, extension through the globe into the posterior chamber occurs, resulting in vitritis and retinal damage. Early diagnosis allowing aggressive treatment is imperative to retain vision.

Sinusitis

Fusarium species can cause chronic invasive sinusitis. This uncommon infection occurs in patients who are not immunosuppressed but often are older and have underlying illnesses, such as diabetes¹⁵. This form of sinusitis slowly progresses over weeks to months, causing increasing pain and discharge from the nares, but it is not life threatening. Fungus ball formation, which almost always occurs in the maxillary sinus, is uncommonly due to *Fusarium*¹⁵.

In patients who are immunosuppressed, sinusitis due to *Fusarium* species is an aggressive infection with invasion into bone and adjacent structures of the face. Clinically, the patients present with the acute onset of fever, face pain, and discharge from the nares; necrosis of the palate or nasal turbinates is common because of the angioinvasive nature of the mold. It is indistinguishable from infection with the Mucorales, such as *Rhizopus* and *Mucor* species, and *Aspergillus* species. Dissemination can occur secondary to an initial focus in the sinuses.

Other localized infections

Other manifestations of fusariosis include infections associated with chronic peritoneal dialysis catheters, osteomyelitis, septic arthritis, and a variety of different visceral abscesses².

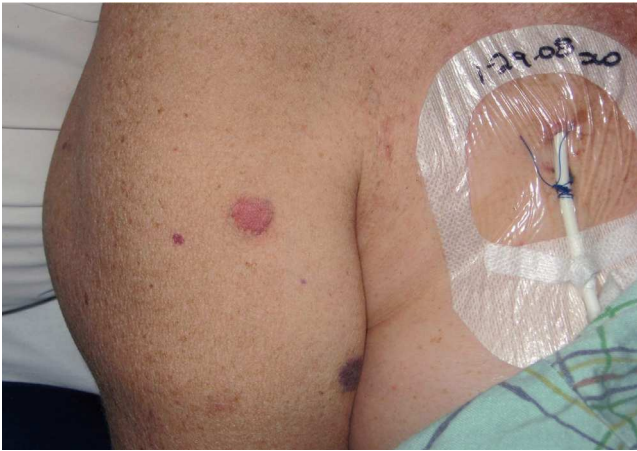

Figure 1 Skin lesions that developed acutely in a profoundly neutropenic woman who had received an allogeneic stem cell transplant 53 days before. The upper lesion was nodular and the lower one purpuric; both were painful.

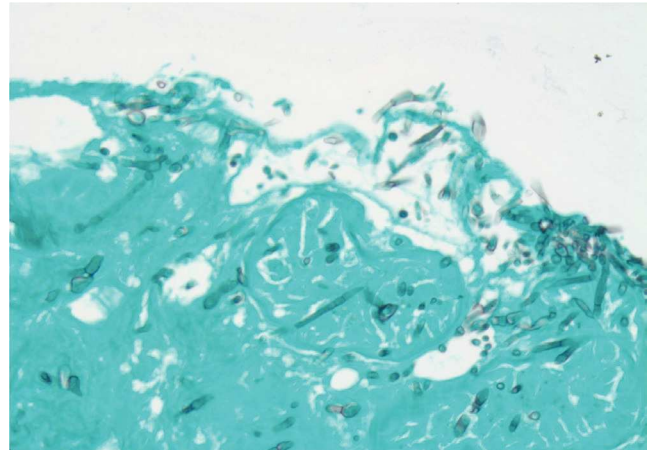


Figure 2 Methenamine silver stain of the biopsy of one of the skin lesions from the patient shown in Figure 1. Acutely branching septate hyphae are scattered throughout the tissue.

Pulmonary Infection

The lungs are frequently the primary site of infection with *Fusarium* species, which is not surprising given that inhalation of aerosolized conidia from the environment is a prime means of spread of these molds. Pneumonia is unusual in immunocompetent hosts, but must always be thought of in immunosuppressed hosts, especially those who have a hematological malignancy and who are neutropenic^{3,5}. Symptoms and signs are similar to those seen with aspergillosis, which is more common. Symptoms include fever, cough, malaise, and dyspnea; pleuritic chest pain and hemoptysis appear as the infection progresses.

Any symptoms suggesting pulmonary infection in an immunosuppressed host should trigger an immediate chest radiograph and computed tomography scan of the thorax. Classic findings on computed tomography scan include those seen with other angioinvasive molds and most commonly include multiple nodules of varying sizes, some of which may be surrounded by ground glass opacification signifying hemorrhage (so-called halo sign), and some of which may show cavitation^{3,16}. Disease may remain localized to the lungs, but more commonly, the pulmonary findings are just one manifestation of disseminated fusariosis.

Disseminated Infection

Dissemination is the rule when *Fusarium* infection occurs in those who are immunosuppressed and especially in those who are neutropenic^{3,5}. Suspicion for disseminated infection is raised when a patient who is febrile and appears severely ill develops painful skin lesions (Fig. 1). The lesions have been characterized by Nucci and Anaissie in their literature review of 232 immunocompromised patients who had fusariosis, 72% of whom developed cutaneous manifestations¹². The lesions vary from papules to nodules, with or without central necrosis. They can appear as target lesions or classic ecthyma gangrenosum. Uncommonly, bullae and vesicles appear. The lesions are

usually on the extremities, almost always multiple, and can become purpuric or hemorrhagic as they evolve. The crucial clue for the clinician is that these lesions are painful, in contrast to the non-painful lesions of candidiasis and aspergillosis.

Diagnosis

The diagnosis of fusariosis is established by growing the organism from a sterile body site. Frequently, a non-sterile site, such as respiratory secretions or skin, is the source for culture, and for these patients, there must be a compatible clinical picture and/or radiological evidence typical for an invasive fungal infection. *Fusarium* is one of the few genera of molds that are able to sporulate *in vivo*. Because of this, they are capable of growing in blood culture bottles, and this may be the first hint that a patient has disseminated fusariosis⁶. This is a valuable clue for clinicians who usually think that a patient who has an invasive fungal pneumonia has aspergillosis. Aspergillosis is clearly much more common than fusariosis, but *Aspergillus* species only very rarely can be isolated from blood culture bottles. Growing *Fusarium* from respiratory secretions, including BAL fluid, in a patient who is immunosuppressed and has computed tomography findings suggestive of invasive mold infection is adequate to make a diagnosis of probable fusariosis and begin treatment immediately.

Histopathological examination of biopsy material from skin lesions or pulmonary infiltrates shows acutely branching septate hyphae that are indistinguishable from those of *Aspergillus* and *Scedosporium* species (Fig. 2). Cytological preparations from BAL fluid and scrapings from keratitis lesions show similar septate hyphae. Histopathology defines the extent of tissue invasion, but culture is needed to differentiate the specific hyaline mold that is causing disease.

There are no antibody or antigen detection tests available to aid in diagnosis. PCR has been used in some cases using universal primers or genus-specific probes for *Fusarium* in BAL fluid, skin biopsy specimens, and ocular

samples⁶. *In situ* hybridization has been reported to be useful to differentiate *Fusarium* from other hyaline molds in a small number of patients¹⁷.

Treatment

Localized Infections

Treatment of localized *Fusarium* infections of the skin and subcutaneous tissues is usually successful. If the infection progresses to become a mycetoma, treatment is more difficult, and surgery along with antifungal therapy is often required. *Fusarium* onychomycosis should be treated with systemic azole therapy. In immunosuppressed patients, especially those who have hematological malignancies and are neutropenic, onychomycosis should be treated as soon as possible by removing the nail and giving systemic antifungal therapy, usually voriconazole (VOR).

The most difficult local infection to treat is keratitis; although the organism is eradicated, visual acuity often remains poor. The standard treatment for fungal keratitis has been topical natamycin, but this has not been effective in many cases of *Fusarium* infection. With extension into the chambers of the eye, systemic antifungal agents should be used, and most cases require a keratoplasty to remove the infected lens. Increasingly, VOR is used for fusariosis as well as other ocular fungal infections¹⁸. Topical VOR as well as oral VOR, at the doses noted below, are used. With extension into the vitreous body, intravitreal VOR is given in addition to systemic therapy.

Pulmonary and Disseminated Infections

Invasive *Fusarium* infections are exceedingly difficult to treat because most species are resistant to many antifungal agents². The most common species that infects humans, *F. solani*, is the most resistant. The most active drugs appear to be amphotericin B (AMB), VOR, and posaconazole (POS), but the minimum inhibitory concentration required to inhibit growth is higher than that noted for other molds, such as *Aspergillus fumigatus*. Fluconazole and itraconazole are not active against most *Fusarium* species, and echinocandins have no activity against *Fusarium* species. *In vitro*, terbinafine has activity against some species and based on these data, has been used as an adjunct along with other agents, but it never should be used as monotherapy. *In vitro* susceptibility studies do not correlate well with outcomes of treatment, and the range of minimum inhibitory concentration values varies for different species and among different laboratories².

In general, a lipid formulation of AMB, VOR, or POS is used for most patients who have disseminated infection or serious localized infection^{5,6,19-25}. Many clinicians use dual therapy with a lipid formulation of AMB and VOR for patients who have disseminated infection^{22,24,25}.

Amphotericin B is almost always given as a lipid formulation (liposomal AMB or AMB lipid complex) so as to decrease the risk of nephrotoxicity and also to allow an increase in the daily dose. The dosages recommended are 3-5 mg/kg daily, but in ill patients, doses as high as 10 mg/kg daily have been used. One study noted a partial or

complete response in 12 of 26 (46%) patients who received high dose AMB lipid complex²³.

A retrospective review of 73 cases of invasive fusariosis treated with VOR found an overall partial or complete response in 34 (47%), most of whom had disseminated infection, and most of whom had received prior antifungal therapy²¹. The best response rate was seen in patients who were least immunosuppressed, which is not surprising; all patients who remained neutropenic throughout the course of therapy died.

Salvage therapy with POS has been shown effective for some patients. In one series, 10 of 21 (48%) patients achieved a complete or partial response with POS therapy after they had failed or developed intolerance to prior therapy. However, only 20% of leukemic patients with persistent neutropenia responded compared with 67% of leukemic patients whose neutropenia resolved²⁰.

Case reports describing the efficacy of combination antifungal therapy are increasingly published. A review of case reports of patients treated with different combinations of antifungal drugs noted a 70% response to combination therapy²⁴. However, in most of these reports, neutropenia was not taken into account, and it is likely that resolution of neutropenia was the primary determinant of outcome. The largest series reported retrospectively on 37 patients who received combination antifungal therapy. For 27 of these patients, therapy consisted of a lipid formulation of AMB and a triazole. After 90 days of dual therapy, 41% were noted to have achieved a complete or partial response²⁵, which is similar to the response noted with monotherapy in prior studies^{20,21}. Thus, it is not clear that combination therapy is any more effective than monotherapy. However, if one is unsure of the susceptibilities of the infecting organism, which is the usual scenario, it seems reasonable to treat with a combination of drugs in the hopes of having at least one active drug in the treatment regimen.

We generally initiate therapy with intravenous VOR, at a dosage of 6 mg/kg twice on the first day, and then 4 mg/kg twice daily thereafter, combined with intravenous liposomal AMB, at a dosage of 5 mg/kg daily, which can be increased to 10 mg/kg daily, if needed. After the patient improves, we step down to oral VOR, 200-300 mg twice daily on an empty stomach. Voriconazole levels should be obtained to ensure appropriate serum concentrations are attained. Posaconazole can also be used as step-down therapy (but not initial therapy) at a dosage of 400 mg twice daily with food, and levels also should be obtained to ensure adequate absorption, which is often problematic with this drug.

Adjunctive therapy with granulocyte colony stimulating factor has been used in some centers in an attempt to improve the outcome of patients who remain neutropenic^{2,25}. Others have infused granulocytes that were obtained from donors who had received granulocyte colony stimulating factor to stimulate higher numbers of more active granulocytes².

Outcomes

Rather than the specific antifungal agent used, the most important factor predicting the outcome of invasive fusariosis is the recovery of the patient's immune function, especially recovery from neutropenia. In several multicenter

and single center reports of patients who had hematological malignancies or who were hematopoietic cell transplant recipients, persistent neutropenia and corticosteroid therapy predicted poor outcomes^{3,5,6,19}. Mortality among this type of patient with disseminated fusariosis has been reported to be 81% to 87%². It is almost always the case that if neutropenia fails to resolve, a patient with disseminated fusariosis will die of this infection.

Patients who are less immunosuppressed and not neutropenic, such as solid organ transplant recipients, have a better outcome than hematopoietic cell transplant recipients. Solid organ transplant recipients tend to have localized skin and subcutaneous *Fusarium* infections rather than disseminated infection, and they generally recover from their infection⁴. Immunocompetent patients who have localized inoculation disease have a good prognosis. The worst prognosis for localized infection is noted with keratitis due to *Fusarium* species; even with a corneal transplant, visual acuity may remain poor.

Conflicts of interest

The author declared no conflicts of interest

References

- Nelson PE, Dignani MC, Anaissie EJ. Taxonomy, biology, and clinical aspects of *Fusarium* species. *Clin Microbiol Rev*. 1994;7:479-504.
- Torres HA, Kontoyiannis DP. Hyalohyphomycoses (Hyaline Molds). En: Kauffman CA, Pappas PG, Sobel JD, Dismukes WE, eds. *Essentials of Clinical Mycology*. 2.^a ed. Springer, NY: 2011. p. 281-304.
- Boutati EI, Anaissie EJ. *Fusarium*, a significant emerging pathogen in patients with hematologic malignancy: ten years' experience at a cancer center and implications for management. *Blood*. 1997;90:999-1008.
- Sampathkumar P, Paya CV. *Fusarium* infection after solid-organ transplantation. *Clin Infect Dis*. 2001;32:1237-40.
- Nucci M, Marr KA, Queiroz-Telles F, Martins CA, Trabasso P, Costa S, et al. *Fusarium* infection in hematopoietic stem cell transplant recipients. *Clin Infect Dis*. 2004;38:1237-42.
- Nucci M, Anaissie E. *Fusarium* infections in immunocompromised patients. *Clin Microbiol Rev*. 2007;20:697-704.
- Carneiro HA, Coleman JJ, Restrepo A, Mylonakis E. *Fusarium* infection in lung transplant patients: report of 6 cases and review of the literature. *Medicine (Baltimore)*. 2011;90:69-80.
- Raad I, Tarrand J, Hanna H, Albitar M, Janssen E, Boktour M, et al. Epidemiology, molecular mycology, and environmental sources of *Fusarium* infection in patients with cancer. *Infect Control Hosp Epidemiol*. 2002;23:532-7.
- Anaissie EJ, Kuchar RT, Rex JH, Francesconi A, Kasai M, Müller FM, et al. Fusariosis associated with pathogenic *Fusarium* species colonization of a hospital water system: a new paradigm for the epidemiology of opportunistic mold infections. *Clin Infect Dis*. 2001;33:1871-8.
- Chang DC, Grant GB, O'Donnell K, Wannemuehler KA, Noble-Wang J, Rao CY, et al; *Fusarium* Keratitis Investigation Team. Multistate outbreak of *Fusarium* keratitis associated with use of a contact lens solution. *JAMA*. 2006;296:953-63.
- Bullock JD, Elder BL, Khamis HJ, Warwar RE. Effects of time, temperature, and storage container on the growth of *Fusarium* species: implications for the worldwide *Fusarium* keratitis epidemic of 2004-2006. *Arch Ophthalmol*. 2011;129:133-6.
- Nucci M, Anaissie E. Cutaneous infection by *Fusarium* species in healthy and immunocompromised hosts: implications for diagnosis and management. *Clin Infect Dis*. 2002;35:909-20.
- Guilhermetti E, Takahachi G, Shinobu CS, Svidzinski TI. *Fusarium* spp. as agents of onychomycosis in immunocompetent hosts. *Int J Dermatol*. 2007;46:822-6.
- Godoy P, Nunes E, Silva V, Tomimori-Yamashita J, Zaror L, Fischman O. Onychomycosis caused by *Fusarium solani* and *Fusarium oxysporum* in São Paulo, Brazil. *Mycopathologia*. 2004;157:287-90.
- Kauffman CA. Fungal sinusitis. En: Brook I, ed. *Sinusitis*. Nueva York: Marcel Dekker, Inc; 2006. p. 419-30.
- Marom EM, Holmes AM, Bruzzi JF, Truong MT, O'Sullivan PJ, Kontoyiannis DP. Imaging of pulmonary fusariosis in patients with hematologic malignancies. *AJR Am J Roentgenol*. 2008;190:1605-9.
- Hayden RT, Isotalo PA, Parrett T, Wolk DM, Qian X, Roberts GD, et al. *In situ* hybridization for the differentiation of *Aspergillus*, *Fusarium*, and *Pseudallescheria* species in tissue section. *Diagn Mol Pathol*. 2003;12:21-6.
- Hariprasad SM, Mieler WF, Lin TK, Sponsel WE, Graybill JR. Voriconazole in the treatment of fungal eye infections: a review of current literature. *Br J Ophthalmol*. 2008;92:871-8.
- Nucci M, Anaissie EJ, Queiroz-Telles F, Martins CA, Trabasso P, Solza C, et al. Outcome predictors of 84 patients with hematologic malignancies and *Fusarium* infection. *Cancer*. 2003;98:315-9.
- Raad II, Hachem RY, Herbrecht R, Graybill JR, Hare R, Corcoran G, et al. Posaconazole as salvage treatment for invasive fusariosis in patients with underlying hematologic malignancy and other conditions. *Clin Infect Dis*. 2006;42:1398-403.
- Lortholary O, Obenga G, Biswas P, Caillot D, Chachaty E, Bienvenu AL, et al; French Mycoses Study Group. International retrospective analysis of 73 cases of invasive fusariosis treated with voriconazole. *Antimicrob Agents Chemother*. 2010;54:4446-50.
- Ho DY, Lee JD, Rosso F, Montoya JG. Treating disseminated fusariosis: amphotericin B, voriconazole or both? *Mycoses*. 2007;50:227-31.
- Perfect JR. Treatment of non-*Aspergillus* moulds in immunocompromised patients with amphotericin B lipid complex. *Clin Infect Dis*. 2005;40 Suppl 6:S401-8.
- Liu JY, Chen WT, Ko BS, Yao M, Hsueh PR, Hsiao CH, et al. Combination antifungal therapy for disseminated fusariosis in immunocompromised patients: a case report and literature review. *Med Mycol*. 2011;49:872-8.
- Campo M, Lewis RE, Kontoyiannis DP. Invasive fusariosis in patients with hematologic malignancies at a cancer center: 1998-2009. *J Infect*. 2010;60:331-7.