




REVISTA MÉDICA DEL  
**HOSPITAL GENERAL**  
DE MÉXICO

[www.elsevier.es/hgmx](http://www.elsevier.es/hgmx)



CLINICAL CASE

## Iliac artery reconstruction secondary to incidental injury in open hernia repair: A case report and literature review



R. Doña-Jaimes<sup>a,\*</sup>, J.A. García-Espinoza<sup>a</sup>, N.E. Basurto Acevedo<sup>b</sup>,  
N.A. Lechuga-García<sup>a</sup>, M.J. López Juárez<sup>a</sup>, R. Aragón-Soto<sup>b</sup>

<sup>a</sup> Department of General and Minimally Invasive Surgery, Hospital Regional de Alta Especialidad de Oaxaca, Oaxaca, Mexico

<sup>b</sup> Hospital General de México, Mexico City, Mexico

Received 17 June 2016; accepted 8 August 2016

Available online 7 September 2016

### KEYWORDS

Hernia;  
Inguinal;  
Iliac artery;  
Injury;  
Grafts

### Abstract

**Introduction:** Inguinal hernia repair is one of the most common surgeries performed worldwide by general surgeons. More than 750,000 inguinal hernia repairs are performed each year in the United States. Complications of inguinal or femoral hernia are relatively rare, depending on the clinical circumstances in which the patient is admitted to the operating room and the type of hernia. The complications are classified as: intraoperative, short term and long term. Arterial lesions are the rarest but most dangerous.

**Objective:** To describe surgical techniques used to repair injuries to the external iliac artery during an inguinal hernia repair that is reproducible by general surgeons.

**Materials and methods:** A case report of an intraoperative external iliac artery injury is presented in which a polytetrafluoroethylene (PTFE) graft was used over the length of the lesion. Different techniques may be used for revascularisation: autogenous vein graft, synthetic grafts, revascularisation with ipsilateral or contralateral internal iliac artery and femoro-femoral crossover graft.

**Conclusion:** The surgical technique using PTFE grafts is effective for repairing arterial injuries and it results in timely revascularisation that promotes satisfactory progress.

© 2016 Sociedad Médica del Hospital General de México. Published by Masson Doyma México S.A. This is an open access article under the CC BY-NC-ND license (<http://creativecommons.org/licenses/by-nc-nd/4.0/>).

\* Corresponding author at: Aldama sin número, colonia Paraje el Tule, San Bartolo Coyotepec, C.P. 71256, Oaxaca, Mexico.  
E-mail address: [dr.ronald.dj@gmail.com](mailto:dr.ronald.dj@gmail.com) (R. Doña-Jaimes).

**PALABRAS CLAVE**

Hernia;  
 Inguinal;  
 Arteria iliaca;  
 Lesión;  
 Injertos

## Reconstrucción de arteria iliaca secundaria a lesión incidental en hernioplastia abierta: presentación de un caso y revisión de literatura

**Resumen**

**Introducción:** La plastia inguinal es una de las cirugías más frecuente realizadas a nivel mundial por cirujanos generales. En Estados Unidos más de 750,000 hernioplastias inguinales se realizan por año. Las complicaciones de una hernia inguinal o femoral son relativamente infrecuentes, depende de las circunstancias clínicas en las que se ingresa a quirófano y el tipo de la hernia. Las complicaciones se clasifican en: intraoperatoria, a corto plazo y a largo plazo. Las lesiones arteriales son las más raras pero más graves.

**Objetivo:** Describir técnicas quirúrgicas para reparación de lesiones de la arteria iliaca durante una plastia inguinal y reproducible por cirujanos generales.

**Material y método:** Se presenta un caso clínico con lesión de arteria iliaca externa intraoperatoria la cual se realiza injerto de politetrafluoroetileno (PTFE) por la longitud de la lesión. Se puede utilizar diferentes técnicas para la revascularización: injerto de vena autóloga, injertos sintéticos, revascularización con arteria hipogástrica ipsi o contralateral e injerto cruzado femoro-femoral.

**Conclusión:** La técnica quirúrgica utilizando injerto de PTFE es eficaz para la reparación de lesión arterial y tener una revascularización oportuna que favorece una satisfactoria evolución. © 2016 Sociedad Médica del Hospital General de México. Publicado por Masson Doyma México S.A. Este es un artículo Open Access bajo la licencia CC BY-NC-ND (<http://creativecommons.org/licenses/by-nc-nd/4.0/>).

**Background**

Inguinal hernia repair is one of the most common surgeries performed worldwide by general surgeons. More than 750,000 inguinal hernia repairs are performed each year in the United States.<sup>1</sup> Hernias are more common in men than in women, and in Caucasians than in blacks. There are many techniques for repairing the hernia which can be categorised as tension-free repair (using a mesh) and tension repair where the primary tissues are pulled tight and no mesh is used.<sup>2</sup> Lichtenstein tension-free repair using polypropylene mesh is the gold standard for inguinal hernia repair.<sup>3</sup> The procedure is easy for surgeons to learn, and can even be performed under local anaesthesia which is attributed to reducing hernia recurrence to <5%.<sup>4</sup>

Hernias are classified based on anatomical location: inguinal (direct or indirect), femoral or crural. Approximately 96% of hernias are inguinal and 4% are femoral.<sup>5</sup> They can be classified according to their aetiology (congenital or acquired).<sup>5</sup> The most commonly used classifications for inguinal hernias are those by Gilbert, Hyhus, and Schumpelick. Other classifications systems have been proposed by Bendavid, Alexander, and Zollinger; however, they are difficult to remember and too complex. For this reason, a process to reach a consensus was used to develop an easier classification to categorise hernias into the updated traditional classification as shown in [Table 1](#).<sup>6</sup>

Risk factors for developing a hernia include the following<sup>3,7-14</sup>:

- History of hernia or prior hernia repair (including in childhood)
- Being older
- Being male
- Being Caucasian

**Table 1** Updated traditional classification of inguinal hernias.

Updated traditional	Nyhus–Stoppa	Gilbert	Schumpelick
1. Small indirect	I	1	L1
2. Medium indirect	II	2	L2
3. Large indirect	IIIB	3	L3
4. Small direct	IIIA	5	M1
5. Medium direct	IIIA	–	M2
6. Large direct	–	4	M3
7. Combined	IIIB	6	MC
8. Femoral	IIIC	7	F
0. Other	–	–	–

- Chronic cough
- Increased intra-abdominal pressure
- Chronic constipation
- Abdominal wall injury
- Smoking
- Ascites
- Prostatism
- Family history of hernia
- Abdominal aortic aneurysm

**Complications related to hernias**

Complications of inguinal or femoral hernia are relatively rare, depending on the clinical circumstances in which the patient is admitted to the operating room and the type of hernia. In a randomised study to determine the frequency of complications in a total of 1,983 patients who underwent laparoscopic and open inguinal hernia repair surgery, it was found that 35% had a significant complication and there was a higher range in those who underwent laparo-

scopic repair than in those who underwent open repair (39% vs 33%;  $P = .02$ ).<sup>1</sup>

The complications can be grouped into three types depending on when they presented:

- Intraoperative complications (bleeding, nerve injury, vascular injury, vessel injury in the vas deferens, anaesthesia complications), 2% of which occurred in open repair using the Lichtenstein mesh technique and 5% in laparoscopic repair. Vascular injury complications were reported in 5 patients who underwent laparoscopic surgery. No major vascular lesions were found in open repair surgeries.
- Short-term post-operative complications (surgical site infection, trocar site infection, wound haematoma, scrotal haematoma, orchitis, seroma or hydrocele, chronic leg pain, chronic inguinal pain, urinary tract infection, and urinary retention) are reported with similar percentages for laparoscopic vs open surgery, with 26% and 20%, respectively. Complications such as wound haematoma, scrotal haematoma, and hydrocele were the most common in both groups.
- Long-term complications (chronic leg pain, chronic inguinal pain, seroma or hydrocele) were the most common.<sup>8,15</sup>

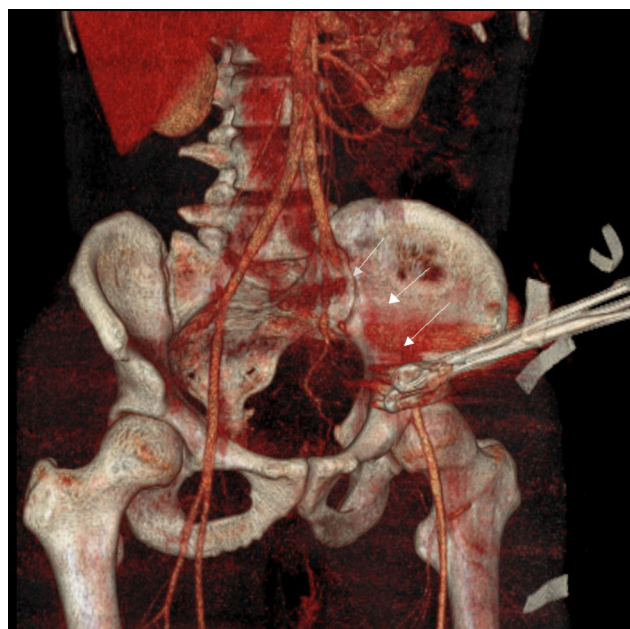
External iliac artery injury has a low incidence in open inguinal hernia repair and there are no case reports in the literature.

## Case report

A 28-year-old male patient. Originally from and residing in Cuyamecalco Cuicatlán with no prior relevant history, the complaint started with pain in the left inguinal region, which was exacerbated with effort and decreased when taking analgesics. There was an increase in volume that grew when performing the Valsalva manoeuvre. He was assessed by the Department of General Surgery and diagnosed with an inguinal hernia. Surgery was scheduled for inguinal hernia repair surgery, plus placement of a Lichtenstein polypropylene mesh. During the surgery he presented incidental arterial injury with 400 ml of blood loss. The site of bleeding was unable to be identified, and so two ring forceps were placed which stopped the bleeding and ended the procedure. He was transferred to this unit.

He was assessed in the Emergency Department at the Hospital Regional de Alta Especialidad de Oaxaca. The patient was conscious, oriented, well-hydrated, normal-coloured skin, uncompromised chest, abdomen flat, bowel sounds present, soft, depressible, non-tender upon palpation, no organomegaly. Transverse wound in the left inguinal region with two forceps inside, left pelvic extremities with no femoral, popliteal, or pedal pulse with diminished capillary refill 6 s after digital pressure and decreased temperature in comparison to the right side.

Blood work at admission: Blood gases: venous pH: 7.24,  $p\text{CO}_2$ : 39  $p\text{O}_2$ : 50  $\text{HCO}_3^-$ : 16.7,  $\text{BEb}^-$ : 10.7,  $\text{SO}_2$ : 77. Blood chemistry: glucose 98 mg/dl, urea 15 mg/dl, creatinine 0.6 mg/dl, albumin 3.8 g/dl, AST 29 U/l, ALT 36 U/l, ALP



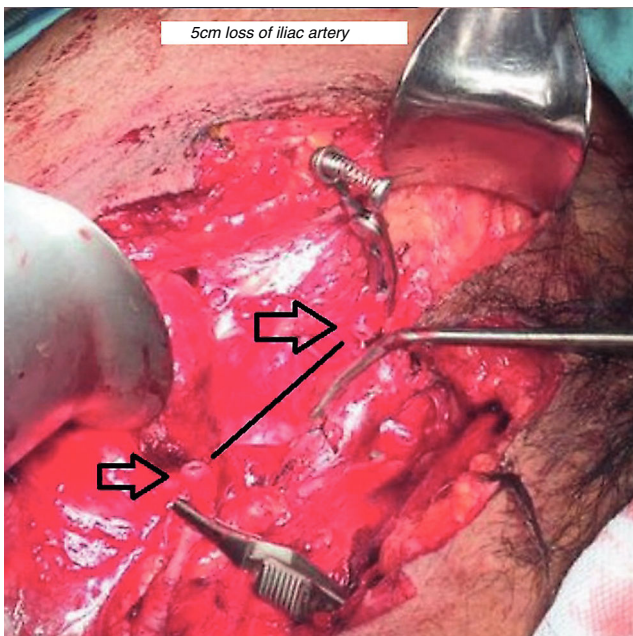
**Figure 1** Artery reconstruction computer tomography angiography (CTA). (Straightforward identification of the iliac artery lesion.)

90 U/l, LDH 758 mg/dl, sodium 139 mmol/l, K 3.8 mmol/l, Cl 105 mmol/l, calcium 9.3 mg/dl, total bilirubin: 2.06 mg/dl, indirect 1.96 mg/dl, complete blood count: white blood cells 17,000, haemoglobin 14.5 g/dl, platelets 218,000, neutrophils 14.68 fl, PT 14 s, aPTT 28 s, INR 1.07%.

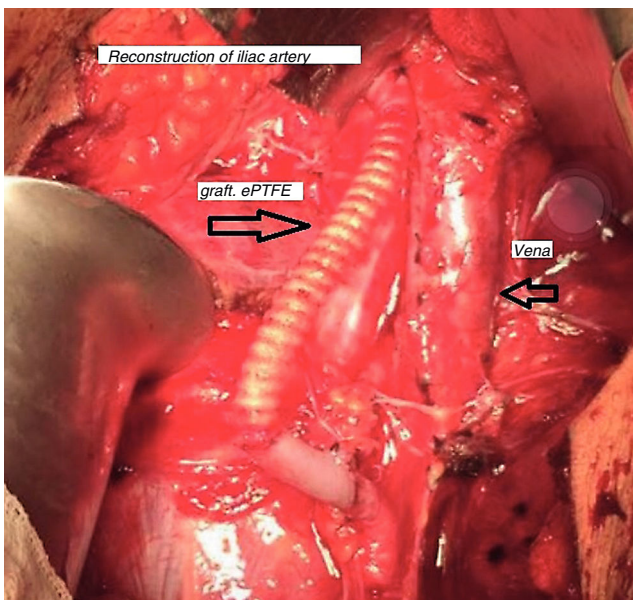
Computed tomography angiography (CTA) was performed with the following significant findings: The left external iliac artery showed no contrast enhancement throughout its entire trajectory. The presence of the ring forceps with which it was clamped were seen at the juncture with the common femoral artery, later bypassing this clamping. A Doppler ultrasound was performed, observing very slow flow rates in this artery, at 22 cm/s (Fig. 1). The common femoral artery was also partially clamped as is seen from the blood flow with the Doppler ultrasound. Diagnosis: occlusion of the left external iliac artery. The common femoral artery and common femoral vein were clamped, showing a bypass in their distal segment with diminished flow rates.

Per surgical protocol he was admitted to the operating room where surgery was performed using a Gibson incision. Findings included external iliac artery integrity and a complete blockage just below the inguinal ligament. Full dissection was performed (Fig. 2). An 8 French Fogarty catheter was introduced into the proximal and distal end of the severed artery and the thrombus was extracted. Adequate blood flow was confirmed and end-to-end anastomosis using polypropylene 6-0 was performed to connect the external iliac artery to the PTFE vascular graft (Fig. 3). Distal flow was confirmed, haemostasis was confirmed, and a layered polypropylene 1 closure was used. The procedure was ended.





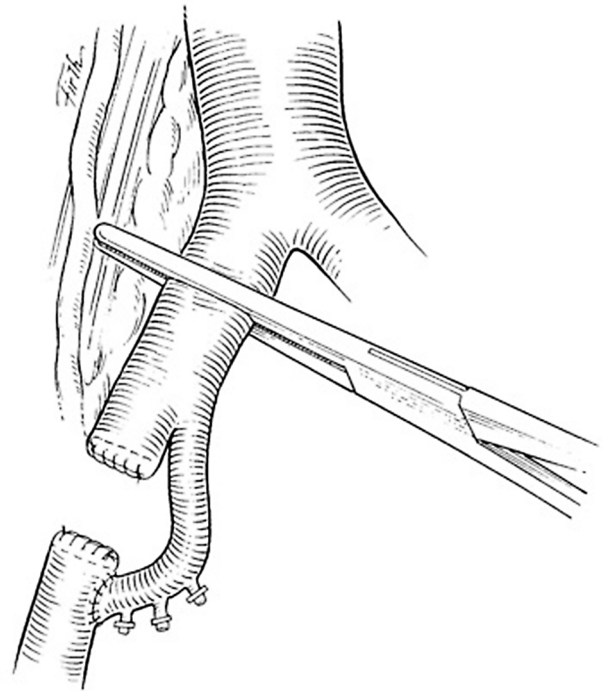
**Figure 2** Exposure of the inguinal region with proximal and distal ends. Iliac artery lesion with loss of tissue.



**Figure 3** Anastomosis of PTFE graft from the external iliac artery to the femoral artery.

## Discussion

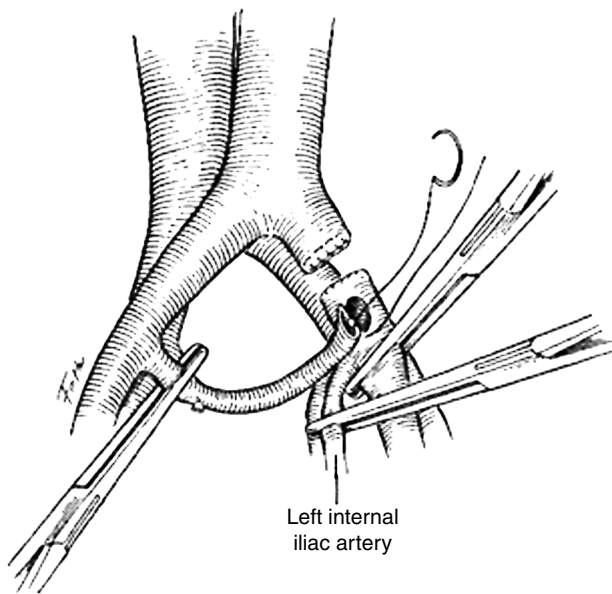
Injury to the external iliac artery during open inguinal hernia repair is extremely rare. However, it is a devastating scenario that can result in the loss of the limb if it is not properly treated in time to re-establish normal blood flow to the limb.<sup>16</sup> This type of lesion requires immediate surgical treatment. The CT angiography used for the diagnosis is a versatile technique with a wide range of applications beyond arteriography. Delineating the vascular anatomy is achieved well within a very short acquisition time and vessel injuries can be identified and characterised by the millimetre to



**Figure 4** Revascularisation with ipsilateral internal iliac artery.

be able to determine the type of lesion and its extent.<sup>17,18</sup> Managing the lesions depends on the anatomical location, the mechanism of the injury, and its nature. Endovascular diagnosis and treatment may be performed, including placing a stent. A good tolerance has been described, with a short hospital stay, and a combination of endovascular therapy may be performed as a complement to definitive surgical treatment.<sup>23</sup> It is possible to treat most lesions with just polypropylene vascular sutures (4-0 to 6-0). However, in more extensive lesions, an autologous vein graft is the material of choice in traumatic wounds, although in new studies the data do not favour vein grafts and even lean towards prosthetic materials to repair traumatic arterial lesions.<sup>19,20</sup> In this case, a synthetic polytetrafluoroethylene (PTFE) graft was placed and its permeability assessed using Doppler ultrasound, observing good blood flow through the femoral artery while also performing a vein check to rule out thrombosis.

Sometimes the necessary graft materials are not at hand, and so different techniques may be used. The ipsilateral internal iliac artery may serve to re-establish blood flow. The artery is moved to the level of the middle rectal artery. Once the internal iliac artery has been moved, the middle rectal artery is severed and the distal end is sutured with a continuous 4-0 polypropylene suture (Fig. 4).<sup>21</sup> Should the lesion be continuous to the internal iliac artery and unable to be moved, the contralateral artery can be used following the same steps (Fig. 5).<sup>21</sup> The extra-anatomical bypass is a femoro-femoral crossover graft. The two femoral arteries should preferably be exposed by two surgical teams, one for each side, and the conserved distal artery identified. A subcutaneous tunnel is created, going over the pubic symphysis between the two groins, and then anastomosis is performed



**Figure 5** Revascularisation with internal iliac artery.

below the inguinal ligament with 4-0 to 6-0 polypropylene vascular sutures.<sup>22</sup>

The most important thing with artery lesions is early identification, as well as damage control. It is important for the surgeon performing the reconstruction to have all the necessary materials to successfully complete the procedure. Should they not be available, it is best for the patient to be sent to a specialised centre where treatment can be offered.<sup>23</sup> For our patient, the quick decision to transfer him and the partial perfusion were a factor in his favour for saving the limb. Full knowledge of the anatomy is among the most important technical aspects for performing hernia repair.

## Ethical disclosure

**Protection of human and animal subjects.** The authors declare that no experiments were performed on humans or animals for this study.

**Confidentiality of data.** The authors declare that they have followed the protocols of their work centre on the publication of patient data.

**Right to privacy and informed consent.** The authors declare that no patient data appear in this article.

## Conflict of interest

The authors declare that they have no conflict of interests.

## References

1. Matthews RD, Anthony T, Kim LT, et al. Factors associated with postoperative complications and hernia recurrence for patients undergoing inguinal hernia repair: a report from the VA Cooperative Hernia Study Group. *Am J Surg.* 2007;194:611–7.
2. Schmedt CG, Sauerland S, Bittner R. Comparison of endoscopic procedures vs Lichtenstein and other open mesh techniques for inguinal hernia repair: a meta-analysis of randomized controlled trials. *Surg Endosc Other Interv Tech.* 2005;19:188–99.
3. Stephenson BM. Complications of open groin hernia repairs. *Surg Clin North Am.* 2003;83:1255–78.
4. Zhang C, Li F, Zhang H, et al. Self-gripping versus sutured mesh for inguinal hernia repair: a systematic review and meta-analysis of current literature. *J Surg Res.* 2013;185:653–60.
5. Abrahamson J. Etiology and pathophysiology of primary and recurrent groin hernia formation. *Surg Clin North Am.* 1998;78:953–72, vi [Internet; accessed 25.05.16].
6. Rutkow IM, Robbins AW. Demographic, classificatory, and socioeconomic aspects of hernia repair in the United States. *Surg Clin North Am.* 1993;73:413.
7. Zollinger RM Jr. An updated traditional classification of inguinal hernias. *Hernia.* 2004;8:318–22.
8. Bendavid R. Femoral hernias in females: facts, figures, and fallacies. In: Bendavid R, Abrahamson J, Arregui ME, et al., editors. *Abdominal wall hernias: principles and management* [Internet]. New York, NY: Springer New York; 2001. p. 639–40. Available from: [http://dx.doi.org/10.1007/978-1-4419-8574-3\\_95](http://dx.doi.org/10.1007/978-1-4419-8574-3_95)
9. Rosemar A, Angeras U, Rosengren A, et al. Effect of body mass index on groin hernia surgery. *Ann Surg* [Internet]. 2010;252:397–401. Available from: <http://www.ncbi.nlm.nih.gov/pubmed/20647921>
10. McIntosh A, Hutchinson A, Roberts A. Evidence-based management of groin hernia in primary care – a systematic review. *Fam Pract.* 2000;17:442.
11. Pannu R, McPhail IR. Prevalence of abdominal wall hernia in participants with abdominal aortic aneurysm versus peripheral arterial disease – a population-based study. *Angiology.* 2012;63:146–9.
12. Leme PL, Turatti RC. Who smokes does have more chance to show inguinal hernia? *Rev Assoc Med Bras.* 2010;56:262–3.
13. Sorensen LT, Friis E, Jorgensen T. Smoking is a risk factor for recurrence of groin hernia. *World J Surg.* 2002;26:397–400.
14. Akbulut S, Cakabay B, Sezgin A. A familial tendency for developing inguinal hernias: study of a single family. *Hernia.* 2010;14:431–4.
15. Koch A, Edwards A, Haapaniemi S. Prospective evaluation of 6895 groin hernia repairs in women. *Br J Surg.* 2005;92:1553.
16. Pascarella R, Del Torto M, Politano R, et al. Critical review of pelvic fractures associated with external iliac artery lesion: a series of six cases. *Injury.* 2014;45:374–8.
17. Güven K, Acuna B, Faculty I. Multidetector computed tomography angiography of the abdomen. *Eur J Radiol.* 2004;52:44–55.
18. Foley WD. Multidetector CT: abdominal visceral imaging. *RadioGraphics.* 2002;22:701–19.
19. Martin TD, Mattox KL, Feliciano DV. Prosthetic grafts in vascular trauma: a controversy. *Compr Ther.* 1985;11:41–5.
20. Vertrees A, Fox CJ, Quan RW, et al. The use of prosthetic grafts in complex military vascular trauma: a limb salvage strategy for patients with severely limited autologous conduit. *J Trauma.* 2009;66:980–3.
21. Lee JT, Bongard FS. Iliac vessel injuries. *Surg Clin North Am.* 2002;82:21–48.
22. Ksycki M, Ruiz G, Perez-Alonso AJ, et al. Iliac vessel injuries: difficult injuries and difficult management problems. *Eur J Trauma Emerg Surg.* 2012;38:347–57.
23. Doody O, Given MF, Lyon SM. Extremities – indications and techniques for treatment of extremity vascular injuries. *Injury.* 2008;39:1295–303.