




REVISTA MÉDICA DEL
HOSPITAL GENERAL
DE MÉXICO

www.elsevier.es/hgmx



CLINICAL CASE

Hypertrophic pyloric stenosis in a preterm infant: a case report



L.P. Islas-Domínguez^{a,d,*}, J.R. Jiménez-Jiménez^{b,d},
J. Cruz-Díaz^{c,d}, K. Castellanos Reyes^{c,d}

^a Head of Paediatrics Department, Hospital General de México "Dr. Eduardo Liceaga", Mexico City, Mexico

^b Neonatologist, Neonatal Intensive Care, Hospital General de México "Dr. Eduardo Liceaga", Mexico City, Mexico

^c Registered Nurse, Hospital General de México, "Dr. Eduardo Liceaga", Mexico City, Mexico

^d Neonatologist, Instituto Mexicano del Seguro Social, Centro Médico Nacional la Raza, Mexico City, Mexico

Received 16 October 2015; accepted 1 February 2017

Available online 28 February 2017

KEYWORDS

Preterm infant;
Pyloric hypertrophy;
Vomiting

Abstract We report the case of a preterm infant of 35 weeks gestation, who presents vomiting towards the end of the first week of life. Suspected diagnosis of hypertrophic pyloric stenosis by exclusion. The ultrasound confirms the diagnosis. Pyloromyotomy is performed with excellent evolution. We describe this case due to time of onset of the disease associated to a preterm infant.

© 2017 Sociedad Médica del Hospital General de México. Published by Masson Doyma México S.A. This is an open access article under the CC BY-NC-ND license (<http://creativecommons.org/licenses/by-nc-nd/4.0/>).

PALABRAS CLAVE

Recién nacido
prematuro;
Hipertrofia de píloro;
vómito

Estenosis hipertrófica de píloro en un prematuro: a propósito de un caso

Resumen Se presenta el caso de un recién nacido prematuro de 35 semanas de gestación, quien presenta vómitos de contenido gástrico hacia el final de la primera semana de vida. Se sospecha diagnóstico de estenosis hipertrófica de píloro por exclusión. El ultrasonido corrobora el diagnóstico. Se realiza piloromiotomía con excelente evolución. Se describe este caso por el tiempo de presentación del padecimiento asociado a un recién nacido prematuro.

© 2017 Sociedad Médica del Hospital General de México. Publicado por Masson Doyma México S.A. Este es un artículo Open Access bajo la licencia CC BY-NC-ND (<http://creativecommons.org/licenses/by-nc-nd/4.0/>).

* Corresponding author at: Hospital General de México Dr. Eduardo Liceaga, Dr. Balmis 148, Colonia Doctores, Delegación Cuauhtémoc, C.P. 06720 Mexico City, Mexico.

E-mail address: luneonatos@hotmail.com (L.P. Islas-Domínguez).

Introduction

Hypertrophic pyloric stenosis (HPS) is a disease which occurs in the second week of life, of unknown origin, which consists of the narrowing of the pylorus due to concentric muscular hypertrophy, causing gastric outlet obstruction with progressive vomiting that leads to malnutrition, dehydration and serious metabolic disorders.¹

Prompt diagnosis prevents complications, reduces the morbidity rate and enables surgical treatment with an excellent prognosis.²

The origin is unknown, but the most accepted hypotheses suggest the use of concentrated baby formulas, lack or reduction of pyloric muscle innervation, elevation of gastrin and gastric somatostatin and even allergy.^{3,4}

Repeated vomiting favours oedema of the pyloric mucous membrane, which exacerbates the symptoms, leading to loss of fluids, hydrogen ions and chlorine, all of which leads to hypochloreaemic alkalosis. The lack of actual ingestion leads to malnutrition and greater sensitivity to metabolic, haemodynamic and infectious complications.^{2,5,6}

Some patients present jaundice derived from elevated indirect bilirubin, from a not completely understood mechanism that reduces glucuronyl transferase and increases enterohepatic bilirubin circulation; this is corrected when the patient undergoes surgery.^{6,7}

The symptoms do not usually appear before the second or third week of life, and earlier onset is exceptional.⁸⁻¹¹

Case report

A male newborn (NB), from the second pregnancy of a 27-year-old mother. She denies drug addiction. Three normal obstetric ultrasounds. Discharge of clear transvaginal fluid for 30 h. Baby born vaginally with Apgar 8-9, Capurro "B" 35 weeks, gestation, weight 2550 g, height 48 cm.

Management starts with fasting, oxygen therapy, ampicillin and amikacin for seven days due to premature membrane rupture. Insidious respiratory and infectious evolution. Sudden onset of postprandial non-biliary vomiting and increase of indirect bilirubin. Given the possibility of nosocomial infection, he is started on cefepime plus dicloxacillin. X-ray of chest and abdomen shows gastromegaly (Fig. 1). Oral ingestion is resumed, with enteral stimulation, but vomiting persists so he continues to fast, a central line is installed and parenteral nutrition is started. Gastric hyperperistalsis and palpation of pyloric mass. Blood gas shows normochloreaemic metabolic alkalosis. Ultrasound shows pylorus 18.8 mm long, with slices showing muscle wall thickness of up to 4.3 mm (Fig. 2), confirming the diagnosis of HPS.

Surgical finding: 2 cm pylorus with pearly appearance. Oral intake resumed 24 h after surgery, well tolerated and accepting milk increments. Antibiotics suspended as there is no evidence of infection. Discharged home with follow-up as outpatient.

Discussion

Hypertrophic pyloric stenosis is a very rare condition in preterm infants. The literature describes an incidence rate

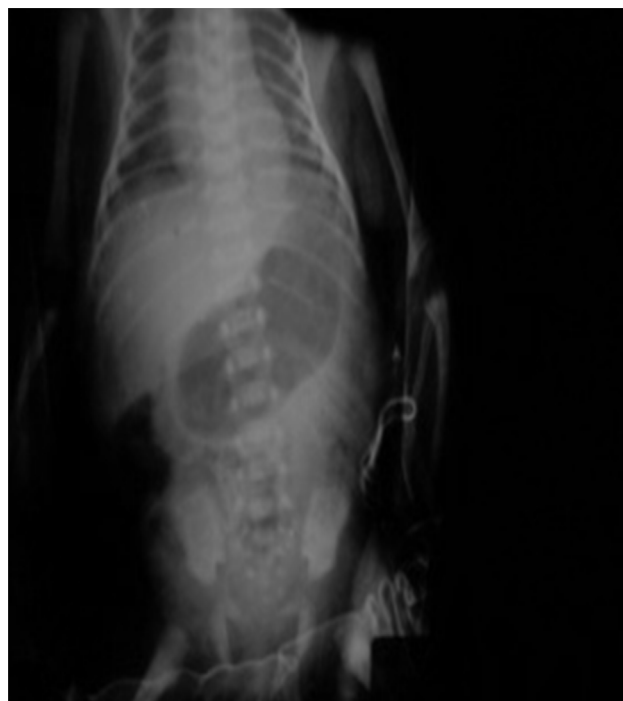

Figure 1 X-ray of abdomen and chest. Note the presence of gastromegaly.

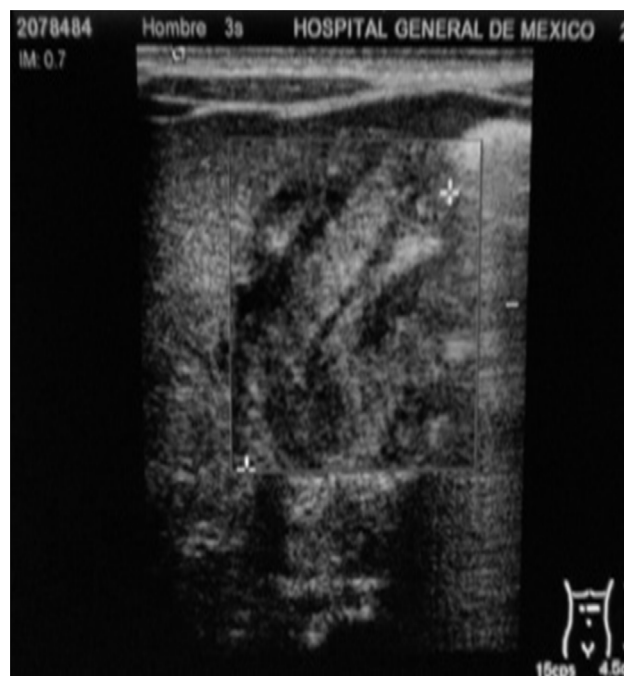

Figure 2 Pyloric ultrasound. Note increased length and thickness of muscle wall.

of 1 to 2.9 cases per 1000 pre-term births.^{10,13,14} It is a very common cause of surgery in the first month of life. Despite the radical change of this condition's presentation in the last 10 years,²³ the rarity of its presentation in preterm infants is still emphasised.¹²

In full-term newborns it appears from the second to the seventh week after birth, and its incidence rate is

much higher than in pre-terms.¹⁰ This year, Stark et al. reported a series of 2466 newborns with HPS, 208 (8.43%) of whom were premature, compared with 2258 (91.57%) full-term babies with the problem, showing how rare this condition is in babies with less than 37 weeks of gestation (wog).¹⁰

The literature describes factors associated to preterm newborns with HPS: mothers with multiple pregnancies, exposure to macrolides and male gender¹⁰; however, the greater the prematurity, from 28 to 31 wog, a ratio of 1:1 F–M is reported. This ratio increases to 2:1 F–M from 32 to 36 wog, and for full-term NBs, the F–M ratio is 5:1.¹² Our patient was of the gender primarily reported in the literature.

Predominance of the male gender has a genetic component, as the greater risk of gastrointestinal malformations in that gender is well documented, as is the risk of rotavirus infections in childhood. This suggests considerable differences in the development, maturity and function of the gastrointestinal tract between men and women.^{15–19}

Mutations in chromosomes 2q, 3p, 5q, 7p, 11q, 16p and even in chromosome x play an important role in the development of HPS.^{14,17–21} However, despite a large variety of studies, it has not been possible to document a Mendelian inheritance pattern, not even when present in monozygotic twins, which supports the theory that environmental factors are fundamental in its presentation.²²

Other risk factors associated to HPS are: caesarian birth and mothers smoking during pregnancy.^{12,13} However, caesarian birth as a risk factor is not fully clear, as in some series the birth method is consistent with maternal infection. Vaginal birth has also been described as beneficial, as it prevents hormonal cascades and stress factors in newborns. Our patient was born vaginally and therefore not affected by such a risk factor.

The association with smoking has also been attributed to tobacco substances that cause pyloric spasm and muscular hypertrophy.^{12,13} The mother of the NB in question denied any toxic habits.

Mothers under 20 years of age, diabetic and with a low education level have also been associated to a greater risk of HPS, as are women exposed to pesticides, as they act as endocrine disruptors.^{20,23} None of these factors were present in this case.

On the other hand, prostaglandin infusion at standard doses has also been reported as a cause of the condition, due to direct pharmacological effects on the pyloric muscle.²⁴ This drug was not administered to our patient, as he did not present a ductus arteriosus-dependent cardiopathy, but it is important to consider this undesirable effect in patients who do.

The clinical presentation often consists of vomiting that could initially be mistaken for reflux, yet episodes often lead to metabolic alkalosis due to loss of hydrogen ions and chlorine. This is consistent with our patient's symptoms. This presentation in pre-term newborns is often diagnosed and treated as gastroesophageal reflux, as premature babies have multiple risk factors such as the use of methyl-xanthines and immaturity of the upper oesophageal sphincter. This makes it difficult to consider HPS as the primary origin of vomiting.²⁵

Table 1 Pathognomic findings in abdominal ultrasound.

a) Pyloric diameter from 15 to 18 mm
b) Muscle thickness from 3 to 4 mm and length more than 17 mm
c) Narrow intestinal span with characteristic "double track" appearance

Our patient was initially treated with anti-reflux measures, using widely recommended drugs at standard doses.^{25–27}

The patient was examined, palpating a pyloric mass, a pathognomic sign of the condition.²⁸

Abdominal ultrasound is considered to be a highly sensitive (91%) and specific (100%) test, which also makes it possible to distinguish duodenal membranes or other malformations as differential diagnoses.^{28,29} In our patient, the ultrasound showed the findings described in [Table 1](#) and [Fig. 2](#), which are consistent with the literature.^{28,29} Three factors have been suggested for the condition's diagnosis: the presence of delayed gastric output by ultrasound, pyloric sphincter muscle thickness of ≥ 2.5 mm and muscle length ≥ 14 mm.³⁰

Other diagnostic tests mentioned in the literature are a gastroduodenal oesophageal series and endoscopy, which can also have therapeutic purposes.^{28,30–32}

Laparoscopic, or minimally invasive, surgery is increasingly recommended in the literature, but requires appropriate medical instruments and equipment to tackle the physiology of pre-term infants and their reduced surgical fields,^{30–33} with small incisions through the umbilical scar and excellent results, starting food intake the following day. However, our hospital does not yet have the equipment required for this procedure in pre-term infants. Even so, the results were excellent in our patient, operated on with a conventional technique, enabling him to feed after 24 h, with no complications and outpatient follow-up.

Conclusion

The objective of presenting this case report is to consider HPS as a possible diagnosis in pre-term NB patients with food intolerance symptoms,^{10–13,25,29} even when gestational age and days of onset are not commonly reported in the literature, as presentation has radically changed in the last 10 years and even male predominance is not common in such patients. This could prevent said diagnosis, delaying treatment, increasing the duration of hospitalisation and inherent complications.

It is therefore important to broaden our diagnostic approach and consider this condition in our patients, as the tendency towards preterm birth in intensive or intermediate care units, mothers aged 20 years or less, with low educational levels, smoking, and the use of macrolides and prostaglandins for commonly associated conditions are increasingly common in our hospital population.

Ethical disclosures

Protection of human and animal subjects. The authors declare that no experiments were performed on humans or animals for this study.

Confidentiality of data. The authors declare that they have followed the protocols of their work centre on the publication of patient data.

Right to privacy and informed consent. The authors declare that no patient data appear in this article.

Conflict of interest

The authors declare that they have no conflict of interests.

References

- Chung E. Infantile hypertrophic pyloric stenosis: genes and environment. *Arch Dis Child*. 2008;93:1003–4.
- Schwartz MZ. Hypertrophic pyloric stenosis. In: Neill O, Rowe MJ, Grosfeld JL, et al., editors. *Pediatric surgery*. St. Louis: Mosby; 1998. p. 1111.
- Özok G, Taneli C, İlhan H, et al. Hypertrophic pyloric stenosis with esophageal atresia: an etiologic dilemma of hypertrophic pyloric stenosis. *Pediatric Cerrahi Dergisi*. 1993;7:44–5.
- Kobayashi H, O Brian DS, Puri P. Selective reduction in intramuscular nerve supporting cells in infantile hypertrophic pyloric stenosis. *J Pediatric Surg*. 1994;29:651.
- Fernbach SK, morello FP. Renal abnormalities in children with hypertrophic pyloric stenosis, fact or fallacy? *Pediatr Radiol*. 1993;23:286.
- Puglisi RN, Whalen TV. Metabolic alkalosis upon presentation with hypertrophic pyloric stenosis: a thig of the past. *Int Pediatr*. 1994;9:251.
- Bracho-Blanchet E, Leon-Villaneva Y. Hipertrofia congenita del piloro. In: Rodríguez-Suarez RS, Velazquez-Jones L, Valencia-Mayoral P, et al., editors. *Urgencias en pediatría*. 4th ed. Mexico: Edit. Panamericana; 1996. p. 718.
- Rollins MD, Shields MD, Quinn RJ, et al. Pyloric stenosis: congenital or acquired. *Arch Dis Child*. 1989;64:138–9.
- Schechter R, Torfs CP, Bateson TF. The epidemiology of infantile hypertrophic pyloric stenosis. *Paediatr Perinat Epidemiol*. 1997;11:407–27.
- Stark CM, Rogers PL, Eberly MD, et al. Nylund. Association of prematurity with the development of infantile hypertrophic pyloric stenosis. *Pediatr Res*. 2015;78:218–22.
- Katumba-Lunyanya J, Misra I, Chawda N, et al. Can you be too premature to develop pyloric stenosis? *BMJ Case Reports*. 2012, <http://dx.doi.org/10.1136/bcr-2012-006592>.
- Krogh C, Gørtz S, Wohlfahrt J, et al. Pre- and perinatal risk factors for pyloric stenosis and their influence on the male predominance. *Am J Epidemiol*. 2012;176:24–31.
- Svenningsson A, Svensson T, Akre O, et al. Maternal and pregnancy characteristics and risk of infantile hypertrophic pyloric stenosis. *J Pediatr Surg*. 2014;92:1226–31.
- Krogh C, Fischer TK, Skotte L, et al. Familial aggregation and heritability of pyloric stenosis. *JAMA*. 2010;303:2393–9.
- Doodnath R, Puri PA. Systematic review and meta-analysis of Hirschsprung's disease presenting after childhood. *Pediatr Surg Int*. 2010;26:1107–10.
- Fischer TK, Bihmann K, Perch M, et al. Intussusception in early childhood: a cohort study of 1.7 million children. *Pediatrics*. 2004;114:782–5.
- Ryan MJ, Ramsay M, Brown D, et al. Hospital admissions attributable to rotavirus infection in England and Wales. *J Infect Dis*. 1996;174 suppl 1:S12–8.
- Manikkam M, Tracey R, Guerrero-Bosagna C, et al. Plastics derived endocrine disruptors (BPA, DEHP and DBP) induce epigenetic transgenerational inheritance of obesity, reproductive disease and sperm epimutations. *PLoS One*. 2013;8:e55387.
- Tracey R, Manikkam M, Guerrero-Bosagna C, et al. Hydrocarbons epigenetic transgenerational inheritance of obesity, reproductive disease and sperm epimutations. *Reprod Toxicol*. 2013;36:104–16.
- Manikkam M, Tracey R, Guerrero-Bosagna C, et al. Pesticide and insect repellent mixture (permethrin and DEET) induces epigenetic transgenerational inheritance of disease and sperm epimutations. *Reprod Toxicol*. 2012;34:708–19.
- Agopian AJ, Lupo PJ, Canfield MA, et al. Case-control study of maternal residential atrazine exposure and male genital malformations. *Am J Med Genet A*. 2013;161A:977–82.
- Gezer HÖ, Oguzkurt P, Temiz A, et al. Hypertrophic pyloric stenosis in twins; genetic or environmental factors. *Clin Genet*. 2015;87:388–91.
- Markel TA, Proctor C, Ying J, et al. Environmental pesticides increase the risk of developing hypertrophic pyloric stenosis. *J Pediatr Surg*. 2015;50:1283–8.
- Soyer T, Yalcin S, Bozkaya D, et al. Transient hypertrophic pyloric stenosis due to prostoglandin Infusión. *J Perinatol*. 2014;34:800–1.
- Acker SN, Garcia AJ, Ross JT, et al. Current trends in the diagnosis and treatment of pyloric stenosis. *Pediatr Surg Int*. 2015;31:363–6.
- Young TE. Pharmacologic treatment of feeding intolerance in neonates. *NeoReviews*. March 2010;11:e139.
- Hibbs AM. Pharmacotherapy for gastroesophageal reflux disease. *NeoReviews*. March 2011;12:e159.
- http://www.cenetec.salud.gob.mx/descargas/gpc/CatalogoMaestro/330.IMSS_10.Estenosis.Hipertrofica.Cong.piloro/EyR-IMSS_330.10.pdf 1-36 sep 2015.
- Cascio S, Steven M, Livingstone H, et al. Hypertrophic pyloric stenosis in premature infants: evaluation of sonographic criteria and short-term outcomes. *Pediatr Surg Int*. 2013;29:697–702.
- Li B, Chen W, Wang S, et al. Single-site umbilical laparoscopic pyloromyotomy in neonates less than 21-day old. *Surg Today*. 2015;45:29–33.
- Ibarguen Secchia E. Endoscopic pyloromyotomy for congenital pyloric stenosis. *Gastrointest Endosc*. 2005;61:598–600.
- Zhang YX, Nie YQ, Xiao X, et al. Treatment of congenital hypertrophic pyloric stenosis with endoscopic pyloromyotomy. *J Pediatr*. 2008;46:247–51.
- Guelfand M, Santos M, Olivos MC, et al. Cirugía mínimamente invasiva en recién nacidos de menos de 2.500. *Rev Chil Pediatr*. 2014;85:64–7.