

**Figure 2** Histology. Massive infiltration of the liver tissue with diffuse sinusoidal embolization by a neoplasm with organoid pattern. Immunohistochemical staining for chromogranin and synaptophysin. Ki67 showed nuclear expression in about 45% of the cells.

is an absence of the classical imaging findings consistent with liver metastases, because of the histological pattern of microinvasion<sup>3</sup>. The massive sinusoidal infiltration and hepatic vessels obstruction by tumor cells result in ischemia and hypoxic hepatocellular necrosis<sup>1,3</sup>. We have a short window for investigation since most of these patients die soon after admission<sup>4</sup>. The diagnosis is frequently made by *postmortem* liver histology.

The majority of neuroendocrine tumors of unknown primary site are poorly differentiated carcinomas with aggressive biology<sup>5</sup>. These cancers are characterized by multiple sites of metastases and rarely produce symptoms related to secretion of bioactive substances. In addition to the liver, common metastatic sites include bone, lung and brain. Small cell neuroendocrine tumors with metastases, frequently originate in the lungs. Diagnosis of these neuroendocrine tumors depends on immunohistochemical staining for chromogranin and/or synaptophysin.

## Bibliografía

1. Rowbotham D, Wendon J, Williams R. Acute liver failure secondary to hepatic infiltration: a single centre experience of 18 cases. *Gut*. 1998;42:576–80.
2. Lee W, Larson A, Stravitz R. AASLD position paper: the management of acute liver failure: update 2011. *Hepatology*. 2011; 1–22.
3. Alexopoulou A, Koskinas J, Deutsch M, Delladetsima J, Kountouras D, Dourakis SP. Acute liver failure as the initial manifestation of hepatic infiltration by a solid tumor: report of 5 cases and review of the literature. *Tumori*. 2006;92: 354–7.
4. McGuire BM, Cherwitz DL, Rabe KM, Ho SB. Small-cell carcinoma of the lung manifesting as acute hepatic failure. *Mayo Clin Proc*. 1997;72:133–9.
5. Hainsworth JD, Johnson DH, Greco FA. Poorly differentiated neuroendocrine carcinoma of unknown primary site. A newly recognized clinicopathologic entity. *Ann Intern Med*. 1988;109: 364.

Nuno Veloso\*, Pedro Amaro, Manuela Ferreira, José Manuel Romãozinho, Carlos Sofia

*Gastroenterology Intensive Care Unit, Gastroenterology Department – Coimbra University Hospital, Coimbra, Portugal*

\*Corresponding author.

E-mail address: [nuno.veloso@hotmail.com](mailto:nuno.veloso@hotmail.com) (N. Veloso).

<http://dx.doi.org/10.1016/j.gastrohep.2013.09.007>

## Pancreatic plasmacytoma with biliary obstruction as a manifestation of multiple myeloma relapse

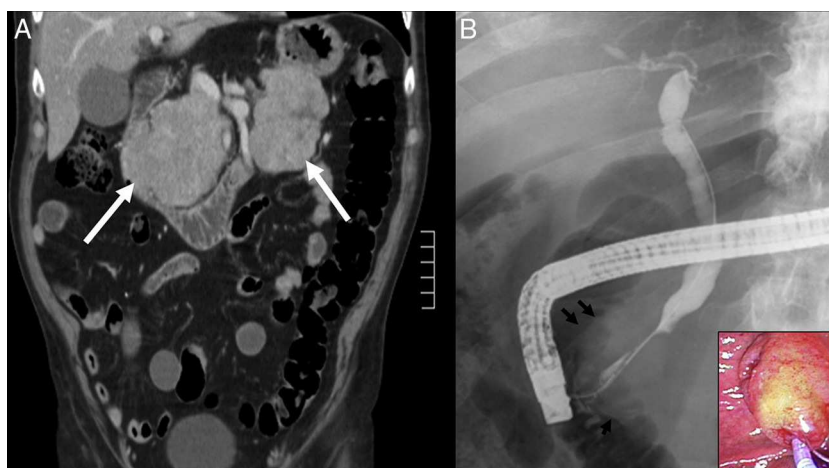


## Plasmocitoma pancreático con obstrucción biliar como manifestación en recidiva de mieloma múltiple

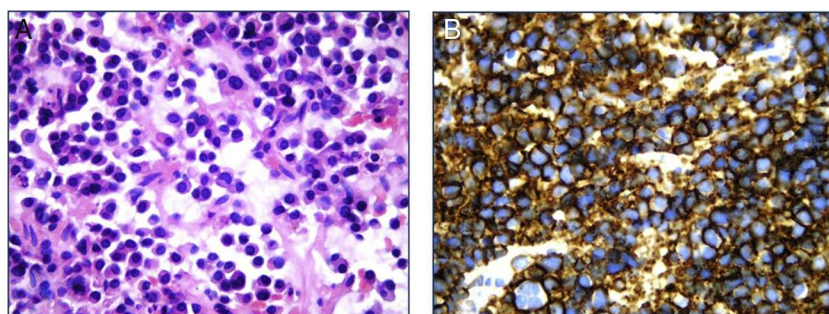
Extramedullary plasmacytomas are uncommon plasma cell neoplasms which account for 3–4% of these tumors.<sup>1</sup> The presence of extramedullary plasmacytoma associated to multiple myeloma (MM) occurs in 4–7% of patients.<sup>2</sup> Gastrointestinal involvement may appear in up to 10% of the cases, usually involving the liver and, less frequently, the pancreas.<sup>2</sup> In a recent review of patients with MM, only 50 reported cases of pancreatic plasmacytomas (PP) were diagnosed as part of a clinical progressive course of the disease in

majority of these cases.<sup>3</sup> There are very few cases reported of PP as a manifestation of MM relapse. We report a case of a man with previous history of MM who developed obstructive jaundice due to PP as a manifestation of MM relapse.

A 70-year-old man with a previous history (3 yrs prior) of stage IIA MM was admitted to the hospital with jaundice. Previous bone marrow aspiration showed 12% plasma cells and lambda light chains were present on serum immunofixation (IF). Serum protein analysis was normal and there was no proteinuria. Urine IF was negative. Treatment with dexamethasone and thalidomide was started with complete response. A follow-up evaluation one year later showed no evidence of bone marrow involvement (bone marrow aspiration was normal and serum/urine IF were negative). Four weeks before admission, he complained of jaundice, anorexia and weight loss (approximately 8 kg). Diabetes mellitus with insulin requirement was diagnosed three weeks before admission. On examination, he was afebrile, and alert and oriented. His abdominal exam revealed a palpable nodular



**Figure 1** A: Abdominal CT showing pancreatic masses located in head and tail regions (arrows). B: ERCP: Long distal bile duct stricture with proximal biliary dilatation. Major duodenal papilla size increase in the cholangiography (arrows) and duodenoscopy (right lower corner).



**Figure 2** A: Pancreatic biopsy showing neoplastic plasma cell infiltration (H/E  $\times$  100). B: Immunohistochemistry showing CD138 expression.

mass localized in the right upper quadrant. Laboratory tests showed serum bilirubin level of 17.2 mg/dl (normal range < 1.2 mg/dl), aspartate aminotransferase 98 U/l (normal range < 37 U/l), alanine aminotransferase 227 U/l (normal range < 41 U/l), gamma glutamyl transpeptidase 1087 U/l (normal range < 49 U/l) and alkaline phosphatase 1106 U/l (normal range 91–258 U/l). Serum lipase and amylase values were within normal values. An abdominal computed tomography (CT) revealed common bile duct dilatation (10 mm) and a pancreatic mass (8.6 cm  $\times$  6.2 cm) located in the pancreatic head and nodular lesions in the pancreas tail. Peripancreatic lymph nodes (>1 cm) were also present, but there were no signs of vascular invasion or liver involvement (Fig. 1A). Carcinoembryonic antigen levels were 5.4 ng/ml (normal value < 5 ng/ml) and CA19-9 levels were 266 IU/ml (normal value < 37 IU/ml). Endoscopic retrograde cholangiopancreatography (ERCP) showed a diffuse increase of the size of the major duodenal papilla with ulcerated mucosa (Fig. 1B). The cholangiogram showed a 30 mm stricture in the distal common bile duct with proximal biliary dilatation. Multiple biopsies from the papillary region were taken and a 10 cm, 10Fr plastic stent was inserted across the stricture. The pathological study showed a neoplastic plasma cell infiltration (Fig. 2A). A CT-guided needle biopsy of the pancreatic head mass confirmed the findings of the papillary biopsies. Plasma cells were CD138 positive and showed

lambda light chain monoclonal expression (Fig. 2B). Proliferation index, assessed with Ki67, was 40% and the neoplastic cells exhibited p53 expression in a 50%. PP secondary to MM was diagnosed. Treatment with lenalidomide, cyclophosphamide and dexamethasone was started with good clinical and analytical response. After three months, liver tests were normal and an abdominal CT showed a significant reduction of the pancreatic head mass and disappearance of the tail lesions. ERCP performed four months after the initial presentation jaundice showed resolution of the biliary stricture.

Extramedullary plasmacytomas are rare tumors that can occur either as a manifestation of MM (secondary tumors) or as a primary lesion (primary tumors).<sup>2</sup> About 80% of the extramedullary plasmacytomas develop in the upper respiratory tract; however, other sites such as the gastrointestinal tract may also be involved. Extramedullary plasmacytomas are frequently diagnosed in advanced stages of MM and are associated with poor prognosis.<sup>4</sup>

Pancreatic involvement by plasma cell neoplasms is very infrequent, accounting for less than 0.1% of pancreatic masses.<sup>3</sup> PP occur most commonly in the sixth and seventh decades of life and have a male predominance (3:1).<sup>1</sup> In a series of autopsies of 57 patients with known MM, PP was found in only 2% of the cases.<sup>2</sup> Most of the PP are single lesions, although two or more concurrent lesions may occur.<sup>3</sup> There are very few cases reported in the literature of PP

as a manifestation of MM relapse. Fischer et al. described a similar case in whom PP of the head of the pancreas was the main manifestation of MM relapse.<sup>5</sup> Furthermore, in two cases PP was diagnosed in association to other extramedullary plasmacytomas localized in the stomach or at the spinal canal.<sup>6,7</sup> Finally, PP was reported as the only clinical manifestation of MM relapse in two patients after an initial response with autologous stem cell transplantation.<sup>8,9</sup>

The differential diagnosis of PP includes pancreatic adenocarcinoma, neuroendocrine tumors, lymphoma and amyloidosis. Endoscopic ultrasound-guided fine needle aspiration or percutaneous biopsy can be helpful to confirm the pathological diagnosis. However, as described in this case, biopsies from the papillary region during ERCP allow a less invasive approach in cases with papillary involvement. The use of ERCP in the diagnosis of PP has not been reported.<sup>10</sup> In our knowledge, this is the first case that PP was diagnosed with biopsies at ERCP.

Treatment of biliary obstruction secondary to PP should include endoscopic stent placement and a size reduction therapy of the pancreatic mass.<sup>3</sup> Plasma cells tumor are highly radiosensitive and chemosensitive. In secondary PP, therapeutic options include chemotherapy, radiation therapy, or a combination of both. Prognosis is more favorable in primary PP than in secondary PP. The presence of extramedullary involvement in MM at any time of its evolution is associated with a more aggressive course.<sup>3</sup>

In conclusion, we present the case of a patient that developed a PP as a manifestation of MM relapse. Obstructive jaundice due to a biliary stricture improved with biliary stenting and chemotherapy. Although symptomatic involvement of the gastrointestinal tract in patients with MM is infrequent, PP should be considered in the differential diagnosis in patients with known MM and a pancreatic mass.

## Bibliografía

1. Akiyama H, Krigel RL. Metastatic extramedullary plasmacytoma: a case report and review of the literature of a rare pseudocarcinoma. *Am J Hepatol.* 1988;27:115-7.

2. Miljkovic M, Senadhi V. Use of endoscopic ultrasound in diagnosing plasmacytoma of the pancreas. *JOP.* 2012;13:26-9.
3. Lopes da Silva R. Pancreatic involvement by plasma cell neoplasms. *J Gastrointest Cancer.* 2012;43:157-67.
4. Sanal SM, Yaylaci M, Mangold KA, Pantazis CG. Extensive extramedullary disease in myeloma. *Cancer.* 1996;77:1298-302.
5. Fischer A, Suhrland MJ, Vogl SE. Myeloma of the head of the pancreas. A case report. *Cancer.* 1991;67:681-3.
6. Hiller N, Goitein O, Ashkenazi YJ. Plasmacytoma of the pancreas. *Isr Med Assoc J.* 2004;6:704-5.
7. Coss A, Zhou C, Byrne MF, Weiss AA. Relapse of multiple myeloma presenting with biliary obstruction. *Can J Gastroenterol.* 2010;24:237-8.
8. Balliu E, Casas JD, Barluenga E. Multifocal involvement of the pancreas in multiple myeloma: sonographic, CT, and MR imaging findings. *AJR Am J Roentgenol.* 2003;180:545-6.
9. Annibaldi O, Marchesi F, Petrucci MT, Tirindelli MC, Avvisati G. Relapse of IgA lambda multiple myeloma presenting as obstructive jaundice and abdominal pain. *Onkologie.* 2009;32:119-21.
10. Leake PA, Coard KC, Plummer JM. Extramedullary plasmacytoma of the pancreas as an uncommon cause of obstructive jaundice: a case report. *J Med Case Rep.* 2009;3:8785.

Luciana Castellani<sup>a</sup>, María Virginia Burgésser<sup>b</sup>,  
Luciana Guanchiale<sup>c</sup>, Analía Benavidez<sup>d</sup>, Ana B. de Diller<sup>b</sup>,  
Ana Lisa Basquiera<sup>c</sup>, Domingo Balderramo<sup>d,\*</sup>

<sup>a</sup> Internal Medicine Department, Hospital Privado-Centro Médico de Córdoba, Córdoba, Argentina

<sup>b</sup> Pathology Department, Hospital Privado-Centro Médico de Córdoba, Córdoba, Argentina

<sup>c</sup> Haematology and Oncology Department, Hospital Privado-Centro Médico de Córdoba, Córdoba, Argentina

<sup>d</sup> Gastroenterology Department, Hospital Privado-Centro Médico de Córdoba, Córdoba, Argentina

\*Corresponding author.

E-mail address: [dbalderramo@hospitalprivadosa.com.ar](mailto:dbalderramo@hospitalprivadosa.com.ar) (D. Balderramo).

<http://dx.doi.org/10.1016/j.gastrohep.2013.10.004>

## Invaginación ileocólica en un paciente infectado por el virus de la inmunodeficiencia humana

### Ileocolonic invagination in an human immunodeficiency virus-positive man

La invaginación intestinal en el adulto es una enfermedad poco frecuente, y en más del 90% existe una lesión orgánica subyacente<sup>1</sup>. Presentamos el caso de un paciente con infección por virus de la inmunodeficiencia humana (VIH) que presenta cuadro de sintomatología abdominal, confirmándose en los estudios de imagen una invaginación ileocólica. El estudio anatomopatológico fue diagnóstico de linfoma de Burkitt. El linfoma de Burkitt es un tipo de linfoma no

hodgkiniano (LNH) que con cierta frecuencia constituye la primera enfermedad definitiva de sida. La variante asociada a inmunodepresión cursa con afectación de ganglios linfáticos, siendo la invaginación intestinal una forma de presentación característica de la variante esporádica<sup>2</sup>.

Varón de 30 años, con antecedentes de hepatitis aguda A, sífilis correctamente tratada e infección VIH, categoría A2. La cifra de CD4 es de 552 pero se inició tratamiento con tenofovir, emtricitabina y efavirenz por elevada carga viral un año después del diagnóstico. Aproximadamente un mes después del inicio del tratamiento antirretroviral, el paciente acude a consultas por un cuadro de una semana de evolución de dolor abdominal en región periumbilical con exacerbaciones cólicas, acompañado de deposiciones líquidas de escasa cuantía sin sangre ni productos patológicos, y disminución de la ingesta por empeoramiento de la sintomatología con la misma, con pérdida de 5 kg de peso. No