



IMAGE OF THE MONTH

Black bowel: An unexpected cause of abdominal pain



Intestino negro: una causa inesperada de dolor abdominal

Rui Gaspar^{a,b,c,*}, Patricia Andrade^{a,b,c}, Helder Cardoso^{a,b,c}, Guilherme Macedo^{a,b,c}

^a Gastroenterology Department, Centro Hospitalar São João, Porto, Portugal

^b Porto Medical School, Portugal

^c Porto WGO Training Center, Portugal

Available online 15 December 2017

A 31-year-old man with past medical history of anal fistula 6 years before and bone marrow failure of unknown etiology diagnosed two months before presentation, was admitted at the Hematology Department due to fever, abdominal pain and nausea. He was under ciclosporine 400 mg/day and aciclovir 400 mg 3 times a day. The results of his examination were significant for moderate epigastric and umbilical

abdominal pain and laboratory data showed pancytopenia (similar to previous results) and C reactive protein of 266 mg/dL. Ultrasound imaging was unremarkable.

He was then treated with piperacilin/tazobactam 4.5 g/3 times a day. The CT scan showed two segments in the jejunum with wall thickening and mesenteric edema and vascular mesenteric prominence.

In the clinical discussion we proposed to perform an enteroscopy which showed a 10 cm segment in the proximal jejunum with edematous and fragile mucosa, with ulceration and extensive necrosis (Figs. 1–3).

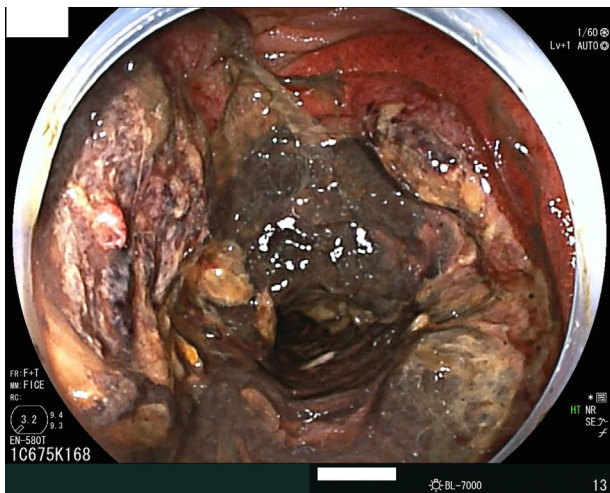


Figure 1 Extensive necrosis of the mucosa.

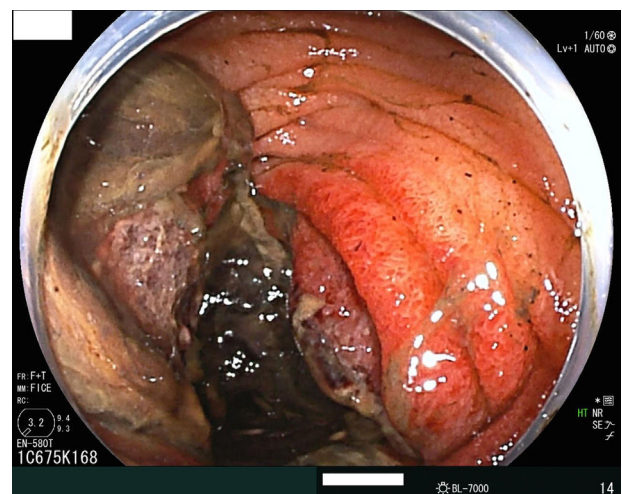


Figure 2 Edematous mucosa of the jejunum.

* Corresponding author.

E-mail address: rui Lopes Gaspar@gmail.com (R. Gaspar).

<https://doi.org/10.1016/j.gastrohep.2017.11.005>

0210-5705/© 2017 Elsevier España, S.L.U. All rights reserved.

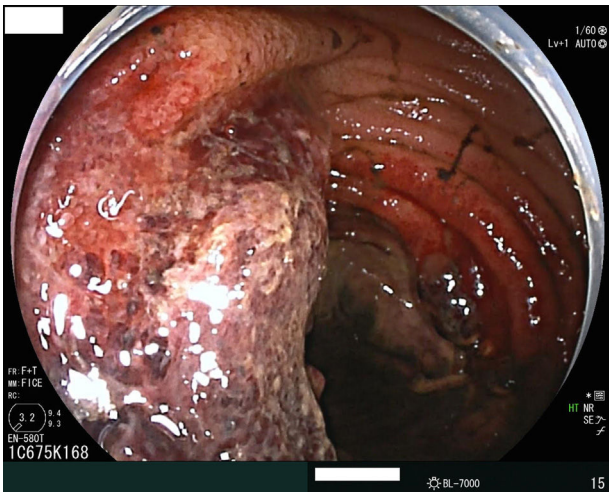


Figure 3 Ulceration of the mucosa.

Histopathological specimen was compatible with ischemic enteritis.

Ischemic enteritis is a rare entity but with high mortality. Therefore, early recognition is very important in the management of these patients.