



IMAGE OF THE MONTH

Gallstone ileus secondary to a cholecystocolonic fistula

Ileo biliar secundario a fístula colecistocolónica

Luisa Roade Tato*, Meritxell Ventura Cots, Mar Riveiro-Barciela

Liver Unit, Internal Medicine Department, Hospital Universitari Vall d'Hebron, Barcelona, Spain

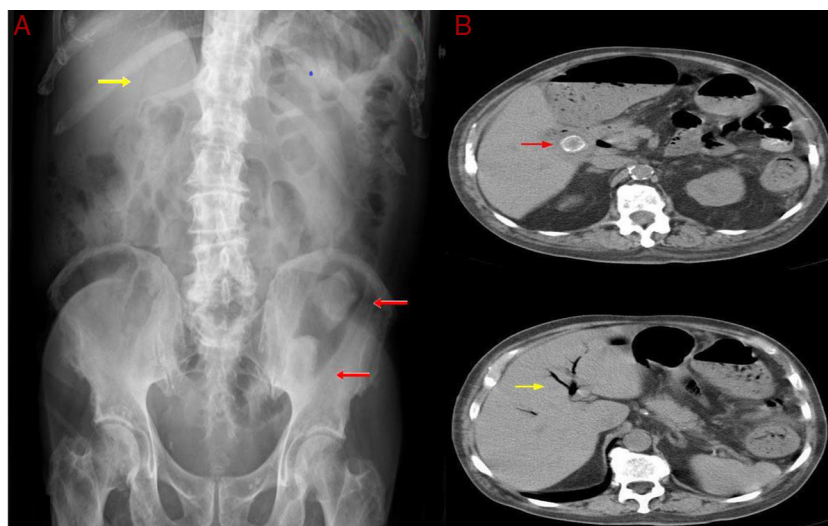


Figure 1

A 78-year-old man exhibited repeated episodes of vomiting, diffuse abdominal pain and constipation for 10 days. One year previously, he had suffered from biliary colic but cholecystectomy was not performed because of high surgical risk. Physical examination showed a mass on the left side of the abdomen and increased bowel sounds. The blood count showed light leukocytosis and normal metabolic profile. An abdominal radiography showed Rigler's triad (Fig. 1, Image A): pneumobilia (yellow arrow),

small-bowel dilatation, and two ectopic gallstones in the sigmoid colon (red arrows). Computerized tomography confirmed the presence of intra and extrahepatic pneumobilia (Fig. 1, Image B), as consequence of cholecysto-colonic fistula secondary to cholelithiasis. Gallstone ileus is a rare complication of gallstone disease, and in less than 4% of cases the gallstone is located in the sigmoid colon. The diagnosis is not always straightforward and usually depends on radiographic findings, although the classic Rigler's triad is described in fewer than half of patients¹⁻³. A laparotomy was performed and a right hemicolectomy was necessary because of colonic perforation. The patient underwent successful surgery and no post-operative complications ensued.

* Corresponding author.

E-mail address: luisaroadet@gmail.com (L. Roade Tato).

References

1. Reisner RM, Cohen JR. Gallstone ileus: a review of 1001 reported cases. *Am Surg.* 1994;60:441–6.
2. Lassandro F, Gagliardi N, Scuderi M, Pinto A, Gatta G, Mazzeo R. Gallstone ileus analysis of radiological findings in 27 patients. *Eur J Radiol.* 2004;50:23–9.
3. Rigler LG, Borman CN, Noble JF. Gallstone obstruction: pathogenesis roentgen manifestations. *JAMA.* 1941;117:1753–9.