



IMAGE OF THE MONTH

Lemmel's syndrome[☆]

Síndrome de Lemmel

Ismael Mora-Guzmán*, Elena Martín-Pérez



Department of General and Digestive Surgery. Hospital Universitario de la Princesa. c/ Diego de León 62 – 4th Floor, 28006, Madrid, Spain

Received 11 July 2018; accepted 20 July 2018

A 57-year-old man with previous cholecystectomy presented with a 5-day history of abdominal pain and jaundice. He did not have a fever. Physical examination revealed pain in the right upper quadrant of the abdomen, rebound was absent; Murphy's sign was negative. Laboratory results included a white-cell count 10.25×10^9 , with 82% neutrophils, liver panel was: total bilirubin 5.84 mg/dL (conjugated bilirubin 4.8 mg/dL), alkaline phosphatase 218 U/L, gamma-glutamyl transferase 340 U/L, aspartate aminotransferase 197 U/L, aspartate aminotransferase 321 U/L. Abdominal ultrasonography was normal and contrast magnetic resonance imaging (MRI) scan (Fig. 1) showed no intrahepatic or extrahepatic biliary dilatation and presence of a large juxtapapillary diverticulum. He was treated with broad-spectrum antibiotic therapy and discharged after one week. At one-year follow-up, the patient was asymptomatic.

Periapillary diverticula are usually asymptomatic; however, complications can occasionally occur,¹ including diverticulitis, duodenal obstruction, perforation, hemorrhage, acute pancreatitis,² or biliary symptoms.

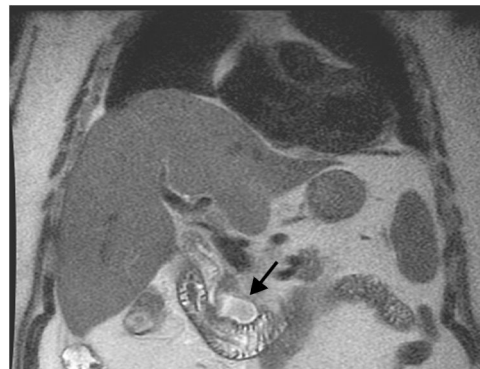


Figure 1 Abdominal T2-MRI scan. T2-contrast magnetic resonance imaging (MRI): a large juxtapapillary diverticulum (arrow) without intrahepatic or extrahepatic biliary dilatation.

Lemmel's syndrome is a rare cause of obstructive jaundice in the absence of gallstones and periampullary tumors, due to biliary mechanical compression by a juxtapapillary diverticulum. There are only few case reports of this rare condition.^{1,3} This entity can associate with abdominal pain or acute cholangitis mimicking periampullary tumors, and can be recurrent. In relatively asymptomatic

[☆] This manuscript is original and has not been submitted to another journal.

* Corresponding author.

E-mail address: moraguzman.dr@gmail.com (I. Mora-Guzmán).

patients, conservative treatment is recommended. In some cases endoscopic treatment can be used by means of sphincterotomy,¹ requiring surgical management if biliary obstruction is present or symptoms are often recurrent.³

Conflicts of interest

The authors declare no conflicts of interest. The patient has signed the informed consent and has agreed to the use and publication of the confidential information and images with a scientific purpose and without a lucrative objective. All authors have read and approved the paper submitted.

References

1. Somani P, Sharma M. Endoscopic ultrasound of Lemmel's syndrome. *Indian J Gastroenterol.* 2017;36:155–7.
2. Mora-Guzmán I, Muñoz de Nova JL, García-Sanz Í, Martín-Pérez E. Acute pancreatitis secondary to perampullary duodenal diverticulitis. *Cir Esp.* 2017;95:231.
3. Rouet J, Gaujoux S, Ronot M, et al. Lemmel's syndrome as a rare cause of obstructive jaundice. *Clin Res Hepatol Gastroenterol.* 2012;36:628–721.