



IMAGE OF THE MONTH

Over-the-scope-clip: Endoscopic treatment of Boerhaave syndrome



Over-the-scope-clip: tratamiento endoscópico del síndrome de Boerhaave

M^a Henar Núñez Rodríguez*, Fátima Sánchez Martín, Rodrigo Nájera, Pilar Díez Redondo

Servicio de Aparato Digestivo, Hospital Universitario Rio Hortega, Valladolid, Spain

A 63-year-old man was admitted in Emergency Services 12 h after vomiting and hematemesis. He was on regular treatment with antihypertensive and anti-inflammatory. Haematocrit decreased from 43% to 30%. The patient had not got any sign of sepsis with a normal chest X-ray. Urgent gastroscopy demonstrated active haemorrhage due to a 10 mm oesophageal disruption located at the oesophagogastric junction (Fig. 1A). The procedure was performed at endoscopy room under deep sedation. The disruption was resolved with placement of over-the-scope clip (OTSC) (Fig. 1B). After that, the computer tomography discarded contrast leakage. The patient remained hemodynamically stable without haemorrhagic recurrence and

without fever during hospitalization. He was discharged home after 72 h. After 4 months of follow-up the patient remains asymptomatic. Endoscopic control demonstrated no clip at oesophageal mucosa (Fig. 1C).

Spontaneous oesophagus perforation (Boerhaave's syndrome) is a spontaneous disruption of the distal oesophagus associated with high mortality. Surgery repair during the first 24 h from perforation is the best option.¹ Surgery is associated with a high rate of mortality and morbidity. In the last years, endoscopic techniques have appeared^{2–4} to resolve gastrointestinal perforation. OTSC could be used for gastrointestinal perforation equal or under 10 mm.

* Corresponding author.

E-mail address: henarnrod@yahoo.es (M.H. Núñez Rodríguez).

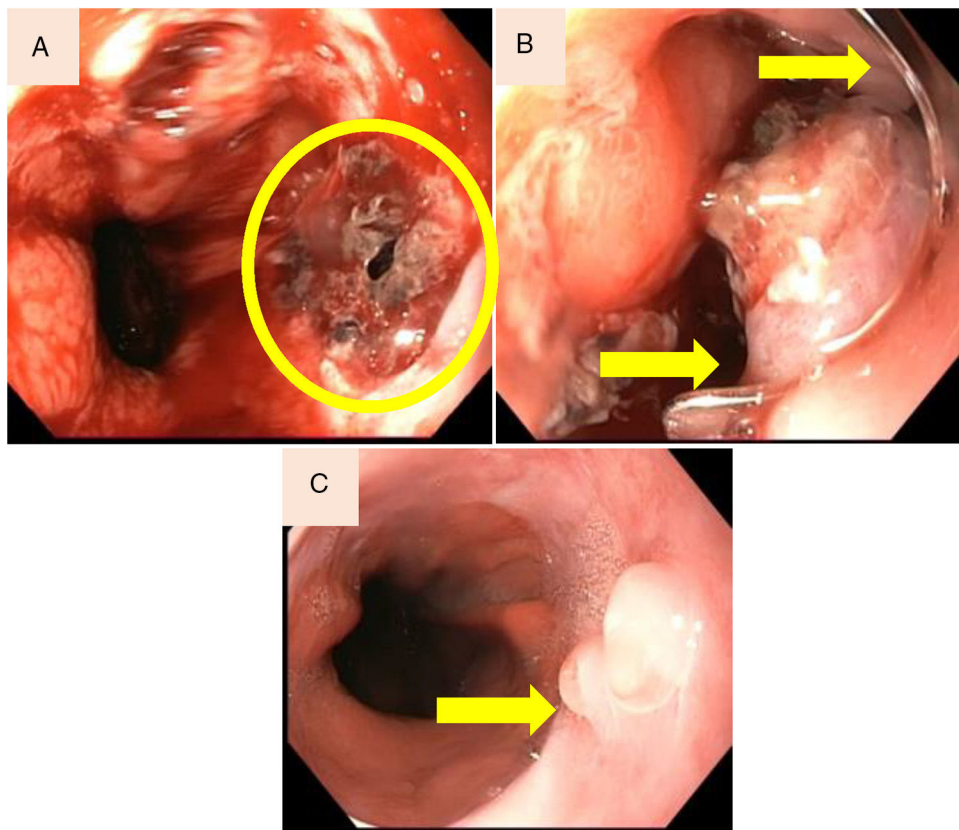


Figure 1 (A) Laceration of the oesophagogastric junction. (B) Disruption resolved with placement of over-the-scope clip (OTSC). (C) Endoscopic control demonstrated no clip and granulation formation at the laceration site.

Conflict of interest

The authors declare no conflict of interest.

References

1. Sutcliffe RP, Forshaw MJ, Datta G, Rohatgi A, Strauss DC, Mason RC, et al. Surgical management of Boerhaave's syndrome in a tertiary oesophagogastric centre. *Ann R Coll Surg Engl.* 2009;91:374–80.
2. Tellechea JI, Gonzalez JM, Miranda-Garcia P, Culetto A, D'Journo XB, Thomas PA, et al. Role of endoscopy in the management of Boerhaave syndrome. *Clin Endosc.* 2018;51:186–91.
3. Bona D, Aiolfi A, Rausa E, Bonavina L. Management of Boerhaave's syndrome with an over-the-scope clip. *Eur J Cardiothorac Surg.* 2014;45:752–4.
4. Paspatis GA, Dumonceau JM, Barthet M, Meisner S, Repici A, Saunders BP, et al. Diagnosis and management of iatrogenic endoscopic perforations: European Society of Gastrointestinal Endoscopy (ESGE) position statement. *Endoscopy.* 2014;46:693–711.