



IMAGE OF THE MONTH

Rectal perforation, a rare adverse event of ventriculoperitoneal shunt: Case report

Perforación rectal, un acontecimiento adverso raro de la derivación ventriculoperitoneal: informe de casos

Guillermo Pérez-Aguado*, Francisca Hernández Medina,
Emilia María García García, Oliver Dub Machado, Néstor Alemán Pérez

Department of Gastroenterology, Hospital Universitario Gran Canaria Doctor Negrín, Las Palmas de Gran Canaria, Las Palmas, Spain



An 87-year-old woman with a VP shunt to treat normotensive hydrocephalus, was derived to Emergencies because she had a catheter protruding through the rectum. Previously, the doctor's residence decided to pull out the catheter and cut it off. In emergencies, she was asymptomatic with no evidence or palpation of the VP shunt during the physical exam. Blood test only revealed an elevation of RCP (188) with no leukocytosis. Cranial and abdominal CT scan confirmed that the shunt was placed correctly and without signs of perforation.

A colonoscopy with CO₂ insufflation was performed, with-out possibility of reaching further than 30 cm from the rectal margin due to inappropriate intestinal preparation,

and showed no foreign bodies. However, 15 mm margin rectal perforation was spotted at 10 cm (Figs. 1 and 2) distance from the rectal margin and clipped using OVESCO, which gave excellent result (Fig. 3). Owing to the endoscopy findings, the ventriculoperitoneal shunt was removed. The patient stayed under surveillance for 24h and continued asymptomatic. She was finally discharged. The next day the patient came again exteriorising the rest of the catheter and it was removed manually with no complications (Fig. 4).

Iatrogenic rectal perforation of a VP is a rare adverse event.¹⁻³ It must be suspected in patients that carry this catheter with abdominal pain.¹⁻⁷ In few cases, surgery can be avoided with endoscopy management.

* Corresponding author.

E-mail address: guiperez92@gmail.com (G. Pérez-Aguado).

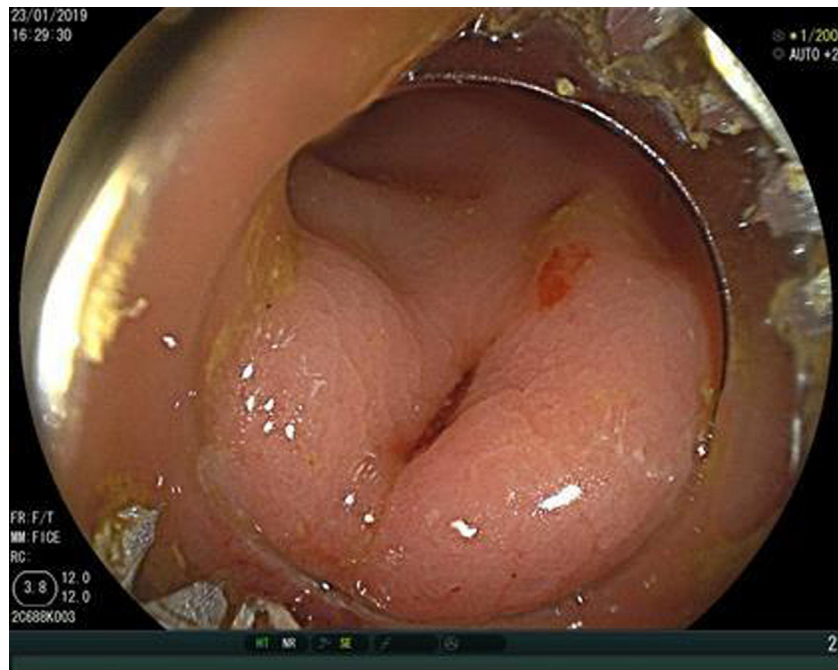


Figure 1 Rectal perforation discovered by colonoscopy.

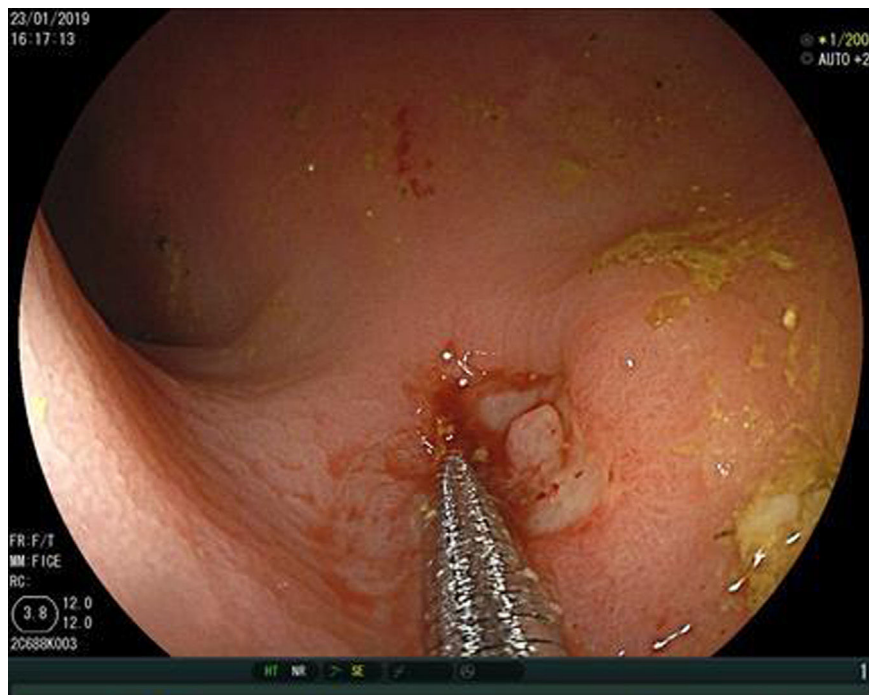


Figure 2 Measurement of the rectal perforation with 15 mm endoscopy forceps.

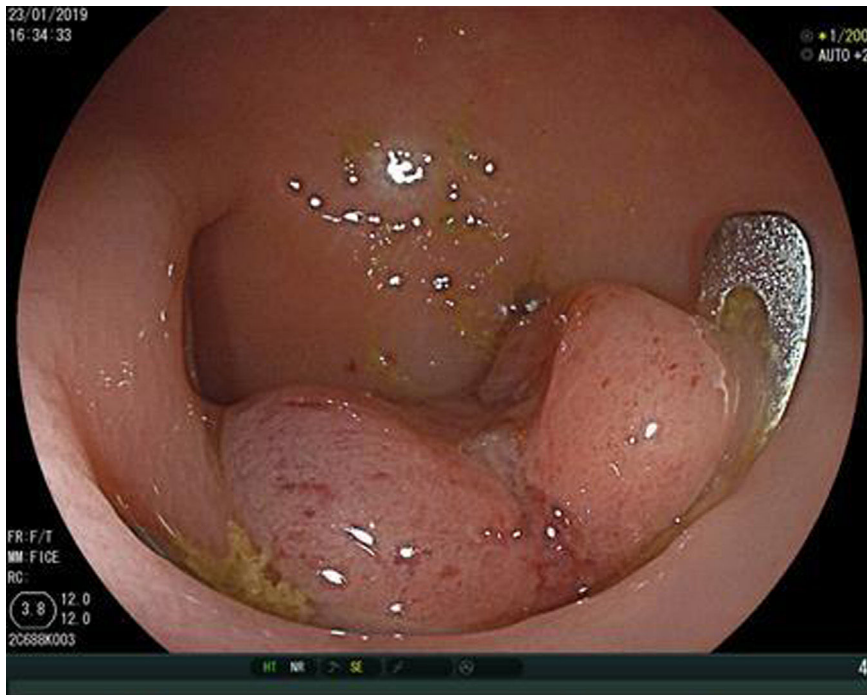


Figure 3 Endoscopic clipping of the rectal perforation with 15 mm OVESCO.

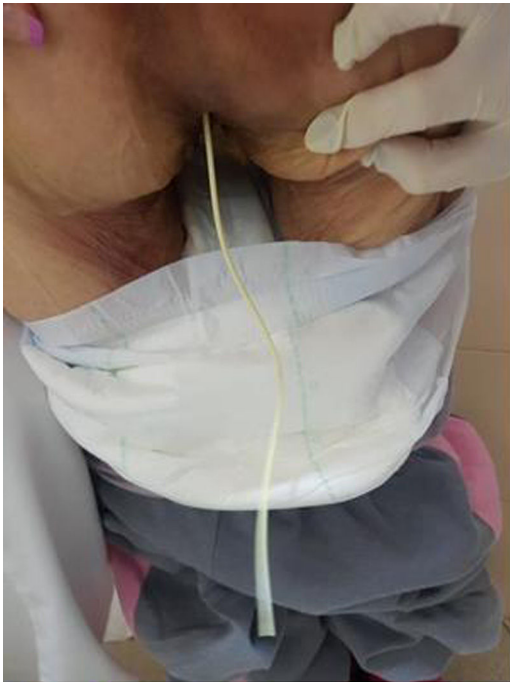

Figure 4 Ventriculoperitoneal shunt going out through the rectum.

References

1. Bosch J, Poch JM, Moraga FA, Terradas P, Rubio E. Complicaciones abdominales en la edad pediátrica de las derivaciones ventrículo-peritoneales. *Neurocirugía*. 1990;1:261–308, [http://dx.doi.org/10.1016/S1130-1473\(90\)71189-X](http://dx.doi.org/10.1016/S1130-1473(90)71189-X)
2. Castillo JL, Martínez B, Venegas DB, Hernández M, García S, Orcharte O, et al. Migración de catéter de derivación ventrículo-peritoneal a través de colon Reporte de un caso y revisión de la literatura; *Rev. Esp Med-Quir*. 2007;12:71–4.
3. Osman B, Roushias S, Hargest R, Narahari K. Migration of ventriculoperitoneal shunt to urethral and rectal orifices. *BMJ Case Rep*. 2017, <http://dx.doi.org/10.1136/bcr-2017-220187>
4. Vilallonga R, Vallribera F, Mañas MJ, Espin E. Perforación del colon por catéter de derivación ventriculoperitoneal. *Cir Esp*. 2008;83:165–223, [http://dx.doi.org/10.1016/S0009-739X\(08\)70552-9](http://dx.doi.org/10.1016/S0009-739X(08)70552-9)
5. Yousfi MM, Jackson NS, Abbas M, Zimmerman RS, Fleischer DE. Bowel perforation complicating ventriculoperitoneal shunt: case report and review. *GIE J*. 2003;58:114–48, <http://dx.doi.org/10.1067/mge.2003.324>
6. Pikoulis E, Psallidas N, Daskalakis P, Kouzelis K, Leppäniemi A, Tsatsoulis PAT A rare complication of a ventriculoperitoneal shunt resolved by colonoscopy. *Endoscopy*. 2003;35:463, <http://dx.doi.org/10.1055/s-2003-38763>
7. Dumoulin FL, Schlieff H-E. An unusual foreign body in the transverse colon. *Endoscopy*. 2007;39:E85, <http://dx.doi.org/10.1055/s-2006-945178>