



IMAGE OF THE MONTH

A case report of drug-induced ischemic colitis accompanied by ulcerative colitis

Un informe sobre un caso de colitis isquémica inducida por drogas acompañada de colitis ulcerosa

Guanyu Zhou^a, Fei Xiong^a, Xudan Yang^b, Pu Wang^{a,*}

^a Department of Gastroenterology, Sichuan Academy of Medical Sciences & Sichuan Provincial People's Hospital, Chengdu, China

^b Department of Pathology, Sichuan Academy of Medical Sciences & Sichuan Provincial People's Hospital, Chengdu, China

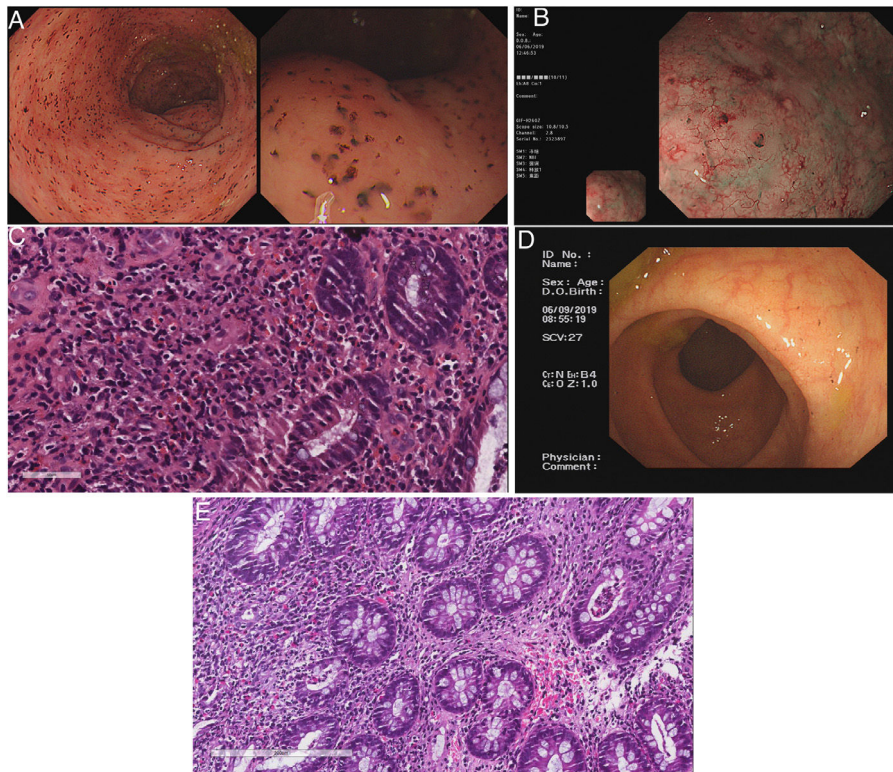


Figure 1

* Corresponding author.

E-mail address: wangpuhuaxi@qq.com (P. Wang).

<https://doi.org/10.1016/j.gastrohep.2020.03.013>

0210-5705/© 2020 Elsevier España, S.L.U. All rights reserved.

A 23-year old woman, presented with progressive abdominal pain and diarrhea for 6 months. During the time, she was treated with a decocted Chinese herbal medicine for 1 month.

On colonoscopy, diffusive black spots from cecum to the sigmoid colon were found (Fig. 1A, white light). The microvessels around the black spots were dilated and interrupted (Fig. 1B, magnified NBI).

Focal crypt abscess, chronic hemorrhagic necrosis, hemosiderin and phagocytes were seen in epithelium. Inflammatory cell infiltrated into the lamina propria, dominated by lymphocytes and plasma cells. Vascular obstruction and remote hemorrhage could be seen (Fig. 1 C, as described in this paragraph).

This patient was diagnosed as drug-induced ischemic colitis¹ accompanied with ulcerative colitis (UC).

The herbal medicine was discontinued. UC was treated with mesalazine. The abdominal pain and bloody diarrhea were alleviated.

Surveillance colonoscopy 3 months later showed a basically normal mucosa with rare black spots (Fig. 1D, images

from surveillance colonoscopy). Pathological examination showed fewer focal crypt abscess and vasculitis, as well as a decline of lymphocyte (Fig. 1E, pathological results after treatment).

Funding

All authors declare no funding on this work.

Conflict of interest

All authors declare no conflict of interest.

Reference

1. Fenoglio-Preiser CM, Noffsinger AE, Stemmermann GN, Lantz PE, Isaacson PG. *Gastrointestinal pathology: an atlas and text*. Lippincott Williams & Wilkins; 2007, ISBN 9780781771467.