



IMAGE OF THE MONTH

Ulcerative jejunitis secondary to Zollinger-Ellison syndrome following endoscopic ultrasound guided gastrojejunostomy

Yeyunitis ulcerativa secundaria al síndrome de Zollinger-Ellison después de una gastroyeyunostomía guiada por ultrasonido endoscópico

Enrique Pérez-Cuadrado-Robles^{a,*}, Hedi Benosman^{a,1}, Emilie Moati^{b,1},
Christophe Cellier^{a,1}, Gabriel Rahmi^{a,1}

^a Department of Gastroenterology, Georges-Pompidou European Hospital, AP-HP.Centre – Université de Paris, Paris, France

^b Department of Oncology, Georges-Pompidou European Hospital, AP-HP.Centre – Université de Paris, Paris, France

A 64-years-old male with a well-differentiated duodenal neuroendocrine tumor of grade 2 was referred to our center because of an inferior vena cava occlusion. An endovascular metal stenting was performed (Fig. 1a, blue arrow). Four days later, he developed an intestinal obstruction due to vascular stent compression in the duodenum. A 12-cm uncovered duodenal self-expandable metal stent was successfully placed (Fig. 1a, left red arrow), but the patient had a persistent gastric outlet obstruction due to the compression of the distal duodenum.

Thus, an endoscopic ultrasound-guided gastrojejunostomy using a 20 mm lumen apposing metal stent (HotAxios, Boston Scientific, Voisins-le-Bretonneux, France) was

decided (Fig. 1a, right red arrow).¹ The procedure occurred without complications and the patient recovered well, with oral solid diet.

One week later he presented with melena and anemia. An upper-GI endoscopy showed no gastric bleeding source. However, multiple circumferential ulcers (Fig. 1c) were found in the jejunal lumen near to the gastrojejunostomy (Fig. 1b). This ulcerative jejunitis lead to the diagnosis of a Zollinger-Ellison syndrome.² A treatment with double dose prompt pump inhibitors was started with clinical improvement. The patient was discharged, and no bleeding recurrence or reintervention was observed for two months follow-up.

* Corresponding author.

E-mail address: kikemurcia@gmail.com (E. Pérez-Cuadrado-Robles).

¹ Service de Gastroentérologie et Endoscopies Digestives, 20 Rue Leblanc, 75015 Paris, France.

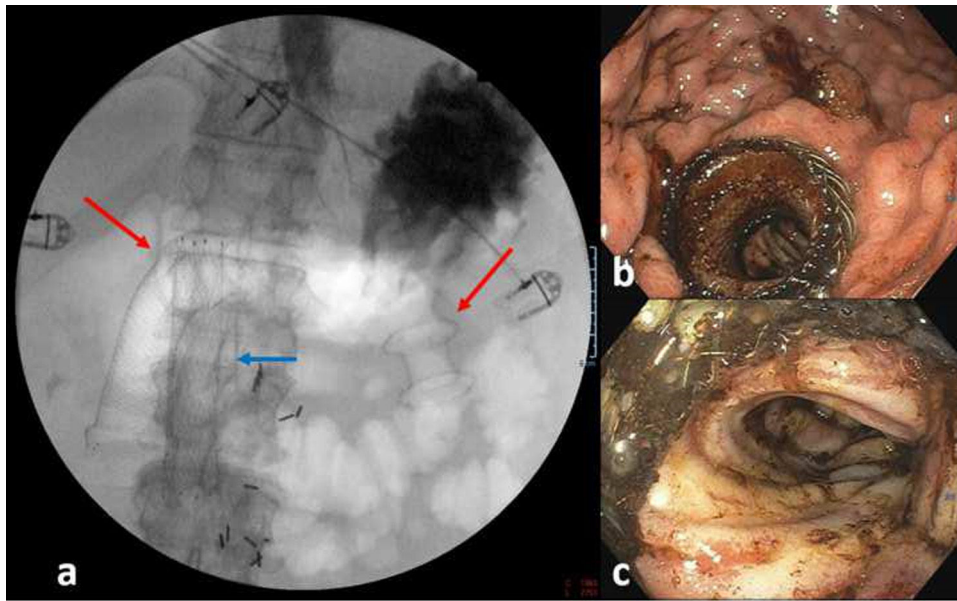


Figure 1 (a) Fluoroscopy during endoscopic ultrasound guided gastrojejunostomy (right red arrow) in a patient with previous uncovered duodenal self-expandable metal stent (left red arrow) and endovascular stent (blue arrow). (b) Endoscopic image of the lumen-apposing metal stent. (c) Ulcerative jejunitis.

Conflict of interest

None.

References

1. Pérez-Cuadrado-Robles E, Perrod G, Benosman H, Ragot E, Gallois C, Cellier C, et al. Endoscopic ultrasound-guided gastrojejunostomy as a rescue therapy for gastric outlet obstruction in a

- patient with multiple previous procedures. *Endoscopy*. 2020, <http://dx.doi.org/10.1055/a-1216-1330>. Epub ahead of print.
2. Sinagra E, Perricone G, Linea C, Montalbano L, Plano S, Simonetti RG, et al. An unusual presentation of Zollinger Ellison syndrome. *Case Rep Gastroenterol*. 2013;7:1–6.