



## IMAGE OF THE MONTH

## Endoscopic retrieval of large nails in the distal duodenum

### Recuperación endoscópica de grandes clavos en el duodeno distal

Liansong Ye <sup>◇</sup>, Wenjuan Yang <sup>◇</sup>, Jiang Du, Ke Liao, Bing Hu <sup>\*</sup>

Department of Gastroenterology, West China Hospital, Sichuan University, Chengdu, Sichuan, China



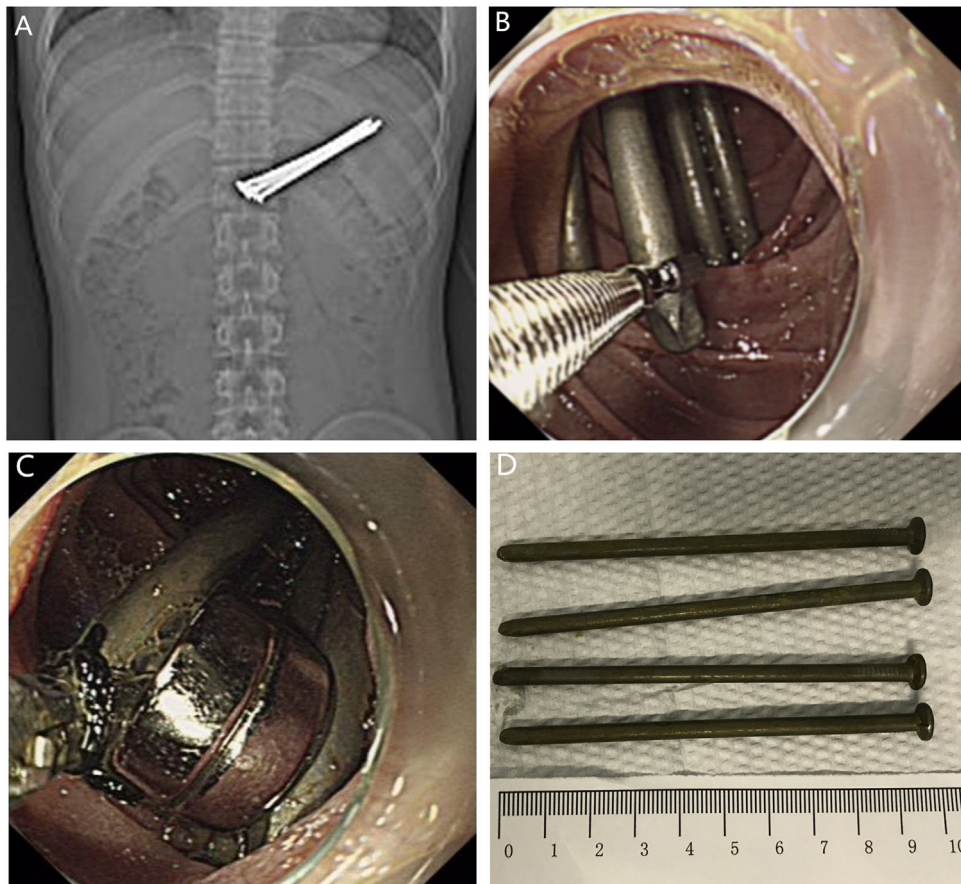
A 20-year-old man was admitted for ingestion of four nails two days earlier. He reported intermittent abdominal pain. Physical examination revealed no significant abnormalities. Abdominal imaging showed several long rods in the stomach, without signs of perforation (Fig. 1A). Upper endoscopy found that the nails had moved to distal duodenum. We used a grasping forceps to grip one of the nails, but duodenal wall was compressed by other two nails (Fig. 1B). Further attempts using the grasping forceps alone were abandoned. Considering the difficulty in trapping the movable nails together, we turned to use two powerful ring-shaped magnets, that were attached with strings and inserted using the forceps along with the re-introduction of the

endoscope. The retained nails and the inserted magnets were drawn together immediately. To avoid additional injury to the wall, we adjusted the binding point to the proximal ends of the nails by gentle rotation of the endoscope and repeated suction and inflation (Fig. 1C). Along with the direction of the lumen, we easily removed all the four nails as we withdrew the endoscope (Fig. 1D). There were no additional damages to digestive tract, and the patient was discharged subsequently. Our experience suggested that magnets can play a promising role in retrieval of magnetic objects when it is difficult or risky to operate using conventional devices like snare and grasping forceps.<sup>1–3</sup>

\* Corresponding author.

E-mail address: [hubingnj@163.com](mailto:hubingnj@163.com) (B. Hu).

◇ Co-first authors.



**Figure 1** (A) Abdominal imaging showed several long rods in the stomach. (B) We failed to remove the nails using a grasping forceps. (C) The inserted magnets and the retained nails were binded together for extraction. (D) The four nails were removed and were about 10 cm in length.

### Informed consent

Informed consent was obtained from the patient for the publication of his information and imaging.

### Conflicts of interest

All authors disclose no conflicts relevant to this article.

### Acknowledgement

We acknowledge the support from 1-3-5 project for disciplines of excellence – Clinical Research Incubation Project, West China Hospital, Sichuan University (20HXFH016).

### References

1. Birk M, Bauerfeind P, Deprez PH, Hafner M, Hartmann D, Hassan C, et al. Removal of foreign bodies in the upper gastrointestinal tract in adults: European Society of Gastrointestinal Endoscopy (ESGE) Clinical Guideline. *Endoscopy*. 2016;48:489–96.
2. Ikenberry SO, Jue TL, Anderson MA, Appalaneni V, Banerjee S, Ben-Menachem T, et al. Management of ingested foreign bodies and food impactions. *Gastrointest Endosc*. 2011;73:1085–91.
3. Ye LS, Zeng XH, Wang XL, Tang CJ, Du J, Zhang YH, et al. Endoscopic removal of two long iron rods impacted in the stomach. *Endoscopy*. 2019;51:E71–2.