



IMAGE OF THE MONTH

Endoscopic removal of intrahepatic biliary ascaris



Extracción endoscópica de ascaris de la bilis ascendente intrahepática

Chun-Cheng Wu, Jiang Du, Ke Liao, Bing Hu*

Department of Gastroenterology, West China Hospital, Sichuan University, China

A 42-year-old female presented with a 3-day history of severe abdominal pain radiating to back, nausea and vomiting, without chills and fever. Physical examination revealed right epigastric tenderness without guarding. Laboratory test results showed total bilirubin and conjugated bilirubin level increased. Magnetic resonance cholangiopancreatography (MRCP) showed a hypo intense strip in the common and right intrahepatic bile ducts (Fig. 1A, yellow arrow). Endoscopic retrograde cholangiography (ERCP) found the ascaris

duct (Fig. 1B, yellow arrow). We extracted the ascaris using a wire-guided basket without sphincterotomy (Fig. 1C, Video 1). The lady's pain was gone after the ascaris extraction and she was discharged two days later.

Biliary ascariasis is one of the most serious complications of gastrointestinal ascariasis. It could cause cholecystitis, cholangitis and acute pancreatitis.¹ The patients may present with unbearable abdominal pain due to the onset

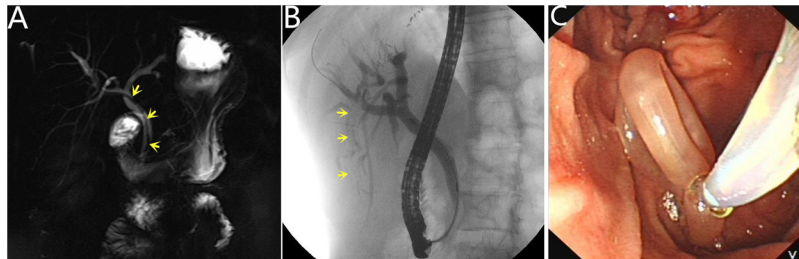


Figure 1 (A) Magnetic resonance cholangiography showed a hypo intense strip in the common and right intrahepatic bile ducts. (B) ERCP revealed a long strip filling defect in the right posterior intrahepatic bile duct. (C) The ascaris was extracted by a wire-guided basket.

had completely gone into right posterior intrahepatic bile

* Corresponding author.

E-mail address: hubingnj@163.com (B. Hu).

of biliary ascariasis. The pain will relieve when the ascaris enters or exits the biliary tract completely.² The ascaris in bile duct should be extracted and endoscopic intervention is an effective choice.³ ERCP is the main treatment for the ascaris in bile ducts. If the endoscopic treatment fails, the surgery is considered.

Financial disclosure

All authors have no financial relationships relevant to this article to disclose.

Conflict of interest

All authors have no conflicts of interest to disclose.

Appendix A. Supplementary data

Supplementary data associated with this article can be found, in the online version, at [doi:10.1016/j.gastrohep.2020.11.023](https://doi.org/10.1016/j.gastrohep.2020.11.023).

References

1. Khuroo MS, Rather AA, Khuroo NS, Khuroo MS. Hepatobiliary and pancreatic ascariasis. *World J Gastroenterol.* 2016;22:7507–17.
2. Shah OJ, Zargar SA, Robbani I. Biliary ascariasis: a review. *World J Surg.* 2006;30:1500–6.
3. Bektas M, Dokmeci A, Cinar K, Halici I, Oztas E, Karayalcin S, et al. Endoscopic management of biliary parasitic diseases. *Dig Dis Sci.* 2010;55:1472–8.