



## CLINICAL GUIDE

## Management of liver and gastrointestinal toxicity induced by immune checkpoint inhibitors: Position statement of the AEEH–AEG–SEPD–SEOM–GETECCU<sup>☆</sup>



Mar Riveiro-Barciela<sup>a,b,c,\*</sup>, Sabela Carballal<sup>b,d,e</sup>, Álvaro Díaz-González<sup>f</sup>,  
 Míriam Mañosa<sup>b,g</sup>, Javier Gallego-Plazas<sup>h</sup>, Joaquín Cubiella<sup>b,i</sup>,  
 Paula Jiménez-Fonseca<sup>j</sup>, María Varela<sup>k</sup>, Luis Menchén<sup>l,m</sup>, Bruno Sangro<sup>b,n</sup>,  
 Ana Fernández-Montes<sup>o</sup>, Francisco Mesonero<sup>p,q</sup>,  
 Miguel Ángel Rodríguez-Gandía<sup>p,r</sup>, Fernando Rivera<sup>s</sup>, María-Carlota Londoño<sup>b,e,t</sup>

<sup>a</sup> Liver Unit, Internal Medicine Department, Hospital Universitari Vall d'Hebron, Vall d'Hebron Barcelona Hospital Campus, Barcelona, Spain

<sup>b</sup> Centro de Investigación Biomédica en Red de Enfermedades Hepáticas y Digestivas (CIBERehd), Instituto de Salud Carlos III, Madrid, Spain

<sup>c</sup> Universitat Autònoma de Barcelona (UAB), Department of Medicine, Spain

<sup>d</sup> Gastroenterology Department, Hospital Clínic de Barcelona, Institut d'Investigacions Biomèdiques August Pi i Sunyer (IDIBAPS), Spain

<sup>e</sup> Universitat de Barcelona, Spain

<sup>f</sup> Gastroenterology Department, Grupo de Investigación Clínica y Traslacional en Enfermedades Digestivas, Instituto de Investigación Valdecilla (IDIVAL), Hospital Universitario Marqués de Valdecilla, Santander, Spain

<sup>g</sup> Gastroenterology Department, Hospital Universitari Germans Trias i Pujol, Badalona, Spain

<sup>h</sup> Medical Oncology Department, Hospital General Universitario de Elche, Spain

<sup>i</sup> Gastroenterology Department, Hospital Universitario de Ourense, Grupo de Investigación en Oncología Digestiva-Ourense, Spain

<sup>j</sup> Medical Oncology Department, Hospital Universitario Central de Asturias, ISPA, Oviedo, Spain

<sup>k</sup> Gastroenterology Department, Hospital Universitario Central de Asturias, IUOPA, ISPA, FINBA, University of Oviedo, Oviedo, Spain

**Abbreviations:** AE, adverse event; ALD, alcoholic liver disease; ALT, alanine aminotransferase; ALP, alkaline phosphatase; anti-CTLA-4, anti-cytotoxic T lymphocyte antigen 4; ANA, anti-nuclear antibodies; anti-PD-1, anti-programmed cell death 1; anti-PD-L1, anti-programmed death ligand 1; ASMA, anti-smooth muscle antibodies; AST, aspartate aminotransferase; AIH, autoimmune hepatitis; BTC, biliary tract cancer; CIOMS/RUCAM, council for international organizations of medical sciences/Roussel Uclaf causality assessment methods; CMV, cytomegalovirus; CS, corticosteroids; CT, computerized tomography; CTCAE, common terminology criteria for adverse events; DILI, drug-induced liver injury; EBV, Epstein–Barr virus; FAERS, food and drug administration adverse event reporting system; GI, gastrointestinal; GGT, gamma-glutamyl transpeptidase; GRADE, grading of recommendations assessment development and evaluation; HAV, hepatitis A virus; HBV, hepatitis B virus; HCV, hepatitis C virus; HE, hepatic encephalopathy; HEV, hepatitis E virus; HCC, hepatocellular carcinoma; HSV, herpes simplex virus; HHV-6, human herpes virus 6; HHV-8, human herpes virus; HR, hazard ratio; IBD, inflammatory bowel disease; ICI, immune-checkpoint inhibitor; IFX, infliximab; IM, immuno-mediated; irAE, immune-related adverse event; IgG, immunoglobulin G; INR, international normalized ratio; mAb, monoclonal antibody; MMF, mycophenolate mofetil; MR, magnetic resonance; MRCP, magnetic resonance cholangiopancreatography; NA, not available; NSAIDs, non-steroidal anti-inflammatory drug; OR, odds ratio; OS, overall survival; PPI, proton-pump inhibitor; PS, performance status; RCT, randomized controlled trial; RR, risk ratio; TB, total bilirubin; TKI, tyrosine kinase inhibitors; UDCA, ursodeoxycholic acid; ULN, upper limit of normal.

<sup>☆</sup> Este artículo se publica conjuntamente, en el marco del correspondiente acuerdo de publicación y derechos de autor, en Revista Española de Enfermedades Digestivas.

\* Corresponding author.

E-mail address: [mar.riveiro@gmail.com](mailto:mar.riveiro@gmail.com) (M. Riveiro-Barciela).

<https://doi.org/10.1016/j.gastrohep.2023.10.009>

0210-5705/© 2024 The Author(s). Published by Elsevier España S.L.U. and by Sociedad Española de Patología Digestiva. This is an open access article under the CC BY-NC-ND license (<http://creativecommons.org/licenses/by-nc-nd/4.0/>).

<sup>l</sup> Servicio de Aparato Digestivo – CEIMI, Instituto de Investigación Sanitaria Gregorio, Marañón, Spain

<sup>m</sup> Departamento de Medicina, Universidad Complutense, Madrid, Spain

<sup>n</sup> Liver Unit, Cancer Center Clínica Universidad de Navarra, Pamplona-Madrid, Spain

<sup>o</sup> Medical Oncology Department, Complejo Hospitalario Universitario de Ourense, Ourense, Spain

<sup>p</sup> Gastroenterology and Hepatology Department, Hospital Universitario Ramón y Cajal, Madrid, Spain

<sup>q</sup> Universidad de Alcalá de Henares, Spain

<sup>r</sup> Instituto Ramón y Cajal de Investigación Sanitaria (IRyCIS), Madrid, Spain

<sup>s</sup> Medical Oncology Department, Hospital Universitario Marqués de Valdecilla, IDIVAL, Santander, Spain

<sup>t</sup> Liver Unit, Hospital Clínic Barcelona, Fundació de Recerca Clínic Barcelona-Institut d'Investigacions Biomèdiques August Pi i Sunyer, European Reference Network on Hepatological Diseases (ERN RARE-LIVER), Spain

Available online 15 January 2024

## KEYWORDS

Immunotherapy;  
Immune checkpoint inhibitors;  
Toxicity;  
Hepatitis;  
Colitis;  
Drug-induced liver injury;  
Immune-related adverse events;  
Diarrhea

## Abstract

The development of the immune checkpoint inhibitors (ICI) is one of the most remarkable achievements in cancer therapy in recent years. However, their exponential use has led to an increase in immune-related adverse events (irAEs). Gastrointestinal and liver events encompass hepatitis, colitis and upper digestive tract symptoms accounting for the most common irAEs, with incidence rates varying from 2% to 40%, the latter in patients undergoing combined ICIs therapy. Based on the current scientific evidence derived from both randomized clinical trials and real-world studies, this statement document provides recommendations on the diagnosis, treatment and prognosis of the gastrointestinal and hepatic ICI-induced adverse events.

© 2024 The Author(s). Published by Elsevier España S.L.U. and by Sociedad Española de Patología Digestiva. This is an open access article under the CC BY-NC-ND license (<http://creativecommons.org/licenses/by-nc-nd/4.0/>).

## PALABRAS CLAVE

Inmunoterapia;  
Inhibidores de checkpoint inmunológicos;  
Toxicidad;  
Hepatitis;  
Colitis;  
Hepatotoxicidad;  
Efectos adversos inmunomediados;  
Diarrea

## Manejo de las toxicidades digestivas secundarias al tratamiento con inhibidores de *checkpoint*: documento de posicionamiento de la AEEH-AEG-SEPD-SEOM-GETECCU

**Resumen** El descubrimiento de los inhibidores de checkpoint inmunológicos (ICI) es uno de los logros más importantes en los últimos años en Oncología. Sin embargo, su uso en aumento ha conllevado a un incremento de los efectos adversos inmunomediados (irAEs). Los eventos hepáticos y gastrointestinales incluyen la hepatitis, colitis y síntomas de tracto digestivo superior, que son de los irAEs más frecuentes, con incidencias entre el 2 y 40%, ésta última en paciente tratados con combo de ICI. Basados en la evidencia científica tanto de ensayo clínicos randomizados como de estudio de vida real, este documento de consenso aporta recomendaciones sobre el diagnóstico, tratamiento y pronóstico de los efectos adversos hepáticos y gastrointestinales asociados con la inmunoterapia.

© 2024 El Autor(s). Publicado por Elsevier España S.L.U. y by Sociedad Española de Patología Digestiva. Este es un artículo Open Access bajo la licencia CC BY-NC-ND (<http://creativecommons.org/licenses/by-nc-nd/4.0/>).

## Introduction

The development of immune-checkpoint inhibitors (ICIs), including anti-cytotoxic T lymphocyte antigen 4 (anti-CTLA-4), anti-programmed cell death 1 (anti-PD-1) and anti-programmed death ligand 1 (anti-PD-L1) antibodies has marked a significant milestone in cancer therapy over the past decade. As ICIs indication continue to expand, so does the appearance of specific immune-related adverse events (irAEs), which can sometimes be severe and life-threatening.<sup>1</sup>

The indications and consequent use of ICIs are constantly growing, either in monotherapy or in combination with chemotherapy or other ICIs. They have approved indications

in solid tumors such as melanoma, small and non-small cell lung cancer, breast, colorectal and esophagogastric, liver, renal and bladder, and head and neck cancer, not only for advanced stages but also in certain scenarios of localized disease. [Table 1](#) includes the mechanism of action and names of the ICIs with more advanced clinical development.

The introduction of ICIs has improved the outcome of many different cancers, with the significant improvement in long-term overall survival (OS) often achieved through these therapies being especially important. However, ICIs are not universally effective, making it crucial to explore new treatment approaches and identify predictive factors (for both efficacy and toxicity) to select the best treatment option for each patient.

**Table 1** Name and mechanism of action of immune checkpoint inhibitors with more advanced clinical development and approved indications (EMA).

Mechanism of action	Drug	Approved indications (EMA)
Anti-PD-1	Camrelizumab	–
	Cemiplimab	Cutaneous squamous cell carcinoma, basal cell carcinoma, non-small cell lung cancer, cervical cancer
	Dostarlimab	MSI-H/dMMR endometrial cancer
	Nivolumab	Non-small cell lung cancer, melanoma, renal cell carcinoma, malignant pleural mesothelioma, squamous cell cancer of the head and neck, urothelial carcinoma, MSI-H/dMMR colorectal cancer, oesophageal squamous cell carcinoma, gastric or oesophageal adenocarcinoma
	Pembrolizumab	Non-small cell lung cancer, melanoma, renal cell carcinoma, squamous cell cancer of the head and neck, urothelial carcinoma, MSI-H/dMMR colorectal, endometrial, gastric, biliary, small intestine cancer, oesophageal carcinoma, triple-negative breast cancer, endometrial carcinoma, cervical cancer
	Serplulimab	–
	Sintilimab	–
Anti-PD-L1	Atezolizumab	Non-small cell lung cancer, small cell lung cancer, urothelial carcinoma, hepatocellular carcinoma, triple-negative breast cancer
	Avelumab	Merkel cell carcinoma, urothelial carcinoma, renal cell carcinoma
	Durvalumab	Non-small cell lung cancer, small cell lung cancer, biliary tract cancer, hepatocellular carcinoma
Anti-CTLA-4	Ipilimumab	Melanoma, non-small cell lung cancer, renal cell carcinoma, malignant pleural mesothelioma, oesophageal squamous cell carcinoma, MSI-H/dMMR colorectal cancer
	Tremelimumab	Hepatocellular carcinoma

MSI-H, high microsatellite instability; dMMR, mismatch repair deficient.

With the gradual inclusion of ICIs into the cancer treatment armamentarium, it is essential to be familiarized with the potential toxicities they may imply. Early recognition and adequate management of ICIs related toxicities are crucial not only to prevent therapy-related complications but also to ensure convenient treatments are not erroneously interrupted. This decision is even more important given the increasing likelihood of achieving long-term OS with the use of ICIs.

## Methods

This positioning document has been carried out through the collaboration of five Spanish scientific societies, comprising: the Spanish Association for the Study of the Liver (Asociación Española para el Estudio de Hígado; AEEH), the Spanish Association of Gastroenterology (Asociación Española de Gastroenterología; AEG); the Spanish Society of Digestive Pathology (Sociedad Española de Patología Digestiva; SEPD); the Spanish Society of Medical Oncology (Sociedad Española de Oncología Médica; SEOM) and the Spanish Working Group on Crohn's Disease and Ulcerative Colitis (Grupo Español de Trabajo en Enfermedad de Crohn y Colitis Ulcerosa; GETECCU).

The AEEH proposed the elaboration of this document (chair MCL) and contacted the rest of the societies to designate a coordinator for each one. Coordinators (MCL, SC, MM, AD, MRB) invited the listed authors to participate in the project development.

The coordinating team established two task force sub-groups (liver-group and gut-group), each with its own leader and divided the key topics among those task forces.

Key questions were discussed and approved by all group members. The process of developing the Guideline included telephone videoconferences and online discussions among the members from March 2021 to February 2023. Searches were performed in MEDLINE, Embase, and the Cochrane Library. Articles were selected through title and abstract screening followed by full-text screening. The results of the search were presented to all group members and statements were created by consensus. Evidence levels and recommendation strengths were assessed using the Grading of Recommendations Assessment, Development and Evaluation (GRADE) system.<sup>2</sup>

Once consensus was reached among all group members, the manuscript was reviewed by a member of the AEG Board (JC) and was sent for further comments to national societies and individual members for additional feedback. After this, it was submitted to "*Gastroenterología y Hepatología*" for publication. This Guideline was issued in 2023 and will be considered for update in 2028.

## Hepatitis induced by immune checkpoint inhibitors

### Epidemiology

ICI-induced hepatitis occurs in 3–20% of patients, generally within the first 4–9 weeks of therapy. In the first trials with nivolumab and pembrolizumab in monotherapy, the incidence of ICI-induced hepatitis ranged between 1% and

4%<sup>1</sup> and severe hepatitis was rare.<sup>3</sup> The most common manifestation was an isolated increase in transaminase levels (aspartate aminotransferase [AST] and alanine aminotransferase [ALT]), which usually normalized after treatment discontinuation, but increased alkaline phosphatase ([ALP] and gamma-glutamyl transpeptidase (GGT) levels have also been observed. Anti-CTLA-4 drugs used in monotherapy have been associated with a higher incidence of ICI-induced hepatitis ranging between 3% and 9% in a dose-dependent manner, with higher rates observed in patients receiving ipilimumab at 10 mg/kg vs. 3 mg/kg.<sup>4</sup> However, approximately 25% of patients treated with the combination of anti-PD-1 or anti-PD-L1 plus anti-CTLA-4 developed ICI-induced hepatitis. In addition, hepatitis was more frequent in patients treated with combinations of ICI with both chemotherapy and targeted therapy, suggesting that perhaps ICIs may sensitize the liver to other forms of drug-induced liver injury (DILI) or the opposite.<sup>5</sup> Real-world observational data in ICI-induced hepatotoxicity have emerged and the incidence appears to be comparable to rates reported in clinical trials. The incidence of ICI-induced hepatitis ranges between 1% and 4% in patients treated with monotherapy with anti-PD-1, between 4% and 9% in patients treated with anti-CTLA-4 in monotherapy, and around 18% in those receiving the combination of anti-PD-1 and anti-CTLA-4. In a French series published in 2018, only 3.5% of patients presented acute hepatitis  $\geq$  grade 3.<sup>6</sup>

There are two main concerns regarding assessment of the incidence and severity of ICI-related hepatotoxicity. First, hepatic irAEs are probably overrepresented in many reviews of liver toxicity.<sup>7-9</sup> A common limitation of these publications is the registry of liver enzyme abnormalities during and/or after the use of ICIs without a formal exclusion of other causes such as hepatic metastasis, thromboembolic disease, biliary compression, perfusion injury, opportunistic infections, or drug reactions. A single center retrospective study conducted in Toronto, included 450 patients treated with anti-PD-1, anti-PD-L1 or anti-CTLA-4 in phase I/II clinical trials between August 2012 and December 2018.<sup>10</sup> Liver enzyme elevations  $\geq$  grade 2 occurred in 120 patients, but this could be attributed to ICI-induced hepatotoxicity in only 17 cases (3.6% of total cohort). The main manifestations of ICI-induced hepatotoxicity were higher ALT values and ALT/AST ratio compared with other causes of liver enzyme abnormalities, such as disease progression or other causes of DILI. In comparison with those treated with ICIs who do not develop liver injury, patients with ICI-induced hepatotoxicity were younger (47.9 years vs. 57 years,  $p=0.006$ ), had previous exposure to ICI (41.2% vs. 15.9%,  $p=0.014$ ), and had experienced irAE affecting other organs (76.5% of patients with ICI-induced hepatotoxicity vs. 21.1% without,  $p<0.001$ ). As described previously, ICI-induced hepatotoxicity was more common in patients receiving an anti-CTLA-4-based treatment (13.9%) compared to those treated with anti-PD-1/PD-L1 (2.8%).<sup>10</sup>

The second issue is the lack of uniformity of the registries regarding liver irAEs, as shown in the assessment of 32,441 reports of ICI-induced irAEs based on the retrospective pharmacovigilance study of the Food and Drug Administration Adverse Event Reporting System (FAERS) database, from January 2004 to December 2019, which includes more than 50 terms to describe liver events.<sup>11</sup>

More than 80% of patients with hepatocellular carcinoma (HCC) have an underlying chronic liver disease, which is frequently related to chronic infections such as hepatitis B (HBV) or C virus (HCV), alcohol consumption, or fatty liver disease associated with metabolic syndrome. Most of these patients have abnormal baseline levels of AST and ALT and, therefore, the application of the Common Terminology Criteria for Adverse Events (CTCAE) grading system should be interpreted with caution.<sup>12</sup> According to different reports, 22% of patients with HBV/HCV have some grade of liver enzyme abnormalities after ICI therapy and 10.8% present a grade  $\geq 3$ .<sup>13</sup> In patients treated for HCC the incidence of liver toxicity varies depending on the type of drug and the dose received (Supplementary Table 1).<sup>14-19</sup> According to a recent meta-analysis that included a total of 117 clinical trials with cancer patients treated with anti-PD-1 or anti-PD-L1, the all-grade incidence of immune-related hepatitis was 2.02 (95% CI 1.05-3.88) in patients with primary liver cancer and 1.20 (95% CI 0.87-1.66) for those with other solid tumors. The incidence of ICI-induced hepatitis grade  $\geq 3$  was 1.27 and 0.96, respectively.<sup>9</sup> Biliary tract cancer (BTC) has emerged as another liver cancer that could benefit from ICI treatment.<sup>20,21</sup> As in patients with HCC, patients with BTC frequently present with abnormal liver tests complicating the diagnosis of ICI-induced hepatitis. Preliminary data of anti-PD-1 treatment alone or in combination with gemcitabine did not show a significant increase in the rate of liver toxicity between those treated with durvalumab alone vs combined with gemcitabine.<sup>22</sup> Similar safety results on pembrolizumab (anti-PD-1) alone vs combined with gemcitabine and cisplatin has been recently published.<sup>23</sup> Yet, in a study combining durvalumab (anti-PD-1) and tremelimumab (anti-CTLA-4), one patient died of DILI-related liver failure.<sup>24</sup>

#### Statement 1

Some degree of ICI-induced hepatitis has been observed during ICI treatment.

**Quality of evidence: high.**

#### Statement 2

ICI-induced hepatitis is more frequently observed in patients receiving anti-CTLA-4 agents or dual CTLA-4 and PD-1/PD-L1 blockade than in those on PD-1/PD-L1 inhibitors.

**Quality of evidence: high.**

#### Diagnosis

**Definition of ICI-induced liver toxicity.** The diagnosis of ICI-induced hepatitis is challenging, especially because there are no clear and specific diagnostic criteria.

According to the EASL (European Association for the Study of the Liver) clinical practice guidelines the definition of drug-induced liver injury (DILI) includes<sup>25</sup>: (1) the exclusion of other etiology of liver test abnormality and (2) one of the following criteria, (i)  $\geq 5 \times$  upper limit of normal (ULN) elevation in ALT, (ii)  $\geq 2 \times$  ULN elevation in ALP or (iii)  $\geq 3 \times$  ULN elevation in ALT with a simultaneous elevation of total bilirubin exceeding  $2 \times$  ULN. In patients with abnormal liver tests prior to starting treatment with the drug involved, ULN is



**Table 2** Grades of hepatotoxicity according to CTCAE by the National Cancer Institute.<sup>12</sup>

	Grade				
	1	2	3	4	5
ALP	>ULN – 2.5 × ULN	>2.5–5 × ULN	>5–20 × ULN	>20 × ULN	–
GGT	>ULN – 2.5 × ULN	>2.5–5 × ULN	>5–20 × ULN	>20 × ULN	–
Bilirubin	>ULN – 1.5 × ULN	>1.5–3 × ULN	>3–10 × ULN	>10 × ULN	–
AST	>ULN – 3 × ULN	>3–5 × ULN	>5–20 × ULN	>20 × ULN	–
ALT	>ULN – 3 × ULN	>3–5 × ULN	>5–20 × ULN	>20 × ULN	–
Liver failure	–	–	Asterixis, subclinical, limitation of daily activities	Moderate to severe encephalopathy, need for urgent treatment	Death
Portal hypertension	–	Decrease portal vein flow	Inverted portal vein flow, esophageal varices, ascites	Life-threatening consequences, need for urgent treatment	Death

ALP, alkaline phosphatase; GGT, gamma-glutamyl transpeptidase; AST, aspartate aminotransferase; ALT, alanine aminotransferase; ULN, upper limit of normal.

replaced by the mean baseline values obtained prior to DILI onset and increases should be proportionate to this modified baseline.

However, these criteria have not been validated in patients with ICI-induced liver toxicity and milder elevations in transaminases oblige us to closely monitor liver tests and even withhold ICI administration (see below).

The lack of definite diagnostic criteria and the variable setting in which these drugs are used make both diagnosis and differential diagnosis challenging, and thus, a structured evaluation of suspected ICI-induced hepatitis is compulsory. This is especially true for patients with HCC or BTC in whom the tumoral burden, already involving the liver, makes the differential diagnosis of liver test abnormalities detected during ICI treatment difficult. Another important issue is the temporal relationship between the immunotherapy administration and the onset of liver injury, though cases of ICI-induced hepatitis have been described just after the first cycle of immunotherapy until several months after its discontinuation.<sup>26,27</sup>

**Severity of hepatitis.** Establishing the severity of liver damage is a necessary step after the diagnosis of hepatitis of any etiology. In the specific case of ICI-induced hepatic toxicity, the CTCAE grading system (Table 2)<sup>6,12,28</sup> is the most accepted. However, it has several limitations: (1) it quantifies the degree of elevation of each liver test separately but there is not a specific scale for hepatitis, and (2) it considers high degree transaminase elevations without a concomitant increase in bilirubin levels as grade 4 hepatotoxicity. This is important because isolated elevation of transaminases is merely an indicator of hepatocellular damage and not liver dysfunction, (3) the International Normalized Ratio (INR), an important parameter to assess liver function and determine the need for treatment, has not been routinely included in oncology guidelines. Therefore, the CTCAE is probably less accurate than Hy's law for reflecting serious hepatotoxicity.<sup>25</sup> In this sense, it would be recommendable to incorporate other grading scales (including those from the U.S. Drug Induced Liver

Injury Network and the International DILI Expert Working Group or DILI severity index) (Table 3) in the evaluation of patients with suspected ICI-induced liver injury.

**Association of causality.** The diagnosis of DILI is generally made by a combination of clinical suspicion in the appropriate context, and the ruling out of other causes of liver test abnormalities. Nevertheless, several causality scales can aid in the diagnosis and are useful to establish a structured diagnosis, which is particularly appropriate in academic and research contexts. The most widely used scale is the Council for International Organizations of Medical Sciences/Roussel Uclaf Causality Assessment Method (CIOMS/RUCAM),<sup>29</sup> which has been proposed to determine the causal relationship between the drug responsible and liver damage. It entails a scoring system that categorizes suspicion into “definite or highly probable” (score > 8), “probable” (score 6–8), “possible” (score 3–5), “unlikely” (score 1–2), and “excluded” (score ≤ 0). The applicability of the CIOMS/RUCAM scale has been hindered by its subjectivity and poor reliability and, therefore, it has recently been updated and computerized into a revised electronic causality assessment method (RECAM) scale using data from the Drug-Induced Liver Injury Network and the Spanish DILI network. The RECAM scale has shown to have higher agreement with expert opinion and higher sensitivity for detecting extreme categories.<sup>30</sup> Of course, these scales need to be validated for ICI-induced liver toxicity.

**Exclusion of other etiologies.**

- Tumor progression

An abdominal ultrasound is indicated to rule-out biliary and/or vascular pathology or hepatic tumoral infiltration. If necessary, an abdominal computerized tomography (CT) scan, liver magnetic resonance (MR) imaging, or magnetic resonance cholangiography should be performed.<sup>31</sup> The performance of an imaging study is mandatory since development of liver metastasis has been described as the

**Table 3** Drug-induced liver injury severity scales.

U.S. drug-induced liver injury network		International DILI expert working group	
1 Mild	Elevated ALT and/ALP but TB < 2.5 mg/dL and INR < 1.5	1 Mild	ALT $\geq$ 5 $\times$ ULN or ALP $\geq$ 2 $\times$ ULN and TB < 2 $\times$ ULN
2 Moderate	Elevated ALT and/ALP and TB $\geq$ 2.5 mg/dL or INR $\geq$ 1.5	2 Moderate	ALT $\geq$ 3 $\times$ ULN or ALP $\geq$ 2 $\times$ ULN and TB $\geq$ 2 $\times$ ULN, or symptomatic hepatitis
3 Moderate-Severe	Elevated ALT, ALP, TB, and/or INR and hospitalization or prolonged hospitalization due to DILI		
4 Severe	Elevated ALT and/or ALP and TB $\geq$ 2.5 mg/dL and at least one of the following: - Liver failure (INR $\geq$ 1.5, ascites or HE) - Organ failure due to DILI	3 Severe	ALT $\geq$ 3 $\times$ ULN or ALP $\geq$ 2 $\times$ ULN and TB $\geq$ 2 $\times$ ULN, and at least one of the following criteria: - INR $\geq$ 1.5 - Ascites and/or HE, disease duration < 26 weeks, and absence of cirrhosis - Organ failure due to DILI
5 Fatal	Death or LT due to DILI	4 Fatal	Death or LT due to DILI

DILI, drug-induced liver injury; ALT, alanine aminotransferase; ALP, alkaline phosphatase; TB, total bilirubin; HE, hepatic encephalopathy; ULN, upper limit of normality.

most common cause of transaminases increase in patients undergoing ICIs.<sup>32</sup>

- Liver toxicity induced by chemotherapy and other concomitant medications

Patients with cancer, and especially those on ICIs, are frequently receiving multiple concomitant medications (and occasionally herbal products) and, therefore it is mandatory to check for potential drug- or herbal-induced liver injury. The risk could be exacerbated by the presence of steatosis or advanced age that could affect the clearance of some drugs.<sup>16</sup>

Hepatic toxicity secondary to chemotherapy is infrequent. The mechanisms of liver injury are those described for other drugs: (1) idiosyncratic immunological or metabolic reactions, that are not predictable or dose-dependent, and (2) direct liver damage or exacerbation of a pre-existing liver disease. However, chemotherapy can also induce hepatocellular necrosis, hepatic steatosis, hepatic fibrosis, or sinusoidal obstruction.<sup>33</sup> The best-known is sinusoidal damage that ranges from sinusoidal dilatation to sinusoidal obstruction syndrome (SOS) causing non-thrombotic obliterations of small intrahepatic veins by fibrin.<sup>34</sup> Among the drugs currently used with immunotherapy, oxaliplatin and irinotecan are the most common, and can also be associated with SOS in around 20% of patients.<sup>29,30</sup> SOS has also been reported with the use of immunotherapy.<sup>35,36</sup>

Lastly, liver-directed radiotherapy may cause hepatotoxicity per se, but this can be exacerbated by the use of concomitant chemotherapy.

- Viral hepatitis

Screening for the following viral infections is recommended, including:

- Hepatitis A, B, C, and E viruses (HAV, HBV, HCV, and HEV): IgM anti-HAV, IgM anti-HEV, anti-HBc, anti-HCV, HEV-RNA, HCV-RNA.
  - In case of previous positive anti-HBc: HBV-DNA.
- Cytomegalovirus (CMV)
  - If IgM is positive, order CMV-RNA.
- In selected patients (severe immunosuppression or epidemiological history)
  - Epstein–Barr virus (EBV)
  - Herpes simplex virus (HSV)
  - Human herpes virus 6 and 8 (HHV 6 and HHV8)

Screening for viral hepatitis encompassing HBsAg, anti-HBc and anti-HCV is highly recommended prior to beginning ICIs.<sup>37</sup> This recommendation is supported by the risk of HBV reactivation associated with ICIs therapy,<sup>38</sup> and the increased risk of HCV infection in the oncology setting compared to the general population.<sup>39</sup>

- Alcohol-related liver disease

Alcoholic liver disease (ALD) is the most prevalent cause of liver disease and cirrhosis in Europe, with a prevalence in Spain of 2%. The possibility of alcohol-associated liver disease should be suspected in women with alcohol consumption of >20 g per day and in men consuming >40 g per day.<sup>40</sup> This is especially relevant in patients with acute severe alcohol consumption, with or without prior known liver disease. The diagnosis of cancer may trigger the abuse of toxic substances and/or alcohol in predisposed individuals.

- Screening for autoimmune diseases

Autoimmune hepatitis (AIH) is relatively uncommon, with a prevalence of 16–18 cases/100,000 inhabitants in Europe,<sup>41</sup> but it must be ruled out in the presence of an increase in transaminase levels, particularly in individu-

als with prior autoimmune diseases. It is recommended to determine:

- Anti-nuclear antibodies (ANA).
- Anti-smooth muscle antibodies (ASMA).
- Immunoglobulin G (IgG) levels.

However, positivity for these autoantibodies or elevated IgG are not diagnostic of autoimmune liver disease. AIH is an exclusion diagnosis and requires the performance of a liver biopsy. Differentiation between AIH and ICI-induced hepatitis can be difficult as there are no specific diagnostic criteria. The study of the immunophenotype of infiltrating immune cells could be helpful but more data are needed to confirm preliminary results.<sup>42</sup>

**Liver biopsy.** In general, a liver biopsy is not mandatory to diagnose ICI-induced liver damage because as in other DILI the clinical diagnosis is appropriate. In addition, no unequivocal histological findings have been established for this entity.<sup>17</sup> However, the panel suggest performing a liver biopsy in patients with  $\geq$  grade 3 hepatitis not improving after ICI withdrawal to evaluate the severity of inflammation. Despite the lack of pathognomonic features, several histological findings have been associated with the use of anti-CTLA-4 or anti-PD-1 treatments. Patients with ipilimumab-related hepatotoxicity may show granulomatous hepatitis with fibrin deposition and those treated with anti-PD-1 may present lobular hepatitis with periportal activity and centrilobular inflammation.<sup>1</sup> Interestingly, the inflammatory infiltrate is mainly composed of CD8+ T cells which is completely different from other liver diseases including AIH in which the portal infiltrate predominately contains CD4+ T and B cells.<sup>42</sup>

#### Recommendation 1

The presence of HBsAg, and anti-HBc and anti-HCV antibodies must be assessed before starting ICI treatment.

**Quality of evidence: moderate**

**Strength of the recommendation: strong in favor.**

#### Recommendation 2

Patients with anti-HCV antibodies must be tested for HCV-RNA and those with anti-HBc antibodies must be tested for HBV-DNA.

**Quality of evidence: moderate.**

**Strength of the recommendation: strong in favor.**

#### Recommendation 3

The diagnosis of ICI-induced hepatitis requires the exclusion of other causes of liver test abnormalities, especially the development or progression of tumoral liver involvement.

**Quality of evidence: high.**

**Strength of the recommendation: strong in favor.**

#### Recommendation 4

If ICI-induced hepatitis is suspected, it is recommended to perform the following tests: liver ultrasound (and CT or MR if needed), IgM anti-HAV, IgM anti-HEV, anti-HBc, anti-HCV, HEV-RNA, HCV-RNA, IgM anti-CMV, IgM anti-EBV, ANA,

ASMA, IgG levels. It is also important to check the potential hepatotoxicity of concomitant medications, and alcohol or substance abuse.

**Quality of evidence: moderate.**

**Strength of the recommendation: strong in favor.**

#### Recommendation 5

The CIOMS/RUCAM scale may help establish the causality of ICI as the hepatotoxic agent.

**Quality of evidence: low.**

**Strength of the recommendation: weak in favor.**

#### Recommendation 6

The severity of an elevation of liver tests should be evaluated with the CTCAE in combination with the U.S Drug Induced Liver Injury Network or the DILI severity index.

**Quality of evidence: low.**

**Strength of the recommendation: strong in favor.**

#### Recommendation 7

In case of  $\geq$  grade 3 hepatitis not improving after ICI withdrawal, the panel suggest performing a liver biopsy to rule out other causes of liver injury and to determine the severity of liver inflammation.

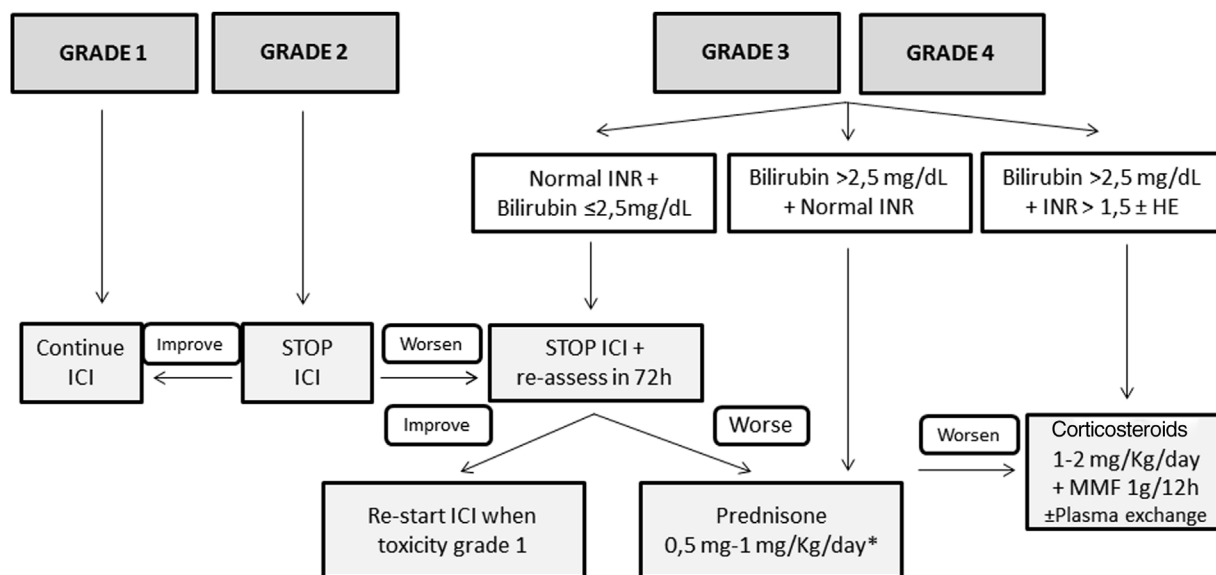
**Quality of evidence: low.**

**Strength of the recommendation: weak in favor.**

### Treatment

Fig. 1 shows the management of ICI-induced hepatitis according to the severity. There is wide consensus recommending bi-weekly monitoring without the need for withholding ICI treatment in patients presenting grade 1 hepatotoxicity.<sup>5,26-28</sup> However, the paucity of available evidence in terms of management is the reason for the varying recommendations among different guidelines in patients with ICI-induced hepatitis grade 2 or greater. While some position documents and guidelines recommend close monitoring without treatment,<sup>3,28</sup> others recommend starting immunosuppressive treatment upon the diagnosis of grade 2 hepatitis.<sup>5,26</sup> However, there is increasing information regarding favorable evolutions in untreated patients.<sup>3,43</sup> Therefore, in patients with grade 2 hepatitis without liver dysfunction, it is reasonable not to start immunosuppression and weekly monitoring with liver tests. In this specific scenario, Sangro B et al.<sup>28</sup> proposed continuing ICI treatment in patients with stable bilirubin values, withholding ICI only in those with rising bilirubin levels with respect to baseline, but less than 3 times the ULN. In patients with an adequate evolution, the resumption of ICI may be considered. However, corticosteroids (CS) must be initiated in patients in whom liver tests steadily worsen or do not improve.

Patients presenting grade 3 or greater represent a challenging scenario. Until recently, most of these patients were invariably treated with different immunosuppressive schemes, all of which were based on corticosteroids (CS).<sup>6,43-54</sup> Most of these patients presented a favorable evolution, with only a minority requiring additional immunosuppression. It is of note that some retrospective studies



**Figure 1** Proposed management of immune checkpoint inhibitors-induced hepatitis according to the CTCAE grading. \* Assess the performance of liver biopsy, mainly in case of alternative diagnosis (other drugs, cancer infiltration, etc.). If bilirubin levels  $>2.5$  mg/dL, the beginning of steroids should NOT be delayed more than 48 h. HE, hepatic encephalopathy; ICI, immune checkpoint inhibitor; MMF, mycophenolate mofetil.

evaluating grade 3 or 4 ICI-induced hepatitis reported a high rate of complete hepatitis resolution in untreated patients. However, many of these studies lack an in-depth evaluation of either the potential risk of selection bias or differences among treated and untreated groups, and thus, the results must be interpreted with caution. In a large retrospective cohort of patients, Miller ED et al.,<sup>54</sup> did not identify relevant differences between grade  $\geq 3$  treated or untreated patients, in the baseline characteristics, evolution, or the rate of ICI rechallenge. Thus, considering the information available, as well as the proposals of different experts, CS may not always be warranted in grade  $\geq 3$  hepatitis.<sup>3,28,44</sup> After ruling out other potential causes of hypertransaminasemia, – withholding ICI and liver test monitoring each 2–3 days is advisable in stable patients with preserved liver function – bilirubin  $<2.5$  mg/dL and INR  $<1.5$ . If liver tests worsen or do not present a clear decline after 7 days in this subgroup of patients, CS induction therapy is recommended. The performance of a liver biopsy may be helpful for selection of patients who would benefit from CS initiation based on the severity of necroinflammation.<sup>55</sup> In patients presenting bilirubin levels  $\geq 2.5$  and/or an INR  $\geq 1.5$  at diagnosis, ICI should be withheld, and immunosuppressive treatment must be promptly started.

If treatment is finally indicated, the recommended drug is predniso(lo)ne – or equivalent – with doses ranging from 0.5 to 1 mg/kg/d. Nevertheless, there is growing evidence suggesting that doses of prednisone greater than 60 mg/d may not add any additional benefits.<sup>46</sup> In the absence of response, either because of worsening or stabilization, the panel recommends: (1) hospital admission, (2) rule-out of other tumoral disease progression and other etiologies of liver test abnormalities, (3) individual assessment of the need for liver biopsy, (4) consider the administration of intravenous CS increasing the dose to 2 mg/kg/d. Additional

immunosuppressive drugs, including mycophenolate mofetil (MMF) 1g every 12 h and/or tacrolimus, can be used, but should be retained for refractory cases. In the setting of persistent lack of response or the development of acute liver injury, anti-thymocyte globulin therapy and/or plasma exchange may be an option, but further information is needed to establish any formal recommendation.<sup>56,57</sup> Budesonide, a CS with low systemic bioavailability because of the 90% liver first pass clearance, has not been tested as induction therapy in this scenario, and therefore no recommendation regarding its use can be made.<sup>58,59</sup> The use of anti-tumor necrosis factor (TNF) therapies is not recommended due to the potential risk of ICI-induced hepatitis reported with these drugs.<sup>60</sup>

Once improvement is documented, CS tapering can be initiated, reducing predniso(lo)ne by 10 mg per week, usually with tapering over 4–8 weeks. Although the time to hepatitis resolution varies widely across series, ranging from 4 days to 4 months,<sup>6,43–54</sup> recovery is usually observed within 5–9 weeks.<sup>44</sup> Strikingly, two studies have described that the time to recovery is slightly shorter in patients without CS treatment than in those with.<sup>43,54</sup>

#### Recommendation 8

In case of grade 1 hepatitis, ICI must be continued, and liver tests should be monitored bi-weekly.

**Quality of evidence: high.**

**Strength of the recommendation: strong in favor.**

#### Recommendation 9

In patients with grade 2 ICI-induced hepatitis, the panel recommends withholding ICI treatment and monitoring liver tests weekly. In case of improvement continue as in grade 1 hepatitis. In case of worsening, perform liver tests and re-



**Table 4** Series of cases of retreatment with immune-checkpoint inhibitors after an episode of severe immune-related hepatitis.

Author, year	Number of retreated patients	Rate of recurrence of hepatitis (overall, severe)	Rate of any irAE	Hepatitis prophylaxis
Ziemer, 2016 <sup>65</sup>	2	0%, 0%	0%	Budesonide and UDCA
Spain, 2017 <sup>66</sup>	2	50%, 50%	100%	50% prednisone 30 mg/d
Pollack, 2018 <sup>67</sup>	19	26.3%, NA	NA	NA
Santini, 2018 <sup>68</sup>	3	33%, NA	NA	NA
Gauci, 2018 <sup>43</sup>	2	0%, 0%	NA	No
Simonaggio, 2019 <sup>69</sup>	5	60%, NA	NA	NA
Cheung, 2019 <sup>46</sup>	2	0%, 0%	NA	NA
Riveiro-Barciela, 2020 <sup>70</sup>	6	0%, 0%	NA	No
Li, 2020 <sup>71</sup>	31	12.9%, 6.5%	19.4%	32.2% prednisone ≤ 10 mg/d
Riveiro-Barciela, 2023 <sup>72</sup>	23	34.8%, 34.8%	43.5%	34.8% prednisone ≤ 10 mg/d

NA, not available; UDCA, ursodeoxycholic acid; irAE, immune-related adverse events.

test in 72 h. If worsening continues, prednisone should be started at 0.5–1 mg/kg/d.

**Quality of evidence: moderate.**

**Strength of the recommendation: strong in favor.**

#### Recommendation 10

In patients with grade 3 or 4 ICI-induced hepatitis, the panel suggests withholding ICI treatment and starting prednisone (0.5–1 mg/kg/d). The decision to start prednisone could be deferred on an individual basis in patients with TB levels < 2.5 mg/dL until a new assessment of liver function.

**Quality of evidence: moderate.**

**Strength of the recommendation: weak in favor.**

#### Recommendation 11

In patients with grade 3 or 4 ICI-induced hepatitis with bilirubin levels > 2.5 mg/dL and an INR > 1.5 (with or without HE), the panel recommends withholding ICI treatment and starting prednisone (1–2 mg/kg/d) in combination with MMF or tacrolimus.

**Quality of evidence: moderate.**

**Strength of the recommendation: strong in favor.**

#### Recommendation 12

Plasma exchange may be an option in patients with grade 3 or 4 hepatitis and liver dysfunction (TB > 2.5 mg/dL and INR > 1.5, with or without HE), particularly in the absence of response to immunosuppressive treatment.

**Quality of evidence: low.**

**Strength of the recommendation: weak in favor.**

#### Retreatment

Hepatitis recurrence after retreatment with ICI is uncommon. In a large recently published retrospective cohort that included 6123 patients treated with ICI who developed irAEs, the rate of recurrence of any-degree of hepatitis was only 29% (95% CI, 16–47%).<sup>61</sup>

In case of grade 2 ICI-induced hepatitis, the recommendation is to discontinue ICI treatment and restart in the case of spontaneous or CS-induced improvement to either grade 1 hepatitis or complete normalization of transaminases. However, in the case of severe ICI-induced hepatitis (CTCAE grade 3 or 4), international guidelines recommend permanent discontinuation of ICI.<sup>26,27</sup> Nevertheless, some of these patients may benefit from restarting ICI in view of increasing data on the better prognosis of cancer associated with severe irAEs, or, in other cases, due to absence of other lines of therapy alternatives to ICI.<sup>62–64</sup> Evidence in clinical practice on the safety of rechallenge with ICI after an episode of severe ICI-induced hepatitis is scarce and mainly based on small series of cases or individual reports (Table 4).<sup>43,46,65–72</sup> Nonetheless, these preliminary data have pinpointed the fact that recurrence is neither universal nor associated with greater severity of hepatotoxicity. In the studies including the largest number of patients, the risk of relapse ranged from 13 to 35%, with progression of the oncological underlying disease and not toxicity as the most frequent cause for ICI discontinuation.

Therefore, after an episode of severe ICI-induced hepatitis, the possibility of retreatment with ICI may be considered based on the risk-benefit assessment: status of the cancer, options for oncological therapy beyond ICI and the severity of prior immune-related hepatitis (according to the DILI severity score). In case of rechallenge with ICI, it is essential to ensure close analytical and clinical follow-up to achieve early identification and treatment in the case of recurrence of hepatotoxicity.

#### Recommendation 13

In patients with grade 3 or 4 ICI-induced hepatitis, ICI rechallenge should be considered after appropriate risk-benefit assessment.

**Quality of evidence: moderate.**

**Strength of the recommendation: weak in favor.**

### Immune checkpoint inhibitor-induced cholangitis

Inflammation of the biliary tree during treatment with ICIs manifests as two separate entities: (1) small duct cholangitis, and (2) large duct cholangitis affecting the intra- and extra-hepatic bile ducts.<sup>73–97</sup> Regardless of its presentation, ICI-induced cholangitis is a very uncommon irAE (0.05–0.7% of treated patients).<sup>63</sup> However, the actual prevalence might be underestimated because ALP and GGT determinations are not routinely performed as part of the standard monitoring of liver tests during ICI treatment.<sup>34,64</sup> ICI-induced cholangitis has more frequently been reported in patients treated with PD-1/PD-L1 blockers, especially nivolumab and pembrolizumab.<sup>75</sup> This is probably explained by the abundant expression of PD-1 ligands (PD-L1 and PD-L2) by the cholangiocytes, which do not express CTLA-4 ligands.<sup>98</sup>

**Small duct cholangitis.** Patients are frequently asymptomatic and present with mild to moderate elevations of ALP and GGT<sup>99</sup> typically after 2–4 cycles of therapy.<sup>75</sup> The diagnosis of a small duct cholangitis requires a liver biopsy, in which a peribiliary lymphocytic infiltrate rich in T lymphocytes (mainly CD8+ T cells) is the typical lesion.<sup>75,100</sup> Other histological findings described in case reports are small bile duct injuries with irregularity of bile duct epithelium and degeneration of the bile ducts.<sup>77</sup>

**Large duct sclerosing cholangitis.** The clinical presentation of this entity is highly variable and ranges from asymptomatic presentation to a clinically apparent cholangitis with jaundice, fever, and abdominal pain. The median number of cycles between the beginning of the treatment and the diagnosis of sclerosing cholangitis is longer than in patients with small duct cholangitis (range 1–27).<sup>73,77</sup> The involvement of large bile ducts is detected by magnetic resonance cholangiopancreatography (MRCP). The radiological findings most frequently described are: (1) dilatation of the extra-hepatic bile ducts, and (2) diffuse hypertrophy of the extra-hepatic bile duct wall.<sup>101</sup> Histological findings of the bile ducts biopsies are similar to those described for small duct cholangitis with CD8+ T cell infiltration.<sup>102</sup> A subgroup of patients also present features of sclerosing cholangitis with strictures and dilatations of the biliary tree. As in other forms of ICI-related hepatotoxicity, it is mandatory to rule-out other causes of biliary tree abnormalities, specifically the presence of tumoral infiltration of the bile duct.<sup>98</sup>

Peroral cholangioscopy has also helped to describe the characteristics of the bile duct lesions in large duct cholangitis showing thickening of the extra-hepatic bile ducts, band-like narrowing, and diverticulum-like outpouching of the wall.<sup>66</sup> Ulceration of the biliary epithelium has also been described indicating a more severe form of the disease.

**Vanishing bile duct syndrome.** This is a rare entity that consists of the destruction of intrahepatic bile ducts leading to cholestasis and complete ductal loss. Over time patients can develop cirrhosis and liver failure. There are very few case reports of vanishing bile duct syndrome in the context of ICI treatment and the prognosis is poor.<sup>103–105</sup>

**Treatment.** Mild forms of small duct ICI-induced cholangitis improve after ICI withdrawal and do not require specific treatment. The remaining patients, including those with large duct cholangitis, likely require treatment with CS and ursodeoxycholic acid (UDCA). However, the appropriate dose, treatment duration, and response criteria are currently unknown. In patients with large duct cholangi-

tis, treatment response is unpredictable and some patients present liver enzyme elevations while tapering steroid doses. The results of a systematic literature review comprising 53 cases of ICI-induced cholangitis indicated that after CS, liver enzymes took a long time (longer than cases of ICI-induced hepatitis) to decrease, and frequently did not completely normalize.<sup>77</sup> In cases showing a lack of response to CS, other immunosuppressive drugs have been used (azathioprine, MMF,<sup>88</sup> or tocilizumab<sup>106</sup>) with variable results. UDCA has cytoprotective, antiapoptotic, and immunomodulatory effects. In the reported cases, UDCA was continued for a long time after CS withdrawal to promote recovery of the bile ducts.<sup>77</sup>

Rechallenge after an episode of ICI-induced cholangitis has been reported in only one case in which cholangitis did not recur after 30 months of ICI treatment.<sup>107</sup>

### Recommendation 14

We suggest performing an MRCP to rule-out ICI-induced cholangitis in patients with significant ALP and GGT elevations and/or bile duct dilation in liver ultrasound.

**Quality of evidence: low.**

**Strength of the recommendation: strong in favor.**

### Recommendation 15

We suggest CS therapy with or without UDCA for management of ICI-induced cholangitis.

**Quality of evidence: low.**

**Strength of the recommendation: weak in favor.**

## Gastrointestinal toxicity induced by ICIs

Gastrointestinal is the second most common irAE after skin involvement, and is at the top as the most common cause for immunotherapy discontinuation.<sup>26,27</sup>

### Clinical manifestations

#### Symptoms of gastrointestinal (GI) toxicity secondary to ICIs

Considering that ICIs can produce irAEs in any section of the digestive tract, the symptoms that they can cause can be varied and nonspecific depending on the location and/or extension of digestive affectation. The predominant symptom recorded in all clinical trials and in the different studies in real practice (most of them retrospective) is diarrhea (defined as the presence of more than 3 daily stools together with a low stool consistency).<sup>108</sup> Diarrhea may be accompanied by other symptoms, such as abdominal pain or bloating (up to 53% of cases), rectal bleeding or mucus in stools (up to 26% of cases), fecal urgency or fever (up to 15% of cases).<sup>108–120</sup> These latter symptoms may refer to another term that appears repeatedly in the literature such as colitis and is usually derived from the presence (detected by endoscopy and/or radiology) of an inflammatory involvement of the colon.<sup>112,113,117,120</sup> Other symptoms described in some series (some of which show upper digestive involvement) are nausea/vomiting (up to 22% of cases) or epigastric pain (see gastric toxicity section).<sup>111–115,121</sup>

Clinicians should have clinical suspicion for other infrequent but serious manifestations that patients receiving ICIs

can present, especially, intestinal perforation (mainly of the colon, although there are cases described in the small intestine), reported in up to 1.5% of cases of colitis or ileitis.<sup>122,123</sup> The symptoms do not differ from those caused by other etiologies (acute abdominal pain, fever, deterioration of the general condition) but it is usually accompanied by a picture of previous digestive toxicity that tends to worsen over time despite specific treatment. Apart from this complication, there is a published case of massive gastrointestinal bleeding and another of intestinal obstruction due to marked inflammation of the terminal ileum.<sup>124,125</sup> Patients with GI toxicity secondary to ICI may present a greater sensitivity to present toxicities in other organs and systems and the concurrence of more than two of them may be a risk factor for new irAEs.<sup>126</sup> A multicenter study in 1281 patients treated with anti-PD-1, 191 cases of GI toxicity in the form of diarrhea/colitis were identified. In this subgroup of patients, a second toxicity (skin, liver or endocrine among the most frequent) was detected in 45.5% of them (and up to 60% in those with two drugs in combination). This second toxicity was detected prior to, subsequent, or concomitant to GI toxicity. Although the pathogenesis of this cascade phenomenon is unclear, it is important for the clinician to recognize and interpret each and every one of the symptoms that these patients may present during treatment and after discontinuation.<sup>127</sup>

Hospitalization could be another severity clinical presentation form. In a retrospective multicenter study, hospital admissions for one year were analyzed in a cohort of patients receiving ICI. Of the 99 patients included, there was a total of 202 admissions, 33 (16%) motivated by an irAE, being hepatotoxicity and colitis the most frequent.<sup>128</sup> Another study found that up to 33% of the reasons for consultation in the emergency room among patients receiving ICI were toxicities that required hospital admission; with colitis (39%) being the most frequent cause of admission.<sup>129</sup> Finally, in a systematic review and meta-analysis, fatal adverse events produced by immunotherapy between 2009 and 2018 were analyzed through the WHO pharmacovigilance registry on the notifications of all clinical trials published to date. In this meta-analysis, 613 irAEs were recorded: 70% and 37% of fatal events secondary to ipilimumab use and anti-PD-1 combination therapy, respectively, were in the form of colitis.<sup>7</sup>

### Statement 3

Diarrhea is the main clinical manifestation of GI toxicity secondary to ICIs. Symptoms are nonspecific, and clinicians should carry out a differential diagnosis with other processes. Colitis is an endoscopic and/or radiological entity.  
**Quality of evidence: high.**

### Time of onset of GI toxicity associated to ICIs

The time of onset of GI toxicity (diarrhea/colitis) is unpredictable. A systematic review in which 50 studies were included, only 14% documented the moment of appearance of the different irAEs.<sup>130</sup> In a pooled analysis conducted on 23 clinical trials with 8436 patients who had received ipilimumab, nivolumab, or combined therapy, the median time to onset of any kind of toxicity was established between 2 and 15 weeks. Diarrhea/colitis appeared after a mean

time of 5, 9 and 5 weeks for ipilimumab, nivolumab and combined treatment respectively.<sup>131</sup> In this study, it was demonstrated that GI toxicity was one of the earliest manifestations along with the skin or liver. Similarly, another meta-analysis showed median time to onset of any symptom was 10 weeks (range 6–20).<sup>132</sup>

These data do not differ substantially from those reported in real practice. The FDA spontaneous notification registry published in 2020, in which 3786 cases of colitis were identified (between 2004 and 2019), showed that >70% of the events occurred in the first 90 days from the administration of the first dose.<sup>133</sup>

Nevertheless, there are patients who develop late-onset toxicity or even after months of drug discontinuation.<sup>134</sup> In a retrospective study that evaluated the characteristics of late irAEs (more than a year from the start of treatment) presented in 144 patients with melanoma, it was found that colitis was found to be the most common late manifestation (22% cases) and up to 58% of cases were serious. Most of these patients were receiving treatment, but up to 26% had stopped it for more than 3 months.<sup>135</sup> It is important, therefore, that the clinician and the patient are aware of this late toxicity profile to identify and treat these forms of presentation as soon as possible.

Although variability has been mentioned concerning the time of onset of diarrhea/colitis, there are some factors associated with the earlier appearance of these events. The most relevant is the use of combination therapies (ipilimumab plus nivolumab or ipilimumab plus pembrolizumab).<sup>133</sup> In a multicenter study in which 1261 patients were included, colitis was more frequent and appeared earlier in patients receiving combined treatment (7 vs 25 weeks).<sup>126</sup> Similarly, the toxicity produced by anti-CTLA-4 tends to appear earlier than anti-PD-1 or anti-PD-L1 drugs.<sup>130,133</sup> Finally, a French study that analyzed the toxicity profile in 356 patients treated with ICIs found that those with severe forms presented earlier than mild presentations (47 vs 91 days,  $p=0.021$ ).<sup>136</sup>

### Statement 4

Gastrointestinal toxicity can appear at any time after starting ICIs, but generally occurs between 2–15 weeks after therapy initiation.

**Quality of evidence: high.**

### Classification of GI toxicity due to ICIs

In oncology clinical trials, AEs are recorded using the CTCAE. The severity of these events is classified into 5 grades ranging from mild to severe and fatal and are specified for each symptom or manifestation (Table 5).<sup>12,137</sup> The different guidelines and recommendations of the scientific oncological societies recommend identifying, classifying and managing the toxicity produced by ICI based on this classification.<sup>26,27,138</sup> However, CTCAE are based exclusively on clinical (subjective) parameters that have not been correlated with prognostic factors such as the need for immunosuppressive treatment, CS-resistance rates or colectomy. A British study analyzed the association between CTCAE grade, biochemical parameters, endoscopic activity and histological findings with prognostic factors

**Table 5** Grades of ICI-induced gastrointestinal adverse events according to CTCAE by the National Cancer Institute (version 5).<sup>137</sup>

	Grade				
	1	2	3	4	5
Diarrhea	Increased bowel movements (<4 times per day over baseline). Low increase of fecal volume per ostomy.	Increased bowel movements (4–6 times per day over baseline). Moderate increase of fecal volume per ostomy.	Increased bowel movements ( $\geq 7$ times per day over baseline). Severe increase of fecal volume per ostomy. Impaired general status. Need for hospital admission.	Increased bowel movements that compromises vital status and requires urgent action.	Death
Colitis	Imaging/endoscopic evidence of colonic inflammation.	Mild abdominal pain and/or rectal bleeding.	Moderate-severe abdominal pain and/or rectal bleeding. Peritoneal signs.	Severe abdominal pain and/or severe bleeding/perforation/ischemia/toxic megacolon that compromises vital status and requires urgent action.	Death

such as need for prolonged CS and/or infliximab (IFX). However, CTCAE classification (grades 2, 3 and 4) did not correlate with the duration of CS treatment and need for IFX ( $p=0.18$ ). Conversely, there was a good correlation between endoscopic activity index and histological activity with these prognostic factors. The authors concluded that endoscopic and histological data could be the most accurate factors to determine severity and need for salvage treatments.<sup>118</sup> Several studies (most of them retrospective) have reported the presence of diarrhea/colitis according to grade severity, observing different rates.

#### Recommendation 16

We recommend the use of CTCAE classification to assess the degree of severity of diarrhea and/or colitis.

**Quality of evidence: high.**

**Recommendation: strong in favor.**

#### Epidemiology

The incidence of ICI-induced colitis among patients included in clinical trials and observational studies ranges between 0.7% and 13.6%<sup>109,126,139–142</sup>; nevertheless, its real incidence is unknown since endoscopy or even fecal inflammatory markers determination are not systematically performed. In fact, most studies present the percentage of diarrhea or GI adverse events which are higher than those reported for colitis.

**Diarrhea/colitis secondary to anti-CTLA-4.** The first irAEs reported due to the use of anti CTLA-4 come from clinical trials in metastatic melanoma and renal cell carcinoma.<sup>115</sup> In the first meta-analysis published in 2015 that included 22 clinical trials (1265 patients) of patients treated with ipilimumab (mainly) or tremelimumab, the rate of GI irAEs was 35% (95% CI: 29–41%), being the predominant toxicities together with the cutaneous ones. Of these events, 11% (95% CI: 8–13.5%) were categorized as severe (grades

3–5). This meta-analysis also demonstrated that toxicity increased in the subgroup of patients treated with high doses of ipilimumab (10 mg/kg vs. 3 mg/kg), especially in cases of GI toxicity (RR 1.43,  $p=0.03$ ).<sup>143</sup> Another subsequent meta-analysis that included 5 new clinical trials showed the highest percentage of diarrhea secondary to ipilimumab (up to 47.8% for all grades) and a 6.4% occurrence of colitis.<sup>144</sup>

Real practice data could differ with respect to clinical trials and may be related to certain limitations such as study design, underdiagnosis, misconception between diarrhea/colitis or limited follow-up data coming from spontaneous notifications. In the systematic review and meta-analysis published in 2020 with 34 observational studies and 3699 patients, the rate of severe colitis (grades 3–5) was 4% (95% CI: 3–7%); however, the mean follow-up time was very short (3 months).<sup>145</sup> **Supplementary Table 2** summarizes global incidence of diarrhea/colitis due to anti-CTLA-4 therapy in several published studies.<sup>115,118,119,143–147</sup>

#### Statement 5

Anti-CTLA-4 therapy (mainly ipilimumab) may be associated with diarrhea and/or colitis as adverse event for up to one in three patients, being a serious event in 11% of these. **Quality of evidence: high.**

**Diarrhea/colitis secondary to anti-PD-1 or anti-PD-L1.** A meta-analysis published in 2017 that analyzes the incidence of adverse events produced by the different antibodies against the PD1 protein and its ligand found a global rate of irAEs of 26.8% (6% serious). The incidence rate for diarrhea of any grade and for severe rate varied between 4 and 13% (the highest percentage corresponding to patients receiving nivolumab treatment) and 0.5–1.9%, respectively, while, colitis rate was <1% for all lines of treatment.<sup>148</sup> These rates were similar in the individual analysis for several drugs.<sup>139,149</sup> However, Sonpavde GP et al. meta-analyzed 35 clinical trials (phase I–IV) comparing the rate of different



serious irAEs in patients treated with anti-PD-1 vs. anti-PD-L1 and found an increased rate of colitis (Odds Ratio [OR] 2.53) and severe colitis (OR 3.79) for patients treated with anti-PD-1 (nivolumab, pembrolizumab), concluding that the toxicity profile could vary between both drugs.<sup>150</sup> Two recent meta-analysis suggest that the risk of colitis is also higher with anti-PD-1 treatment compared to anti-PD-L1 therapy.<sup>151,152</sup> Cases of diarrhea and colitis reported in real practice are scarce.<sup>151,153,154</sup> On the other hand, some cases of microscopic colitis in relation to anti-PD-1 have been reported, although the real prevalence is difficult to establish. For this reason, it is important to perform colonic random biopsies in cases of immune checkpoint-associated unexplained diarrhea, even when colonoscopy shows macroscopically normal colonic mucosa.<sup>155</sup> [Supplementary table 3](#) summarizes studies that have evaluated incidence of gastrointestinal toxicity secondary to anti-PD-1/PD-L1.<sup>118,119,126,134,135,139,146–150,153,154,156,157</sup>

#### Statement 6

Anti-PD-1 or anti-PD-L1 therapy may be associated with diarrhea and/or colitis as adverse event in 4–13% of cases. This risk seems to be lower for anti-PD-L1 treatment.

**Quality of evidence: high.**

*Risk of diarrhea/colitis comparing anti-CTLA-4 vs. anti-PD-1(PD-L1).* Based on the data previously mentioned, a low risk of GI toxicity (diarrhea/colitis) is expected in patients treated with anti-PD-1/anti-PD-L1 drugs. In the meta-analysis with the largest number of studies and patients included (145 trials, 21,786 patients) recently published by Ouyang T et al. the comparative risk of severe toxicity in patients treated with several lines of ICI were specifically evaluated.<sup>158</sup> The incidence of severe irAEs was significantly higher for anti-CTLA-4 than anti-PD-1 or anti-PD-L1 (21.7% vs 3.2%,  $p < 0.001$ , 21.7% vs 2.4%,  $p < 0.001$ , respectively). These differences were also maintained when the different irAEs were analyzed; thus, diarrhea and colitis were significantly more common in patients treated with anti-CTLA-4 vs. anti-PD-1/PD-L1 group [OR 8.1, 95% CI: 6.4–10.3 ( $p < 0.001$ ) and OR 12.2, 95% CI: 8.7–17.1 ( $p < 0.001$ ); respectively]. In fact, the immunological profile of colitis associated with anti-CTLA-4 seems to be different from colitis induced by anti-PD-1 therapy.<sup>159</sup>

Despite these differences in the GI toxicity profile and although safety may be a limitation when selecting a treatment, in many cases the decision to start an immunotherapy drug is closely linked to the tumor lineage and the clinician cannot choose between different drugs.

#### Statement 7

The risk of diarrhea/colitis seems to be higher for anti-CTLA-4 therapy than anti-PD-1 or anti-PD-L1, even for serious events (RR 8–12).

**Quality of evidence: high.**

*Risk of diarrhea/colitis with the combination of anti-CTLA-4 and anti-PD-L1.* The combination of two immunotherapeutic drugs (anti-CTLA-4 plus anti-PD-1 or anti-PD-L1) is used as a therapeutic strategy in some neoplasms that show

resistance to monotherapy treatment. Considering the risk of toxicity in monotherapy presented by these treatments, we could expect an increase in irAEs with this therapeutic approach. CheckMate clinical trials evaluated the efficacy and safety of ipilimumab plus nivolumab in patients with advanced melanoma; of the 945 patients included, 314 received combination therapy. At 4 years of follow-up, 59% of the patients in combination therapy presented some serious adverse event (grades 3–4) compared with 22 and 28% of the patients treated with nivolumab and ipilimumab monotherapy, respectively. The most frequently reported event was diarrhea. Up to 40% of the patients in combination therapy needed to stop treatment, mainly due to the appearance of colitis (30 patients, 10%).<sup>160</sup> The most robust subsequent evidence comes from different meta-analysis showing an increased risk compared to monotherapy, especially with anti-CTLA-4.<sup>158,161–164</sup> A recent meta-analysis that evaluates 18 studies (2767 patients) included patients treated with combined therapy (mainly ipilimumab plus nivolumab) vs monotherapy and showed an increase in serious adverse events with a RR 2.21 (95% CI: 1.57–3.10).<sup>165</sup> The most reported events were diarrhea and colitis (for all grades) with an accumulated incidence of 3 out of 10 patients. Finally, retrospective studies and the pharmacovigilance data from the FAERS show data along the same lines.<sup>11,146,166,167</sup>

#### Statement 8

The risk of diarrhea and/or colitis is higher with combination of ICI (anti-CTLA-4 plus anti-PD-1 or anti-PD-L1) compared to ICI in monotherapy (RR 2).

**Quality of evidence: high.**

#### Risk factors for GI toxicity induced by ICIs

Many risk factors for severe diarrhea and endoscopically proven colitis have been suggested; however, strong evidence is lacking and, to date, there are no reliable baseline biomarkers that can predict the development of ICIs-induced colitis in the clinical practice.

*Risk of GI toxicity depending on the type of ICI.* Main risk factor for ICI-induced colitis, as a group, seems to be the class of drug with a higher risk with anti-CTLA-4 and the combination of two ICIs.<sup>118,126,139,146,168–170</sup> Moreover, the occurrence of colitis in patients under ipilimumab has been shown to be dose-dependent,<sup>171–173</sup> although some studies did not show differences between lower and higher doses.<sup>115,174</sup> On the other hand, the recurrence rate of colitis in those patients who discontinued ICIs is high after patients received a rechallenge with the same drug,<sup>61</sup> suggesting that a previous episode of ICIs-induced colitis is a significant risk factor for further development of new flares of this adverse event.

*Risk of GI toxicity in patients treated with combination of ICIs and oncology therapies.*

*Chemotherapy.* Chemotherapy and immunotherapy have different safety profiles. Shao J et al. demonstrated in a meta-analysis that the risk of presenting classic adverse events (such as cytopenia, nausea, asthenia, etc.) in patients with lung cancer treated with ICIs were lower than those treated with CT (risk ratio [RR]: 0.9, 95% CI:



0.84–0.95,  $p$  0.001). Nevertheless, when the rate of irAEs in different organs was compared, this risk was higher for ICIs (colitis RR 5.54, hepatitis RR 2.49, hypophysitis RR 3.91, or pneumonitis RR 2.57). Therefore, with the advent of immunotherapy, the safety profile of treatments used in oncology has changed.<sup>175</sup>

Considering the therapeutic resistance of different tumors to chemotherapy or immunotherapy used in monotherapy, different therapeutic strategies that combine both drugs have been evaluated. A meta-analysis published in 2020 analyzed the risk of GI toxicity comparing combined ICIs and chemotherapy regimens and it was demonstrated that chemotherapy plus ICIs (both anti-CTLA-4 and anti-PD-1/PD-L1) vs. chemotherapy alone significantly increased the risk of diarrhea (RR 2.23 and RR 1.38, respectively) and colitis (RR 28.39 and RR 2.90, respectively).<sup>176</sup> These results were confirmed in other meta-analysis.<sup>177</sup>

Considering the essence of this guide, it would be interesting to know if there is an increased risk between associating chemotherapy with immunotherapy vs. isolated immunotherapy; however, scientific evidence regarding this topic is still scarce. A meta-analysis of 16,409 patients included in 26 randomized controlled trials (RCT), of which five studies included ICIs (atezolizumab or pembrolizumab) plus chemotherapy regimens showed a higher rate of colitis of any grade with the combination of ICIs and chemotherapy (RR 2.62; 95% CI, 1.25–5.48,  $p$ =0.01), with no statistically significant differences in severe colitis (RR 2.27; 95% CI: 0.93–5.53,  $p$ =0.07).<sup>177</sup>

**Targeted therapies.** Another therapeutic approach includes the use of targeted therapies [antiangiogenic monoclonal antibodies (mAbs) and tyrosine Kinase inhibitors (TKIs)] together with immunotherapy as a synergistic effect of two different mechanisms of action assumed. A systematic review analyzed the safety profile of a combination of ICIs and antiangiogenic drugs (14 with bevacizumab and 1 with ramucirumab) or TKIs (5 with axitinib, 4 with pazopanib, 2 with sorafenib, 2 with lenvatinib and 1 each with sunitinib, cabozantinib, apatinib and cediranib). The rate of serious adverse events (AEs) with ICIs plus TKI was higher than that of ICI plus mAbs (60.1% vs 44.5%). The incidence of severe colitis was less than 1% for both strategies.<sup>178</sup> The data available with the different immunotherapies and targeted therapies are scarce and many of them are poor quality and without a control group.<sup>179–181</sup> The largest extractable evidence shows that atezolizumab plus bevacizumab could increase the rate of AEs but not the rate of irAEs.<sup>182</sup> In summary, the available data on the safety of combining immunotherapy with targeted therapies makes it difficult to draw conclusions about its safety at present.

On the other hand, two retrospective studies showed that patients treated with IPCIs and concomitant radiotherapy – particularly those who received a higher dose – had a greater rate of irAEs than patients treated with ICIs alone<sup>183,184</sup>; however, these studies did not find a significant association between site irradiated and organ-specific adverse events, probably due to their small sample size.

#### Statement 9

The risk of diarrhea/colitis due to ICIs plus chemotherapy has not been properly addressed and does not appear to be increased.

**Quality of evidence: moderate.**

#### Statement 10

Combination therapy with ICIs plus target therapy may increase the risk of diarrhea/colitis (especially for TKIs).

**Quality of evidence: low.**

**Patient-related risk factors for developing ICI-induced GI-toxicity.** A retrospective analysis of a cohort of 327 patients from MD Anderson Cancer Center<sup>174</sup> and a nationwide, population-based study including more than 13,000 patients treated with ICIs<sup>185</sup> showed that caucasians had higher odds of developing diarrhea or colitis. Thus, it is tempting to hypothesize that genetic factors might play a role in the development of ICI-induced colitis; but, few studies have investigated this issue demonstrating association with some polymorphisms and the development of irAEs.<sup>186–189</sup> However, to date, all these data have not been validated.

Compared to patients diagnosed with other malignancies, melanoma patients seem to have a higher risk for ICIs-induced colitis development.<sup>109,174,190</sup> The reason for this association is unknown, but it should be considered that ICIs, and particularly ipilimumab, were initially tested on melanoma patients, and the majority of trials on lung cancer patients evaluate anti-PD-1/PD-L1 therapy. In fact, multivariate logistic regression model for the risk of colitis depending on tumor type carried out from a systematic review including around 7000 patients did not confirm this relationship.<sup>140</sup>

It is well known that body composition is related with drug toxicity: in this sense, sarcopenia and low muscle attenuation – assessed before treatment by computed tomography – were significantly associated with the development of high-grade irAEs, including colitis, in a study that included 84 patients diagnosed with melanoma and treated with ipilimumab.<sup>191</sup> In addition, it has been shown that obese individuals had a significantly higher risk for ICI-induced colitis.<sup>192</sup> On the other hand, gut microbial composition – which is influenced by the body mass index – might also be a risk factor for ICIs-induced colitis: in 2016 Dubin K et al. demonstrated, analysing fecal samples from a cohort of patients treated with ipilimumab, that an increased representation of bacteria belonging to the *Bacteroidetes* phylum was associated with a lower rate of development of ICI-induced colitis, consistent with a previously suggested immunomodulatory role of these commensal bacteria. They also showed that a paucity of genetic pathways involved in polyamine transport and vitamin B biosynthesis was associated with an increased risk of colitis.<sup>193</sup> A second study that analyzed fecal samples from 26 melanoma patients treated with ipilimumab confirmed those findings,<sup>194</sup> showing that individuals with a baseline gut microbiota enriched with *Faecalibacterium* and other *Firmicutes* had a higher rate of ipilimumab-induced colitis in comparison with those whose baseline microbiota was driven by *Bacteroides*. Therefore, a high *Firmicutes* to *Bacteroidetes* ratio in fecal samples at baseline may

predict a higher risk of ICI-induced colitis.<sup>195</sup> Moreover, baseline levels of antibodies directed to microbial antigens such as *Escherichia coli* outer membrane porin (anti-OmpC) could also be related with a higher risk for ICI-induced colitis.<sup>196</sup> Additional evidence on the role of microbiota in the pathogenesis of ICI-induced colitis comes from a retrospective study including more than 800 patients that showed antibiotic use at any time was associated with a reduced ICI-induced colitis incidence but a more frequent hospital and intensive care unit admission due to more severe forms of intestinal inflammation. Furthermore, those receiving antibiotics after ICIs therapy start, and those treated with antibiotics with anaerobic activity had a higher rate and severity of colitis.<sup>197</sup>

Certain cellular and molecular features suggestive of immune dysregulation at baseline or immediately after ICIs treatment initiation have been proposed as risk factors for immune-related – including gastrointestinal – adverse events and could predict their development.<sup>198,199</sup> Neutrophil to lymphocyte ratio – an increasingly used biomarker of systemic inflammation – before ICIs treatment has been shown to be significantly lower in patients with irAEs,<sup>200–202</sup> including colitis.<sup>140,170</sup> It has been reported that patients with ICI-induced colitis tend to have higher absolute CD4<sup>+</sup> T-cell numbers and lower percentage of regulatory T cells in peripheral blood at baseline compared to patients who did not develop such AE.<sup>194</sup> Early changes in circulating B cells subpopulations following combination of ICIs may also identify patients at risk of irAEs, including colitis.<sup>203</sup> Moreover, gene expression profiling of peripheral blood, sampled before or early after ipilimumab treatment start, resulted in the identification of a set of potential biomarkers – notably increases of the gene expression of neutrophil-activation markers CD177 and CEACAM1 – that were associated with the subsequent development of GI AEs.<sup>204</sup> In a more recent study on melanoma patients included in two clinical trials evaluating the anti-CTLA-4 antibody tremelimumab, an RNA transcript-based gene signature (including 16 immune response-related genes) in peripheral blood obtained after treatment initiation have been shown to discriminate patients developing grades 0–1 from grades 2 to 4 diarrhea or colitis.<sup>205</sup> On the other hand, a positive correlation between elevated baseline serum IL-17 levels and the risk of diarrhea and severe colitis was found in a phase 1 trial of ipilimumab.<sup>206</sup> Finally, vitamin D intake – that has been associated with immunomodulatory effects – was correlated with a reduced risk for ICI-induced colitis in a retrospective analysis.<sup>170</sup> In any case, this interesting finding should be confirmed in future RCTs. Risk factors associated with the development of diarrhea and/or colitis are summarized in the [supplementary table 4](#).

*IBD as a risk factor for the subsequent development of ICI-induced enterocolitis.* Cancer patients with a previous diagnosis of an immune-mediated (IM) disease, including inflammatory bowel disease (IBD), were mostly excluded from ICI clinical trials.<sup>5</sup> But real-world studies have suggested that patients diagnosed with pre-existing IBD before ICI treatment seems to have an increased risk of severe diarrhea and colitis after treatment with both anti-CTLA-4 and anti-PD-1/PD-L1 therapy.<sup>207–210</sup> In patients with pre-existing IBD, the risk of flare after ICIs treatment seems to be higher in patients treated with ipilimumab (vs

anti-PD-1/anti-PD-L1),<sup>207</sup> in younger patients and, probably, in those previously diagnosed with microscopic colitis (vs ulcerative colitis or Crohn's disease).<sup>208</sup>

#### Statement 11

Many patient-related factors, such as race, body mass index, genetic or immunogenic profile, antibiotic use, gut microbiome composition, or vitamin D intake, have been proposed as risk modifiers for developing ICI-induced GI toxicity. Patients with pre-existing IBD seems to have an increased risk of severe diarrhea and colitis.

**Quality of evidence: low.**

#### Diagnosis and differential diagnosis

*Diagnosis tools.* Colonoscopy with biopsies has been proposed as the gold standard diagnostic tool for patients with suspicion of ICI-induced colitis.<sup>26,138,207</sup> In the majority of patients, the inflammatory process affects exclusively the colon, more than 40% of them having pancolitis, and approximately half of cases show continuous involvement; less than 20% show both ileal and colonic involvement, whereas isolated ileal involvement is anecdotic.<sup>109,112,114–116,146,151,196,211–213</sup> Mucosal erythema, absence of vascular pattern, granularity and friability seems to be the most frequent endoscopic findings, but in up to one to two thirds of cases, ulcers are present at endoscopic examination.<sup>112,116,212,213</sup> Ulcers are associated with a worse prognosis in terms of need for hospital admission, CS-refractoriness and need for biologic treatment<sup>117,118,120,211</sup>; therefore, early endoscopic evaluation of patients with ICIs-associated diarrhea is mandatory, it being associated with better prognosis.<sup>117</sup> It is noteworthy to underline that the vast majority of patients with ICI-induced colitis have recto-sigmoid involvement; thus, flexible sigmoidoscopy might represent a safer and more affordable alternative to complete colonoscopy,<sup>214</sup> and recent studies suggested that sigmoidoscopy with biopsies may be sufficient for the initial evaluation of suspected ICI-induced colitis.<sup>215–217</sup> Histological features of ICIs-induced enterocolitis are non-specific, and include lymphoplasmocytic infiltration of the *lamina propria*, increased intraepithelial lymphocytes and/or neutrophils, cryptitis and crypt distortion – usually mild – and, characteristically, augmented epithelial apoptosis.<sup>109,218,219</sup> Moreover, granulomas and thickening of the subepithelial collagen band have been described.<sup>112,114–116,146,196,211,213,220–223</sup> Immunohistochemical analysis shows an increase of all T-cell subsets (CD3<sup>+</sup>, CD4<sup>+</sup>, and CD8<sup>+</sup>) and of CD4<sup>+</sup>CD25<sup>+</sup> regulatory T cells.<sup>220,222</sup> A recent, comprehensive single-cell analysis of mucosal immune cell populations in ICI-induced colitis showed a predominant accumulation of CD8<sup>+</sup> T cells with highly cytotoxic and proliferative states – without evidence of regulatory T cells depletion – as well as an increase in myeloid-lineage cells.<sup>224</sup> In the same line, another recent study has elegantly demonstrated that the predominant activated T cell subset in this condition is a population of interferon gamma-producing CD8<sup>+</sup> tissue-resident memory T cells.<sup>225</sup> In those cases of recurrent ICIs-induced colitis, histological features are similar to the initial episode but, in addition, fea-

tures of chronicity develop – basal plasmocytosis, prominent crypt architectural irregularity and Paneth cell metaplasia – mimicking classical IBD.<sup>221</sup> Few studies have reported ICI-induced gastrointestinal pathological findings outside the colon, such as *lamina propria* expansion and intraepithelial neutrophils in the stomach, or *lamina propria* expansion by lymphoplasmocytic infiltrates and eosinophils, villous blunting, intraepithelial lymphocytosis and neutrophilic villitis in the duodenum and ileum.<sup>115,213,220,226</sup>

Nevertheless, it should be considered that gastrointestinal clinical symptoms do not properly correlate with ICIs-induced histological or endoscopic inflammation.<sup>120,211</sup> In this sense, non-invasive, fecal markers could represent a first screening test in this clinical scenario, to identify those patients at risk of colitis.<sup>5,26,138</sup> It is well known that fecal calprotectin and lactoferrin correlates with endoscopic inflammation in patients diagnosed with IBD, but these markers also have an adequate sensitivity detecting endoscopic and even histological inflammation in patients with ICI-induced diarrhea, and can predict endoscopic and histological remission in patients receiving treatment for this condition.<sup>117,196,227</sup> However, we must keep in mind that calprotectin may be elevated by concomitant treatment with either non-steroidal anti-inflammatory drugs (NSAIDs) or proton-pump inhibitors (PPIs).<sup>228,229</sup>

The role of cross-sectional imaging techniques – CT and MR – in the diagnosis of ICI-induced enterocolitis has also been explored. CT might have a role in the diagnosis of ICI-induced colitis, particularly in the emergency room setting,<sup>5,230</sup> and is essential for excluding complications such as perforation and abscesses.<sup>114,115</sup> Nevertheless, and although positive-predictive value of CT is reported from being high, negative predictive value and correlation with colonoscopy seem far to be optimal.<sup>211,231</sup> CT findings in patients with ICI-induced colitis include diffuse or segmental colonic wall thickening with mucosal or mural hyperenhancement, colonic dilation, pericolonic inflammatory changes and mesenteric vascular engorgement.<sup>126,231–236</sup> *Clostridium difficile* and CMV superinfections have been described in patients treated with ICIs,<sup>112,151,237</sup> and should be ruled out in every patient.<sup>5,26,214,238,239</sup> In relation to CMV superinfection, IgM and IgG serology in blood must be first requested to guide whether it is a reactivation or primary infection, and also the presence of inclusion bodies, immunohistochemistry staining or determination of the viral load in the biopsies is recommended. Those patients with CMV superinfection should start treatment with intravenous ganciclovir in severe cases or oral valganciclovir in outpatient cases for 21 days.<sup>240</sup>

Other enteric infections have been also diagnosed,<sup>112,241,242</sup> and it seems reasonable to rule them out by means of stool culture and direct parasite examination in fecal samples in every patient with new onset or recurrent ICI-induced diarrhea.<sup>5,26</sup> Other causes of diarrhea within this clinical scenario include pancreatic exocrine insufficiency due to immune-induced pancreatitis<sup>243</sup> or pancreatic cancer, de novo coeliac disease,<sup>244</sup> and immune hyperthyroidism.<sup>245</sup> Finally, radiation proctitis or intestinal metastasis of malignant melanoma, among many other conditions, can cause haematochezia and should be considered in the appropriate clinical setting.

#### Recommendation 17

We recommend early endoscopic evaluation (colonoscopy or sigmoidoscopy) with histologic assessment as the gold standard diagnostic test for patients with suspicion of ICI-induced enterocolitis.

**Quality of evidence: moderate.**

**Recommendation: strong in favor.**

#### Recommendation 18

We recommend the use of fecal markers such as calprotectin as first screening test in patients treated with ICIs who develop diarrhea.

**Quality of evidence: low.**

**Recommendation: strong in favor.**

#### Recommendation 19

We recommend ruling out *bacterial infection* (including *Clostridioides difficile*), CMV and parasites superinfections in every patient with suspicion of ICI-induced enterocolitis.

**Quality of evidence: moderate.**

**Recommendation: strong in favor.**

**Differential diagnosis.** Diarrhea is a common AE with both immunotherapy and chemotherapy, as demonstrated in the phase III RCT KEYNOTE-177, which compared pembrolizumab vs. chemotherapy in advanced microsatellite instability-high colorectal cancer. Diarrhea was the most common toxicity, 44% (6% grades 3–4) with pembrolizumab and 62% (11% grades 3–4) with chemotherapy.<sup>246</sup> On the other hand, differentiating between ICI-induced colitis and chemotherapy-induced colitis can be complicated in patients treated with a combination of both, as evidenced by the diagnosis of up to 15% of GI-AEs with potential immunologic etiology in the chemotherapy and placebo arm of the phase III RCT CHECKMATE-648 in advanced esophageal squamous cell carcinoma.<sup>247</sup>

Any chemotherapy can cause diarrhea but it is often self-limiting, not usually associated with abdominal pain, and responds to diet and loperamide.<sup>248</sup> In contrast, in the presence of events of significant duration or magnitude or associated with abdominal pain, signs of systemic inflammation or fecal calprotectin and lactoferrin increase, ICI-induced colitis should be suspected and sigmoidoscopy with colonic biopsy should be performed to check for inflammation and lymphocytic infiltrates to support the diagnostic suspicion.

When diarrhea is refractory, prolonged, aggravated or associated with unusual symptoms/signs, other etiologies should be ruled out. Common causes include infectious, medicinal (antibiotics, antacids), food intolerances to lactose or gluten (coeliac disease), irritable bowel, inflammatory bowel disease and ischemic colitis.<sup>249</sup> Certain neoplasms, complications or treatments are also associated with diarrhea such as neuroendocrine tumors with carcinoid syndrome, and peritoneal mesothelioma,<sup>250</sup> oncological surgeries such as wide bowel resections (short-bowel syndrome), partial intestinal obstruction, and radiation toxicity. In addition, immunotherapy may cause diarrhea due to less common causes than colitis such as pancreatic atrophy (and



exocrine pancreatic insufficiency),<sup>251</sup> interstitial nephritis<sup>252</sup> or pseudolipomatosis.<sup>253</sup>

### Treatment and prognosis of ICI-induced colitis

All available recommendations and published guidelines regarding the treatment of ICI-induced colitis are based on the opinion or consensus of experts based on limited data from observational studies and case series. There are no prospective clinical trials to guide ICI-induced colitis treatment. Four consensus guidelines on the management of irAEs have been published.<sup>26,27,138,254</sup> Due to the lack of clinical evidence, some criteria used in IBD are assumed. A management algorithm of diarrhea and colitis in patients undergoing ICI therapy is proposed in Fig. 2.

*Treatment algorithm in ICI-induced colitis according to severity.* Fig. 2 shows the management of ICI-induced diarrhea. Patients with grade 1 who do not respond to supportive therapy (hydration, fiber, anti-diarrheal drugs) and patients with grade 2 diarrhea should start oral CS (0.5–1 mg/kg/d prednisolone).<sup>119,142,255–258</sup> CS should be started as soon as possible. Once clinical improvement to grade 1 or less is achieved, CS should be tapered over 4–6 weeks.<sup>27,114</sup> In grades 3–4 diarrhea, hospitalization is required for systemic symptoms (fever, hypotension, tachycardia, and/or dehydration) and electrolyte imbalance.<sup>142</sup> Patients with grades 3–4 diarrhea should receive intravenously CS (1 mg/kg/d methylprednisolone).<sup>114,119,128,255–258</sup> Doses higher than 1 mg/kg/d do not increase the efficacy and have poor tolerance, moreover, there are more efficient and safer alternatives. Patients who respond to intravenous CS within 3 to 5 days should be switched to the oral form; subsequently, oral CS should be tapered during a period of 8-week by analogy with IBD management.<sup>26,27,114,119,128,138,142,254–259</sup> Overall, between 40 and 70% of patients who develop ICI-induced colitis respond to CS.<sup>114,116,119,126,128,255–258,260</sup> Data from a retrospective study show that the median duration of CS for grade 3 diarrhea/colitis is 58 days, this long mean time increases the risk of AEs due to CS.<sup>260</sup> In fact, around 17% of patients with GI irAEs have adverse events due to CS, such as adrenal insufficiency, diabetes, infections, and volume overload.<sup>126</sup>

There are no data regarding the usefulness of antibiotics in this scenario although their use could be considered in case of severe colitis. Analogous to other types of severe colitis, morphine derivatives (including loperamide) and NSAIDs are contraindicated for the risk of precipitating a toxic megacolon. In addition, dehydration and hydroelectrolytic disorders need to be corrected as well as an assessment of nutritional status. Patients with ICI-induced colitis have an increased risk of thromboembolic disease due to both the colitis itself and the underlying neoplasm. Therefore, low molecular weight heparin prophylaxis is recommended. In this clinical setting (severe colitis), immunotherapy should be discontinued.

Many patients with ICI-induced colitis are treated without prior endoscopy and histology evaluation. Some patients developed IM-microscopic colitis. The treatment of choice for microscopic colitis is budesonide, however, a case-control study comparing IM-microscopic colitis with microscopic colitis showed that patients with IM-microscopic colitis required significantly more systemic CS

or biologic agents.<sup>261</sup> Some data demonstrated a rate of 60% of response to CS in IM-microscopic colitis.<sup>262</sup> Patients with grade 2 IM-microscopic colitis could be treated with budesonide, but patients who do not improve after 1-week or those with grades 3–4 should be treated with CS.<sup>263,264</sup>

### Recommendation 20

We recommended a management based on supportive therapy in patients with grade 1 diarrhea.

**Quality of evidence: low.**

**Recommendation: strong in favor.**

### Recommendation 21

We recommend starting oral CS (0.5–1 mg/kg/d prednisolone oral route) in patients with grade 1 who do not respond to supportive therapy and those with grade 2 diarrhea. In case of response, CS should be tapered over 4–6 weeks.

**Quality of evidence: low.**

**Recommendation: strong in favor.**

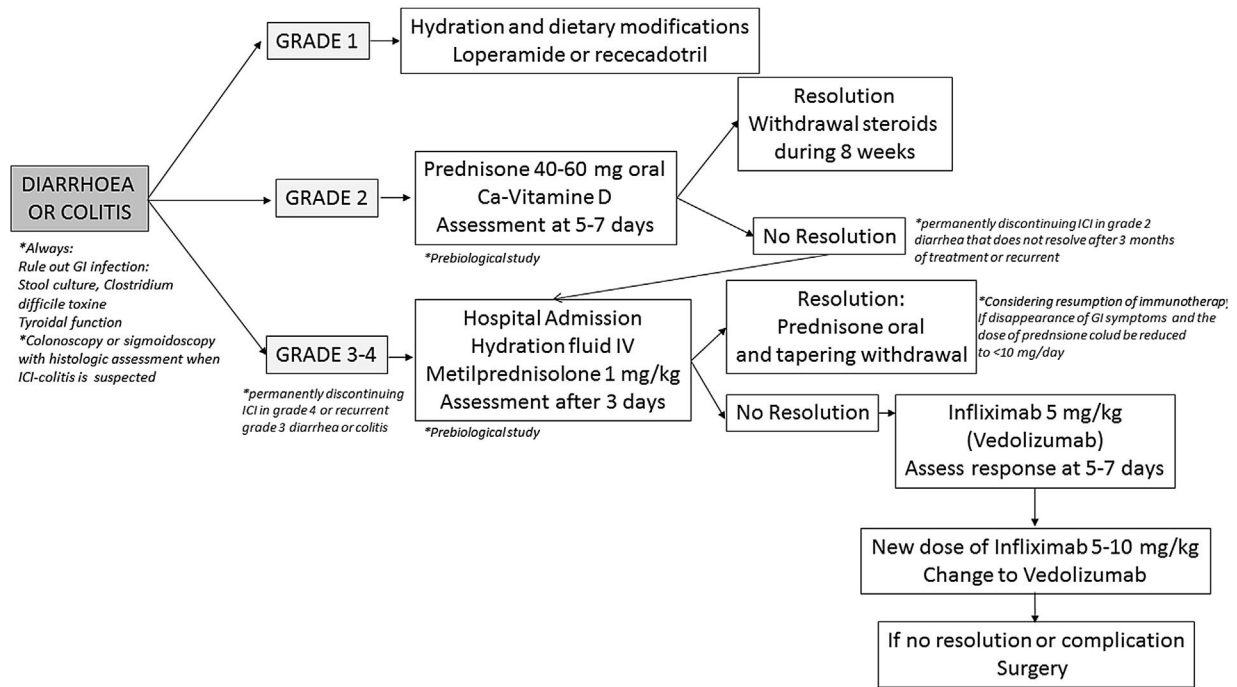
### Recommendation 22

We recommend starting systemic CS (1 mg/kg/d of methylprednisolone intravenously) in patients with grades 3–4 diarrhea-colitis. Patients who respond to intravenous CS within 3–5 days should be switched to the oral form and should be tapered during a period of 8 weeks.

**Quality of evidence: low.**

**Recommendation: strong in favor.**

*Corticosteroid-refractory ICI-induced colitis.* CS-refractory ICI-induced colitis is defined as the persistence of symptoms within 3–5 days of high-dose CS intravenously. Around 30–50% of patients develop CS-refractory ICI-induced colitis and 15–50% of patients relapse during CS tapering.<sup>114,116,119,126,128,255–258,260,262</sup> These patients could be treated with rescue therapies for avoiding serious complications such as perforation and colectomy. In this scenario, more data are available with IFX.<sup>265</sup> IFX use has been associated with a shorter time to resolution and CS titration, without a negative impact on OS or response, although patients who received IFX had more severe enterocolitis than those treated with CS.<sup>112,114,126,157,181,224,256–258,265–273</sup> In this sense, a retrospective study showed a shorter duration of CS use and faster symptoms resolution (median 3 days) in IFX-treated patients compared to CS-treated patients ( $p=0.001$ ).<sup>266</sup> No prospective studies are available to guide IFX dosing, but, due to similarities with IBD, IFX should be started at a dose of 5–10 mg/kg. Most published cases used IFX at the standard dose of 5 mg/kg, except for some cases of partial response in which the subsequent dose was increased to 10 mg/kg.<sup>274</sup> Around 70% of patients achieved response after the first IFX infusion and in most cases the number of IFX infusions did not exceed 3 doses (baseline, day 14, and day 42).<sup>112,115,116,151,211,265–276</sup> Some retrospective data have reported the results of vedolizumab therapy in patients with ICI-induced colitis refractory to CS or IFX.<sup>260,262,277–285</sup> With vedolizumab, clinical remission was obtained in most patients (80%) and improvement was observed after a median of 5 days and sustained at 15



**Figure 2** Proposed management of immune checkpoint inhibitors-induced diarrhea or colitis according to the CTCAE grading.

months. Overall, the median number of vedolizumab infusions was 3, the median interval for symptom resolution was 56 days, with endoscopic and histologic remission achieved in 54% and 29%, respectively.<sup>211,260,262,275,277-284</sup> One of the largest series of ICI-induced colitis refractory to CS treated with vedolizumab showed that 67% of patients who failed previously to IFX attained clinical remission compared with 95% of patients who did not receive IFX.<sup>277</sup> Vedolizumab was also an effective treatment for ICI-induced colitis with microscopic colitis on histology.<sup>262</sup> Vedolizumab is an option in patients who do not respond to IFX or in whom IFX is contraindicated.

Guidelines recommend IFX as first line therapy for patients with ICI-induced colitis and vedolizumab is recommended for IFX refractory patients or when IFX therapy is contraindicated. However, no prospective clinical studies are available to guide the choice of IFX vs. vedolizumab. Based on IBD area, IFX is associated with rapid response, but vedolizumab is linked with a better safety profile.

On the other hand, early introduction of biologic therapy in the treatment algorithm had been associated with a better outcome in a retrospective study of 179 patients with ICI-induced colitis, 84 of them treated with biologics agents. Those patients who received biologic therapy in less than 10 days from colitis onset had fewer hospitalizations ( $p=0.03$ ), shorter CS taper ( $p=0.09$ ), and shorter duration of symptoms ( $p=0.01$ ).<sup>275</sup>

In patients who have not been tested for viral hepatitis prior to the beginning of ICIs in order to assess the risk of reactivation, the performance of HBsAg, anti-HBc and anti-HCV is highly recommended before the administration of monoclonal antibodies, especially IFX.<sup>286,287</sup>

Moreover, in all patients treated with CS, screening for latent tuberculosis infection by means of an interferon-

gamma release assay is highly recommended for the possibility of later refractoriness and need of biological therapy.

**Recommendation 23**

We recommend treatment with Infliximab 5 mg/kg in patients with CS-refractory ICI-induced colitis. If there is no response at 7 days another infusion at week 1 and week 6 is recommended or increase the dose to 10 mg/kg in case of severity.

*Quality of evidence: low.*

*Recommendation: strong in favor.*

**Recommendation 24**

We recommend treatment with vedolizumab (300 mg) in those patients who do not respond to infliximab or in whom infliximab are contraindicated.

*Quality of evidence: low.*

*Recommendation: strong in favor.*

**Recommendation 25**

We recommend that, once clinical remission has been achieved, biological treatment can be discontinued, and CS removed slowly. An extended course of 2-3 months of CS is recommended for those patients with initially severe symptoms. The dose of CS could be reduced to  $\leq 10$  mg per week without the need to add any other maintenance immunosuppressive therapy.

*Quality of evidence: low.*

*Recommendation: strong in favor.*

*Immune-induced colitis-refractory to biological agents.* Patients who do not response to biological agents may



develop a toxic megacolon, an intra-abdominal abscess or a colonic perforation. This situation is very severe, nonetheless it is rare. In case of perforation, surgical intervention should be mandatory (usually a subtotal colectomy with temporal ileostomy). If no response to IFX, vedolizumab or other rescue therapies,<sup>288–292</sup> surgical interventions are indicated.

Anecdotally, some case reports have shown positive outcomes treating ICI-induced colitis refractory to biological agents with conventional immunosuppressants and selective immunosuppressants such as cyclosporine, mycophenolate, tofacitinib and ustekinumab with good results.<sup>260,274,283,284</sup> Fecal microbiota transplantation has been tested in ICI-induced colitis refractory to CS, IFX and vedolizumab. However, further prospective studies are needed to define appropriate candidates and candidate donors.<sup>293</sup>

### Continuation, resumption and withdrawal of immunotherapy in patients with prior ICI-induced colitis

The irAEs that force the withdrawal of ICIs most frequently are diarrhea and colitis.<sup>115</sup> ICIs can be maintained in grade 1 diarrhea and may be continued without any interruption or delay in therapy but should be withheld in grade 2 diarrhea. Overall, discontinuation rates of ICI are approximately 7.5% with anti-PD-1 and 14% with anti-CTLA-4.<sup>114,142</sup> Management after developing an irAE varies depending on the ICIs received. Guidelines recommend considering permanent discontinuation of anti-CTLA-4 agents, due to high incidence of recurrent GI irAEs (44%).<sup>114,142</sup> However, anti-PD-1/PD-L1 drugs can usually be resumed in monotherapy when symptoms are resolved or improve to grade 1 diarrhea, or when CS is tapered to daily doses  $\leq 10$  mg. Biological rescue therapy for initial ICI-induced colitis and a long duration of symptoms was associated with a more likely ICI-induced colitis recurrence after the resumption of ICI therapy.<sup>68,238</sup>

Resumption of immunotherapy can be considered if the following requirements are met: (1) disappearance of gastrointestinal symptoms, (2) the dose of CS can be reduced to  $\leq 10$  mg/d without the need of any other maintenance immunosuppressive therapy and, (3) the benefit of immunotherapy outweighs the potential risks.

Re-treatment with immunotherapy after irAEs can be grouped into four scenarios: (1) class switch (anti-CTLA-4 to anti-PD-1)<sup>294</sup>; (2) resume same agent after recovery from irAE<sup>238</sup>; (3) drop anti-CTLA-4 after irAE with anti-CTLA-4 and anti-PD-1 combination<sup>294</sup>; and (4) sample with a mix of the above attitudes.<sup>68,238</sup> When sequencing or switching from one class of ICI to another, the relatively long half-life of the agents and the duration of T-cell receptor occupancy of up to 2 months should be considered since early exposure to the second ICI may be equivalent to giving these agents in combination with a higher likelihood of inducing irAEs.<sup>295</sup>

On the other hand, ICI should be permanently discontinued in the following cases: (1) diarrhea or grade 4 colitis; (2) recurrent grade 3 diarrhea or colitis and, (3) grade 2 diarrhea that does not resolve after 3 months of treatment. *Risk of GI-toxicity with anti-PD-1 after GI-toxicity due to anti-CTLA-4 (or vice versa).* The risk of immunotherapy withdrawal due to the development of serious irAEs can reach up to 25% of cases in patients treated with anti-CTLA-4.<sup>140</sup> Although it is described that the clinical outcome for

these patients could be favorable without treatment (see treatment section), it would be interesting to know the risk of developing recurrence or onset of GI toxicity “de novo” in patients treated with another subsequent ICI. The incidence of recurrence of the initial irAE or the appearance of a new one is 40–50% in patients re-treated with ICI. The decision of ICI rechallenges after an irAE should be based on the type and severity of the irAE, the previous response to the immunosuppressive treatment, efficacy expectations and therapeutic alternatives. It seems conceivable to rechallenge patients with ICI after recovery from non-severe ICI-induced colitis, and this is an aspect of treatment for which some data are available (two meta-analysis and 11 retrospective studies).<sup>61,67–69,238,294–301</sup> A total of 789 ICI rechallenge cases after toxicity were analyzed and the incidence of irAEs of any grade and grade 3/4 after rechallenge was 34.2% and 11.7%, respectively. Rechallenge compared to initial ICI treatment showed a higher incidence of irAEs, but a similar rate of severe irAEs. Previous GI irAEs and the interval between initial irAEs and ICI reissue were associated with a higher recurrence of high grade irAEs.<sup>296</sup>

For patients initially treated with anti-PD-1/PD-L1, anti-CTLA-4 rechallenge had a significantly higher incidence of irAEs than anti-PD-1/PD-L1 rechallenge, whereas for those initially treated with anti-CTLA-4 or combination, no significant difference existed in the incidence of irAEs in different rechallenged ICIs.

A meta-analysis including 437 patients from 10 studies who were retreated with ICI after irAEs, confirmed an incidence of recurrence of any grade and grade 3/4 irAEs of 47%, and 13.2%, respectively.<sup>297</sup> This incidence is comparable to the historical rate of irAEs in patients with initial ICI while serious events were lower on re-exposure than on previous treatment. The risk of serious irAEs at rechallenge was higher in the subgroup that received combination therapy as the initial regimen.

The study with the largest series is based on cases from the VigiBase, an international pharmacovigilance database.<sup>61</sup> Out of 452 informative rechallenges, the recurrence rate was 29% after anti-PD-1/PD-L1, 47% after anti-CTLA-4, and 43% after combination therapy resumption. One-quarter to one-third of patients had the same irAE, being colitis in 37%. In the multivariate analysis, anti-CTLA-4 regimen, colitis, hepatitis, and pneumonitis initial irAEs were associated with a higher irAE recurrence rate.<sup>61</sup>

Pollack MH et al. evaluated the safety of anti-PD-1 treatment in patients who had prior adverse events (grades 2–4) under combination therapy (ipilimumab plus nivolumab).<sup>67</sup> Out of eighty patients included, diarrhea/colitis was the most previous prevalent event (41%) and required CS and/or immunosuppressive treatment in all cases. The data of recurrence and appearance of colitis “de novo” were similar to those previously reported (6% and 19% respectively). This risk was associated with a short time interval between the adverse event and the start of the second treatment (56 vs. 62 days,  $p=0.03$ ) and the continuation of CS treatment at the time of second line therapy; neither severity nor the need of immunosuppressants were associated with the risk of recurrence. Data from a retrospective study described the evolution of 80 patients who developed GI toxicity due to ICIs and received a second line of treatment (27% grades 3–4).<sup>298</sup> After one year of follow-up, 80% of the patients were free

of the appearance of diarrhea/colitis. Although there was an increased risk of developing colitis in patients who were exposed to anti-CTLA-4 as a second-line treatment, these differences were not significant.

Given that the evidence is scarce and the risk of colitis “de novo” is not negligible, it seems reasonable that the decision to start new lines of immunotherapy treatment is strictly related with the characteristics of the oncological disease and the oncologist’s criteria. There should be close monitoring of potential toxicity.

#### Recommendation 26

We recommend permanently discontinuing ICI in the following cases: diarrhea or grade 4 colitis, recurrent grade 3 diarrhea or colitis or grade 2 diarrhea that does not resolve after 3 months of treatment.

**Quality of evidence: low.**

**Recommendation: strong in favor.**

#### Recommendation 27

We recommend considering the resumption of immunotherapy if the following requirements are met: disappearance of gastrointestinal symptoms, the dose of prednisone could be reduced to  $\leq 10$  mg/d without the need to add any other maintenance immunosuppressive therapy, the benefit of immunotherapy exceeds the potential risks.

**Quality of evidence: low.**

**Recommendation: weak in favor.**

#### Recommendation 28

The introduction of other ICI in patients with prior digestive toxicity secondary to ICI should be balanced by a multidisciplinary team, due to the possible occurrence or diarrhea/colitis.

**Quality of evidence: low.**

**Recommendation: strong in favor.**

#### Prophylactic therapy to decrease the risk of ICI-induced colitis

Only one RCT has evaluated budesonide prophylaxis as a prevention of ICI-induced colitis,<sup>285</sup> however, prophylactic budesonide (9 mg/d orally) did not prevent ipilimumab-induced diarrhea or colitis.<sup>302</sup>

#### Recommendation 29

Prophylactic therapy with budesonide is not recommended to decrease the risk of ICI-induced colitis.

**Quality of evidence: high.**

**Recommendation: strong against.**

#### Prognostic factors: association between ICI-induced colitis risk and anti-PD-1 efficacy

Although immunotherapy increases survival in diverse advanced cancers, it only benefited a subset of patients with no clear evidence of predictive factors beyond PD-

L1 expression or microsatellite instability.<sup>160</sup> The increase in OS in patients developing grades 3–4 ICI-induced colitis is probably a projection of the magnitude of the immune response, reflects the anti-tumor efficacy of ICIs and could be a predictor of survival.<sup>303</sup> Since irAE is not a baseline but a time-dependent event, appropriate statistical methods should be used to compare outcomes in patients with ICI to avoid bias such as time exposition and spurious conclusions.<sup>304</sup>

Two retrospective studies of advanced melanoma patients treated with ICI showed that colitis of any grade was associated with increased OS and improved performance status (PS) scale.<sup>302,304</sup> In 576 nivolumab-treated patients with melanoma (phase I and phase III studies) a significantly higher response rate with no impact on PS was found in patients with irAEs of any grade ( $n = 255$ ) compared to those without.<sup>285</sup> Another phase III trial compared pembrolizumab vs placebo in patients with melanoma, the development of irAEs was associated with a longer recurrence free survival (Hazard Ratio [HR] 0.61, 95% CI: 0.39–0.95,  $p = 0.03$ ).<sup>305</sup>

Between the different irAEs, endocrine, cutaneous and GI were associated with an improve OS, while hepatic and pulmonary irAEs conditioned a poor OS outcome ( $p = 0.001$ ).<sup>306</sup> A pooled analysis of seven trials in 1747 patients with metastatic or locally advanced urothelial cancer that led to approval of an anti-PD-1/PD-L1, found an improvement in OS among patients who developed irAE (HR, 0.53; 95% CI, 0.43–0.66) when adjusted for baseline covariates and for duration of exposure.<sup>307</sup>

The prospective non-interventional ST-ICI trial investigated the prognostic role of irAEs ( $n = 29$ ) in patients with non-melanoma solid cancer treated with anti-PD-L1 alone and in combination with radiotherapy ( $n = 104$ ). OS was higher in patients with vs. without irAEs (22.8 vs 9.0 months,  $p = 0.001$ ). On multivariate analysis, only PD-L1 on tumor cells ( $p = 0.049$ ) and irAEs ( $p = 0.001$ ) remained independent predictors of OS.<sup>308</sup> In a French series of patients with advanced solid tumors treated with ICI ( $n = 410$ ), when defining irAEs as a time-varying covariate and adjusting on potential confounding factors, grade  $\geq 2$  irAEs ( $n = 126$ ) increased OS in the overall population (HR 0.57, 95% CI: 0.43–0.74,  $p < 0.0001$ ) and in patients treated with anti-PD-L1 (HR 0.50, 95% CI: 0.36–0.70,  $p < 0.0001$ ). Regarding types of irAEs, thyroiditis, colitis and rash were statistically significantly associated with better OS.<sup>309</sup>

In a meta-analysis including 30 studies ( $n = 4971$ ), cancer patients who developed irAEs experienced an OS and PS benefit from ICI compared to patients without irAEs (OS: HR 0.54, 95% CI: 0.45–0.65,  $p < 0.001$ ). In sensitivity analysis, the pooled results for OS and PS remained significant indicating that the association between irAE and ICI efficacy was robust. The pooled HR for OS in large studies ( $n > 100$ ) was comparable to the overall effect (0.58 vs 0.54). Notably, neither the Beggfunnel plot nor Egger’s test revealed publication bias for OS, further confirmed the stability of the OS results.<sup>310</sup>

In conclusion, irAEs appear to represent a clinical biomarker for response to ICI, although the true nature of this association is unknown and does not appear to be due to exposure time bias.

**Statement 12**

Immuno-related adverse events have a prognostic role for the response to ICI, although the true nature of this association is unknown.

**Quality of evidence: low.**

**Immunotherapy toxicity in the upper digestive tract**

Although the literature is scarce, and the scientific evidence is mostly poor quality (many case reports and two retrospective series), it shows that immunotherapy can affect the upper gastrointestinal tract, mainly at the gastric level. One of the first reports of upper digestive involvement was published by Beck KE et al. describing the cases of enterocolitis caused by ipilimumab in 137 patients with melanoma. Cases were identified by suggestive symptoms and compatible endoscopic/histological involvement. Sixteen of the 41 patients diagnosed with enterocolitis had also undergone gastroscopy, of which 10/16 presented macroscopic alterations and 14/16 histological alterations.<sup>115</sup> Cheung V et al. publish data on the incidence of gastritis associated with the use of anti-PD-1/PD-L1 or in combination with anti-CTLA-4 in a hospital setting. Of the 205 patients included, 11 (5.4%) developed gastritis.<sup>311</sup> Finally, Tang T et al. published data on upper gastrointestinal involvement in a retrospective, single-center series of 4716 patients treated with different lines of immunotherapy. One percent of the patients ( $n = 60$ ) were diagnosed with upper gastrointestinal involvement through endoscopic or histological confirmation, within these, 48% had received treatment with anti-PD-1, 33% anti-CTLA-4 and 18% on combination therapy.<sup>312</sup>

Despite limited published data, it is likely that upper digestive involvement is underdiagnosed because the symptoms it produces are nonspecific, they may scarcely be reported by patients and little suspected by clinicians. Symptoms associated with digestive toxicity include nausea/vomiting (78%), abdominal pain (28%), hyporexia and weight loss or upper gastrointestinal bleeding (hematemesis/melena) in up to 18% of cases. It is important to note that many patients may present symptoms of associated diarrhea/colitis (68%) with endoscopic and histological involvement in the upper and lower digestive tracts (35%).<sup>312,313</sup> The time to onset can also be variable, with a median time of 3 months (range 1–8).<sup>312</sup> There are also published cases of late onset.<sup>92,314</sup>

Although there is grading of the severity of gastritis within the CTCAE classification, this classification has not been used in any study, nor are there any recommendations about its use in clinical practice.<sup>137</sup>

There are no recommendations for establishing the diagnosis of ICI-induced gastritis. Considering that upper gastrointestinal involvement presents nonspecific symptoms, it is important to perform a diagnostic study that includes an esophagogastroduodenoscopy with taking biopsies in all segments. In published series, endoscopic involvement can occur in 68–77% of cases with the presence of erythema, erosions, ulcerations, exudates or mucosal atrophy. The most frequent form of presentation could be

gastritis without ulcerations (56.7%). In the study by Tang T et al. the presence of ulcerations was more frequent in patients who received anti-PD-1 when compared with anti-CTLA-4 (21% vs 5%). The predominant involvement was gastric (57%), followed by duodenal (45%) or gastroduodenal (14%).<sup>312</sup> There are two case reports published with esophageal involvement.<sup>315,316</sup>

Histological findings are important for differential diagnosis with other disorders and when there are no endoscopic changes. Histological alterations can appear in 83–100% of cases, even with no endoscopic involvement and duodenal changes can be less prevalent than gastric ones (38%).<sup>312</sup> Johncilla M et al. analyzed specifically histological patterns. The most common presentation was the presence of active and diffuse chronic gastritis with lymphoplasmacytic infiltrate in the lamina propria together with the presence of apoptosis and the second one was gastritis with focal enhancement and neutrophilic infiltration of the glandular epithelium.<sup>313–316</sup> There are published cases of CMV superinfection which makes it important to perform biopsies in these patients.<sup>317,318</sup>

Therapeutic management of upper GI toxicity is not well established and there are no recommendations in different clinical guidelines. In the largest series ( $n = 60$  patients), 89% received treatment with PPIs and anti-H2; although there are no data regarding clinical response to this therapy, 42% required CS treatment, 22% IFX, and 15% vedolizumab. Either data on response to CS or biological therapy were reported, although a relapse rate of 15% was documented. As an interesting data, the percentage of patients who required biological therapy was higher when they had upper and lower digestive involvement in comparison with those with isolated lower tract involvement (62% vs 6%).<sup>312</sup> In the series by Johncilla M et al. 10 of the 12 patients were treated with CS and two with IFX (one of them due to CS failure), in the follow-up (range 1–37 months) 9 of the 10 patients responded to the initial treatment, but there were 3 relapses. However, in most, the immunotherapy was able to be reintroduced.<sup>313</sup> Obviously, larger prospective studies are needed to investigate upper GI tract irAEs to include this toxicity in clinical guidelines and provide help to physicians for treatment management.

Likewise, there are few cases of pancreatic injury due to immunotherapy, ranging from asymptomatic hyperamylasemia to symptomatic acute pancreatitis.<sup>319,320</sup> PD-1 inhibitors have been associated with a significant higher risk of pancreatic irAEs compared with anti-PD-L1 agents and those undergoing combined ICI therapy have a significant higher risk compared to subjects undergoing single ICI therapy.<sup>320</sup>

**Statement 13**

GI toxicity secondary to ICI can involve upper tract, mainly gastric area. Main clinical manifestations include nausea/vomiting and/or abdominal pain. Upper endoscopy with biopsies is required for diagnosis. Therapeutic management is not well established and includes PPIs, CS and biological therapy for refractory cases.

**Quality of evidence: low.**



## Funding statement

This research received no specific grant from any funding agency in the public, commercial, or not-for-profit sectors.

## Conflict of interest

MRB has received research educational and/or travel grants from Gilead and has served as a speaker for Gilead and GSK; ADG has received travel grants from Intercept/Advanzpharma. Speaker for Intercept/Advanzpharma. Consultant or advisory role for GlaxoSmithKline and IPSEN; MM has served as a speaker, advisory member or has received research funding from Takeda, Abbvie, Janssen, Pfizer, TillottsPharma and Faes; JGP has acted as consultant or advisory role for AAA, Amgen, Bayer, BMS, Eisai, Ipsen, Lilly, Merck, MSD, Pierre-Fabre, Roche, Servier, VeracYTE. Research funding: Astellas, AstraZeneca, BMS, Daiichi-Sankyo, Lilly, Servier. Speaker role: AAA, Amgen, Bayer, BMS, Ipsen, Lilly, Merck, Novartis, Servier. Educational activities: Amgen, Ipsen, Merck, Novartis, Pierre-Fabre, Roche; MV: lecture fees, consulting work, travel support and congress registration: Astra-Zeneca, Eisai-MSD, Roche; LM received unrestricted grants from MSD and Abbvie, and served as advisory board member and/or speaker for MSD, Abbvie, Pfizer, Janssen, Takeda, Biogen, Tillotts, Dr. Falk Pharma, Ferring, Medtronic and General Electric; BS reports consultancy fees from Adaptimmune, Astra Zeneca, Bayer, BMS, Boston Scientific, Eisai, Eli Lilly, Incyte, Ipsen, Novartis, MSD, Roche, Sanofi, Sirtex Medical, Terumo; speaker fees from Astra Zeneca, Bayer, BMS, Eisai, Eli Lilly, Incyte, Ipsen, Novartis, Roche, Sirtex Medical, Terumo; research grants (to Institution) from BMS and Sirtex Medical; AFM has received grants as invited speaker for BMS, MSD and Roche; MARG has received research educational and/or travel grants from GORE and has served as a speaker for GORE; FR: Consultant or Advisory Role: Roche, Merck-Serono, Amgen, MSD, BMS, Lilly, Celgene, Sanofi-Aventis, Servier, Astra-Zeneca, Bayer, Atellas; Research Funding: Roche, Merck-Serono, Amgen, MSD, Lilly, Celgene, Sanofi-Aventis, Servier, Bayer. Speaking: Roche, Merck-Serono, Amgen, MSD, BMS, Lilly, Celgene, Sanofi-Aventis, Servier, Bayer; Grant support: Amgen; MCL has received travel grants from Intercept/Advanz pharma. Speaker for Intercept/Advanz pharma. Consultant or advisory role for Intercept/Advanz pharma, GlaxoSmithKline and IPSEN.

The rest of authors have no conflict of interest to declare.

## Acknowledgements

English writing support was provided by Fidelma Greaves.

## Appendix A. Supplementary material

Supplementary material associated with this article can be found in the online version available at <https://doi.org/10.1016/j.gastrohep.2023.10.009>.

## References

- Martins F, Sofiya L, Sykietis GP, Lamine F, Maillard M, Fraga M, et al. Adverse effects of immune-checkpoint inhibitors: epidemiology, management and surveillance. *Nat Rev Clin Oncol*. 2019;16:563–80.
- Aguayo-Albasini JL, Flores-Pastor B, Soria-Aledo V. GRADE system: classification of quality of evidence and strength of recommendation. *Cir Esp*. 2014;92:82–8.
- De Martin E, Michot JM, Rosmorduc O, Guettier C, Samuel D. Liver toxicity as a limiting factor to the increasing use of immune checkpoint inhibitors. *JHEP Rep: Innov Hepatol*. 2020;2:100170.
- Ascierto PA, Del Vecchio M, Mandalá M, Gogas H, Arance AM, Dalle S, et al. Adjuvant nivolumab versus ipilimumab in resected stage IIIB-C and stage IV melanoma (CheckMate 238): 4-year results from a multicentre, double-blind, randomised, controlled, phase 3 trial. *Lancet Oncol*. 2020;21:1465–77.
- Dougan M, Wang Y, Rubio-Tapia A, Lim JK. AGA clinical practice update on diagnosis and management of immune checkpoint inhibitor colitis and hepatitis: expert review. *Gastroenterology*. 2021;160:1384–93.
- De Martin E, Michot JM, Papouin B, Champiat S, Mateus C, Lambotte O, et al. Characterization of liver injury induced by cancer immunotherapy using immune checkpoint inhibitors. *J Hepatol*. 2018;68:1181–90.
- Wang DY, Salem JE, Cohen JV, Chandra S, Menzer C, Ye F, et al. Fatal toxic effects associated with immune checkpoint inhibitors: a systematic review and meta-analysis. *JAMA Oncol*. 2018;4:1721–8.
- Weissman S, Saleem S, Sharma S, Krupka M, Inayat F, Aziz M, et al. Incidence, mortality, and risk factors of immunotherapy-associated hepatotoxicity: a nationwide hospitalization analysis. *Liver Res*. 2021;5:28–32.
- Fu J, Li WZ, McGrath NA, Lai CW, Brar G, Xiang YQ, et al. Immune checkpoint inhibitor associated hepatotoxicity in primary liver cancer versus other cancers: a systematic review and meta-analysis. *Front Oncol*. 2021;11:650292.
- Cunningham M, Iafolla M, Kanjanapan Y, Cerocchi O, Butler M, Siu LL, et al. Evaluation of liver enzyme elevations and hepatotoxicity in patients treated with checkpoint inhibitor immunotherapy. *PLOS ONE*. 2021;16:e0253070.
- Chen C, Wu B, Zhang C, Xu T. Immune-related adverse events associated with immune checkpoint inhibitors: an updated comprehensive disproportionality analysis of the FDA adverse event reporting system. *Int Immunopharmacol*. 2021;95:107498.
- Institute USDoHaHSNNC. Common Terminology Criteria for Adverse Events (CTCAE) version 4.03.
- Pu D, Yin L, Zhou Y, Li W, Huang L, Cai L, et al. Safety and efficacy of immune checkpoint inhibitors in patients with HBV/HCV infection and advanced-stage cancer: a systematic review. *Medicine (Baltimore)*. 2020;99:e19013.
- Finn RS, Qin S, Ikeda M, Galle PR, Ducreux M, Kim TY, et al. Atezolizumab plus bevacizumab in unresectable hepatocellular carcinoma. *N Engl J Med*. 2020;382:1894–905.
- Duffy AG, Ulahannan SV, Makorova-Rusher O, Rahma O, Wedemeyer H, Pratt D, et al. Tremelimumab in combination with ablation in patients with advanced hepatocellular carcinoma. *J Hepatol*. 2017;66:545–51.
- El-Khoueiry AB, Sangro B, Yau T, Crocenzi TS, Kudo M, Hsu C, et al. Nivolumab in patients with advanced hepatocellular carcinoma (CheckMate 040): an open-label, non-comparative, phase 1/2 dose escalation and expansion trial. *Lancet (Lond, Engl)*. 2017;389:2492–502.
- Yau T, Kang YK, Kim TY, El-Khoueiry AB, Santoro A, Sangro B, et al. Efficacy and safety of nivolumab plus ipilimumab in

- patients with advanced hepatocellular carcinoma previously treated with sorafenib: the CheckMate 040 randomized clinical trial. *JAMA Oncol.* 2020;6:e204564.
18. Kelley RK, Sangro B, Harris W, Ikeda M, Okusaka T, Kang YK, et al. Safety, efficacy, and pharmacodynamics of tremelimumab plus durvalumab for patients with unresectable hepatocellular carcinoma: randomized expansion of a phase I/II study. *J Clin Oncol.* 2021;39:2991–3001.
  19. Finn RS, Ryoo BY, Merle P, Kudo M, Bouattour M, Lim HY, et al. Pembrolizumab as second-line therapy in patients with advanced hepatocellular carcinoma in KEYNOTE-240: a randomized, double-blind, phase III trial. *J Clin Oncol.* 2020;38:193–202.
  20. Gutiérrez-Larrañaga M, González-López E, Roa-Bautista A, Rodrigues PM, Díaz-González Á, Banales JM, et al. Immune checkpoint inhibitors: the emerging cornerstone in cholangiocarcinoma therapy? *Liver Cancer.* 2021;10:545–60.
  21. Zeng FL, Chen JF. Application of immune checkpoint inhibitors in the treatment of cholangiocarcinoma. *Technol Cancer Res Treat.* 2021;20, 15330338211039952.
  22. Oh D, He A, Qin S, Chen L, Okusaka T, Vogel A, et al. A phase 3 randomized, double-blind, placebo-controlled study of durvalumab in combination with gemcitabine plus cisplatin (GemCis) in patients (pts) with advanced biliary tract cancer (BTC): TOPAZ-1. *J Clin Oncol.* 2022;40(4 Suppl):378.
  23. Kelley RK, Ueno M, Yoo C, Finn RS, Furuse J, Ren Z, et al. Pembrolizumab in combination with gemcitabine and cisplatin compared with gemcitabine and cisplatin alone for patients with advanced biliary tract cancer (KEYNOTE-966): a randomised, double-blind, placebo-controlled, phase 3 trial. *Lancet (Lond, Engl).* 2023;401:1853–65.
  24. Ioka T, Ueno M, Oh D, Fujiwara Y, Chen J, Doki Y, et al. Evaluation of safety and tolerability of durvalumab (D) with or without tremelimumab (T) in patients (pts) with biliary tract cancer (BTC). *J Clin Oncol.* 2019;37:387.
  25. EASL Clinical Practice Guidelines: drug-induced liver injury. *J Hepatol.* 2019;70:1222–61.
  26. Brahmer JR, Lacchetti C, Schneider BJ, Atkins MB, Brassil KJ, Caterino JM, et al. Management of immune-related adverse events in patients treated with immune checkpoint inhibitor therapy: American Society of Clinical Oncology Clinical Practice Guideline. *J Clin Oncol.* 2018;36:1714–68.
  27. Haanen J, Carbone F, Robert C, Kerr KM, Peters S, Larkin J, et al. Management of toxicities from immunotherapy: ESMO Clinical Practice Guidelines for diagnosis, treatment and follow-up. *Ann Oncol.* 2017;28:iv119–42.
  28. Sangro B, Chan SL, Meyer T, Reig M, El-Khoueiry A, Galle PR. Diagnosis and management of toxicities of immune checkpoint inhibitors in hepatocellular carcinoma. *J Hepatol.* 2020;72:320–41.
  29. Danan G, Benichou C. Causality assessment of adverse reactions to drugs – I. A novel method based on the conclusions of international consensus meetings: application to drug-induced liver injuries. *J Clin Epidemiol.* 1993;46:1323–30.
  30. Hayashi PH, Lucena MI, Fontana RJ, Bjornsson ES, Aithal GP, Barnhart H, et al. A revised electronic version of RUCAM for the diagnosis of DILI. *Hepatology (Baltimore, Md).* 2022;76:18–31.
  31. Londoño MC, Reig M. RETOINMUNO multidisciplinary clinical approach to cancer patients with immune-related adverse events induced by checkpoint inhibitors. *Cancers.* 2020;12:3446.
  32. Tsung I, Dolan R, Lao CD, Fecher L, Riggenbach K, Yeboah-Korang A, et al. Liver injury is most commonly due to hepatic metastases rather than drug hepatotoxicity during pembrolizumab immunotherapy. *Aliment Pharmacol Therap.* 2019;50:800–8.
  33. Rodriguez-Frias EA, Lee WM. Cancer chemotherapy II: atypical hepatic injuries. *Clin Liver Dis.* 2007;11:663–76, viii.
  34. Bahirwani R, Reddy KR. Drug-induced liver injury due to cancer chemotherapeutic agents. *Semin Liver Dis.* 2014;34:162–71.
  35. Riveiro-Barciela M, González-Sans D, Marmolejo D, Salcedo MT, Muñoz-Couselo E. Hepatic sinusoidal obstruction syndrome associated with nivolumab: an uncommon adverse event related to immune checkpoint inhibitors. *J Gastrointest Liver Dis.* 2021;30:171–2.
  36. Charvet E, Lheure C, Isnard C, Franck N, Kramkimel N, Vallet-Pichard A, et al. Hepatic sinusoidal obstruction syndrome induced by nivolumab in advanced melanoma: a case report. *Ann Oncol.* 2020;31:661–2.
  37. Gonzalez-Cao M, Puertolas T, Riveiro M, Muñoz-Couselo E, Ortiz C, Paredes R, et al. Cancer immunotherapy in special challenging populations: recommendations of the Advisory Committee of Spanish Melanoma Group (GEM). *J Immunother Cancer.* 2021:9.
  38. Zhang X, Zhou Y, Chen C, Fang W, Cai X, Zhang X, et al. Hepatitis B virus reactivation in cancer patients with positive Hepatitis B surface antigen undergoing PD-1 inhibition. *J Immunother Cancer.* 2019;7:322.
  39. Aceituno L, Bañares J, Ruiz-Ortega L, Callejo-Pérez A, Muñoz-Couselo E, Ortiz-Velez C, et al. The low incidence of viral hepatitis reactivation among subjects on immunotherapy reduces the impact of suboptimal screening rate. *Front Med.* 2022;9:916213.
  40. Bataller R, Cabezas J, Aller R, Ventura-Cots M, Abad J, Albillos A, et al. Alcohol-related liver disease. Clinical practice guidelines. Consensus document sponsored by AEEH. *Gastroenterol Hepatol.* 2019;42:657–76.
  41. EASL Clinical Practice Guidelines: autoimmune hepatitis. *J Hepatol.* 2015;63:971–1004.
  42. Zen Y, Yeh MM. Hepatotoxicity of immune checkpoint inhibitors: a histology study of seven cases in comparison with autoimmune hepatitis and idiosyncratic drug-induced liver injury. *Mod Pathol.* 2018;31:965–73.
  43. Gauci ML, Baroudjian B, Zeboulon C, Pages C, Poté N, Roux O, et al. Immune-related hepatitis with immunotherapy: are corticosteroids always needed? *J Hepatol.* 2018;69:548–50.
  44. Peeraphatdit TB, Wang J, Odenwald MA, Hu S, Hart J, Charlton MR. Hepatotoxicity from immune checkpoint inhibitors: a systematic review and management recommendation. *Hepatology (Baltimore, Md).* 2020;72:315–29.
  45. Dearden H, Au L, Wang DY, Zimmer L, Eroglu Z, Smith JL, et al. Hyperacute toxicity with combination ipilimumab and anti-PD1 immunotherapy. *Eur J Cancer (Oxf, Engl: 1990).* 2021;153:168–78.
  46. Cheung V, Gupta T, Payne M, Middleton MR, Collier JD, Simmons A, et al. Immunotherapy-related hepatitis: real-world experience from a tertiary centre. *Frontline Gastroenterol.* 2019;10:364–71.
  47. Bajwa R, Cheema A, Khan T, Amirpour A, Paul A, Chaughtai S, et al. Adverse effects of immune checkpoint inhibitors (programmed death-1 inhibitors and cytotoxic T-lymphocyte-associated protein-4 inhibitors): results of a retrospective study. *J Clin Med Res.* 2019;11:225–36.
  48. Sanz-Segura P, García-Cámara P, Fernández-Bonilla E, Arbonés-Mainar JM, Bernal Monterde V. Gastrointestinal and liver immune-related adverse effects induced by immune checkpoint inhibitors: a descriptive observational study. *Gastroenterol Hepatol.* 2021;44:261–8.
  49. Gauci ML, Baroudjian B, Bédérède U, Zeboulon C, Delyon J, Allayous C, et al. Severe immune-related hepatitis induced by immune checkpoint inhibitors: clinical features and management proposal. *Clin Res Hepatol Gastroenterol.* 2021;45:101491.



50. Patrinely JR Jr, McGuigan B, Chandra S, Fenton SE, Chowdhary A, Kennedy LB, et al. A multicenter characterization of hepatitis associated with immune checkpoint inhibitors. *Oncoimmunology*. 2021;10:1875639.
51. Riveiro-Barciela M, Trallero-Araguás E, Martínez-Valle F. Toxicities from immunotherapy: from clinical trials to real-world clinical practice. *Med Clin (Barc)*. 2020;155:541–7.
52. Sawada K, Hayashi H, Nakajima S, Hasebe T, Fujiya M, Okumura T. Non-alcoholic fatty liver disease is a potential risk factor for liver injury caused by immune checkpoint inhibitor. *J Gastroenterol Hepatol*. 2020;35:1042–8.
53. Romanski NA, Holmstroem RB, Ellebaek E, Svane IM. Characterization of risk factors and efficacy of medical management of immune-related hepatotoxicity in real-world patients with metastatic melanoma treated with immune checkpoint inhibitors. *Eur J Cancer (Oxf, Engl: 1990)*. 2020;130:211–8.
54. Miller ED, Abu-Sbeih H, Styskel B, Nogueras Gonzalez GM, Blechacz B, Naing A, et al. Clinical characteristics and adverse impact of hepatotoxicity due to immune checkpoint inhibitors. *Am J Gastroenterol*. 2020;115:251–61.
55. Riveiro-Barciela M, Barreira-Díaz A, Salcedo M, Callejo-Pérez A, Muñoz-Couselo E, Irazo P, et al. A two-step algorithm avoids corticosteroids in two-thirds of cancer patients with severe immune-mediated hepatitis due to immune checkpoint inhibitors. *J Hepatol*. 2023;78.
56. Chmiel KD, Suan D, Liddle C, Nankivell B, Ibrahim R, Bautista C, et al. Resolution of severe ipilimumab-induced hepatitis after antithymocyte globulin therapy. *J Clin Oncol*. 2011;29:e237–40.
57. Riveiro-Barciela M, Muñoz-Couselo E, Fernandez-Sojo J, Diaz-Mejia N, Parra-López R, Buti M. Acute liver failure due to immune-mediated hepatitis successfully managed with plasma exchange: new settings call for new treatment strategies? *J Hepatol*. 2019;70:564–6.
58. Manns MP, Woynarowski M, Kreisel W, Lurie Y, Rust C, Zuckerman E, et al. Budesonide induces remission more effectively than prednisone in a controlled trial of patients with autoimmune hepatitis. *Gastroenterology*. 2010;139:1198–206.
59. Brattsand R. Overview of newer glucocorticosteroid preparations for inflammatory bowel disease. *Can J Gastroenterol Hepatol*. 1990;4:407–14.
60. Vollmer O, Felten R, Mertz P, Lebrun-Vignes B, Salem JE, Arnaud L. Characterization of auto-immune hepatitis associated with the use of anti-TNF $\alpha$  agents: an analysis of 389 cases in VigiBase. *Autoimmunity Rev*. 2020;19:102460.
61. Dolladille C, Ederhy S, Sassié M, Cautela J, Thuny F, Cohen AA, et al. Immune checkpoint inhibitor rechallenge after immune-related adverse events in patients with cancer. *JAMA Oncol*. 2020;6:865–71.
62. Bouhlel L, Doyen J, Chamorey E, Poudenx M, Ilie M, Gal J, et al. Occurrence and number of immune-related adverse events are independently associated with survival in advanced non-small-cell lung cancer treated by nivolumab. *Bull Cancer (Paris)*. 2020;107:946–58.
63. Das S, Johnson DB. Immune-related adverse events and anti-tumor efficacy of immune checkpoint inhibitors. *J Immunother Cancer*. 2019;7:306.
64. Shimozaki K, Sukawa Y, Beppu N, Kurihara I, Suzuki S, Mizuno R, et al. Multiple immune-related adverse events and anti-tumor efficacy: real-world data on various solid tumors. *Cancer Manage Res*. 2020;12:4585–93.
65. Ziemer M, Koukouliti E, Beyer S, Simon JC, Berg T. Managing immune checkpoint-inhibitor-induced severe autoimmune-like hepatitis by liver-directed topical steroids. *J Hepatol*. 2017;66:657–9.
66. Spain L, Walls G, Messiou C, Turajlic S, Gore M, Larkin J. Efficacy and toxicity of rechallenge with combination immune checkpoint blockade in metastatic melanoma: a case series. *Cancer Immunol Immunother*. 2017;66:113–7.
67. Pollack MH, Betof A, Dearden H, Rapazzo K, Valentine I, Brohl AS, et al. Safety of resuming anti-PD-1 in patients with immune-related adverse events (irAEs) during combined anti-CTLA-4 and anti-PD1 in metastatic melanoma. *Ann Oncol*. 2018;29:250–5.
68. Santini FC, Rizvi H, Plodkowski AJ, Ni A, Lacouture ME, Gambarin-Gelwan M, et al. Safety and efficacy of re-treating with immunotherapy after immune-related adverse events in patients with NSCLC. *Cancer Immunol Res*. 2018;6:1093–9.
69. Simonaggio A, Michot JM, Voisin AL, Le Pavec J, Collins M, Lallart A, et al. Evaluation of readministration of immune checkpoint inhibitors after immune-related adverse events in patients with cancer. *JAMA Oncol*. 2019;5:1310–7.
70. Riveiro-Barciela M, Barreira-Díaz A, Vidal-González J, Muñoz-Couselo E, Martínez-Valle F, Viladomiu L, et al. Immune-related hepatitis related to checkpoint inhibitors: clinical and prognostic factors. *Liver Internatl*. 2020;40:1906–16.
71. Li M, Sack JS, Rahma OE, Hodi FS, Zucker SD, Grover S. Outcomes after resumption of immune checkpoint inhibitor therapy after high-grade immune-mediated hepatitis. *Cancer*. 2020;126:5088–97.
72. Riveiro-Barciela M, Barreira-Díaz A, Callejo-Pérez A, Muñoz-Couselo E, Díaz-Mejía N, Díaz-González Á, et al. Retreatment with immune checkpoint inhibitors after a severe immune-related hepatitis: results from a prospective multicenter study. *Clin Gastroenterol Hepatol*. 2023;21:732–40.
73. Onoyama T, Takeda Y, Yamashita T, Hamamoto W, Sakamoto Y, Koda H, et al. Programmed cell death-1 inhibitor-related sclerosing cholangitis: a systematic review. *World J Gastroenterol*. 2020;26:353–65.
74. Björnsson ES, Andrade RJ. Long-term sequelae of drug-induced liver injury. *J Hepatol*. 2022;76:435–45.
75. Scoazec JY. Drug-induced bile duct injury: new agents, new mechanisms. *Curr Opin Gastroenterol*. 2022;38:83–8.
76. Kashima J, Okuma Y, Shimizuguchi R, Chiba K. Bile duct obstruction in a patient treated with nivolumab as second-line chemotherapy for advanced non-small-cell lung cancer: a case report. *Cancer Immunol Immunother*. 2018;67:61–5.
77. Pi B, Wang J, Tong Y, Yang Q, Lv F, Yu Y. Immune-related cholangitis induced by immune checkpoint inhibitors: a systematic review of clinical features and management. *Eur J Gastroenterol Hepatol*. 2021;33:e858–67.
78. Koya Y, Shibata M, Shinohara N, Nebuya S, Oe S, Honma Y, et al. Secondary sclerosing cholangitis with hemobilia induced by pembrolizumab: case report and review of published work. *Hepatol Res*. 2019;49:950–6.
79. Mizuno K, Ito T, Ishigami M, Ishizu Y, Kuzuya T, Honda T, et al. Real world data of liver injury induced by immune checkpoint inhibitors in Japanese patients with advanced malignancies. *J Gastroenterol*. 2020;55:653–61.
80. Suda T, Kobayashi M, Kurokawa K, Matsushita E. Simultaneous occurrence of autoimmune pancreatitis and sclerosing cholangitis as immune-related adverse events of pembrolizumab. *BMJ Case Rep*. 2021:14.
81. Fujii M, Ozato T, Mizukawa S, Nasu J, Kawai H, Fujioka SI, et al. A rare case of immunotherapy-induced cholangitis and gastritis. *Clin J Gastroenterol*. 2020;13:1083–90.
82. Nabeshima S, Yamasaki M, Matsumoto N, Takaki S, Nishi Y, Kawamoto K, et al. Atezolizumab-induced sclerosing cholangitis in a patient with lung cancer: a case report. *Cancer Treat Res Commun*. 2021;26:100270.
83. Gelsomino F, Vitale G, Ardizzoni A. A case of nivolumab-related cholangitis and literature review: how to look for the right tools for a correct diagnosis of this rare immune-related adverse event. *Invest New Drugs*. 2018;36:144–6.

84. Tahboub Amawi AD, Tremaine WJ, Venkatesh SK. Pembrolizumab-induced sclerosing cholangitis. *Clin Gastroenterol Hepatol.* 2022;20:e18.
85. Williams H, Aitchison R. Pembrolizumab-induced autoimmune haemolytic anaemia and cholangitis. *BMJ Case Rep.* 2019;12.
86. Yoshikawa Y, Imamura M, Yamaoka K, Kosaka Y, Murakami E, Morio K, et al. A case with life-threatening secondary sclerosing cholangitis caused by nivolumab. *Clin J Gastroenterol.* 2021;14:283–7.
87. Talbot S, MacLaren V, Lafferty H. Sclerosing cholangitis in a patient treated with nivolumab. *BMJ Case Rep.* 2021;14:e241700.
88. Izumi H, Kodani M, Kurai J, Takeda K, Okazaki R, Yamane K, et al. Nivolumab-induced cholangitis in patients with non-small cell lung cancer: case series and a review of literature. *Mol Clin Oncol.* 2019;11:439–46.
89. Hirasawa Y, Yoshimura K, Matsui H, Kubota Y, Ishida H, Arai J, et al. A case report on severe nivolumab-induced adverse events similar to primary sclerosing cholangitis refractory to immunosuppressive therapy. *Medicine (Baltimore).* 2021;100:e25774.
90. Hamoir C, de Vos M, Clinckart F, Nicaise G, Komuta M, Lanthier N. Hepatobiliary and pancreatic: nivolumab-related cholangiopathy. *J Gastroenterol Hepatol.* 2018;33:1695.
91. Sato K, Hayashi M, Abe K, Fujita M, Takahashi A, Ohira H. Pembrolizumab-induced sclerosing cholangitis in a lung adenocarcinoma patient with a remarkable response to chemotherapy: a case report. *Clin J Gastroenterol.* 2020;13:1310–4.
92. Călugăreanu A, Rompteaux P, Bohelay G, Goldfarb L, Barrau V, Cucherousset N, et al. Late onset of nivolumab-induced severe gastroduodenitis and cholangitis in a patient with stage IV melanoma. *Immunotherapy.* 2019;11:1005–13.
93. Sawada K, Shonaka T, Nishikawa Y, Hasegawa K, Hayashi H, Hasebe T, et al. Successful treatment of nivolumab-related cholangitis with prednisolone: a case report and review of the literature. *Intern Med (Tokyo, Japan).* 2019;58:1747–52.
94. Ogawa K, Kamimura K, Terai S. Antiprogrammed cell death-1 immunotherapy-related secondary sclerosing cholangitis. *Hepatology (Baltimore, Md).* 2019;69:914–6.
95. Stuart L, Lambourne B, Turner P, Jones DEJ, Plummer R, Cresti N, et al. Pembrolizumab as a cause of cholangiopathy in a patient with metastatic melanoma. *Hepatology (Baltimore, Md).* 2020;71:2164–6.
96. Anderson B, Dawe DE. Nivolumab-induced secondary sclerosing cholangitis with deterioration despite immunosuppression. *J Thorac Oncol.* 2019;14:e205–6.
97. Gelsomino F, Vitale G, D'Errico A, Bertuzzi C, Andreone P, Ardizzoni A. Nivolumab-induced cholangitic liver disease: a novel form of serious liver injury. *Ann Oncol.* 2017;28:671–2.
98. Vitale G, Lamberti G, Comito F, Di Nunno V, Massari F, Morelli MC, et al. Anti-programmed cell death-1 and anti-programmed cell death ligand-1 immune-related liver diseases: from clinical pivotal studies to real-life experience. *Expert Opin Biol Ther.* 2020;20:1047–59.
99. Takinami M, Ono A, Kawabata T, Mamesaya N, Kobayashi H, Omori S, et al. Comparison of clinical features between immune-related sclerosing cholangitis and hepatitis. *Invest New Drugs.* 2021;39:1716–23.
100. Zen Y, Yeh MM. Checkpoint inhibitor-induced liver injury: a novel form of liver disease emerging in the era of cancer immunotherapy. *Semin Diagn Pathol.* 2019;36:434–40.
101. Kawakami H, Tanizaki J, Tanaka K, Haratani K, Hayashi H, Takeda M, et al. Imaging and clinicopathological features of nivolumab-related cholangitis in patients with non-small cell lung cancer. *Invest New Drugs.* 2017;35:529–36.
102. Zen Y, Chen YY, Jeng YM, Tsai HW, Yeh MM. Immune-related adverse reactions in the hepatobiliary system: second-generation check-point inhibitors highlight diverse histological changes. *Histopathology.* 2020;76:470–80.
103. Gourari K, Catherine J, Garaud S, Kerger J, Lepida A, Georgala A, et al. A rare case of hepatic vanishing bile duct syndrome occurring after combination therapy with nivolumab and cabozantinib in a patient with renal carcinoma. *Diagnostics (Basel, Switzerland).* 2022;12:539.
104. Zhong YY, McLean L, Buckle A, Siva S, Tran B. Vanishing bile duct syndrome associated with pazopanib after progression on pembrolizumab. *Can J Urol.* 2020;27:10339–41.
105. Gemelli M, Carbone M, Abbate MI, Mancin M, Zucchini N, Colonese F, et al. Vanishing bile duct syndrome following pembrolizumab infusion: case report and review of the literature. *Immunotherapy.* 2022;14:175–81.
106. Moi L, Bouchaab H, Mederos N, Nguyen-Ngoc T, Perreau M, Fenwick C, et al. Personalized cytokine-directed therapy with tocilizumab for refractory immune checkpoint inhibitor-related cholangiohepatitis. *J Thorac Oncol.* 2021;16:318–26.
107. Kataoka S, Moriguchi M, Okishio S, Takahashi A, Okuda K, Seko Y, et al. Re-administration of nivolumab after immune checkpoint inhibitor-induced cholangitis: the first reported case. *Clin J Gastroenterol.* 2022;15:467–74.
108. Cheung VTF, Brain O. Immunotherapy induced enterocolitis and gastritis – what to do and when? Best practice & research. *Clin Gastroenterol.* 2020;48–49:101703.
109. Soularue E, Lepage P, Colombel JF, Coutzac C, Faleck D, Marthey L, et al. Enterocolitis due to immune checkpoint inhibitors: a systematic review. *Gut.* 2018;67:2056–67.
110. Gupta A, De Felice KM, Loftus EV Jr, Khanna S. Systematic review: colitis associated with anti-CTLA-4 therapy. *Aliment Pharmacol Therap.* 2015;42:406–17.
111. Hughes MS, Zheng H, Zubiri L, Molina GE, Chen ST, Mooradian MJ, et al. Colitis after checkpoint blockade: a retrospective cohort study of melanoma patients requiring admission for symptom control. *Cancer Med.* 2019;8:4986–99.
112. Verschuren EC, van den Eertwegh AJ, Wonders J, Slangen RM, van Delft F, van Bodegraven A, et al. Clinical, endoscopic, and histologic characteristics of ipilimumab-associated colitis. *Clin Gastroenterol Hepatol.* 2016;14:836–42.
113. Shieh AC, Guler E, Pfau D, Radzinsky E, Smith DA, Hoimes C, et al. Imaging and clinical manifestations of immune checkpoint inhibitor-related colitis in cancer patients treated with monotherapy or combination therapy. *Abdom Radiol (New York).* 2020;45:3028–35.
114. Marthey L, Mateus C, Mussini C, Nachury M, Nancey S, Grange F, et al. Cancer immunotherapy with anti-CTLA-4 monoclonal antibodies induces an inflammatory bowel disease. *J Crohn's Colitis.* 2016;10:395–401.
115. Beck KE, Blansfield JA, Tran KQ, Feldman AL, Hughes MS, Royal RE, et al. Enterocolitis in patients with cancer after antibody blockade of cytotoxic T-lymphocyte-associated antigen 4. *J Clin Oncol.* 2006;24:2283–9.
116. Geukes Foppen MH, Rozeman EA, van Wilpe S, Postma C, Snaebjornsson P, van Thienen JV, et al. Immune checkpoint inhibition-related colitis: symptoms, endoscopic features, histology and response to management. *ESMO Open.* 2018;3:e000278.
117. Abu-Sbeih H, Ali FS, Luo W, Qiao W, Raju GS, Wang Y. Importance of endoscopic and histological evaluation in the management of immune checkpoint inhibitor-induced colitis. *J Immunother Cancer.* 2018;6:95.
118. Cheung VTF, Gupta T, Olsson-Brown A, Subramanian S, Sasson SC, Heseltine J, et al. Immune checkpoint inhibitor-related colitis assessment and prognosis: can IBD scoring point the way? *Br J Cancer.* 2020;123:207–15.
119. Favara DM, Spain L, Au L, Clark J, Daniels E, Diem S, et al. Five-year review of corticosteroid duration and complications in

- the management of immune checkpoint inhibitor-related diarrhoea and colitis in advanced melanoma. *ESMO Open*. 2020;5.
120. Mooradian MJ, Wang DY, Coromilas A, Lumish M, Chen T, Giobbie-Hurder A, et al. Mucosal inflammation predicts response to systemic steroids in immune checkpoint inhibitor colitis. *J Immunother Cancer*. 2020;8:e000451.
  121. Alhatem A, Patel K, Eriksen B, Bukhari S, Liu C. Nivolumab-induced concomitant severe upper and lower gastrointestinal immune-related adverse effects. *ACG Case Rep J*. 2019;6:e00249.
  122. Mitchell KA, Kluger H, Sznol M, Hartman DJ. Ipilimumab-induced perforating colitis. *J Clin Gastroenterol*. 2013;47:781–5.
  123. Mohamed AA, Richards CJ, Boyle K, Faust G. Severe inflammatory ileitis resulting in ileal perforation in association with combination immune checkpoint blockade for metastatic malignant melanoma. *BMJ Case Rep*. 2018;2018, bcr2018224913.
  124. Trystram N, Laly P, Bertheau P, Baroudjian B, Aparicio T, Gornet JM. Haemorrhagic shock secondary to a diffuse ulcerative enteritis after Ipilimumab and Nivolumab treatment for metastatic melanoma: a case report. *Ann Palliat Med*. 2022;11:837–42.
  125. Mourad AP, De Robles MS. Chemoimmunotherapy-related enteritis resulting in a mechanical small bowel obstruction – a case report. *Int J Surg Case Rep*. 2021;79:131–4.
  126. Wang DY, Mooradian MJ, Kim D, Shah NJ, Fenton SE, Conry RM, et al. Clinical characterization of colitis arising from anti-PD-1 based therapy. *Oncoimmunology*. 2019;8:e1524695.
  127. Molina GE, Allen IM, Hughes MS, Zubiri L, Lee H, Mooradian MJ, et al. Prognostic implications of co-occurring dermatologic and gastrointestinal toxicity from immune checkpoint inhibition therapy for advanced malignancies: a retrospective cohort study. *J Am Acad Dermatol*. 2020;82:743–6.
  128. Nice L, Bycroft R, Wu X, Rai SN, Figg L, Bhandari S, et al. Assessment of hospitalization rates for immune-related adverse events with immune checkpoint inhibitors. *J Oncol Pharm Pract*. 2021;27:1736–42.
  129. Cooksley T, Gupta A, Al-Sayed T, Lorigan P. Emergency presentations in patients treated with immune checkpoint inhibitors. *Eur J Cancer (Oxf, Engl: 1990)*. 2020;130:193–7.
  130. Chen TW, Razak AR, Bedard PL, Siu LL, Hansen AR. A systematic review of immune-related adverse event reporting in clinical trials of immune checkpoint inhibitors. *Ann Oncol*. 2015;26:1824–9.
  131. Tang SQ, Tang LL, Mao YP, Li WF, Chen L, Zhang Y, et al. The pattern of time to onset and resolution of immune-related adverse events caused by immune checkpoint inhibitors in cancer: a pooled analysis of 23 clinical trials and 8436 patients. *Cancer Res Treat*. 2021;53:339–54.
  132. Sun X, Roudi R, Dai T, Chen S, Fan B, Li H, et al. Immune-related adverse events associated with programmed cell death protein-1 and programmed cell death ligand 1 inhibitors for non-small cell lung cancer: a PRISMA systematic review and meta-analysis. *BMC Cancer*. 2019;19:558.
  133. Hu Y, Gong J, Zhang L, Li X, Li X, Zhao B, et al. Colitis following the use of immune checkpoint inhibitors: a real-world analysis of spontaneous reports submitted to the FDA adverse event reporting system. *Int Immunopharmacol*. 2020;84:106601.
  134. Nuzzo PV, Pond GR, Abou Alaiwi S, Nassar AH, Flippot R, Curran C, et al. Conditional immune toxicity rate in patients with metastatic renal and urothelial cancer treated with immune checkpoint inhibitors. *J Immunother Cancer*. 2020;8:e000371.
  135. Owen CN, Bai X, Quah T, Lo SN, Allayou C, Callaghan S, et al. Delayed immune-related adverse events with anti-PD-1-based immunotherapy in melanoma. *Ann Oncol*. 2021;32:917–25.
  136. Michot JM, Lappara A, Le Pavec J, Simonaggio A, Collins M, De Martin E, et al. The 2016–2019 ImmunoTOX assessment board report of collaborative management of immune-related adverse events, an observational clinical study. *Eur J Cancer (Oxf, Engl: 1990)*. 2020;130:39–50.
  137. Institute USDoHaHSNNC. Common terminology criteria for adverse events (CTCAE). Version 5.0. 2017.
  138. Puzanov I, Diab A, Abdallah K, Bingham CO 3rd, Brogdon C, Dadu R, et al. Managing toxicities associated with immune checkpoint inhibitors: consensus recommendations from the Society for Immunotherapy of Cancer (SITC) Toxicity Management Working Group. *J Immunother Cancer*. 2017;5:95.
  139. Bishay K, Tandon P, Bourassa-Blanchette S, Laurie SA, McCurdy JD. The risk of diarrhea and colitis in patients with lung cancer treated with immune checkpoint inhibitors: a systematic review and meta-analysis. *Curr Oncol (Toronto, Ont)*. 2020;27:e486–94.
  140. Khoja L, Day D, Wei-Wu Chen T, Siu LL, Hansen AR. Tumour- and class-specific patterns of immune-related adverse events of immune checkpoint inhibitors: a systematic review. *Ann Oncol*. 2017;28:2377–85.
  141. De Velasco G, Je Y, Bossé D, Awad MM, Ott PA, Moreira RB, et al. Comprehensive meta-analysis of key immune-related adverse events from CTLA-4 and PD-1/PD-L1 inhibitors in cancer patients. *Cancer Immunol Res*. 2017;5:312–8.
  142. Collins M, Soularue E, Marthey L, Carbonnel F. Management of patients with immune checkpoint inhibitor-induced enterocolitis: a systematic review. *Clin Gastroenterol Hepatol*. 2020;18, 1393–403.e1391.
  143. Bertrand A, Kostine M, Barnetche T, Truchetet ME, Schaefferbeke T. Immune related adverse events associated with anti-CTLA-4 antibodies: systematic review and meta-analysis. *BMC Med*. 2015;13:211.
  144. Xu H, Tan P, Zheng X, Huang Y, Lin T, Wei Q, et al. Immune-related adverse events following administration of anti-cytotoxic T-lymphocyte-associated protein-4 drugs: a comprehensive systematic review and meta-analysis. *Drug Des Dev Ther*. 2019;13:2215–34.
  145. Witges K, Shafer LA, Zarychanski R, Abou-Setta AM, Rabbani R, Dingwall O, et al. Ipilimumab-induced enterocolitis: a systematic review and meta-analysis. *Drug Saf*. 2020;43:1255–66.
  146. Nahar KJ, Rawson RV, Ahmed T, Tattersall S, Sandanayake N, Kiely CJ, et al. Clinicopathological characteristics and management of colitis with anti-PD1 immunotherapy alone or in combination with ipilimumab. *J Immunother Cancer*. 2020;8:e001488.
  147. Schmerling RA, Buzaid AC, Haddad CK, Schutz FA, Kater FR, Pimenta J, et al. Immune manifestations with checkpoint inhibitors in a single Brazilian center: experience and literature review. *Future Sci OA*. 2020;7:Fso655.
  148. Wang PF, Chen Y, Song SY, Wang TJ, Ji WJ, Li SW, et al. Immune-related adverse events associated with anti-PD-1/PD-L1 treatment for malignancies: a meta-analysis. *Front Pharmacol*. 2017;8:730.
  149. Berti A, Bortolotti R, Dipasquale M, Kinspergher S, Prokop L, Grandi G, et al. Meta-analysis of immune-related adverse events in phase 3 clinical trials assessing immune checkpoint inhibitors for lung cancer. *Crit Rev Oncol Hematol*. 2021;162:103351.
  150. Sonpavde GP, Grivas P, Lin Y, Hennessy D, Hunt JD. Immune-related adverse events with PD-1 versus PD-L1 inhibitors: a meta-analysis of 8730 patients from clinical trials. *Future Oncol (Lond, Engl)*. 2021;17:2545–58.
  151. Cañete F, Mañosa M, Lobatón T, Mesonero F, Rodríguez-Lago I, Cabré E, et al. Nivolumab-induced immune-mediated colitis: an ulcerative colitis look-alike-report of new cases and review of the literature. *Int J Colorect Dis*. 2019;34:861–5.
  152. Miyashita H, Mikami T, Satoi S, Cruz C, Galsky MD. Incidence and risk of colitis with programmed death 1 versus



- programmed death ligand 1 inhibitors for the treatment of cancer. *J Immunother* (Hagerstown, Md: 1997). 2020;43:291–8.
153. Hofmann L, Forschner A, Loquai C, Goldinger SM, Zimmer L, Ugurel S, et al. Cutaneous, gastrointestinal, hepatic, endocrine, and renal side-effects of anti-PD-1 therapy. *Eur J Cancer* (Oxf, Engl: 1990). 2016;60:190–209.
  154. Grimaud F, Penaranda G, Stavris C, Retornaz F, Brunel V, Cailleres S, et al. Adverse events induced by PD-1/PD-L1 inhibitors: a real-world single-centre experience with a management-based approach. *Therap Clin Risk Manage*. 2021;17:669–77.
  155. Sakellariou S, Papathanasiou E, Perdiki M, Sotiropoulou M, Zampeli E, Michopoulos S, et al. Histological diversity of anti-PD1-induced colitis. *Histol Histopathol*. 2022;37:699–708.
  156. Kiyohara Y, Uhara H, Ito Y, Matsumoto N, Tsuchida T, Yamazaki N. Safety and efficacy of nivolumab in Japanese patients with malignant melanoma: an interim analysis of a postmarketing surveillance. *J Dermatol*. 2018;45:408–15.
  157. Sternberg CN, Llorca Y, James N, Choy E, Castellano D, Lopez-Rios F, et al. Primary results from SAUL, a multinational single-arm safety study of atezolizumab therapy for locally advanced or metastatic urothelial or nonurothelial carcinoma of the urinary tract. *Eur Urol*. 2019;76:73–81.
  158. Ouyang T, Cao Y, Kan X, Chen L, Ren Y, Sun T, et al. Treatment-related serious adverse events of immune checkpoint inhibitors in clinical trials: a systematic review. *Front Oncol*. 2021;11:621639.
  159. Coutzac C, Adam J, Soularue E, Collins M, Racine A, Mussini C, et al. Colon immune-related adverse events: anti-CTLA-4 and anti-PD-1 blockade induce distinct immunopathological entities. *J Crohn's Colitis*. 2017;11:1238–46.
  160. Hodi FS, Chiarion-Sileni V, Gonzalez R, Grob JJ, Rutkowski P, Cowey CL, et al. Nivolumab plus ipilimumab or nivolumab alone versus ipilimumab alone in advanced melanoma (CheckMate 067): 4-year outcomes of a multicentre, randomised, phase 3 trial. *Lancet Oncol*. 2018;19:1480–92.
  161. Almutairi AR, McBride A, Slack M, Erstad BL, Abraham I. Potential immune-related adverse events associated with monotherapy and combination therapy of ipilimumab, nivolumab, and pembrolizumab for advanced melanoma: a systematic review and meta-analysis. *Front Oncol*. 2020;10:91.
  162. Zhou S, Khanal S, Zhang H. Risk of immune-related adverse events associated with ipilimumab-plus-nivolumab and nivolumab therapy in cancer patients. *Therap Clin Risk Manage*. 2019;15:211–21.
  163. Da L, Teng Y, Wang N, Zaguirre K, Liu Y, Qi Y, et al. Organ-specific immune-related adverse events associated with immune checkpoint inhibitor monotherapy versus combination therapy in cancer: a meta-analysis of randomized controlled trials. *Front Pharmacol*. 2019;10:1671.
  164. Mearns ES, Bell JA, Galaznik A, Puglielli SM, Cichewicz AB, Boulanger T, et al. Gastrointestinal adverse events with combination of checkpoint inhibitors in advanced melanoma: a systematic review. *Melan Manage*. 2018;5:Mmt01.
  165. Park R, Lopes L, Cristancho CR, Riano IM, Saeed A. Treatment-related adverse events of combination immune checkpoint inhibitors: systematic review and meta-analysis. *Front Oncol*. 2020;10:258.
  166. Shieh C, Chalikhonda D, Block P, Shinn B, Kistler CA. Gastrointestinal toxicities of immune checkpoint inhibitors: a multicenter retrospective analysis. *Ann Gastroenterol*. 2021;34:46–52.
  167. Heppt MV, Amaral T, Kähler KC, Heinzerling L, Hassel JC, Meissner M, et al. Combined immune checkpoint blockade for metastatic uveal melanoma: a retrospective, multi-center study. *J Immunother Cancer*. 2019;7:299.
  168. Reese SW, Marchese M, McNabb-Baltar J. Insights from pharmacovigilance: gastrointestinal-related immune checkpoint inhibitor adverse events. *Gastroenterology*. 2020;159, 1195–200.e1191.
  169. Larkin J, Hodi FS, Wolchok JD. Combined nivolumab and ipilimumab or monotherapy in untreated melanoma. *N Engl J Med*. 2015;373:1270–1.
  170. Grover S, Dougan M, Tyan K, Giobbie-Hurder A, Blum SM, Ishizuka J, et al. Vitamin D intake is associated with decreased risk of immune checkpoint inhibitor-induced colitis. *Cancer*. 2020;126:3758–67.
  171. Yao J, Li M, Zhang H, Ge Y, Weygant N, An G. Differential risks of immune-related colitis among various immune checkpoint inhibitor regimens. *Int Immunopharmacol*. 2020;87:106770.
  172. Wolchok JD, Neyns B, Linette G, Negrier S, Lutzky J, Thomas L, et al. Ipilimumab monotherapy in patients with pretreated advanced melanoma: a randomised, double-blind, multicentre, phase 2, dose-ranging study. *Lancet Oncol*. 2010;11:155–64.
  173. Ascierto PA, Del Vecchio M, Robert C, Mackiewicz A, Chiarion-Sileni V, Arance A, et al. Ipilimumab 10 mg/kg versus ipilimumab 3 mg/kg in patients with unresectable or metastatic melanoma: a randomised, double-blind, multicentre, phase 3 trial. *Lancet Oncol*. 2017;18:611–22.
  174. Wang Y, Abu-Sbeih H, Mao E, Ali N, Ali FS, Qiao W, et al. Immune-checkpoint inhibitor-induced diarrhea and colitis in patients with advanced malignancies: retrospective review at MD Anderson. *J Immunother Cancer*. 2018;6:37.
  175. Shao J, Wang C, Ren P, Jiang Y, Tian P, Li W. Treatment- and immune-related adverse events of immune checkpoint inhibitors in advanced lung cancer. *Biosci Rep*. 2020;40. BSR20192347.
  176. Yang W, Men P, Xue H, Jiang M, Luo Q. Risk of gastrointestinal adverse events in cancer patients treated with immune checkpoint inhibitor plus chemotherapy: a systematic review and meta-analysis. *Front Oncol*. 2020;10:197.
  177. Tian Y, Zhang Z, Yang X, Li D, Zhang L, Li Z, et al. The risk ratio of immune-related colitis, hepatitis, and pancreatitis in patients with solid tumors caused by PD-1/PD-L1 inhibitors: a systematic review and meta-analysis. *Front Oncol*. 2020;10:261.
  178. Gao L, Yang X, Yi C, Zhu H. Adverse events of concurrent immune checkpoint inhibitors and antiangiogenic agents: a systematic review. *Front Pharmacol*. 2019;10:1173.
  179. Reck M, Mok TSK, Nishio M, Jotte RM, Cappuzzo F, Orlandi F, et al. Atezolizumab plus bevacizumab and chemotherapy in non-small-cell lung cancer (IMpower150): key subgroup analyses of patients with EGFR mutations or baseline liver metastases in a randomised, open-label phase 3 trial. *Lancet Respir Med*. 2019;7:387–401.
  180. Motzer RJ, Penkov K, Haanen J, Rini B, Albiges L, Campbell MT, et al. Avelumab plus axitinib versus sunitinib for advanced renal-cell carcinoma. *N Engl J Med*. 2019;380:1103–15.
  181. Paoluzzi L, Cacavio A, Ghesani M, Karambelkar A, Rapkiewicz A, Weber J, et al. Response to anti-PD1 therapy with nivolumab in metastatic sarcomas. *Clin Sarcom Res*. 2016;6:24.
  182. McDermott DF, Huseni MA, Atkins MB, Motzer RJ, Rini BI, Escudier B, et al. Clinical activity and molecular correlates of response to atezolizumab alone or in combination with bevacizumab versus sunitinib in renal cell carcinoma. *Nat Med*. 2018;24:749–57.
  183. Barker CA, Postow MA, Khan SA, Beal K, Parhar PK, Yamada Y, et al. Concurrent radiotherapy and ipilimumab immunotherapy for patients with melanoma. *Cancer Immunol Res*. 2013;1:92–8.
  184. Bang A, Wilhite TJ, Pike LRG, Cagney DN, Aizer AA, Taylor A, et al. Multicenter evaluation of the tolerability of combined treatment with PD-1 and CTLA-4 immune checkpoint inhibitors and palliative radiation therapy. *Int J Radiat Oncol Biol Phys*. 2017;98:344–51.



185. Farha N, Alkhayyat M, Lindsey A, Mansoor E, Saleh MA. Immune checkpoint inhibitor induced colitis: a nationwide population-based study. *Clin Res Hepatol Gastroenterol.* 2022;46:101778.
186. Sanderson K, Scotland R, Lee P, Liu D, Groshen S, Snively J, et al. Autoimmunity in a phase I trial of a fully human anti-cytotoxic T-lymphocyte antigen-4 monoclonal antibody with multiple melanoma peptides and Montanide ISA 51 for patients with resected stages III and IV melanoma. *J Clin Oncol.* 2005;23:741–50.
187. Hasan Ali O, Berner F, Bomze D, Fässler M, Diem S, Cozzio A, et al. Human leukocyte antigen variation is associated with adverse events of checkpoint inhibitors. *Eur J Cancer (Oxf, Engl: 1990).* 2019;107:8–14.
188. Refae S, Gal J, Ebran N, Otto J, Borchiellini D, Peyrade F, et al. Germinal Immunogenetics predict treatment outcome for PD-1/PD-L1 checkpoint inhibitors. *Invest New Drugs.* 2020;38:160–71.
189. Abdel-Wahab N, Diab A, Yu RK, Futreal A, Criswell LA, Tayar JH, et al. Genetic determinants of immune-related adverse events in patients with melanoma receiving immune checkpoint inhibitors. *Cancer Immunol Immunother.* 2021;70:1939–49.
190. Wang X, Niu X, An N, Sun Y, Chen Z. Comparative efficacy and safety of immunotherapy alone and in combination with chemotherapy for advanced non-small cell lung cancer. *Front Oncol.* 2021;11:611012.
191. Daly LE, Power DG, O'Reilly Á, Donnellan P, Cushen SJ, O'Sullivan K, et al. The impact of body composition parameters on ipilimumab toxicity and survival in patients with metastatic melanoma. *Br J Cancer.* 2017;116:310–7.
192. Bai S, Tian T, Pacheco JM, Tachihara M, Hu P, Zhang J. Immune-related adverse event profile of combination treatment of PD-(L)1 checkpoint inhibitors and bevacizumab in non-small cell lung cancer patients: data from the FDA adverse event reporting system. *Transl Lung Cancer Res.* 2021;10:2614–24.
193. Dubin K, Callahan MK, Ren B, Khanin R, Viale A, Ling L, et al. Intestinal microbiome analyses identify melanoma patients at risk for checkpoint-blockade-induced colitis. *Nat Commun.* 2016;7:10391.
194. Chaput N, Lepage P, Coutzac C, Soularue E, Le Roux K, Monot C, et al. Baseline gut microbiota predicts clinical response and colitis in metastatic melanoma patients treated with ipilimumab. *Ann Oncol.* 2019;30:2012.
195. Westdorp H, Sweep MWD, Gorris MAJ, Hoentjen F, Boers-Sonderen MJ, van der Post RS, et al. Mechanisms of immune checkpoint inhibitor-mediated colitis. *Front Immunol.* 2021;12:768957.
196. Berman D, Parker SM, Siegel J, Chasalow SD, Weber J, Galbraith S, et al. Blockade of cytotoxic T-lymphocyte antigen-4 by ipilimumab results in dysregulation of gastrointestinal immunity in patients with advanced melanoma. *Cancer Immun.* 2010;10:11.
197. Abu-Sbeih H, Herrera LN, Tang T, Altan M, Chaftari AP, Okhuysen PC, et al. Impact of antibiotic therapy on the development and response to treatment of immune checkpoint inhibitor-mediated diarrhea and colitis. *J Immunother Cancer.* 2019;7:242.
198. Manson G, Norwood J, Marabelle A, Kohrt H, Houot R. Biomarkers associated with checkpoint inhibitors. *Ann Oncol.* 2016;27:1199–206.
199. Hommes JW, Verheijden RJ, Suijkerbuijk KPM, Hamann D. Biomarkers of checkpoint inhibitor induced immune-related adverse events – a comprehensive review. *Front Oncol.* 2020;10:585311.
200. Pavan A, Calvetti L, Dal Maso A, Attili I, Del Bianco P, Pasello G, et al. Peripheral blood markers identify risk of immune-related toxicity in advanced non-small cell lung cancer treated with immune-checkpoint inhibitors. *Oncologist.* 2019;24:1128–36.
201. Peng L, Wang Y, Liu F, Qiu X, Zhang X, Fang C, et al. Peripheral blood markers predictive of outcome and immune-related adverse events in advanced non-small cell lung cancer treated with PD-1 inhibitors. *Cancer Immunol Immunother.* 2020;69:1813–22.
202. Fujimoto A, Toyokawa G, Koutake Y, Kimura S, Kawamata Y, Fukuishi K, et al. Association between pretreatment neutrophil-to-lymphocyte ratio and immune-related adverse events due to immune checkpoint inhibitors in patients with non-small cell lung cancer. *Thorac Cancer.* 2021;12:2198–204.
203. Das R, Bar N, Ferreira M, Newman AM, Zhang L, Bailur JK, et al. Early B cell changes predict autoimmunity following combination immune checkpoint blockade. *J Clin Investig.* 2018;128:715–20.
204. Shahabi V, Berman D, Chasalow SD, Wang L, Tsuchihashi Z, Hu B, et al. Gene expression profiling of whole blood in ipilimumab-treated patients for identification of potential biomarkers of immune-related gastrointestinal adverse events. *J Transl Med.* 2013;11:75.
205. Friedlander P, Wood K, Wassmann K, Christenfeld AM, Bhardwaj N, Oh WK. A whole-blood RNA transcript-based gene signature is associated with the development of CTLA-4 blockade-related diarrhea in patients with advanced melanoma treated with the checkpoint inhibitor tremelimumab. *J Immunother Cancer.* 2018;6:90.
206. Tarhini AA, Zahoor H, Lin Y, Malhotra U, Sander C, Butterfield LH, et al. Baseline circulating IL-17 predicts toxicity while TGF- $\beta$ 1 and IL-10 are prognostic of relapse in ipilimumab neoadjuvant therapy of melanoma. *J Immunother Cancer.* 2015;3:39.
207. Abu-Sbeih H, Faleck DM, Ricciuti B, Mendelsohn RB, Naqash AR, Cohen JV, et al. Immune checkpoint inhibitor therapy in patients with preexisting inflammatory bowel disease. *J Clin Oncol.* 2020;38:576–83.
208. Grover S, Ruan AB, Srivoleti P, Giobbie-Hurder A, Braschi-Amirfarzan M, Srivastava A, et al. Safety of immune checkpoint inhibitors in patients with pre-existing inflammatory bowel disease and microscopic colitis. *JCO Oncol Pract.* 2020;16:e933–42.
209. Sleiman J, Wei W, Shah R, Faisal MS, Philpott J, Funchain P. Incidence of immune checkpoint inhibitor-mediated diarrhea and colitis (imDC) in patients with cancer and preexisting inflammatory bowel disease: a propensity score-matched retrospective study. *J Immunother Cancer.* 2021;9:e002567.
210. Meserve J, Facciorusso A, Holmer AK, Annese V, Sandborn WJ, Singh S. Systematic review with meta-analysis: safety and tolerability of immune checkpoint inhibitors in patients with pre-existing inflammatory bowel diseases. *Aliment Pharmacol Therap.* 2021;53:374–82.
211. Wang Y, Abu-Sbeih H, Mao E, Ali N, Qiao W, Trinh VA, et al. Endoscopic and histologic features of immune checkpoint inhibitor-related colitis. *Inflamm Bowel Dis.* 2018;24:1695–705.
212. Kröner PT, Mody K, Farraye FA. Immune checkpoint inhibitor-related luminal GI adverse events. *Gastrointest Endosc.* 2019;90:881–92.
213. Hayashi Y, Hosoe N, Takabayashi K, Limpas Kamiya KJL, Tsugaru K, Shimozaki K, et al. Clinical, endoscopic, and pathological characteristics of immune checkpoint inhibitor-induced gastroenterocolitis. *Dig Dis Sci.* 2021;66:2129–34.
214. Powell N, Ibraheim H, Raine T, Speight RA, Papa S, Brain O, et al. British Society of Gastroenterology endorsed guidance for the management of immune checkpoint inhibitor-induced enterocolitis. *Lancet Gastroenterol Hepatol.* 2020;5:679–97.
215. Wright AP, Piper MS, Bishu S, Stidham RW. Systematic review and case series: flexible sigmoidoscopy identifies most cases

- of checkpoint inhibitor-induced colitis. *Aliment Pharmacol Therap.* 2019;49:1474–83.
216. Herlihy JD, Beasley S, Simmelink A, Maddukuri V, Amin A, Kamionek M, et al. Flexible sigmoidoscopy rather than colonoscopy is adequate for the diagnosis of ipilimumab-associated colitis. *South Med J.* 2019;112:154–8.
  217. De Silva S, Trieu H, Rajan A, Liang Y, Lin JL, Kidambi TD. Flexible sigmoidoscopy may be sufficient for initial evaluation of suspected immunotherapy-mediated colitis: a cross-sectional study. *J Gastroenterol Hepatol.* 2022;37:284–90.
  218. Assarzadegan N, Montgomery E, Anders RA. Immune checkpoint inhibitor colitis: the flip side of the wonder drugs. *Virch Arch.* 2018;472:125–33.
  219. Feakins R, Torres J, Borralho-Nunes P, Burisch J, Cúrdia Gonçalves T, De Ridder L, et al. ECCO topical review on clinicopathological spectrum and differential diagnosis of inflammatory bowel disease. *J Crohn's Colitis.* 2022;16:343–68.
  220. Oble DA, Mino-Kenudson M, Goldsmith J, Hodi FS, Seliem RM, Dranoff G, et al. Alpha-CTLA-4 mAb-associated panenteritis: a histologic and immunohistochemical analysis. *Am J Surg Pathol.* 2008;32:1130–7.
  221. Chen JH, Pezhouh MK, Lauwers GY, Masia R. Histopathologic features of colitis due to immunotherapy with anti-PD-1 antibodies. *Am J Surg Pathol.* 2017;41:643–54.
  222. Bavi P, Butler M, Serra S, Chetty R. Immune modulator-induced changes in the gastrointestinal tract. *Histopathology.* 2017;71:494–6.
  223. Kubo T, Hirohashi Y, Keira Y, Akimoto M, Ikeda T, Kikuchi N, et al. Identification of characteristic subepithelial surface granulomatosis in immune-related adverse event-associated enterocolitis. *Cancer Sci.* 2021;112:1320–5.
  224. Luoma AM, Suo S, Williams HL, Sharova T, Sullivan K, Manos M, et al. Molecular pathways of colon inflammation induced by cancer immunotherapy. *Cell.* 2020;182, 655–71.e622.
  225. Sasson SC, Slevin SM, Cheung VTF, Nassiri I, Olsson-Brown A, Fryer E, et al. Interferon-gamma-producing CD8(+) tissue resident memory T cells are a targetable hallmark of immune checkpoint inhibitor-colitis. *Gastroenterology.* 2021;161, 1229–44.e1229.
  226. Gonzalez RS, Salaria SN, Bohannon CD, Huber AR, Feely MM, Shi C. PD-1 inhibitor gastroenterocolitis: case series and appraisal of 'immunomodulatory gastroenterocolitis'. *Histopathology.* 2017;70:558–67.
  227. Zou F, Wang X, Glitza Oliva IC, McQuade JL, Wang J, Zhang HC, et al. Faecal calprotectin concentration to assess endoscopic and histologic remission in patients with cancer with immune-mediated diarrhea and colitis. *J Immunother Cancer.* 2021;9:e002058.
  228. Meling TR, Aabakken L, Røseth A, Osnes M. Faecal calprotectin shedding after short-term treatment with non-steroidal anti-inflammatory drugs. *Scand J Gastroenterol.* 1996;31:339–44.
  229. Cohen M. Proton pump inhibitors may cause elevation in faecal calprotectin levels. *Br J Gener Pract.* 2016;66:350.
  230. Abu-Sbeih H, Ali FS, Wang Y. Immune-checkpoint inhibitors induced diarrhea and colitis: a review of incidence, pathogenesis and management. *Curr Opin Gastroenterol.* 2020;36:25–32.
  231. Durbin SM, Mooradian MJ, Fintelmann FJ, Zubiri L, Chute DF, Kambadakone A, et al. Diagnostic utility of CT for suspected immune checkpoint inhibitor enterocolitis. *J Immunother Cancer.* 2020;8:e001329.
  232. Kim KW, Ramaiya NH, Krajewski KM, Shinagare AB, Howard SA, Jagannathan JP, et al. Ipilimumab-associated colitis: CT findings. *Am J Roentgenol.* 2013;200:W468–74.
  233. Tirumani SH, Ramaiya NH, Keraliya A, Bailey ND, Ott PA, Hodi FS, et al. Radiographic profiling of immune-related adverse events in advanced melanoma patients treated with ipilimumab. *Cancer Immunol Res.* 2015;3:1185–92.
  234. Barina AR, Bashir MR, Howard BA, Hanks BA, Salama AK, Jaffe TA. Isolated recto-sigmoid colitis: a new imaging pattern of ipilimumab-associated colitis. *Abdom Radiol (New York).* 2016;41:207–14.
  235. Widmann G, Nguyen VA, Plaickner J, Jaschke W. Imaging features of toxicities by immune checkpoint inhibitors in cancer therapy. *Curr Radiol Rep.* 2016;5:59.
  236. Garcia-Neuer M, Marmarelis ME, Jangi SR, Luke JJ, Ibrahim N, Davis M, et al. Diagnostic comparison of CT scans and colonoscopy for immune-related colitis in ipilimumab-treated advanced melanoma patients. *Cancer Immunol Res.* 2017;5:286–91.
  237. Franklin C, Rooms I, Fiedler M, Reis H, Milsch L, Herz S, et al. Cytomegalovirus reactivation in patients with refractory checkpoint inhibitor-induced colitis. *Eur J Cancer (Oxf, Engl: 1990).* 2017;86:248–56.
  238. Abu-Sbeih H, Ali FS, Naqash AR, Owen DH, Patel S, Otterson GA, et al. Resumption of immune checkpoint inhibitor therapy after immune-mediated colitis. *J Clin Oncol.* 2019;37:2738–45.
  239. Putignani L, Del Chierico F, Vernocchi P, Cicala M, Cucchiara S, Dallapiccola B. Gut microbiota dysbiosis as risk and pre-morbid factors of IBD and IBS along the childhood–adulthood transition. *Inflamm Bowel Dis.* 2016;22:487–504.
  240. Mourad FH, Hashash JG, Kariyawasam VC, Leong RW. Ulcerative colitis and cytomegalovirus infection: from A to Z. *J Crohn's Colitis.* 2020;14:1162–71.
  241. McCutcheon JL, McClain CM, Puzanov I, Smith TA. Infectious colitis associated with ipilimumab therapy. *Gastroenterol Res.* 2014;7:28–31.
  242. Ma W, Gong Z, Abu-Sbeih H, Peng Y, Peng F, Zou F, et al. Outcomes of immune checkpoint inhibitor-related diarrhea or colitis in cancer patients with superimposed gastrointestinal infections. *Am J Clin Oncol.* 2021;44:402–8.
  243. Eshet Y, Baruch EN, Shapira-Frommer R, Steinberg-Silman Y, Kuznetsov T, Ben-Betzalel G, et al. Clinical significance of pancreatic atrophy induced by immune-checkpoint inhibitors: a case–control study. *Cancer Immunol Res.* 2018;6:1453–8.
  244. Badran YR, Shih A, Leet D, Mooradian MJ, Coromilas A, Chen J, et al. Immune checkpoint inhibitor-associated celiac disease. *J Immunother Cancer.* 2020;8:e000958.
  245. Champiat S, Lambotte O, Barreau E, Belkhir R, Berdelou A, Carbonnel F, et al. Management of immune checkpoint blockade dysimmune toxicities: a collaborative position paper. *Ann Oncol.* 2016;27:559–74.
  246. André T, Shiu KK, Kim TW, Jensen BV, Jensen LH, Punt C, et al. Pembrolizumab in microsatellite-instability-high advanced colorectal cancer. *N Engl J Med.* 2020;383:2207–18.
  247. Chau I, Ajani JA, Doki Y, Xu J, Wyrwicz L, Motoyama S, et al. Nivolumab (NIVO) plus chemotherapy (chemo) or ipilimumab (IPI) versus chemo as first-line (1L) treatment for advanced esophageal squamous cell carcinoma (ESCC): expanded efficacy and safety analyses from CheckMate 648. *J Clin Oncol.* 2022;40:4035.
  248. Majeed M, Agrawal R, Gandhi S. Diarrhea in a patient receiving chemotherapy. *Gastroenterology.* 2019;157:1492–3.
  249. Kuriakose Kuzhianjal AJ, Nigam GB, Afzal M. Amelanotic anorectal malignant melanoma in an ulcerative colitis patient: a rare coincidence or a rare association. *BMJ Case Rep.* 2021;14:e240398.
  250. Zhang ZG, Hao XS. Diagnosis and treatment of 41 patients with malignant peritoneal mesothelioma. *Zhonghua zhong liu za zhi.* 2004;26:631–3.

251. Khamaysi I, Hajj E. Drug-induced pancreatic atrophy ("the vanishing pancreas"). *Eur J Hepato-gastroenterol.* 2020;10:101–2.
252. Gordon L, Dokouhaki P, Hagel K, Prasad B. Acute kidney injury from immune checkpoint inhibitor use. *BMJ Case Rep.* 2019;12:e231211.
253. Naito T, Nosaka T, Takahashi K, Ofuji K, Matsuda H, Ohtani M, et al. A case of immune checkpoint inhibitor-related colitis with a distinctive endoscopic finding of colonic pseudolipomatosis. *Clin J Gastroenterol.* 2021;14:1431–6.
254. Coit DG, Thompson JA, Albertini MR, Barker C, Carson WE, Contreras C, et al. Cutaneous melanoma, version 2.2019, NCCN clinical practice guidelines in oncology. *J Natl Compreh Cancer Netw.* 2019;17:367–402.
255. O'Connor A, Marples M, Mulatero C, Hamlin J, Ford AC. Ipilimumab-induced colitis: experience from a tertiary referral center. *Therap Adv Gastroenterol.* 2016;9:457–62.
256. Jain A, Lipson EJ, Sharfman WH, Brant SR, Lazarev MG. Colonic ulcerations may predict steroid-refractory course in patients with ipilimumab-mediated enterocolitis. *World J Gastroenterol.* 2017;23:2023–8.
257. Hillock NT, Heard S, Kichenadasse G, Hill CL, Andrews J. Infliximab for ipilimumab-induced colitis: a series of 13 patients. *Asia-Pac J Clin Oncol.* 2017;13:e284–90.
258. Minor DR, Chin K, Kashani-Sabet M. Infliximab in the treatment of anti-CTLA4 antibody (ipilimumab) induced immune-related colitis. *Cancer Biother Radiopharm.* 2009;24:321–5.
259. Bellaguarda E, Hanauer S. Checkpoint inhibitor-induced colitis. *Am J Gastroenterol.* 2020;115:202–10.
260. Mir R, Shaw HM, Nathan PD. Mycophenolate mofetil alongside high-dose corticosteroids: optimizing the management of combination immune checkpoint inhibitor-induced colitis. *Melanoma Res.* 2019;29:102–6.
261. Choi K, Abu-Sbeih H, Samdani R, Nogueras Gonzalez G, Raju GS, Richards DM, et al. Can immune checkpoint inhibitors induce microscopic colitis or a brand new entity? *Inflamm Bowel Dis.* 2019;25:385–93.
262. Collins M, Michot JM, Danlos FX, Mussini C, Soularue E, Mateus C, et al. Inflammatory gastrointestinal diseases associated with PD-1 blockade antibodies. *Ann Oncol.* 2017;28:2860–5.
263. de Andrea CE, Perez-Gracia JL, Castanon E, Ponz-Sarvise M, Echeveste JI, Melero I, et al. Endoscopic and pathological dissociation in severe colitis induced by immune-checkpoint inhibitors. *Oncoimmunology.* 2020;9:1760676.
264. Hughes MS, Molina GE, Chen ST, Zheng H, Deshpande V, Fadden R, et al. Budesonide treatment for microscopic colitis from immune checkpoint inhibitors. *J Immunother Cancer.* 2019;7:292.
265. Pagès C, Gornet JM, Monsel G, Allez M, Bertheau P, Bagot M, et al. Ipilimumab-induced acute severe colitis treated by infliximab. *Melanoma Res.* 2013;23:227–30.
266. Johnson DH, Zobniw CM, Trinh VA, Ma J, Bassett RL Jr, Abdel-Wahab N, et al. Infliximab associated with faster symptom resolution compared with corticosteroids alone for the management of immune-related enterocolitis. *J Immunother Cancer.* 2018;6:103.
267. Johnston RL, Lutzky J, Chodhry A, Barkin JS. Cytotoxic T-lymphocyte-associated antigen 4 antibody-induced colitis and its management with infliximab. *Dig Dis Sci.* 2009;54:2538–40.
268. Nassri AB, Muenyi V, Alkhasawneh A, Ribeiro BS, Scolapio JS, Malespin M, et al. Ipilimumab and Nivolumab induced steroid-refractory colitis treated with infliximab: a case report. *World J Gastrointest Pharmacol Therap.* 2019;10:29–34.
269. Kadokawa Y, Takagi M, Yoshida T, Tatsumi A, Fujita K, Inoue T, et al. Efficacy and safety of Infliximab for steroid-resistant immune-related adverse events: a retrospective study. *Mol Clin Oncol.* 2021;14:65.
270. Connolly EA, Walker T, Van der Westhuizen A. Impending infliximab access crisis: a case of steroid-refractory, relapsing immunotherapy-induced colitis responsive to infliximab. *Intern Med J.* 2020;50:767–8.
271. Lankes K, Hundorfean G, Harrer T, Pommer AJ, Agaimy A, Angelovska I, et al. Anti-TNF-refractory colitis after checkpoint inhibitor therapy: possible role of CMV-mediated immunopathogenesis. *Oncoimmunology.* 2016;5:e1128611.
272. Horvat TZ, Adel NG, Dang TO, Momtaz P, Postow MA, Callahan MK, et al. Immune-related adverse events, need for systemic immunosuppression, and effects on survival and time to treatment failure in patients with melanoma treated with ipilimumab at memorial Sloan Kettering cancer center. *J Clin Oncol.* 2015;33:3193–8.
273. Arriola E, Wheeler M, Karydis I, Thomas G, Ottensmeier C. Infliximab for IPILIMUMAB-related colitis-letter. *Clin Cancer Res.* 2015;21:5642–3.
274. Bishu S, Melia J, Sharfman W, Lao CD, Fecher LA, Higgins PDR. Efficacy and outcome of tofacitinib in immune checkpoint inhibitor colitis. *Gastroenterology.* 2021;160, 932–4.e933.
275. Abu-Sbeih H, Ali FS, Wang X, Mallepally N, Chen E, Altan M, et al. Early introduction of selective immunosuppressive therapy associated with favorable clinical outcomes in patients with immune checkpoint inhibitor-induced colitis. *J Immunother Cancer.* 2019;7:93.
276. Céspedes Martínez E, Robles Alonso V, Herrera-De Guise C, Mayorga L, Casellas F, Roca-Herrera M, et al. Severe and refractory gastrointestinal toxicity due to immune checkpoint inhibitors: clinical experience in a tertiary referral hospital. *Revista española de enfermedades digestivas* 2023.
277. Abu-Sbeih H, Ali FS, Alsaadi D, Jennings J, Luo W, Gong Z, et al. Outcomes of vedolizumab therapy in patients with immune checkpoint inhibitor-induced colitis: a multi-center study. *J Immunother Cancer.* 2018;6:142.
278. Burla J, Bluemel S, Biedermann L, Barysch MJ, Dummer R, Levesque MP, et al. Retrospective analysis of treatment and complications of immune checkpoint inhibitor-associated colitis: histological ulcerations as potential predictor for a steroid-refractory disease course. *Inflam Intest Dis.* 2020;5:109–16.
279. Randhawa M, Gaughran G, Archer C, Pavli P, Morey A, Ali S, et al. Vedolizumab in combined immune checkpoint therapy-induced infliximab-refractory colitis in a patient with metastatic melanoma: a case report. *World J Clin Oncol.* 2019;10:350–7.
280. Hsieh AH, Ferman M, Brown MP, Andrews JM. Vedolizumab: a novel treatment for ipilimumab-induced colitis. *BMJ Case Rep.* 2016;2016:bcr2016216641.
281. Bergqvist V, Hertervig E, Gedeon P, Kopljar M, Griph H, KINHULT S, et al. Vedolizumab treatment for immune checkpoint inhibitor-induced enterocolitis. *Cancer Immunol Immunother.* 2017;66:581–92.
282. Iyoda T, Kurita N, Takada A, Watanabe H, Ando M. Resolution of infliximab-refractory nivolumab-induced acute severe enterocolitis after cyclosporine treatment in a patient with non-small cell lung cancer. *Am J Case Rep.* 2018;19:360–4.
283. Esfahani K, Hudson M, Batist G. Tofacitinib for refractory immune-related colitis from PD-1 therapy. *N Engl J Med.* 2020;382:2374–5.
284. Thomas AS, Ma W, Wang Y. Ustekinumab for refractory colitis associated with immune checkpoint inhibitors. *N Engl J Med.* 2021;384:581–3.
285. Weber JS, Hodi FS, Wolchok JD, Topalian SL, Schadendorf D, Larkin J, et al. Safety profile of nivolumab monotherapy: a pooled analysis of patients with advanced melanoma. *J Clin Oncol.* 2017;35:785–92.
286. Loras C, Gisbert JP, Saro MC, Piqueras M, Sánchez-Montes C, Barrio J, et al. Impact of surveillance of hepatitis B



- and hepatitis c in patients with inflammatory bowel disease under anti-TNF therapies: multicenter prospective observational study (REPENTINA 3). *J Crohn's Colitis*. 2014;8:1529–38.
287. Cabriada JL, Vera I, Domènech E, Barreiro-de Acosta M, Esteve M, Gisbert JP, et al. Recommendations of the Spanish Working Group on Crohn's Disease and Ulcerative Colitis on the use of anti-tumor necrosis factor drugs in inflammatory bowel disease. *Gastroenterol Hepatol*. 2013;36:127–46.
  288. Pesántez D, Seguí E, Ordás I, Viladot M, Arance A. Successful management of refractory immune-mediated enterocolitis with cyclosporine. *Eur J Cancer (Oxf, Engl: 1990)*. 2020;131:37–9.
  289. Shirwaikar Thomas A, Lee SE, Shatila M, De Toni EN, Török HP, Ben Khaled N, et al. IL12/23 blockade for refractory immune-mediated colitis: 2-center experience. *Am J Gastroenterol*. 2023;118:1679–83.
  290. Perez Del Nogal G, Patel N. Refractory checkpoint inhibitor colitis responsive to ustekinumab. *ACG Case Rep J*. 2022;9:e00946.
  291. Holmstroem RB, Dahl EK, Helms M, Nielsen HV, Andersen JB, Bjerrum JT, et al. Tofacitinib and faecal microbiota transplantation in treating checkpoint inhibitor-induced enterocolitis: case report. *BMJ Open Gastroenterol*. 2022;9:e000989.
  292. Sleiman J, Brand RM, Pai R, Brand RE, Rhee J, Schwartz M, et al. Mirroring UC care pathways in refractory immune checkpoint inhibitor (ICI)-mediated colitis: distinct features and common pathways. *Clin J Gastroenterol*. 2023;16:680–4.
  293. Wang Y, Wiesnoski DH, Helmink BA, Gopalakrishnan V, Choi K, DuPont HL, et al. Fecal microbiota transplantation for refractory immune checkpoint inhibitor-associated colitis. *Nat Med*. 2018;24:1804–8.
  294. Menzies AM, Johnson DB, Ramanujam S, Atkinson VG, Wong ANM, Park JJ, et al. Anti-PD-1 therapy in patients with advanced melanoma and preexisting autoimmune disorders or major toxicity with ipilimumab. *Ann Oncol*. 2017;28:368–76.
  295. Haanen J, Ernstoff M, Wang Y, Menzies A, Puzanov I, Griivas P, et al. Rechallenge patients with immune checkpoint inhibitors following severe immune-related adverse events: review of the literature and suggested prophylactic strategy. *J Immunother Cancer*. 2020;8:e000604.
  296. Zhao Q, Zhang J, Xu L, Yang H, Liang N, Zhang L, et al. Safety and efficacy of the rechallenge of immune checkpoint inhibitors after immune-related adverse events in patients with cancer: a systemic review and meta-analysis. *Front Immunol*. 2021;12:730320.
  297. Park R, Lopes L, Saeed A. Outcomes following immunotherapy re-challenge after immune-related adverse event: systematic review and meta-analysis. *Immunotherapy*. 2020;12:1183–93.
  298. de Malet A, Antoni G, Collins M, Soularue E, Marthey L, Vaysse T, et al. Evolution and recurrence of gastrointestinal immune-related adverse events induced by immune checkpoint inhibitors. *Eur J Cancer (Oxf, Engl: 1990)*. 2019;106:106–14.
  299. Allouchery M, Lombard T, Martin M, Rouby F, Sassier M, Bertin C, et al. Safety of immune checkpoint inhibitor rechallenge after discontinuation for grade  $\geq 2$  immune-related adverse events in patients with cancer. *J Immunother Cancer*. 2020;8.
  300. Siddiqui BA, Gheeya JS, Goswamy R, Bathala TK, Surasi DS, Gao J, et al. Durable responses in patients with genitourinary cancers following immune checkpoint therapy rechallenge after moderate-to-severe immune-related adverse events. *J Immunother Cancer*. 2021;9:e002850.
  301. Kartolo A, Holstead R, Khalid S, Emack J, Hopman W, Baetz T. Safety of immunotherapy rechallenge after immune-related adverse events in patients with advanced cancer. *J Immunother (Hagerstown, Md: 1997)*. 2021;44:41–8.
  302. Thompson JA, Hamid O, Minor D, Amin A, Ron IG, Ridolfi R, et al. Ipilimumab in treatment-naive and previously treated patients with metastatic melanoma: retrospective analysis of efficacy and safety data from a phase II trial. *J Immunother (Hagerstown, Md: 1997)*. 2012;35:73–7.
  303. Abu-Sbeih H, Ali FS, Qiao W, Lu Y, Patel S, Diab A, et al. Immune checkpoint inhibitor-induced colitis as a predictor of survival in metastatic melanoma. *Cancer Immunol Immunother*. 2019;68:553–61.
  304. Carmona-Bayonas A, Jimenez-Fonseca P, Fernández-Somoano A, Álvarez-Manceñido F, Castañón E, Custodio A, et al. Top ten errors of statistical analysis in observational studies for cancer research. *Clin Transl Oncol*. 2018;20:954–65.
  305. Eggermont AMM, Kicinski M, Blank CU, Mandala M, Long GV, Atkinson V, et al. Association between immune-related adverse events and recurrence-free survival among patients with stage III melanoma randomized to receive pembrolizumab or placebo: a secondary analysis of a randomized clinical trial. *JAMA Oncol*. 2020;6:519–27.
  306. Verzoni E, Carteni G, Cortesi E, Giannarelli D, De Giglio A, Sabbatini R, et al. Real-world efficacy and safety of nivolumab in previously-treated metastatic renal cell carcinoma, and association between immune-related adverse events and survival: the Italian expanded access program. *J Immunother Cancer*. 2019;7:99.
  307. Maher VE, Fernandes LL, Weinstock C, Tang S, Agarwal S, Brave M, et al. Analysis of the association between adverse events and outcome in patients receiving a programmed death protein 1 or programmed death ligand 1 antibody. *J Clin Oncol*. 2019;37:2730–7.
  308. Schweizer C, Schubert P, Rutzner S, Eckstein M, Haderlein M, Lettmaier S, et al. Prospective evaluation of the prognostic value of immune-related adverse events in patients with non-melanoma solid tumour treated with PD-1/PD-L1 inhibitors alone and in combination with radiotherapy. *Eur J Cancer (Oxf, Engl: 1990)*. 2020;140:55–62.
  309. Maillet D, Corbaux P, Stelmes JJ, Dalle S, Locatelli-Sanchez M, Perier-Muzet M, et al. Association between immune-related adverse events and long-term survival outcomes in patients treated with immune checkpoint inhibitors. *Eur J Cancer (Oxf, Engl: 1990)*. 2020;132:61–70.
  310. Zhou X, Yao Z, Yang H, Liang N, Zhang X, Zhang F. Are immune-related adverse events associated with the efficacy of immune checkpoint inhibitors in patients with cancer? A systematic review and meta-analysis. *BMC Med*. 2020;18:87.
  311. Cheung Y, Gupta T, Ye W, Middleton M, Fairfax B, Payne M, et al. PTU-061 immunotherapy-related gastritis in a tertiary oncology centre. *Gut*. 2019;68:A147.
  312. Tang T, Abu-Sbeih H, Luo W, Lum P, Qiao W, Bresalier RS, et al. Upper gastrointestinal symptoms and associated endoscopic and histological features in patients receiving immune checkpoint inhibitors. *Scand J Gastroenterol*. 2019;54:538–45.
  313. Johncilla M, Grover S, Zhang X, Jain D, Srivastava A. Morphological spectrum of immune check-point inhibitor therapy-associated gastritis. *Histopathology*. 2020;76:531–9.
  314. Vandepapelière J, Sipler J, Libbrecht L, Dano H, Baurain JF, Moreels T. Auto-immune gastritis induced by pembrolizumab, an anti-PD-1, in a melanoma patient. *Acta Gastro-enterol Belg*. 2020;83:482–4.
  315. Boike J, DeJulio T. Severe esophagitis and gastritis from nivolumab therapy. *ACG Case Rep J*. 2017;4:e57.
  316. Horisberger A, La Rosa S, Zurcher JP, Zimmermann S, Spertini F, Coukos G, et al. A severe case of refractory esophageal stenosis induced by nivolumab and responding to tocilizumab therapy. *J Immunother Cancer*. 2018;6:156.
  317. Lu J, Firpi-Morell RJ, Dang LH, Lai J, Liu X. An unusual case of gastritis in one patient receiving PD-1 blocking therapy: coexisting immune-related gastritis and cytomegaloviral infection. *Gastroenterol Res*. 2018;11:383–7.
  318. Hulo P, Toucheffeu Y, Cauchin E, Archambeaud I, Chapelle N, Bossard C, et al. Acute ulceronecrotic gastritis with



- cytomegalovirus reactivation: uncommon toxicity of immune checkpoint inhibitors in microsatellite instability-high metastatic colorectal cancer. *Clin Colorect Cancer*. 2020;19:e183–8.
319. Townsend MJ, Liu M, Giobbie-Hurder A, Sack JS, LeBoeuf NR, Hodi FS, et al. Pancreatitis and hyperlipasemia in the setting of immune checkpoint inhibitor therapy. *J Natl Compreh Cancer Netw*. 2023;21, 831–40.e833.
320. Zhao Z, Zhang W, Pang L, Zeng L, Liu S, Liu J. Pancreatic adverse events of immune checkpoint inhibitors therapy for solid cancer patients: a systematic review and meta-analysis. *Front Immunol*. 2023;14:1166299.