

The 40-kDa protein of *Lumbricus rubellus* eradicates methicillin-resistant *Staphylococcus aureus* in an long-term nasal carriage model



La proteína de 40 kDa de *Lumbricus rubellus* erradica *Staphylococcus aureus* resistente a la metilina en un modelo de portador nasal a largo plazo

Nasal carriage of methicillin-resistant *Staphylococcus aureus* (MRSA) plays a pivotal role in the epidemiology and pathogenesis of MRSA infection.¹ Although mupirocin has emerged as the agent of choice for elimination of *S. aureus* nasal carriage,³ several studies have identified high rates of MRSA resistant to mupirocin.^{3,4} Therefore, the development of eradication therapy for MRSA nasal carriage is needed.

Previously, it has been demonstrated that the 40-kDa fetidin of the earthworm *Eisenia fetida* suppressed the growth of *Bacillus megaterium*.⁵ Moreover, the extract of *Lumbricus rubellus*, another species of earthworm, displays more potent antibacterial activity *in vitro* against *S. aureus* than *E. fetida*.⁶ Hence, this study aimed to investigate the antibacterial activity of the 40-kDa protein of *L. rubellus* in a model of long-term MRSA nasal carriage. Besides, the innate immune response, secretory IgA (sIgA) levels, was also evaluated.

L. rubellus was obtained from a local store in Malang, Indonesia. Total proteins of *L. rubellus* were extracted and characterized by SDS-PAGE. The 40-kDa protein band of *L. rubellus* was cut and eluted, yielding a concentration of 3550 mg/L.^{7–10} The bacterial isolate, MRSA, was provided by the Department of Clinical Microbiology, Faculty of Medicine, Brawijaya University. For *in vivo* experiments, thirty female Balb/c mice (8–12 weeks of age) were randomly divided into six groups (5 mice/group), such as negative control, positive control, and infected mice treated with mupirocin and three different doses of the 40-kDa protein of *L. rubellus*. The study was approved by the ethics committee of Brawijaya University (Ref. No. 26-KE).

The model of long-term MRSA nasal carriage was performed as previously described.² Briefly, mice were injected with hydrocortisone subcutaneously (100 mg/kg/day at days 0 and 4), followed by intranasal infections of MRSA (10 µL containing 3 × 10⁴ CFU) on days 5, 7, 9, 30, 32 and 34. On day 35, nasal swab specimens were inoculated on CHROMagar to confirm the nasal carriage of MRSA. The control treatment group was administered with 2% mupirocin (Bactroban, 125 mg diluted in 240 mL saline¹¹), while the treatment groups were treated with the 40-kDa protein of *L. rubellus* (diluted in saline at a concentration of 1:10, 1:50, and 1:100 from the total protein obtained previously) in a volume of 10 µL to the respective nares for 5 days starting from day 36

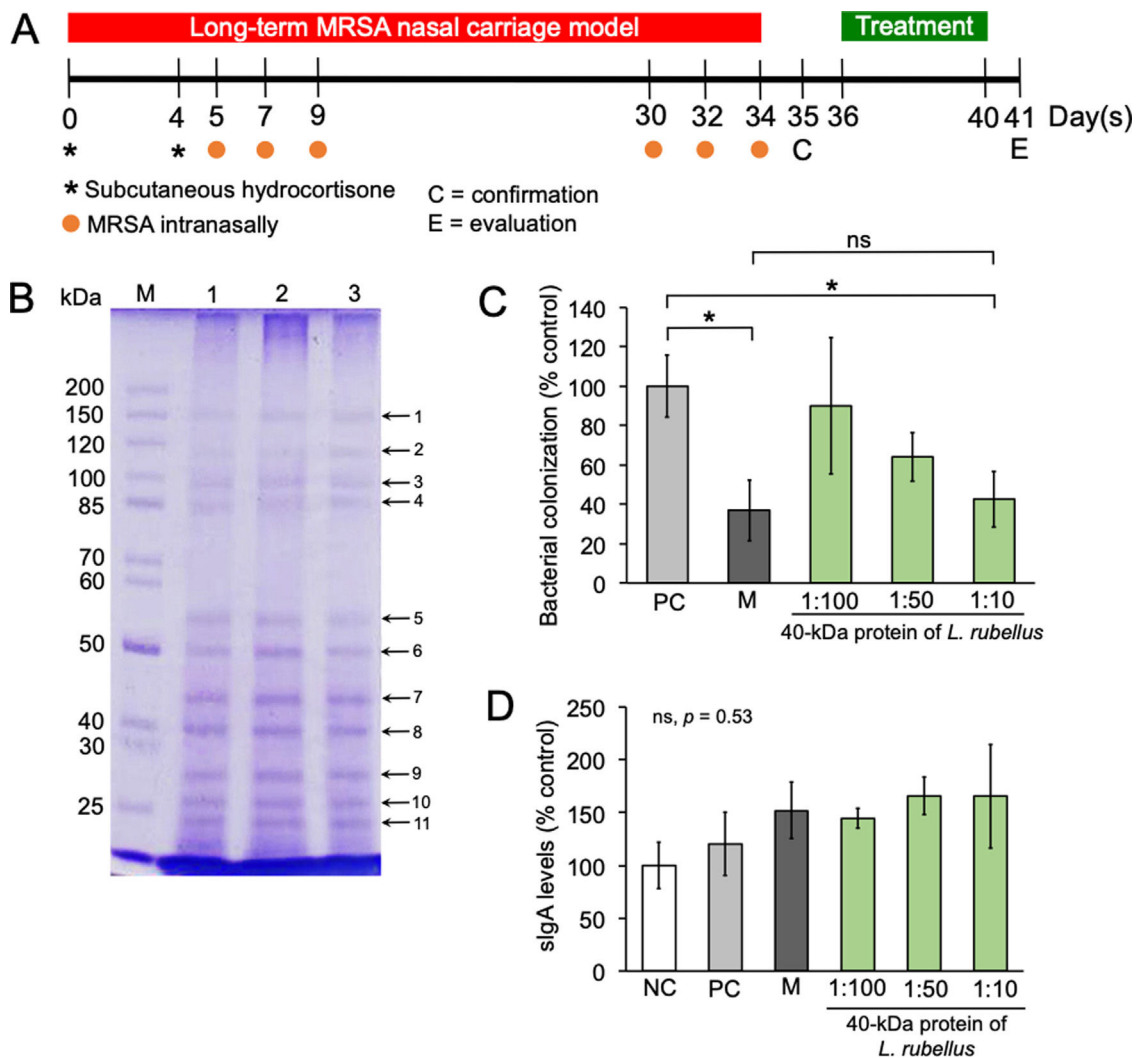


Fig. 1. Effect of the 40-kDa protein of *Lumbricus rubellus* in the long-term MRSA nasal carriage model. (A) Experimental timeline; (B) Protein profile of *L. rubellus*; M, marker; lane 1–3, replication 1–3; (C, D) MRSA colonization and the level of sIgA in the nasal mucosa after treatment with mupirocin or 40-kDa protein of *L. rubellus*, respectively. NC, negative control; PC, positive control; M, mupirocin; ns, not significant. (*) Indicates a significant difference between the two groups indicated in the graphs ($p < 0.05$).

(Fig. 1A). Negative controls were treated with saline only. The nasal swabs were conducted 24 h after the last administration of mupirocin or 40-kDa protein of *L. rubellus*. Swabs were then cultured in phenol red broth at 37 °C. The next day, 10 µL of broth at a concentration of 10⁻¹ CFU/mL were inoculated on CHROMagar, incubated at 37 °C for 24 h, and then bacterial numbers were counted. No colonization of MRSA was observed in negative controls.

For quantification of sIgA levels, mice were sacrificed. Nasal mucosa was scrapped, diluted in 5 mL PBS containing a protease inhibitor cocktail (25 µg/mL) and centrifuged at 12,000 rpm (4 °C) for 15 min. Supernatants were purified with 40% ammonium sulfate. Suspensions were then diluted in 1 mL PBS and used for ELISA of sIgA.¹² All experiments were done in duplicate, resulting in similar findings. The numbers of bacterial colonization and sIgA levels were analyzed by one-way ANOVA, followed by Tukey's post hoc test using StatPlus. Significant differences were accepted when $p < 0.05$.

We identified eleven conserved protein bands from *L. rubellus* (Fig. 1B). Among them, low molecular protein bands (50, 40, 27, 25, and 22-kDa) displayed high concentration profiles. Mupirocin and a high dose of the 40-kDa protein of *L. rubellus* significantly inhibited MRSA colonization ($p = 0.03$ and $p = 0.04$, respectively) in the nasal mucosa of mice (Fig. 1C), thereby implying that the 40-kDa protein of *L. rubellus* was able to eradicate MRSA colonization as effectively as mupirocin. No significant antibacterial activity was observed from the other protein bands (data not shown). Although we failed to show that neither mupirocin nor the 40-kDa protein of *L. rubellus* were able to stimulate sIgA secretion ($p = 0.35$) (Fig. 1D), both groups tended to have higher levels of sIgA, suggesting that the level of sIgA would initially be beneficial to protect the nasal mucosa from MRSA invasion. Altogether, the 40-kDa protein of *L. rubellus* exhibits potent activity anti-MRSA *in vivo*.

Funding statement

None to declare.

Conflict of interest

None to declare.

Acknowledgement

The authors would like to thank to Alif Fakhurrozi and Budi Darmansyah for their help in this project.

Bibliografía

1. El Aila NA, Al Laham NA, Ayesh BM. Nasal carriage of methicillin resistant *Staphylococcus aureus* among health care workers at Al Shifa hospital in Gaza Strip. *BMC Infect Dis.* 2017;17:28. <http://dx.doi.org/10.1186/s12879-016-2139-1>.
2. Kruszewska D, Sahl HG, Bierbaum G, Pag U, Hynes SO, Ljungh A. Mersacidin eradicates methicillin-resistant *Staphylococcus aureus* (MRSA) in a mouse rhinitis model. *J Antimicrob Chemother.* 2004;54:648–53. <http://dx.doi.org/10.1093/jac/dkh387>.
3. Laupland KB, Conly JM. Treatment of *Staphylococcus aureus* colonization and prophylaxis for infection with topical intranasal mupirocin: an evidence-based review. *Clin Infect Dis.* 2003;37:933–8. <http://dx.doi.org/10.1086/377735>.
4. Mustafa Y, Sahin I, Basak S, Oksuz S, Ozaydin C, Acar S, et al. The investigation of nasal MRSA carriage and colonization of nasopharyngeal pathogens at a primary school in Duzce. *Turk J Med Sci.* 2007;37:359–65.
5. Lassegues M, Milochau A, Doignon F, Du Pasquier L, Valembos P. Sequence and expression of an *Eisenia fetida*-derived cDNA clone that encodes the 40-kDa fetidin antibacterial protein. *Eur J Biochem.* 1997;246:756–62. <http://dx.doi.org/10.1111/j.1432-1033.1997.00756.x>.
6. Kartikaningsih H, Hartati K, Maharani S, Sartika F. Antibacterial activity ethyl acetate extracts of earthworms (*Lumbricus rubellus*, *Eisenia foetida*, *Nereis* spp.) toward *Staphylococcus aureus*, *Enterococcus faecalis* *Salmonella thyposa* in vitro. *El-Hayah.* 2019;7:2. <http://dx.doi.org/10.18860/elha.v7i2.8248>.
7. Ulhaq ZS, Kishida M. Brain aromatase modulates serotonergic neuron by regulating serotonin levels in zebrafish embryos and larvae. *Front Endocrinol (Lausanne).* 2018;9:230. <http://dx.doi.org/10.3389/fendo.2018.00230>.
8. Ulhaq ZS. Brain aromatase modulates cardiac functions in embryonic zebrafish. *Int J Vet Sci Med.* 2019;7:31–4. <http://dx.doi.org/10.1080/23144599.2019.1675287>.
9. Ulhaq ZS. Dopamine D2 receptor influences eye development and function in zebrafish. *Arch Soc Esp Ophthalmol.* 2020;95:84–9. <http://dx.doi.org/10.1016/j.oftal.2019.11.013>.
10. Ulhaq ZS, Hendyatama TH, Hameed F, Santosaningsih D. Antibacterial activity of *Citrus hystrix* toward *Salmonella* spp. infection. *Enferm Infecc Microbiol Clin.* 2020. <http://dx.doi.org/10.1016/j.eimc.2020.05.016>. S0213-005X(20)30215-9.
11. Jervis-Bardy J, Boase S, Psaltis A, Foreman A, Wormald PJ. A randomized trial of mupirocin sinonasal rinses versus saline in surgically recalcitrant staphylococcal chronic rhinosinusitis. *Laryngoscope.* 2012;122:2148–53. <http://dx.doi.org/10.1002/lary.23486>.
12. Wang M, Gong S, Du S, Zhu Y, Rong F, Pan R, et al. The effect of immunoregulation of *Streptococcus lactis* L16 strain upon *Staphylococcus aureus* infection. *BMC Microbiol.* 2017;17:130. <http://dx.doi.org/10.1186/s12866-017-1038-y>.

Zulvikar Syambani Ulhaq^{a,b,*}, Anggi Sasmita Kharisma Putri^b, Wahyu Picesa Sila Atmaja^b, Dewi Santosaningsih^b

^a Department of Biochemistry, Faculty of Medicine and Health Sciences, Maulana Malik Ibrahim State Islamic University of Malang, Batu, East Java, Indonesia

^b Department of Clinical Microbiology, Faculty of Medicine, Brawijaya University/Dr. Saiful Anwar Hospital, Malang, East Java, Indonesia

* Corresponding author.

E-mail address: zulhaq@kedokteran.uin-malang.ac.id (Z.S. Ulhaq).

<https://doi.org/10.1016/j.eimc.2020.08.019>

0213-005X/ © 2020 Sociedad Española de Enfermedades Infecciosas y Microbiología Clínica. Published by Elsevier España, S.L.U. All rights reserved.

Osteomielitis costal por neumococo en lactante vacunado, un caso excepcional



Pneumococcal osteomyelitis of the rib in a vaccinated infant; an exceptional case

La osteomielitis afecta principalmente a los huesos largos de las extremidades inferiores. La localización costal es infrecuente (< 1%). En la localización costal el *Staphylococcus aureus* es el causante de la mayoría de casos, seguido de *Mycobacterium tuberculosis*¹. Hay 3 casos en la literatura producidas por microorganismos del género estreptococo, y únicamente uno por *Streptococcus pneumoniae*².

Se trata de un lactante de 6 meses que acude a urgencias por tumoración costal izquierda, sin antecedente traumático, con febrícula de 37,5 °C 48 h antes de la visita al hospital, afebril actualmente. No posee antecedentes familiares ni personales relevantes. No alergias. Calendario vacunal actualizado, incluyendo 3 dosis de vacuna antineumocócica 13 V (primera dosis lote G64205, segunda G75546), la tercera dosis de vacuna antineumocócica fue administrada 10 días antes (lote G92049). No clínica infecciosa previa salvo pico febril aislado de 38,6 °C sin otra sintomatología, 24 h después de la vacuna antineumocócica. La tumoración se localiza en el 6.º arco costal izquierdo, es dura y dolorosa a la palpación.