



Enfermedades Infecciosas y Microbiología Clínica

www.elsevier.es/eimc



Brief report

Legionella endocarditis: A case report and review

Andrea Teira^{a,*}, Juan Sánchez^a, Ignacio Santiago^a, Jesús Zarauza^a, Daniel Nan^b, Ramón Teira^c

^a Service of Cardiology, Hospital Universitario Marqués de Valdecilla, Santander, Cantabria, Spain

^b Service of Internal Medicine, Hospital Universitario Marqués de Valdecilla, Santander, Cantabria, Spain

^c Unit of Infectious Diseases, Service of Internal Medicine, Hospital de Sierrallana, Torrelavega, Cantabria, Spain



ARTICLE INFO

Article history:

Received 14 September 2020

Accepted 28 October 2020

Available online 27 December 2020

Keywords:

Infective endocarditis

Negative culture endocarditis

Coronary abscess

Legionella spp.

16S rDNA PCR

ABSTRACT

Background: *Legionella* is a well known but infrequent cause of bacterial endocarditis.

Methods: We report a case of endocarditis caused by *Legionella* spp. We reviewed previously reported cases in PubMed, Google Scholar and in references included in previous reports, and summarized relevant clinical data.

Results: A 63-year-old man with a history of aortic valve replacement developed persistent fever and monoarthritis. Transesophageal echocardiography showed perivalvular abscess. He died during surgery. Blood and valve cultures were negative. *Legionella* spp. was demonstrated with 16S-rRNA PCR from the resected material. Twenty cases of *Legionella* endocarditis have been reported. Harboring a prosthetic valve was the main risk factor. Prognosis was favorable, both for patients treated with or without surgical valve replacement. Overall mortality was <10%.

Conclusions: *Legionella* is an infrequent cause of endocarditis. It frequently requires surgical treatment. Prognosis is good. Molecular techniques are likely to become the gold standard for diagnosis.

© 2020 Sociedad Española de

Enfermedades Infecciosas y Microbiología Clínica. Published by Elsevier España, S.L.U. All rights reserved.

Endocarditis por *Legionella*: caso clínico y revisión

RESUMEN

Introducción: *Legionella* es una causa bien conocida, aunque infrecuente, de endocarditis bacteriana.

Métodos: A continuación, presentamos un caso de endocarditis por *Legionella* spp. Hemos revisado los casos publicados hasta la fecha en PubMed, Google Scholar y otras referencias incluidas en las comunicaciones previas, y resumimos aquí los datos clínicos relevantes. Un varón de 63 años con historia de recambio valvular aórtico desarrolló fiebre y monoartritis por lo que se realizó un ecocardiograma transesofágico que demostró un absceso perivalvular. Se decidió tratamiento quirúrgico, y el paciente falleció durante la cirugía. Los cultivos tanto de sangre como valvulares fueron negativos. El análisis mediante 16S rRNA PCR del material valvular resecado durante la cirugía demostró *Legionella* spp. Se han publicado un total de veinte casos de endocarditis por *Legionella* en la literatura médica. El principal factor de riesgo observado fue la presencia de una válvula protésica. El pronóstico fue bueno tanto para los pacientes tratados de manera conservadora como para aquellos sometidos a recambio valvular quirúrgico. La mortalidad global fue <10%.

Conclusiones: *Legionella* es una causa infrecuente de endocarditis. Generalmente requiere tratamiento quirúrgico. El pronóstico es bueno. Las técnicas moleculares podrían convertirse en el método de referencia para su diagnóstico.

© 2020 Sociedad Española de Enfermedades Infecciosas y Microbiología Clínica. Publicado por Elsevier España, S.L.U. Todos los derechos reservados.

Palabras clave:

Endocarditis infecciosa

Endocarditis con hemocultivos negativos

Absceso coronario

Legionella spp

16S rDNA PCR

* Corresponding author.

E-mail addresses: andreateira@gmail.com, andrea.teira@scsalud.es (A. Teira).

Introduction

Several species of the genus *Legionella* have been identified, albeit infrequently, as the causative agents of well documented cases of bacterial endocarditis. The real incidence of *Legionella* endocarditis is uncertain, as standard blood (and tissue) culture media do not support the growth of these microorganisms. In the last decade, an increase in the number of cases can be observed. This is probably due to the increased diagnostic yield provided by the introduction of molecular techniques. In our report, we outline a novel case of *Legionella* endocarditis and review previous reports, which provide notable conclusions as experience begins to accumulate with respect to the recognition and management of this disease.

Case report

A 63-year old man, with a past medical history of biological aortic valve replacement in 2015 due to aortic valve stenosis, was first admitted to the hospital in July 2019 with a fever that lasted over 96 h. The results of clinical examination and tests (chest radiography, transthoracic echocardiography, cultures, and urine analysis) revealed only mild neutropenia. An infectious agent or focus was not identified. He was diagnosed of presumptive viral infection and was discharged.

The patient continued to experience intermittent fevers; additionally, ten weeks after his discharge, he developed monoarthritis of the first metacarpophalangeal joint. Consequently, the patient was readmitted to the hospital.

Physical examination confirmed monoarthritis and also revealed palpable purpura. He had leukocytosis and a PCR value of 4.5 mg/dl. Serial blood cultures were negative, as well as serologic tests for *Mycoplasma pneumoniae*, *Coxiella burnetii*,

Bartonella henselae, *Brucella* sp., *Borrelia burgdorferi* and *Leptospira* sp. Serological testing for *Legionella* sp. was not performed.

A transesophageal echocardiogram was performed which showed vegetation in the aortic prosthesis and a large periprosthetic abscess (180° around the prosthesis). The abscess led to the formation of a fistula from the ventricular outflow tract to the ascending aorta. The mitral valve was free of vegetation; however, the abscess reached the mitro-aortic curtain (Fig. 1).

The patient was submitted for aortic root replacement and left coronary button re-implantation. He died during the procedure due to hemorrhagic and cardiogenic shock. Culture of the resected material was negative; however, 16S rRNA polymerase chain reaction was positive for *Legionella* spp.

Discussion

Epidemiology

Valvular *Legionella* infection was first described in 1984 in a 60-year-old woman with a mitral prosthetic valve. *Legionella* organisms are considered to cause lesser than 1% of all types of bacterial cardiac infections.²

We have reviewed 20 cases (11 men (55%) and 9 women (45%)); median age: 58.9 years old (range 28–80 years) of *Legionella* endocarditis reported in the medical literature.^{1–15}. The data on gender, age, clinical features, diagnostic tests, surgical treatment, and survival are summarized in Table 1.

The risk factors for the development of *Legionella* cardiac infections are not well known. A combination of previous medical history of pneumonia, immunosuppression, and prosthetic valves has been reported in the majority of the cases.

Our patient did not have a history of pneumonia or respiratory infection. According to previous reports, five patients (25%)

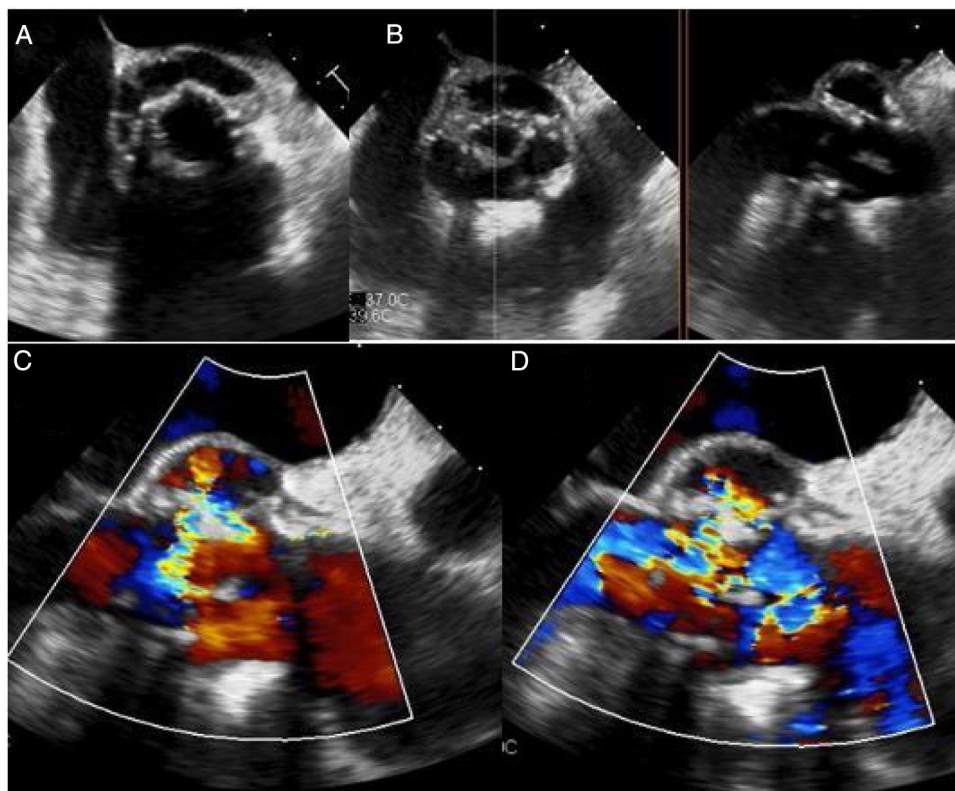


Fig. 1. (A) Transesophageal echocardiography (longitudinal plane) showing a circumferential abscess 180° around the aortic prosthesis; (B) X plane imaging with transesophageal echocardiography showing the periprosthetic abscess. (C and D) Transesophageal echocardiography (horizontal plane) showing fistula from the ventricular outflow tract to the ascending aorta on a color Doppler map.

Table 1
Main characteristics of patients at hospital admission from the twenty cases of *Legionella* endocarditis reported in the medical literature.

Author	Pub. year	Sex	Age	Pneumonia	Immuno-suppression	Valve localization	Valve type	Time from valve Repl.	Clinical presentation	Diagnostic test	Echocardiogram	Valve repl.	Antibiotic	Duration of treatment	Death
McCabe R.	1984	Fem	60	No	No	Aortic	Biological p.	>6 months	Fever	(+) valve culture (+) serology	New regurgitation	Yes	Erythromycin + Rifampin	6 months	No
Littrup P.	1987	Fem	38	Yes	No	Aortic	Native		Fever	(+) serology	Vegetation	No	Erythromycin	8 weeks	No
Tompkins LS	1988	Male	-	-	-	Aortic and mitral	Biological p.	>6 months	Fever	(+) serology (+) valve culture	Vegetation	Yes	Erytromicine + Rifampin	6 months	No
Tompkins LS	1988	Male	-	-	-	Aortic	Biological p.	>6 months	Fever	(+) serology (+) valve culture	New regurgitation	Yes	Erytromicine + Rifampin	6 monts	No
Tompkins LS	1988	Male	-	-	-	Aortic	Biological p.	>6 months	Fever	(+) serology (+) blood culture (+) valve culture	Negative	Yes	Erytromicine + Rifampin	9 months	No
Tompkins LS	1988	Fem	-	-	-	Mitral	Biological p.	>6 months	Fever	(+) serology (+) blood culture (+) valve culture	New regurgitation	Yes	Erytromicine + Rifampin	14 months	No
Tompkins LS	1988	Fem	-	-	-	Mitral	Biological p.	>6 months	Fever	(+) serology and blood culture (+) blood culture	New regurgitation	Yes	Ciprofoxacink + Rifampin	5 months	No
Tompkins LS	1988	Fem	-	-	-	Mitral	Biological p.	>6 months	Fever	(+) serology (+) blood culture	New regurgitation	No	Erytromicine + Rifampin	5 months	No
Park D.	1994	Male	65	Yes	No	Aortic	Biological p.	>6 months	HF	(+) serology	New regurgitation	Yes	Doxycycline	6 months	No
Chen	1996	Male	33	No	No	Ao	Mecanical p.	<6 months	Fever	HC (+) (+) valve	Negative	yes	Erytromicine	6 months	No
Massey R.	2003	Male	28	Yes	No	Aortic	Biological p.	>6 months	HF		New regurgitation	Yes	Clarithromycin + Rifampin	Unknown	No
Patel MC	2005	Male	63	No	Yes	Aortic	Biological p.	>6 months	Fever	(+) blood culture (+) PCR	Abscess	Yes	Levofloxacin	36 moths	No
Pearce MM.	2011	Fem	68	No	Yes	Aortic	Native		Chest pain	(+)PCR	Vegetation	Yes	Moxifloxacin	2 weeks	Yes
Samuel V.	2011	Fem	42	No	Yes	Aortic	Native		Fever	(+) blood culture (+) urinary antigen.	Vegetation	No	Levofloxacin + Rifampin	6weeks	No
Fukuta Y.	2012	Male	57	No	Yes	Mitral	Mecanical p.	>6 months	Brain abscess	(+) PCR	Abscess	Yes	Levofloxacin	5 months	No
Leggieri N.	2012	Male	73	No	No	Aortic	Biological p.	>6 months	Fever	(+) PCR (+) serology	Abscess	Yes	Erytromicine + Ciprofloxacín	6 weeks	No
Thurneysen C	2014	Fem	70	No	Yes	Mitral	Native		Arthritis	(+) synovial culture	Vegetation	No	Ciprofloxacín	3 months	No
Compain F.	2015	Fem	58	Yes	No	Aortic	Native		HF	(+) PCR	New regurgitation	Yes	Levofloxacin	3 weeks	No
Baumgartner V.	2016	Male	64	Yes	No	Aortic	Native		Fever	(+) serology	Vegetation	No	Clarithromycin	6 weeks	No
Young JS.	2019	Male	80	No	No	Mitral	Biological p.	>6 months	Fever	(+) serology (+) PCR	Vegetation	Yes	Levofloxacin	6 weeks	No

had received a diagnosis of pneumonia; however, the diagnosis of *Legionella* pneumonia was confirmed in only one patient (ref). In three cases, pneumonia had occurred in the year before the diagnosis of endocarditis and no microorganism had been identified; a fifth case had been diagnosed with *Mycoplasma* pneumonia one month prior to the diagnosis of *Legionella* endocarditis.

Although our patient was not immunosuppressed, four of the 20 (20%) cases reviewed had a history of immunosuppression. One patient had undergone renal transplantation and was receiving immunosuppressive treatment; a second patient had hypersensitivity pneumonitis and was treated with corticosteroids; a third patient was undergoing chemotherapy for Hodgkin disease; and the fourth patient had lupus and antiphospholipid syndrome and was being treated with corticosteroids and azathioprine.

Prosthetic valves seem to be the predisposing condition most strongly associated with the incidence of *Legionella* endocarditis. Out of the 20 reviewed cases, 2 cases (10%) were endocarditis on mechanical prostheses; 12 cases (60%) were endocarditis on biological prostheses; and 6 cases (30%) had occurred on native valves. All the prostheses had been placed at least 6 months before the diagnosis of *Legionella* endocarditis. Twelve (60%) cases had occurred on aortic valves, six cases (30%) involved the mitral valve; in one case both aortic and mitral valves were affected; the location of the endocarditis in the remaining case was not reported.

Clinical presentation

Legionella endocarditis is a chronic disease that presents long after surgery and is characterized, as seen in our patient, by low grade fever. The majority of the cases had a protracted clinical course featured by weakness and fever. Heart failure and chest pain have also been reported, while embolic phenomena have been rare. In our review, one patient presented with a brain abscess and another patient presented with arthritis. Arthritis was prominent in the case that we are reporting along with previously unreported palpable purpura.

Diagnosis

The diagnosis of *Legionella* endocarditis poses an extraordinary challenge. There is universal agreement in the central role achieved by the Duke criteria in the diagnosis of infective endocarditis.¹⁶ However, their limitations, which have been pointed out in the scenario for which they were developed (infective endocarditis caused by bacteria regularly grown on standard blood culture media) are particularly noteworthy in the case of *Legionella* endocarditis. Overall, 15 out of 20 reported cases (75%) can be considered to have received a definite diagnosis: 9 according to the Duke clinical criteria and 11 according to the pathological criteria (six cases fulfilled both types of criteria; four cases diagnosed by clinical criteria did not undergo surgery or had a negative microbiological study of the surgical samples; four clinically “possible” cases were confirmed pathologically; and, notably, two cases clinically rejected were diagnosed only after the identification of *Legionella* in the surgical samples). Of the remaining 5 cases, one could be rejected and 4 could be possibly considered as *Legionella* endocarditis with strict application of the Duke criteria. Serologic tests for anti-*Legionella* antibodies have been positive in 12/13 (92%) cases in which they are reported. They have been instrumental in the etiologic diagnosis in four patients. Unfortunately, serologic testing was not performed in our patient. Conversely, the results of the *Legionella* urinary antigen test were positive in only 2 of 6 cases in which it was reported.

Treatment

The treatment of *Legionella* endocarditis, as that of endocarditis of other etiologies, relies on two pillars: appropriate antibiotic

choice (regarding activity, pharmacokinetics, and duration) and appropriate surgical indication. There are no controlled studies to provide firm recommendations relative to the antibiotic choice, duration, or indications for surgery. From our review of reported cases, as summarized in Table 1, the following general statements can be inferred:

1. The prognosis of *Legionella* endocarditis is favorable, with an overall mortality of less than 10% (including our case).
2. Assuming an appropriate surgical indication for the reported cases, the prognosis appears to be equally good irrespective of surgery, as all six cases treated with medical therapy alone were reported to be cured.
3. Although long treatment-regimens were selected in earlier studies, more recent reports strongly suggest that shorter courses of antibiotics, not exceeding 6 weeks, are likely to cure most cases even in the absence of surgical intervention.

Conclusions

Bacteria of the genus *Legionella* are well-known; however, they rarely are determined to be the cause of culture-negative endocarditis. A high index of suspicion is necessary for progress in selecting the appropriate diagnostic tests in culture-negative endocarditis, given the poor yield of standard microbiological techniques in the identification of *Legionella* spp. The clinical course is subacute or chronic and embolic phenomena are rare. Most *Legionella* endocarditis patients have required valve replacements with good outcomes. PCR from valve material extracted during the surgery seems likely to replace culture for the identification of the bacteria in the material resected during surgery. Both fluoroquinolones and macrolides have been associated with the cure of the majority of the reported cases, with a treatment duration as short as 6 weeks (and shorter in isolated cases).

Funding

This review did not receive grant from any funding agency in the public, commercial, or non-for-profit sectors.

Conflict of interest

The authors report no conflicts of interest.

References

1. McCabe RE, Balwain JC, McGregor CA, Miller DC, Vosti KL. Prosthetic valve endocarditis caused by *Legionella pneumophila*. *Ann Intern Med*. 1984;100:525–7, <http://dx.doi.org/10.7326/0003-4819-100-4-525>.
2. Littrup P, Madsen JK, Lind K. Aortic valve endocarditis associated with *Legionella* infection after *Mycoplasma pneumoniae*. *Br Heart J*. 1987;58:293–5, <http://dx.doi.org/10.1136/hrt.58.3.293>.
3. Tompkins LS, Roessler BJ, Redd SC, Markowitz LE, Cohen ML. *Legionella* prosthetic-valve endocarditis. *N Engl J Med*. 1988;318:530–5, <http://dx.doi.org/10.1056/NEJM198803033180902>.
4. Park D, Pugliese A, Cunha BA. *Legionella micdadei* prosthetic valve endocarditis. *Infection*. 1994;22:213–5, <http://dx.doi.org/10.1007/bf01716708>.
5. Massey R, Kumar P, Pepper JR. Innocent victim of a localised outbreak: legionella endocarditis. *Heart*. 2003;89:16, <http://dx.doi.org/10.1136/heart.89.5.e16>.
6. Patel MC, Levi MH, Mahadevi P, Nana M, Merav AD, Robbins N. L. *micdadei* PVE successfully treated with levofloxacin/valve replacement: case report and review of the literature. *J Infection*. 2005;51:e265–8.
7. Pearce M, Theodoropoulos N, Noskin GA, Flaherty JP, Stemper ME, Aspeslet T, et al. Native valve endocarditis due to a novel strain of *Legionella*. *J Clin Microbiol*. 2011;49:3340–2, <http://dx.doi.org/10.1128/JCM.01066-11>.
8. Samuel V, Bajwa AA, Cury JD. First case of *Legionella pneumophila* native valve endocarditis. *Int J Infect Dis*. 2011;15:576–7, <http://dx.doi.org/10.1016/j.ijid.2011.04.007>.

9. Fukuta Y, Yildiz-Aktas IZ, William Pasculle A, Veldkamp PJ. *Legionella micdadei* prosthetic valve endocarditis complicated by brain abscess: case report and review of the literature. *Scand J Infect Dis.* 2012;44:414–8, <http://dx.doi.org/10.3109/00365548.2011.645506>.
10. Leggieri N, Gouriet F, Thuny F, Habib G, Raoult D, Casalta JP, et al. *Legionella longbeachae* and endocarditis. *Emerg Infect Dis.* 2012;18:95–7, <http://dx.doi.org/10.3201/eid1801.110579>.
11. Thurneysen C, Boggian K. *Legionella pneumophila* serogroup 1 septic arthritis with probable endocarditis in an immunodeficient patient. *J Clin Rheumatol.* 2014;20:297–8, <http://dx.doi.org/10.1097/RHU.000000000000128>.
12. Compain F, Bruneval P, Jarraud S, Perrot S, Aubert S, Napoly V, et al. Chronic endocarditis due to *Legionella anisa*: a first case difficult to diagnose. *New Microbes* *New Infect.* 2015;8:113–5, <http://dx.doi.org/10.1016/j.nmni.2015.10.003>.
13. Baumgartner V, Eich G, Christen S, Chmiel C. *Legionella* native valve endocarditis case report and review of literature. *Int Arch Med.* 2016;9, <http://dx.doi.org/10.3823/1885>.
14. Young JS, Farber BF, Pupovac SS, Graver LM. Prosthetic valve *Legionella Endocarditis.* *Ann Thorac Surg.* 2019;108:271–2, <http://dx.doi.org/10.1016/j.athoracsur.2019.02.006>.
15. Chen TT, Schapiro JM, Loutit J. Prosthetic valve endocarditis due to *Legionella pneumophila.* *J Cardiovasc Surg.* 1996;37:631–3.
16. Habib G, Lancellotti P, Antunes MJ, Bongiorni MG, Casalta JP, Del Zotti F, et al. ESC Scientific Document Group, 2015 ESC Guidelines for the management of infective endocarditis: The Task Force for the Management of Infective Endocarditis of the European Society of Cardiology (ESC). *Eur Heart J.* 2015;36:3075–128, <http://dx.doi.org/10.1093/eurheartj/ehv319>.