



LETTER TO THE EDITOR

FLAIR-hyperintense lesions in anti-MOG-associated encephalitis with seizures (FLAMES) in a patient with Crohn's disease on anti-TNF treatment



Lesiones hiperintensas en FLAIR asociadas a encefalitis con convulsiones por anticuerpos anti-MOG en un paciente con enfermedad de Crohn en tratamiento con fármacos anti-TNF

Dear Editor:

Introduction

The FLAIR-hyperintense lesions in anti-MOG-associated encephalitis with seizures (FLAMES) was first described by Ogawa et al. in 2017,¹ as a distinctive clinical-radiological syndrome from other anti-MOG antibody-associated demyelination syndromes, and often with a more indolent course.² The most frequent clinical manifestations of this syndrome are seizures, headache, fever and focal cortical deficits congruent with the localization of unilateral cortical FLAIR hyperintense lesions but is not infrequent to find bi-hemispheric affectation.³

Etiology and risk factors to develop the syndrome are still unknown. Some cases have been associated with concomitant anti-NMDAR antibodies^{4,5} but the association of anti-MOG related disorders and other autoimmune disease seems rare. Recently a case of FLAMES in a patient with inflammatory bowel disease (ulcerative colitis) on TNF inhibitor therapy have been reported.⁶

In this context, we present the case of a woman with Crohn's disease in treatment with adalimumab that developed FLAMES with a favorable outcome despite anti-TNF maintenance.

Case report

A 36-year-old right-handed woman was transferred to our third level hospital with a clinical picture of right parietal headache, fluctuating right hemispherical symptoms and signs, and eventually a generalized tonic-clonic seizure. His medical history is remarkable for suffering CD associated with HLA-B27 positive spondyloarthritis and hidradeni-

tis suppurativa in treatment with adalimumab biweekly and doxycycline.

Symptoms began in the previous month as right facial pain attributed to mandibular joint inflammation in context of spondyloarthritis but some days after, the pain presented in right parietal localization without remission. Three weeks after beginning of these symptoms, the patient is transferred by emergency services to her regional hospital because of sudden onset of intermittent involuntary movements of left hand with associated clumsiness and paresthesia during an hour and eventually dysarthria. Stroke is suspected, urgent CT scan showed subtle right parietal cortical gyri swelling and no vessel obstruction. During administration of intravenous alteplase the patient suffered abrupt clinical worsening in the form of left-side hemiplegia. A new CT scan did not show any hemorrhagic complications or other changes from the previous one. The patient in a few hours full-recovered spontaneously and only right parietal headache remained. In day five after admission MRI (Fig. 1) showed right hemisphere predominantly parietal cortical gyri and some sulci hyperintensity and swelling on FLAIR without the involvement of the adjacent juxta-cortical white matter, hypointensity in ADC and subtle hyperintensity on DWI suggesting diffusion restriction, subtle leptomeningeal gadolinium enhancement, vessels hyperintensity in susceptibility weight image compatible with hyperperfusion⁷ confirmed later by perfusion weighted MRI. During hospitalization the patient remained stable and without fever but on day seven suffered a generalized tonic-clonic seizure and was transferred to Intensive critical care treated with levetiracetam and without new alterations in urgent CT scan. Then the patient is transferred to our hospital. Upon arrival the neurological exam was unremarkable and the patient only complained of right parietal headache. A lumbar puncture was performed suspecting encephalitis or vasculitis. Results revealed mild lymphocytic pleocytosis with 25 cells/ μ L and all microbiological tests (including bacterial and fungal culture PCR por viruses including Herpes simplex and Varicella Zoster virus) were negative. Suspecting an autoimmune process including the possibility of FLAMES we solicited antibody testing for vasculitis and anti-myelin oligodendrocyte glycoprotein (MOG) in serum and decided to administer intravenous corticosteroids. We request a rheumatology and gastroenterology assessment of adalimumab withdrawal given the possibility of being related to the cerebral inflammatory process. Given the stability of the patient and not being able to attribute a clear causal relationship, it was agreed to maintain adalimumab. Autoimmunity testing for vasculitis including ANCA were negative. Electroencephalogram (EEG) showed right tempo-

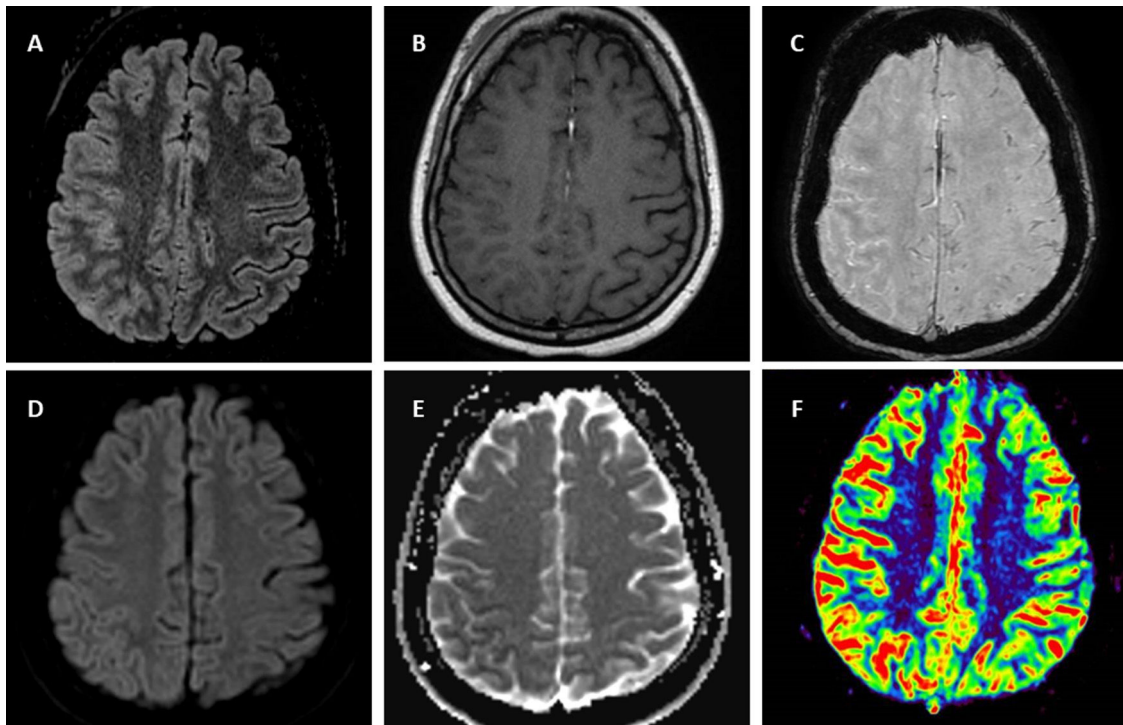


Figure 1 Brain 1.5T MRI of FLAIR-hyperintense Lesion in Anti-MOG-associated Encephalitis with Seizures. T2-fluid attenuated inversion recovery (FLAIR) imaging showing right parietal cortical gyri and some sulci hyperintensity and swelling without involvement of adjacent juxta-cortical white matter (A). Axial T1-weighted post-gadolinium imaging shows right parietal leptomeningeal enhancement (B). Axial susceptibility weighted imaging shows hyperintense vessels in the same region due to decreased oxygen extraction secondary to hyperperfusion (C) confirmed by perfusion imaging sequences (F). Diffusion restriction in posterior parietal gyri (D,E).

ral slow waves. The patient was discharged asymptomatic with levetiracetam and oral prednisone in a descending regimen during four weeks and with anti-MOG antibodies results pending. Few weeks later positive anti-MOG in serum (Euroimmune® cell based-assay) were received confirming FLAMES diagnosis. Oligoclonal bands in mirror pattern were found. Slow waves in four weeks control EEG were less frequent compared with the previous and eventually normalized. In the control MRI five weeks from discharge there was significant improvement of FLAIR hyperintensity and swelling. The patient remained asymptomatic except for sporadic right parietal headache. A recent MRI performed four months after the presentation of focal neurological symptoms showed resolution of FLAIR hyperintensity and the rest of alterations.

Discussion

We have presented the case of a patient who suffered FLAMES under treatment with anti-TNF. Recent publications have suggested an association between FLAMES and anti-TNF therapy.⁶ In our case, however, there has been a complete recovery while maintaining adalimumab.

In the study published in 2020 by Kunchok et al.⁸ there was an association between the use of anti-TNF therapy in patients with autoimmune pathology and the appearance of inflammatory phenomena in central nervous system, both

demyelinating and non-demyelinating, but the mechanism by which this association occurred could not be specified. Furthermore, there are several cases where patients with syndromes associated with anti-MOG in anti-TNF treatment are specifically reported, including patients with inflammatory bowel disease.⁹ However, it should be noted that a case has also been reported in which FLAMES developed after withdrawal of anti-TNF and azathioprine during pregnancy.¹⁰

Taking into account all the above, we agree that there should be a special surveillance of this syndrome (and other inflammatory events at the CNS level) in patients with inflammatory bowel disease receiving anti-TNF treatment, including in assessing the determination of anti-MOG before starting such a treatment. However, anti-TNFs are an effective drug in many immune-mediated diseases and withdrawing or maintaining this treatment will have to be weighed on a case-by-case and multidisciplinary basis. Prospective studies should be carried out with a large number of patients that confirm the association of anti-TNF with inflammatory events and which patients are at risk.

Funding

No acknowledgments nor funding for this paper.

References

- Ogawa R, Nakashima I, Takahashi T, Kaneko K, Akaishi T, Takai Y, et al. MOG antibody-positive, benign, unilateral, cerebral cortical encephalitis with epilepsy. *Neurol Neuroimmunol Neuroinflamm.* 2017;4.
- Budhram A, Sechi E, Nguyen A, Lopez-Chiriboga AS, Flanagan EP. FLAIR-hyperintense Lesions in Anti-MOG-associated Encephalitis with Seizures (FLAMES): is immunotherapy always needed to put out the fire? *Mult Scler Relat Disord* [Internet]. 2020;44:102283, <http://dx.doi.org/10.1016/j.msard.2020.102283>.
- Budhram A, Mirian A, Le C, Hosseini-Moghaddam SM, Sharma M, Nicolle MW. Unilateral cortical FLAIR-hyperintense Lesions in Anti-MOG-associated Encephalitis with Seizures (FLAMES): characterization of a distinct clinico-radiographic syndrome. *J Neurol.* 2019;266:2481–7.
- Zhou L, Zhang Bao J, Li H, Li X, Huang Y, Wang M, et al. Cerebral cortical encephalitis followed by recurrent CNS demyelination in a patient with concomitant anti-MOG and anti-NMDA receptor antibodies. *Mult Scler Relat Disord* [Internet]. 2017;18:90–2, <http://dx.doi.org/10.1016/j.msard.2017.09.023>.
- Fujimori J, Takahashi T, Kaneko K, Atobe Y, Nakashima I. Anti-NMDAR encephalitis may develop concurrently with anti-MOG antibody-associated bilateral medial frontal cerebral cortical encephalitis and relapse with elevated CSF IL-6 and CXCL13. *Mult Scler Relat Disord.* 2021;47:13–5.
- Chang YC, Sharma M, Budhram A. Unilateral cortical FLAIR-hyperintense Lesion in Anti-MOG-associated Encephalitis with Seizures (FLAMES) on TNF inhibitor therapy. *J Neurol Neurosurg Psychiatry.* 2021;2–3.
- Jain K, Cherian A, Divya KP, Rajalakshmi P, Thomas B, Nandana J. FLAMES: a novel burning entity in MOG IgG associated disease. *Mult Scler Relat Disord.* 2021;49, 2020.
- Kunchok A, Aksamit AJ, Davis JM, Kantarci OH, Keegan BM, Pittock SJ, et al. Association between tumor necrosis factor inhibitor exposure and inflammatory central nervous system events. *JAMA Neurol.* 2020;77:937–46.
- Philippart M, Fastré S, Rahier JF, London F. First report of coexistence of MOG-antibody-positive disease and Crohn's disease. *Mult Scler Relat Disord* [Internet]. 2019;28:1–3, <http://dx.doi.org/10.1016/j.msard.2018.12.006>.
- Stamenova S, Redha I, Schmierer K, Garcia ME. FLAIR-hyperintense lesions in anti-MOG-associated encephalitis with seizures (FLAMES) unmasked by withdrawal of immunosuppression for Crohn's disease? *Mult Scler Relat Disord.* 2021;48.

P. Cabezudo-García^{a,*}, M. Vidal Denis^b,
N.L. Ciano-Petersen^a, M.V. Irigoyen-Oyarzábal^c,
P.J. Serrano-Castro^a

^a Instituto de Investigación Biomédica de Málaga (IBIMA), Servicio de Neurología, UGC de Neurociencias, Hospital Regional Universitario de Málaga, Málaga, Spain

^b Servicio de Radiología, Hospital Regional Universitario de Málaga, Málaga, Spain

^c Instituto de Investigación Biomédica de Málaga (IBIMA), Servicio de Reumatología, Hospital Regional Universitario de Málaga, Málaga, Spain

* Corresponding author.

E-mail address: pablocabezudo@gmail.com

(P. Cabezudo-García).

<https://doi.org/10.1016/j.nrl.2021.06.002>
0213-4853/

© 2021 Sociedad Española de Neurología. Published by Elsevier España, S.L.U. This is an open access article under the CC BY-NC-ND license (<http://creativecommons.org/licenses/by-nc-nd/4.0/>).

Isolated speech-induced lingual dystonia successfully treated with botulinum neurotoxin



Distonía lingual inducida por el habla con respuesta favorable a toxina botulínica

Dear Editor:

Dystonia is a hyperkinetic disorder characterized by sustained or intermittent muscle contractions, resulting in abnormal repetitive movements and/or postures.¹ Oro-mandibular dystonia (OMD) is a focal type of dystonia that involves masticatory and/or lingual muscles. Lingual dystonia is one of its subtypes. According to some case series, it might take up to the 4% of all the dystonias assessed in a Movement Disorder Department.² Speech-induced lingual dystonia is rare. Mainly, it can be idiopathic and according to literature can be considered as an occupational dystonia in some patients.³ Despite its low prevalence, it can be very disabling and requires proper identification and management. We report here a case of a young man who presented with an isolated speech-induced lingual dysto-

nia with an excellent response to Botulinum neurotoxin (BoNT).

A 34 year-old man was referred to our department of Neurology with a five month history of slurred speech and progressive difficulty to move the tongue. A second-grade relative suffered from epilepsy, but there was no other family history of interest. He worked as telemarketer and spent up to eight hour-a-day speaking. Due to his symptoms, which continued worsening, he had to stop working and felt embarrassed when holding a conversation. No concomitant treatment or any other precipitating factor were found. His neurological exam revealed speech-induced tongue protrusion associated with mild to moderate dysarthria (Video 1). His symptoms improved when chewing gum (Video 2) or bread, as well as when speaking out. Brain MRI (including T2-sequence), electromyography (EMG), and extensive blood tests (including thyroid function, copper metabolism, folate and vitamin B12 levels) were normal. A diagnosis of idiopathic speech-induced focal dystonia (occupational) was performed and trihexyphenidyl (up to 4.5 mg) was started, obtaining slight improvement without remarkable secondary effects. Six months later BoNT was started. Specifically, 2.5 units of BoNT (Botox®, Allergan Pharmaceuticals) were injected intraoral bilaterally in only 1 point of each genioglossus muscle (Fig. 1). No secondary effects were observed. One week later he noticed slight