

## RESEARCH LETTERS

# Immediate allergic reactions by polyethylene glycol 4000: two cases

M. Antón Gironés, J. Roan Roan, B. de la Hoz and M. Sánchez Cano

Allergology Department of Ramon y Cajal Hospital. Madrid. Spain.

### ABSTRACT

The evacuant solution (ES) is a drug that has been used to clean the colon. The most common described side effects when using this drug are abdominal symptoms; skin rash is rare.

We report on two patients who presented urticaria and angioedem after the intake of an evacuant solution to make a rectoscopy.

We performed allergy studies: skin prick tests with common inhalants, pure ES and the components (polyethylene glycol 4000 (PEG 4000), KCl, NaCO<sub>3</sub>, NaPO<sub>3</sub>, NaSO<sub>3</sub>, NaCl, neohesperidine, potasic acesulfam and orange flavouring), intradermic test, total serum IgE and single-blind placebo oral challenge with ES and the components.

We report on the first cases of immediate allergy reactions (type1) caused by oral intake of a drug containing PEG 4000 which were demonstrated by intradermic tests and oral challenge.

**Key words:** Evacuant solution. Immediate allergy reactions. Intradermic tests. Polyethylene glycol 4000. Single-blind placebo oral challenge.

#### Correspondence:

Mónica Antón Gironés  
Hospital General de Elda  
Carretera Elda-Sax por la Torreta  
Elda 03600 (Alicante)  
E-mail: manton.girones@hotmail.com

### INTRODUCTION

The evacuant solution is a drug that has been used to clean the colon, like an enema to study some colonic lesions such as polyps, neoplasm or arteriovenous malformations and before practising surgery to this organ.

The most commonly described side effects when using this drug are: bloating, nausea, abdominal or stomach cramps, anus irritation or vomiting. Skin rash is rare.

We report on two patients who presented urticaria and angioedem after the intake of an evacuant solution to make a rectoscopy.

### FIRST CASE

A 36 year-old man referred to our Allergology Department for an episode of urticaria and lip swelling after the intake of an evacuant solution (Bohm®)

The reaction appeared half an hour after the drug consumption and he had not taken other drugs that day or on previous days. He was not atopic and he needed study of spastic colon.

We performed allergy studies: skin prick tests with common inhalants were negative; total serum IgE was 98 kU/l. We prepared 250ml of evacuant solution (ES) following the instructions of Bohm laboratories: skin prick test with pure solution was negative, but single-blind placebo oral challenge was positive with similar symptoms to the reaction that the patient suffered (Fig. 1).

Subsequently, we contacted Bohm laboratories in Spain and they furnished us the components of ES: polyethylene glycol 4000 (PEG 4000), KCl, NaCO<sub>3</sub>,

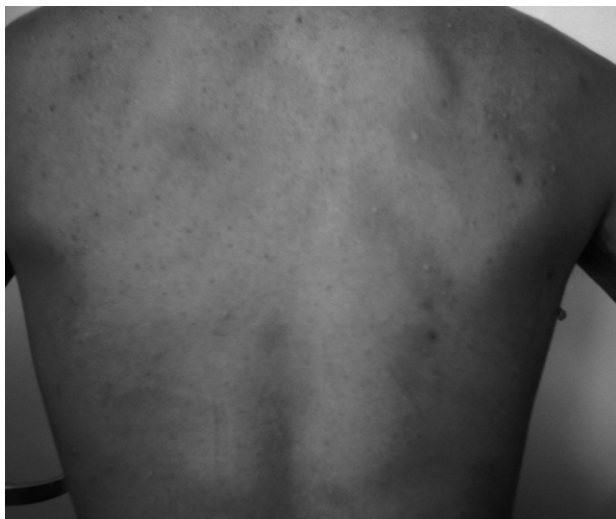

Figure 1.—Hives after oral challenge ES.

NaPO<sub>3</sub>, NaSO<sub>3</sub>, NaCl, neohesperidine, potasic aceulfam and orange flavouring.

Skin prick test were performed with: ES components and saline solution; ES and PBS; and ES components and human seric albumin to 1/10 concentration for each one. The results were negative, but single-blind placebo oral challenge with increasing doses of each component of ES on consecutive days was positive 5 minutes after the intake of 25cc of PEG 4000.

We wanted to know the immunologic mechanism of the reaction so we performed an intradermic test with PEG 4000 which was immediately positive to the 1/10 concentration (Fig. 2). The patient presented general urticaria with hives and nodules, rhinitis, nausea and vomiting; and he needed treatment.

## SECOND CASE

A non-atopic 44 year-old man referred to our Allergy Department for an episode of urticaria and angioedem one minute after the intake of ES, as above.

We performed similar allergy studies: skin prick test with common inhalants and ES and its components were negative, but single-blind placebo oral challenge with ES and PEG 4000 were positive; intradermic test was positive to the 1/10000 concentration of PEG 4000.

Despite the symptoms being "type I immunologic mechanism", we did not know the mechanism which made the reaction so serious. We performed patch tests with ES and its components and all of them were negative.

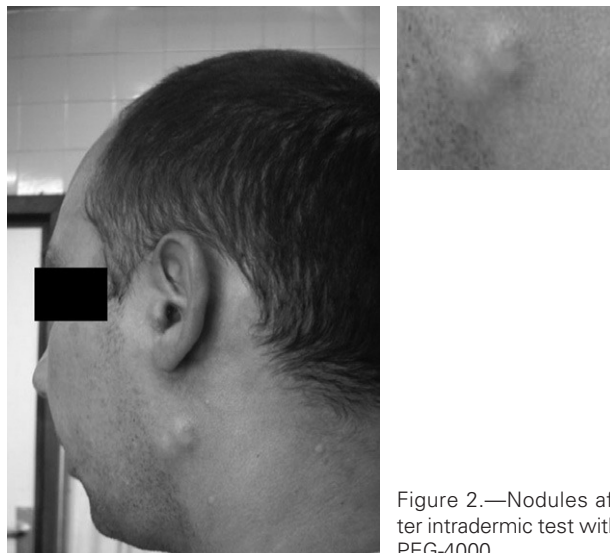


Figure 2.—Nodules after intradermic test with PEG-4000.

Control tests were performed on ten patients (five atopic and five non-atopic) and the results were negative.

## DISCUSSION

Polyethylene glycol 4000 is a hydrosoluble base used as a carrier in a lot of topical drugs, in creams and in body oils as an emulsion<sup>1</sup> (Table I).

It is a polymer of ethylen glycol molecules [H(OCH<sub>2</sub> CH) nOH] and its physical and chemical characteristics depend on the number of molecules. PEG slow molecular weight (200-700) are liquids and PEG high molecular weight (1000-7500) are soft or hard solids.

There are no references of other cases of allergic reactions after oral intake of ES or PEG. Side effects with PEG described to date have been nausea, vomiting, abdominal pain and rectal irritation if taken orally; and skin rash with a topical drug.

Bohm laboratories have no news of allergy reactions with ES. PEG can be the cause of eczemas or

Table I

### List of drugs with PEG

- 
- Creams and body oils
  - Evacuant solutions: Bohm<sup>®</sup>, Lainco<sup>®</sup>, Klean Prep<sup>®</sup>
  - Sperm-killing contraceptive: Lavolen<sup>®</sup>
  - Others: Bactroban<sup>®</sup>, Oftalmowell<sup>®</sup>, Synalar nasal<sup>®</sup>, Betadine<sup>®</sup>, Furacina<sup>®</sup>, Ibuprofeno Steve<sup>®</sup>, Antalgin<sup>®</sup>, Skin formulation
-

**Table II**  
**Contact dermatitis with PEG**

Author	Patient	Drug	Diagnosis
<b>Stenveld<sup>4</sup></b> Contact Dermatitis 1994; 30: 184	Man 44 years	Betadine <sup>®</sup> Furacina <sup>®</sup>	Patch test + (PEG 300,400,555)
<b>Córdoba<sup>5</sup></b> Am J Contact Derm 1999; 10(4): 226-7	Man 59 years	Betadine <sup>®</sup> Furacina <sup>®</sup>	Patch test + (atb and PEG)
<b>Le Coz<sup>6</sup></b> Contact Dermatitis 2001; 44(5):308-9	Woman 43 years	Body milk	Patch test + PEG
<b>Issakson<sup>7</sup></b> Contact Dermatitis 2002; 47(3): 175-6	Woman 25 years	Massage oils	Patch test + PEG

contact dermatitis as some articles about patch tests have demonstrated <sup>2-7</sup> (Table II).

## CONCLUSION

We report on the first cases of immediate allergy reactions (type1) caused by the oral intake of a drug containing PEG 4000 which were demonstrated by intradermic tests and oral challenge.

## ACKNOWLEDGMENTS

This report has been translated by Aurea Moreno Pastor.

## REFERENCES

1. Martindale. The extrapharmacopoeia. Reynolds J. The pharmaceutical press. 28<sup>th</sup> edition: 709-711.
2. Fisher et al. Immediate and delayed allergic contact reactions to polyethylene glycol. Contact Dermatitis 1978; vol 4(3): 135-138.
3. Bajaj AF et al. Contact sensitivity to polyethylene glycol. Contact Dermatitis 1990; 22:291.
4. Stenveld HJ et al. Contact sensitivity to polyethylene glycols. Contact Dermatitis 1994; 30: 184.
5. Guijarro SC et al. Allergic contact dermatitis to polyethylene glycol and nitrofurazone. Am J Contact Derm 1999; 10 (4): 226-227.
6. Le Coz J et al. Allergic contact dermatitis from methoxy PEG-17/dodecyl glycol copolymer. Contact Dermatitis 2001; 44(5): 308-309.
7. Issakson M. Occupational allergic contact dermatitis from PEG-4 rape seed amide in a massage oil. Contact Dermatitis 2002; 47(3): 175-176.