

Fixed drug eruptions induced by cross-reactive imidazoles

To the Editor:

Adverse drug reactions are a frequent cause of consultation in allergology and dermatology services that affect up to 10% of the population (20% in hospitalised patients). More than 10% of them are hypersensitivity reactions. Fixed drug eruptions (FDE) are defined as erythematous plaques recurring at the same anatomical localisation in every occasion that the drug is re-administered to the allergic patient. Lesions are well delimited rounded or oval plaques, erythematous to violaceous with an erythematous border, pruriginous and painful, various centimetres in diameter, and which can evolve to vesicles and leave residual hyperpigmentation.

Together with the exanthemas, urticaria, angio-oedema and multiforme erythema, FDE are the most common allergic reactions to drugs, constituting about 10% of all drug reactions.^{1,2} The drugs most commonly involved in FDE induction include phenolphthalein, sulphonamides, barbiturics, tetracyclins, aspirin and phenylbutazone.² In the present paper we will discuss the case of a patient who developed FDE to cross-reacting drugs containing the imidazole ring.

A 51-year-old male patient consulted because he noticed recurrent rounded erythematous and hyperpigmented plaques in the same anatomic areas for the last five years. The lesions were localised in the back, posterior surfaces of the thighs, dorsal aspect of the right hand, and lumbar region. The patient referred that he had similar lesions at the same sites in multiple occasions every time he took self-prescribed metronidazole for non-specific gastrointestinal complaints such as abdominal pain and meteorism. At the time he consulted to the allergy clinics he had lesions with the same characteristics as described above that had appeared four days after starting treatment with oral ketoconazole, 200 mg/d, which was prescribed for tinea pedis (Figures 1 and 2).

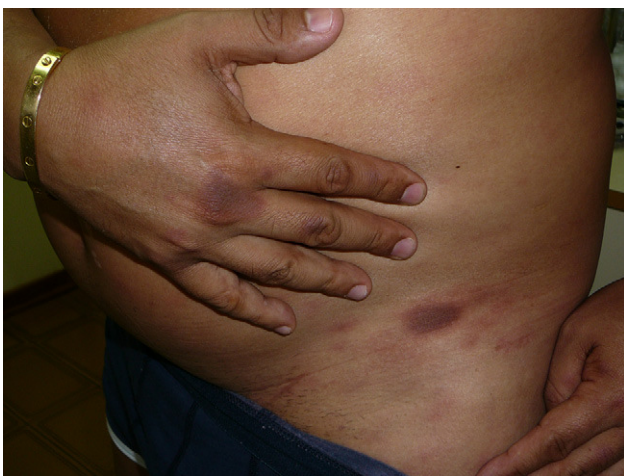

Figure 1 Erythematous and hyperpigmented plaques on the right hand and left groin.

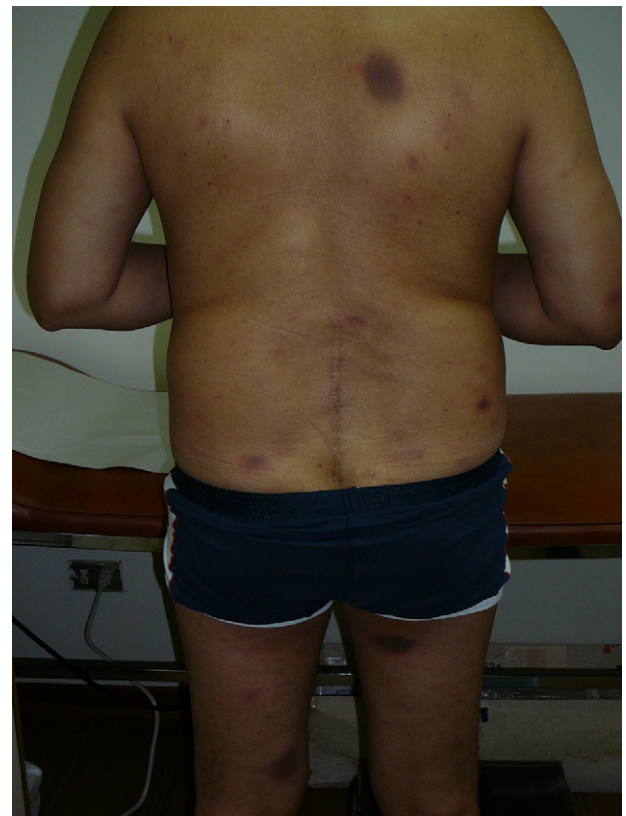


Figure 2 Fixed drug eruption lesions on the back and posterior surfaces of the thighs.

This patient has a FDE caused by two drugs that contain the imidazole ring in their chemical structure, metronidazole and ketoconazole. This nucleus is present in various frequently used, mainly antifungal and anti-parasitic pharmaceutical products (Table 1). Cross-reactions between imidazolic compounds, clinically manifested as FDE, have been rarely reported in the literature. Cross-reactions appearing as FDE have been observed between metronidazole and tinidazole,^{3,4} and between metronidazole and albendazole.⁵

Contact dermatitis due to cross-reactions between tioconazole and other imidazoles,⁶ and between ketoconazole and miconazole⁷ have also been published. Therefore, cross-reactions secondary to the topical application of imidazole-containing drugs can occur. Other cross-reactions of the imidazolic drugs occur with the preservative isoth-

Table 1 Drugs that contain the imidazole ring

Action	Drugs
Anti-fungal	Bifonazole, Clomidazole, Clotrimazole, Croconazole, Econazole, Fenticonazole, Ketoconazole, Isoconazole, Miconazole, Neticonazole, Oxiconazole, Sertaconazole, Sulconazole, Tioconazole
Anti-parasitic	Metronidazole, Tinidazole, Albendazole, Secnidazole

iazolonone. We are not aware of any published report of cross-reactivity between metronidazole and ketoconazole.

FDE due to cross-reacting drugs have been also observed between non-steroidal anti-inflammatory drugs of the oxicam group (piroxicam, tenoxicam, droxicam), and between oxyphenbutazone and phenylbutazone.⁸

Although this patient did not have any underlying condition that might predispose him for FDE, it has been proposed that diseases that are accompanied by intense immune stimulation, such as autoimmune and infectious diseases (for example, HIV and other viral infections), can increase the susceptibility to develop allergic drug reactions, especially those mediated by T cells (type IV allergic reactions).

The diagnosis of FDE is generally done by means of a history of drug exposure and examination of the lesions. The drug aetiology can be confirmed through a provocation test (contraindicated in patients with severe reactions) and by means of patch testing.⁸ In our case the patient had induced himself the skin lesions repeatedly during five years, and the diagnosis was so clear that a confirmatory challenge or patch tests were not considered necessary. The patient was instructed to avoid all imidazolic drugs, and a list of medications that contain the imidazole ring was provided. After avoidance for three years, no new skin lesions have appeared.

References

1. Kauppinen K, Stubb S. Drug eruptions: causative agents and clinical types. A series of in-patients during a 10-year period. *Acta Dermatol Venereol* (Stockholm). 1984;64:320–4.
2. Mahboob A, Haroon TS. Drugs causing fixed eruptions. *J Dermatol*. 1984;11:383–5.
3. Mishra D, Mobashir M, Zaheer MS. Fixed drug eruption and cross-reactivity between tinidazole and metronidazole. *Int J Dermatol*. 1990;29:740.
4. Thami GP, Kanwar AJ. Fixed drug eruption due to metronidazole and tinidazole without cross-sensitivity to secnidazole. *Dermatology*. 1998;196:368.
5. Mahboob A, Haroon TS. Fixed drug eruption with albendazole and its cross-sensitivity with metronidazole—a case report. *J Pak Med Assoc*. 1998;48:316–7.
6. Izu R, Aguirre A, González M, Díaz-Pérez JL. Contact dermatitis from tioconazole with cross-sensitivity to other imidazoles. *Contact Dermatitis*. 1992;26:130–1.
7. Imafuku S, Nakayama J. Contact allergy to ketoconazole cross-sensitive to miconazole. *Clin Exp Dermatol*. 2009;34:411–2.
8. Kanwar AJ, Bharija SC, Singh M, Belhaj MS. Ninety-eight fixed drug eruptions with provocation tests. *Dermatologica*. 1998;177:271–9.

M. Sánchez-Borges^{a,*}, L.A. González-Aveledo^b

^a *Allergy and Clinical Immunology Service, Clínica El Avila, Caracas, Venezuela*

^b *Dermatology Service, Centro Médico de Caracas, Caracas, Venezuela*

*Corresponding author.

E-mail address: sanchezbmario@gmail.com

(M. Sánchez-Borges).

doi:10.1016/j.aller.2010.07.003

Heavy metals and antioxidant trace elements in children with recurrent wheezing

In their very interesting article Razi et al.¹ have investigated the relation between serum heavy metals and antioxidant trace elements (selenium and zinc) in children with recurrent wheezing. They conclude that children with hyper-responsiveness may be more susceptible to exposure to mercury and lead, as happens with environmental exposure to heavy metals. They believe that heavy metals are important factors contributing (if not primary) to frequent wheezing.¹ The authors are to be congratulated for making this pivotal study. We would like to raise some points regarding the methods used in determining heavy metals in serum samples. It is feasible that exposure to toxic metals may have made children more vulnerable to recurrent wheezing attacks in comparison with other subjects, as noted by the authors in their study.¹ Nevertheless, the speculation that both mercury and lead may cause recurrent wheezing via a direct contrast effect on antioxidant trace elements, would have been strengthened greatly if they had used whole blood instead of serum samples from children to assess environmental exposure to heavy metals. In fact, mercury and lead are bound to red blood cells in the bloodstream.² We have described elsewhere³ that both serum and/or plasma does

not correctly reflect the degree of mercury and lead body burden.²

Given that there was an observed association between serum heavy metals and recurrent wheezing,^{1,4,5} extending this research is of paramount importance. In the future, it will be essential to include whole blood toxic metals analysis for the assessment of wheezing disorders in childhood.

Conflict of interest statement

We have no conflicts of interest connected with this work.

Funding

None.

References

1. Razi CH, Akin O, Harmanci K, Akin B, Renda R. Serum heavy metal and antioxidant element levels of children with recurrent wheezing. *Allergol Immunopathol (Madr)*. 2011. Jan 12. [Epub ahead of print].
2. Goyer RA, Clarkson TW. Toxic effects of metals. In: Klaassen CD, editor. *Casarett & Doull's Toxicology: the basic sci-*