

## ORIGINAL ARTICLE

# The effect of royal jelly on CD3<sup>+</sup>, CD5<sup>+</sup>, CD45<sup>+</sup> T-cell and CD68<sup>+</sup> cell distribution in the colon of rats with acetic acid-induced colitis

T. Karaca<sup>a,\*</sup>, N. Şimşek<sup>b</sup>, S. Uslu<sup>c</sup>, Y. Kalkan<sup>d</sup>, I. Can<sup>b</sup>, A. Kara<sup>b</sup>, M. Yörük<sup>c</sup>

<sup>a</sup> University of Trakya, Faculty of Medicine, Department of Histology and Embryology, Edirne, Turkey

<sup>b</sup> University of Ataturk, Faculty of Veterinary Medicine, Department of Histology and Embryology, Erzurum, Turkey

<sup>c</sup> University of Yuzuncu Yil, Faculty of Veterinary Medicine, Department of Histology and Embryology, Van, Turkey

<sup>d</sup> University of Rize, Faculty of Medicine, Department of Histology and Embryology, Rize, Turkey

Received 31 May 2011; accepted 9 September 2011

Available online 23 November 2011

### KEYWORDS

Colitis;  
Royal jelly;  
Lymphocytes;  
Macrophages;  
Rat

### Abstract

**Background:** Traditional medicines and health supplements have historically been used to treat many illnesses but most of them have not been evaluated objectively to prove their efficacy. We have been investigating the effects of royal jelly (RJ) supplements on acetic acid-induced colitis on the distribution of CD3<sup>+</sup>, CD5<sup>+</sup>, CD45<sup>+</sup> T-cell and CD68<sup>+</sup> cells in rats.

**Methods:** The rats were divided into four equal groups: control group, royal jelly-treated (RJ – 150 mg kg<sup>-1</sup> body weight), acetic acid-treated (colitis) and acetic acid-treated (colitis) + royal jelly (CRJ – 150 mg kg<sup>-1</sup> body weight). Colitis was induced by intracolonic instillation of 4% acetic acid; the control group received physiological saline (10 mL kg<sup>-1</sup>). Colon samples were obtained under deep anaesthesia from animals in four groups. Tissues were fixed in 10% formalin neutral buffer solution for 24 h and embedded in paraffin.

**Results:** The proliferative response of CD3<sup>+</sup> and CD45<sup>+</sup> T cells stimulated with colitis was affected by colitis treated with RJ. No differences were found in CD5<sup>+</sup> T cells and CD68<sup>+</sup> macrophages in the colitis treated with RJ.

**Conclusions:** This study has shown that RJ has anti-inflammatory and cell regeneration effect in the colon of rats with acetic acid induced colitis.

© 2011 SEICAP. Published by Elsevier España, S.L. All rights reserved.

## Introduction

Mucosal surfaces of the intestinal tract represent one of the main routes for microbial pathogens to enter a host and are important sites of microbially induced diseases. The intestinal immune system is responsible for protecting a large surface area from invasion by pathogens,

\* Corresponding author.

E-mail addresses: turankaraca74@hotmail.com, turan.karaca@omu.edu.tr (T. Karaca).

whilst remaining tolerant to a complex microflora and to dietary Ags.<sup>1</sup> Pathogens might lead to acute inflammation, characterised by an excessive production of inflammatory mediators. These are responsible for the recruitment of specific cell types, for example, lymphocytes, macrophages, or neutrophils.<sup>2</sup>

A characteristic feature of the immune system at the mucosal surfaces, such as the respiratory and intestinal tracts, is that protective, cell-mediated and humoral immune responses against invading pathogens are allowed to proceed whilst pathogenic responses against innocuous antigens are prevented. The importance of an intact immune system for intestinal homeostasis is shown by the fact that a number of immune manipulations, including the deletion of cytokine genes and alterations in T lymphocytes subsets, lead to the development of an inflammatory bowel disease-like syndrome in mice.<sup>3</sup> A number of infiltrated lymphocytes, neutrophils, macrophages and natural killer cells are significantly increased after injury induced by toxins such as alcohols, CCl<sub>4</sub>, and acetic acid and most of which causes activation of lymphocytes, neutrophils, monocytes and macrophages.<sup>4</sup> The activation of these cells causes apoptosis, necrosis and inflammations with release to cell death ligand.<sup>5,6</sup> Following damage and inflammation in cell tissue, repair by anti-inflammatory agents takes place in necrotic and apoptotic cells.<sup>6</sup>

Natural compounds, such as components of Royal Jelly (RJ), can play a significant role against inflammation, cancer,<sup>7</sup> colitis,<sup>8</sup> liver damage,<sup>9</sup> immunomodulatory,<sup>10</sup> cell proliferation,<sup>11</sup> and hepatocyte and tubular cell apoptosis,<sup>12</sup> RJ that is produced by the hypopharyngeal and mandibular glands of worker honeybees contains a variety of free amino acids, vitamins and sugars. A number of biological and immunoregulatory effects attributed to RJ have been reported.<sup>13</sup> In addition, Şimşek et al.<sup>14</sup> reported that RJ might be used as a supportive agent in immune deficiency and anaemic patients, because of both the increased erythrocyte count and the diameter.

The aim of this study was to evaluate the protective and antioxidative effect of RJ in acetic acid-induced colitis by determining changes in distribution of T-lymphocytes and macrophages.

## Material and methods

Twenty-four adult, Wistar, albino rats ( $n=6 \times 4$ ) weighing about 230–300 g were obtained from the Laboratory of Animal Science, Medical School, Firat University, Elazığ, Turkey. The animals were given standard rat pellets (Van Feed Factory, Van, Turkey) and tap water *ad libitum* and were housed in individual cages (360 mm  $\times$  200 mm  $\times$  190 mm), each containing three animals, for seven days prior to the start of the experiment.

The rats were divided into four equal groups. Control group, royal jelly-treated (RJ), acetic acid-treated (colitis) and acetic acid-treated (colitis) + royal jelly (CRJ). Control group received normal food and water during the experiment. The RJ group received normal food and royal jelly (150 mg kg<sup>-1</sup>) suspended in water. The Colitis group received normal food and a dose of acetic acid dissolved in 0.9% NaCl delivered via the anus to the colon. The CRJ group received

normal food along with 150 mg kg<sup>-1</sup> royal jelly suspended in water and a dose of acetic acid dissolved in 0.9% NaCl delivered via the anus to the colon. The RJ used was purchased from a local natural food store in Istanbul, Turkey. All animals were housed in stainless steel cages under standard laboratory conditions (light period 07.00 h to 20.00 h,  $21 \pm 2$  °C, relative humidity 55%), and received humane care according to the criteria outlined in the *Guide for the Care and Use of Laboratory Animals* prepared by the National Academy of Sciences and published by the National Institute of Health.

All experimental animals were not fed for 24 h before induction of colitis. Each rat was lightly anaesthetised with ether, and a polyethylene cannula was inserted into the lumen of the colon via the anus. The tip of the cannula was positioned at 8 cm proximal to the anus. Either 1 mL of acetic acid (4% vol/vol in 0.9% NaCl) or saline as the inert control was slowly infused into the distal colon. After 30 s exposure, 1 mL of saline (0.9%) was instilled in order to withdraw the previous solution from the colon.<sup>8,15</sup>

One month after initiation of the experiment, rats were euthanized under ether anaesthesia and the colon of each was excised and gently rinsed under tap water. The colon was then stretched on a piece of cork with mucosal surface upwards in the standard position for macroscopic examination and the severity of colitis was scored with the help of a magnifying glass. Finally, the colon was dissected and fixed in 10% formalin neutral buffer solution at room temperature for 24 h and cross-sections were processed routinely for light microscopy. Sections of 5  $\mu$ m were stained with Mallory's triple stain and examined under a light microscope.

Colon tissue samples were fixed in 10% formalin neutral buffer solution, embedded in paraffin, and cut in 5  $\mu$ m sections. CD3, CD5, CD45 and CD68 positive cells were determined with streptavidin–biotin–peroxidase staining method. Antigens were retrieved in deparaffinised and rehydrated sections by boiling in citrate buffer (10 mM, pH 6) for 15 min. T lymphocytes (CD3, CD5 and CD45) and monocyte/macrophage lineage cells (CD68) were determined with streptavidin–biotin–peroxidase staining method. For immunohistochemistry examinations, anti-CD3, anti-CD5, anti-CD45 (Abbotec – USA) and monoclonal mouse anti-CD68 (Clone KP1, Invitrogen, 08-0125) primary antibodies and biotinylated secondary antibody (DAKO-Universal LSAB Kit-K0690) were used. The binding sites of antibody were covered with 3,3'-diaminobenzidine (Sigma) or aminoethyl-carbazole substrate kit (AEC kit; Zymed Laboratories) and evaluated by high-power light microscopic (Nikon i50 or Optiphot 2, Japan). For each specimen, CD3<sup>+</sup>, CD5<sup>+</sup>, CD45<sup>+</sup> and CD68<sup>+</sup> immunoreactivity was determined in ten randomly selected areas using an approximately X20 objective lens.

## Results

Light microscopy examination of the colon mucosa of control rats and RJ rats stained with Mallory's triple stain showed normal mucosal glands. The rats from the acetic acid-induced colitis group exhibited severe damage to the colon mucosa, with pathological changes including massive destruction of the epithelial layer and cellular debris,

**Table 1** Distribution of CD3<sup>+</sup>, CD5<sup>+</sup>, CD45<sup>+</sup> and CD68<sup>+</sup> cells.

Groups	CD3	CD5	CD45	CD68
Control	+	++	+	++
Royal jelly	+	++	+	++
Colitis	++++	++++	+++	++++
Colitis + royal jelly	++	++	++	++

haemorrhagic colitis in the colon mucosa and gross lesions in the colon. The colon mucosa of the colitis plus RJ group rats (oral treatment with 150 mL kg<sup>-1</sup> RJ) showed superficial ulceration and slight focal congestion and the crypts appeared normal.

Colonic CD3<sup>+</sup>, CD5<sup>+</sup>, CD45<sup>+</sup> T cells and CD68<sup>+</sup> macrophages levels were significantly elevated in colitic rats, although no change was induced by the RJ (Table 1). The proliferative response of CD3<sup>+</sup> and CD45<sup>+</sup> T cells stimulated with colitis was affected by colitis treated with RJ. No differences were found in CD5<sup>+</sup> T cells and CD68<sup>+</sup> macrophages in the colitis treated with RJ compared with control group rats. The histological appearance and distributions of immunopositive cells are summarised in Figs. 1 and 2 and Table 1.

In all rats, CD3<sup>+</sup>, CD5<sup>+</sup> and CD45<sup>+</sup> T cells, were mainly observed in the subepithelial region, between crypts and deep lamina propria whereas they were rarely observed in lamina epithelium. There was a striking increase in CD68<sup>+</sup> cells in deep lamina propria, between crypts and near crypts in the colitic group, particularly where inflammation was severe. However, there were a decreased number of these cells in the colitis treated with RJ group compared with colitis group rats.

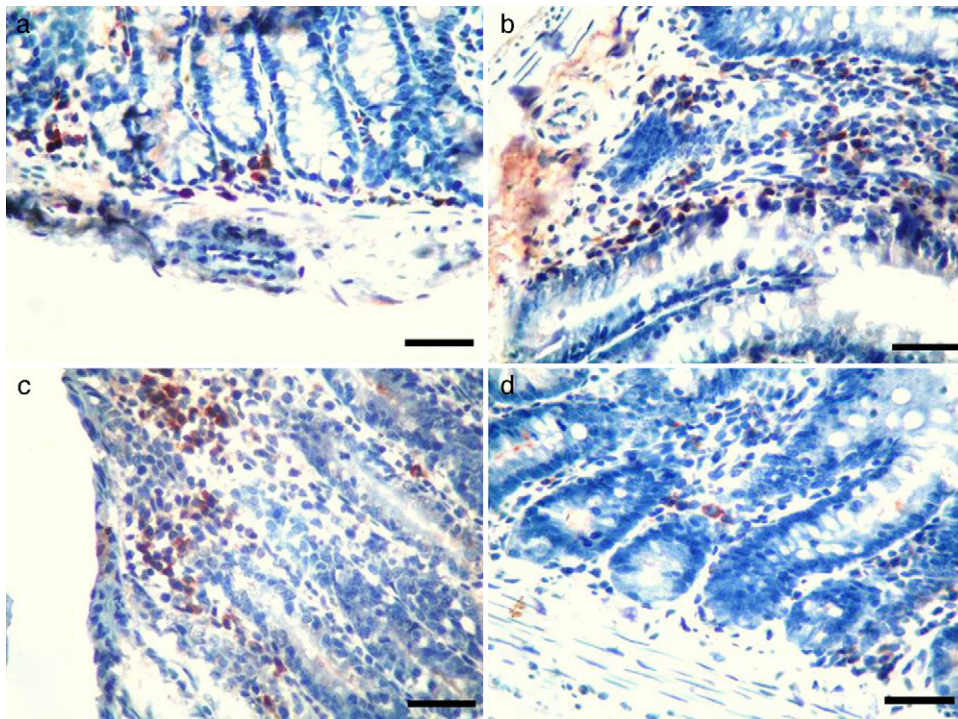
## Discussion

In this study, distribution of T-cell and macrophages in acetic acid-induced colitis in rats. Paraffin section immunohistochemistry with antibodies against CD3, CD5, CD45 and CD68 was stained. Previous studies referred to in this report, demonstrate the immunomodulatory properties of RJ.<sup>10,16,17</sup> Hamerlinck (1999) showed that RJ exhibited immunomodulatory properties by stimulating antibody production and immunocompetent cell proliferation in mice or by depressing humoral immune functions in rats.<sup>18</sup> Royal jelly has been shown to exhibit anti-inflammatory, DNA-protective,<sup>13</sup> and anti-tumour effects in experimental animals.<sup>19,20</sup> The protection afforded by RJ against the immunosuppression produced by increased PGE<sub>2</sub> levels has been demonstrated in studies *in vivo*<sup>21</sup> and *in vitro*.<sup>13</sup>

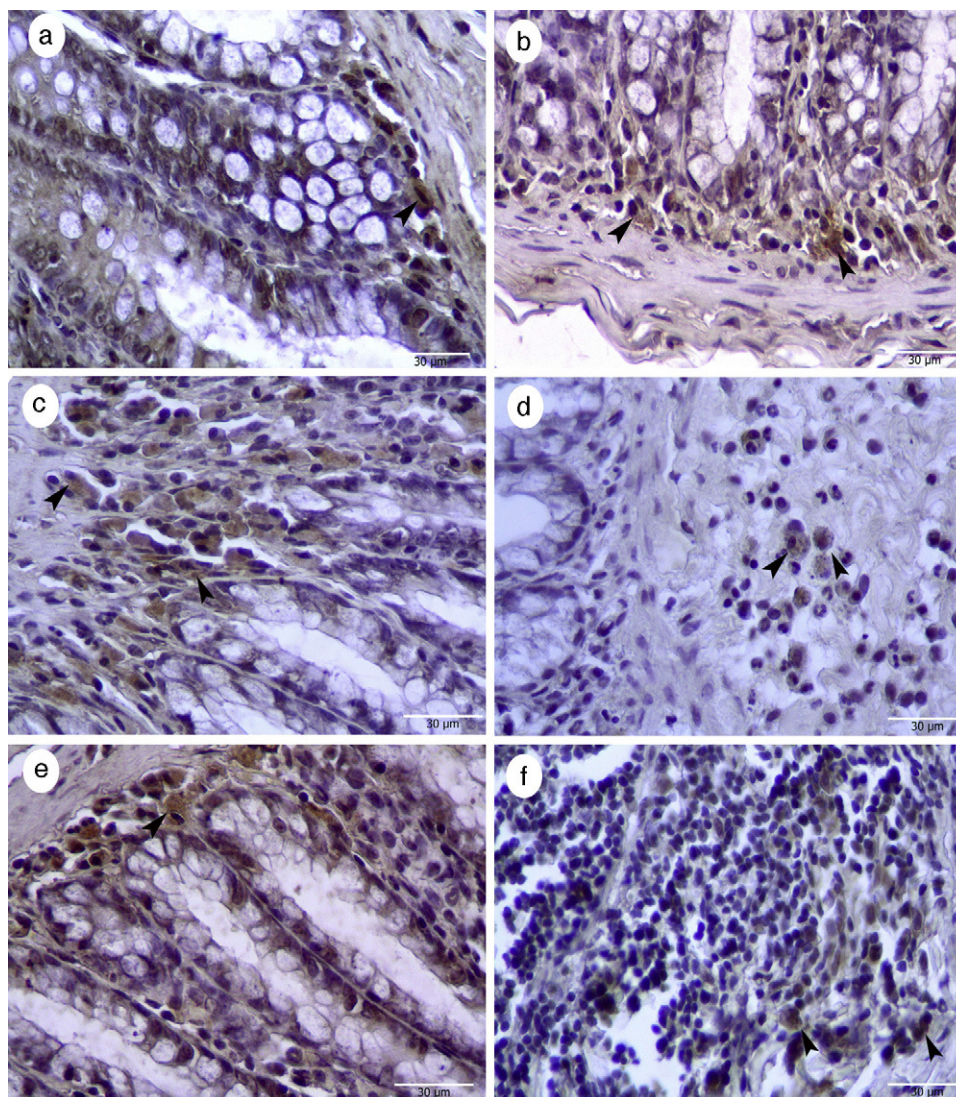
The previous study suggested a potential protective effect of RJ against the toxic hazards of fumonisins. In another study it was reported that RJ in the diet decreased the gene expression of cytochrome P450 4A14 enzymes and detoxifying enzymes, which catalyse peroxidation of endogenous lipids, and increased the gene expression of glutathione S-transferase and glutathione peroxidase.<sup>8,22,23</sup>

We found increases in CD3<sup>+</sup>, CD5<sup>+</sup>, CD45<sup>+</sup>, and CD68<sup>+</sup> cells in the colon induced by acetic acid. The previous studies' results suggested that mucosal CD4<sup>+</sup> cells tend towards the lamina propria of the villi in the duodenum and jejunum.<sup>24</sup> In the ileum and colon, the CD4<sup>+</sup> lymphocytes were equally distributed throughout the mucosa.

The previous studies reported that at higher concentrations, RJ fatty acids inhibited the proliferation of T cells. The same study suggested that lower concentrations of



**Figure 1** Immunohistochemical characteristics of T lymphocytes. (a) Control group, CD5, (b) royal Jelly group, CD3; (c) colitis group, CD45; (d) colitis + royal jelly group, CD45. Bar: 30 μm.



**Figure 2** Colon CD68<sup>+</sup> cells by immunohistochemical. (a) Control group, (b) royal Jelly, (c-d) colitis, (e-f) colitis + royal jelly group. Bar: 30 µm.

fatty acids inhibited maturation of dendritic cells. Many fatty acids used as supplementary diets inhibited inflammation and suppressed strongly different components of the immune system including T-cell proliferation.<sup>25-27</sup> Treatment of colitic rats with an oral dose of RJ gave a degree of recovery from acute colitis.<sup>8</sup> The anti-colitogenic effects of RJ could be attributed to improvement of the antioxidant status of the animals due to an increase in mucin content of the colon mucosa.<sup>28</sup> Polyphenolic compounds in their many forms are the main components responsible for the functional properties associated with many foods, such as antioxidant capacity<sup>29,30</sup> and anti-inflammatory capacity.<sup>31</sup> In this study, CD68<sup>+</sup> cell numbers were elevated with colitis, but significant differences were found in the colitis treated with RJ group. However, CD3<sup>+</sup> and CD45<sup>+</sup> T-cells density was increased in colitis treated RJ compared to control group rats.

A previous study has shown that the CD8<sup>+</sup>/CD44<sup>high</sup> T cell population increased in frequency in mice with established inflammation.<sup>32</sup> However, another study demonstrated there

were no increases in the CD8<sup>+</sup>/CD44<sup>high</sup> T cell population.<sup>1</sup> Also, Carlsen et al.<sup>33</sup> reported that the CD40<sup>high</sup>CD68<sup>+</sup> macrophages were significantly higher in severely inflamed specimens. In this study, it was determined that the proportion of Colonic CD3<sup>+</sup>, CD5<sup>+</sup>, CD45<sup>+</sup> T cells and CD68<sup>+</sup> macrophages were significantly decreased in the colitis treated with RJ group when compared to colitis group rats. A decreased number of CD68<sup>+</sup> cells in colitis + RJ group possibly contribute to the decrease in mucosal inflammation.

In summary, we have shown that oral supplement RJ can be useful in restoring a previously impaired immune function in acetic acid-induced colitis rats. To further evaluate the beneficial effects of RJ in rats, experiments with rat colitis models are particularly useful.

### Conflict of interest

The authors have no conflict of interest to declare.

## References

1. Ho J, Kurtz CC, Naganuma M, Ernst PB, Cominelli F, Rivera-Nieves JA. CD8<sup>+</sup>/CD103<sup>high</sup> T cell subset regulates TNF-mediated chronic murine ileitis. *J Immunol.* 2008;180:2573–80.
2. Porath D, Riegger C, Drewe J, Schwager J. Epigallocatechin-3-gallate impairs chemokine production in human colon epithelial cell lines. *J Pharmacol Exp Ther.* 2005;315:1172–80.
3. Asseman C, Fowler S, Powrie F. Control of experimental inflammatory bowel disease by regulatory T cells. *Am J Respir Crit Care Med.* 2000;162:S185–9.
4. Ramadori G, Saile B. Portal tract fibrogenesis in the liver. *Lab Invest.* 2004;84:153–9.
5. Canbay A, Feldstein A, Baskin-Bey E, Bronk SF, Gores GJ. The caspase inhibitor IDN-6556 attenuates hepatic injury and fibrosis in the bile duct ligated mouse. *J Pharmacol Exp Ther.* 2004;3:1191–6.
6. Saile B, Ramadori G. Inflammation, damage repair and liver fibrosis role of cytokines and different cell types. *Z Gastroenterol.* 2007;45:77–86.
7. Chen C, Shen G, Hebbar V, Hu R, Owuor ED, Kong AN. Epigallocatechin-3-gallate-induced stress signals in HT-29 human colon adenocarcinoma cells. *Carcinogenesis.* 2003;24:1369–78.
8. Karaca T, Bayiroglu F, Yoruk M, Kaya MS, Uslu S, Comba B, et al. Effect of royal jelly on experimental colitis induced by acetic acid and alteration of mast cell distribution in the colon of rats. *Eur J Histochem.* 2010;54:e35, 158–61.
9. Kanbur M, Eraslan G, Beyaz L, Silici S, Liman BC, Altınordu S, et al. The effects of royal jelly on liver damage induced by paracetamol in mice. *Exp Toxicol Pathol.* 2009;61:123–32.
10. Sver L, Orsolic N, Tadic Z, Njari B, Valpotic I. A royal jelly as a new potential immunomodulator in rats and mice. *Comp Immunol Microbiol Infect Dis.* 1996;19:31–8.
11. Katiyar SK, Mukhtar H. Tea antioxidants incancer chemoprevention. *J Cell Biochem Suppl.* 1997;27:59–67.
12. Karadeniz A, Şimşek N, Karakuş E, Yıldırım S, Kara A, Can I, Kisa F, Turkel M. Royal jelly modulates oxidative stress and apoptosis in liver and kidneys of rats treated with cisplatin. *Oxidative Med Cell Longevity*, doi:10.1155/2011/981793, in press.
13. Kohno K, Okamoto I, Sano O, Arai N, Iwaki K, Ikeda M, et al. Royal jelly inhibits the production of proinflammatory cytokines by activated macrophages. *Biosci Biotechnol Biochem.* 2004;68:138–45.
14. Şimşek N, Karadeniz A, Bayraktaroğlu AG. Ratlarda periferik kan hücreleri üzerine L-karnitin, arı sütü ve nar çekirdeğinin etkileri. *Kafkas Üniv Vet Fak Derg.* 2009;15:63–9.
15. Kang JW, Kim TW, La JH, Sung TS, Kim HJ, Kwon YB, et al. Electroacupuncture ameliorates experimental colitis induced by acetic acid in rat. *J Vet Sci.* 2004;5:189–95.
16. Taniguchi Y, Kohno K, Inoue S, Koya-Miyata S, Okamoto I, Arai N, et al. Oral administration of royal jelly inhibits the development of atopic dermatitis-like skin lesions in NC/Nga mice. *Int Immunopharmacol.* 2003;3:1313–24.
17. Okamoto I, Taniguchi Y, Kunikata T, Kohno K, Iwaki K, Ikeda M, et al. Major royal jelly protein 3 modulates immune responses in vitro and in vivo. *Life Sci.* 2003;5:2029–45.
18. Hamerlinck FF. Neopterin: a review. *Exp Dermatol.* 1999;9:167–76.
19. Nakaya M, Onda H, Sasaki K, Yukiyooshi A, Tachibana H, Yamada K. Effect of royal jelly on bisphenol A-induced proliferation of human breast cancer cells. *Biosci Biotechnol Biochem.* 2007;71:253–5.
20. Fujii A. Pharmacological effect of royal jelly. *Honeybee Sci.* 1995;16:97–104 (Abstract).
21. Oka H, Emori Y, Kobayashi N, Hayashi Y, Nomoto K. Suppression of allergic reactions by royal jelly in association with the restoration of macrophage function and the improvement of Th1/Th2 cell responses. *Int Immunopharmacol.* 2001;1:521–32.
22. El-Nekeety AA, El-Kholy W, Abbas NF, Ebaid A, Amra HA, Abdel-Wahhab MA. Efficacy of royal jelly against the oxidative stress of fumonisin in rats. *Toxicol.* 2007;50:256–69.
23. Kamakura M, Maebuchi M, Ozasa S, Komori M, Ogawa T, Sakaki T, et al. Influence of royal jelly on mouse hepatic gene expression and safety assessment with a DNA microarray. *J Nutr Sci Vitaminol (Tokyo).* 2005;51:148–55.
24. Vega-Lopez MA, Telemo E, Bailey M, Stevens K, Stokes CR. Immune cell distribution in the small intestine of the pig: immunohistological evidence for an organized compartmentalization in the lamina propria. *Vet Immunol Immunopathol.* 1993;37:49–60.
25. Calder PC. N-3 polyunsaturated fatty acids, inflammation and immunity: pouring oil on troubled water or another fishy tale? *Nutr Res.* 2001;21:309–41.
26. Endres S, Meydani SN, Ghorbani R, Schindler R, Dinarello CA. Dietary supplementation with n-3 fatty acids suppresses interleukin-2 production and mononuclear cell proliferation. *Leukoc Biol.* 1993;54:599–603.
27. Kelley DS. Modulation of human immune and inflammatory responses by dietary fatty acids. *Nutrition.* 2001;17:669–73.
28. Nieto N, Torres MI, Rios A, Gil A. Dietary polyunsaturated fatty acids improve histological and biochemical alterations in rats with experimental ulcerative colitis. *J Nutr.* 2002;132:11–9.
29. Kerem Z, Chetrit D, Shoseyov O, Regev-Shoshani G. Protection of lipids from oxidation by epicatechin, trans-resveratrol, and gallic and caffeic acids in intestinal model systems. *J Agric Food Chem.* 2006;54:10288–93.
30. Almaraz N, Campos MG, Avila JA, Naranjo N, Herrera J, Gonzalez LS. Antioxidant activity of polyphenolic extract of monofloral honeybee collected pollen from mesquite (*Prosopis juliflora*, Leguminosae). *J Food Compos Anal.* 2007;20:119–24.
31. Wu YH, Zhou CX, Li XP, Song LY, Wu XM, Lin WY, et al. Evaluation of antiinflammatory activity of the total flavonoids of *Laggera pterodonta* on acute and chronic inflammation models. *Phytother Res.* 2006;20:585–90.
32. Kontoyiannis D, Boulougouris G, Manoloukos M, Armaka M, Apostolaki M, Pizarro T, et al. Genetic dissection of the cellular pathways and signaling mechanisms in modeled tumor necrosis factor-induced Crohn's-like inflammatory bowel disease. *J Exp Med.* 2002;196:1563–74.
33. Carlsen HS, Yamanaka T, Scott H, Rugtveit J, Brandtzaeg P. The proportion of CD40<sup>+</sup> mucosal macrophages is increased in inflammatory bowel disease whereas CD40 ligand (CD154)<sup>+</sup> T cells are relatively decreased, suggesting differential modulation of these costimulatory molecules in human gut lamina propria. *Inflamm Bowel Dis.* 2006;12:1013–24.