

- Bannon GA. What makes a food protein an allergen? *Curr Allergy Asthma Rep.* 2004;4:43–6.
- Lin RY, Schwartz LB, Curry A, et al. Histamine and tryptase levels in patients with acute allergic reactions: an emergency department-based study. *J Allergy Clin Immunol.* 2000;106:65–71.
- Fernandez-Rivas M, Cuevas M. Peels of Rosaceae fruits have a higher allergenicity than pulps. *Clin Exp Allergy.* 1999;29:1239–47.
- Bianchi A, Di Rienzo Businco A, Bondanini, Mistrello G, Carlucci A, Tripodi S. Rosaceae-associated exercise-induced anaphylaxis with positive SPT and negative IgE reactivity to Pru p3. *Eur Ann Allergy Clin Immunol.* 2011;43:122–4.

S. Miceli Sopo^{a,*}, S. Monaco^a, V. Giorgio^a, M. Calvani^b, G. Mistrello^c, R. Onesimo^a

^a *Department of Paediatrics, Catholic University, Rome, Italy*

^b *Department of Paediatrics, San Camillo Hospital, Rome, Italy*

^c *Lofarma SpA, Milano, Italy*

*Corresponding author.

E-mail address: smicelisopo@rm.unicatt.it (S. Miceli Sopo).

<http://dx.doi.org/10.1016/j.aller.2012.07.009>

Fixed drug eruption due to ibuprofen with patch test positive on the residual lesion

To the Editor,

Ibuprofen is a non-steroidal anti-inflammatory drug that belongs to the propionic acid group.¹ Skin reactions to ibuprofen include urticaria, angio-oedema, contact dermatitis and photosensitivity. Fixed drug eruption due to ibuprofen has rarely been described.

Fixed drug eruption is characterised by sudden onset of round and/or oval, oedematous, dusky-red macules on the skin and/or mucous membranes, accompanied by burning and/or itching.²

We report a case of fixed drug eruption due to ibuprofen with tolerance to acetylsalicylic acid.

A 64-year-old man with no history of atopy or drug allergy presented one year ago with three pruritic erythematous macules on his right knee, right calf, and right flank, as well as an aphthous ulcer on the oral mucosa, a few hours after taking allopurinol (Faes Farma SA; Madrid, Spain) and ibuprofen (Kern Pharma SL; Madrid, Spain). The mucosal lesions resolved some days later without treatment, leaving hyperpigmented lesions on the affected skin measuring 4 cm in diameter. The patient had previously tolerated both drugs.

The patient was referred to our Allergy Department for further study. He reported that the previous day he had taken ibuprofen and tetrazepam (Sanofi-Synthelabo; Barcelona, Spain) for a muscular contracture. Eight hours after taking the drugs, he developed the same skin lesions, although with no aphthous ulcers on the oral mucosa. Skin sections of the right calf showed a variable dermal perivascular and bandlike lymphocytic and eosinophilic infiltrate with focal basilar vacuolopathy and post inflammatory pigmentation.

One month later, the patient underwent patch testing (upper back) with allopurinol 1% and 10%, ibuprofen 1% and 5%, and tetrazepam 1% and 10%, all in petrolatum (Nonwoven Patch test Strips Curatest®; Lohman&Rauscher International; Rangsdorf, Germany). Ibuprofen 1% and 5% were applied to the calf lesion. The results of the patch test on the residual lesion at 48 and 96 h were positive with ibuprofen 1% (++) and ibuprofen 5% (+++) (Fig. 1). The results

of the tests on the upper back were all negative. Patch tests in 10 control subjects were all negative.

After obtaining the patient's informed consent, we performed a single blind oral challenge with allopurinol and tetrazepam. The results were negative for both drugs.

To investigate possible cross-reactivity between other non-steroidal anti-inflammatory drugs, we carried out a single blind oral challenge with acetylsalicylic acid, and the result was negative. We therefore recommended the patient to avoid propionic acid group drugs and take only the remaining non-steroidal anti-inflammatory drugs.

Fixed drug eruption is a non-immediate reaction that is well described in the literature.³ The exact pathogenesis of fixed drug eruption is unknown.²

Patch testing is a simple and safe method to identify certain causative agents of fixed drug eruption, especially if residual lesions persist.² In our case, patch test with

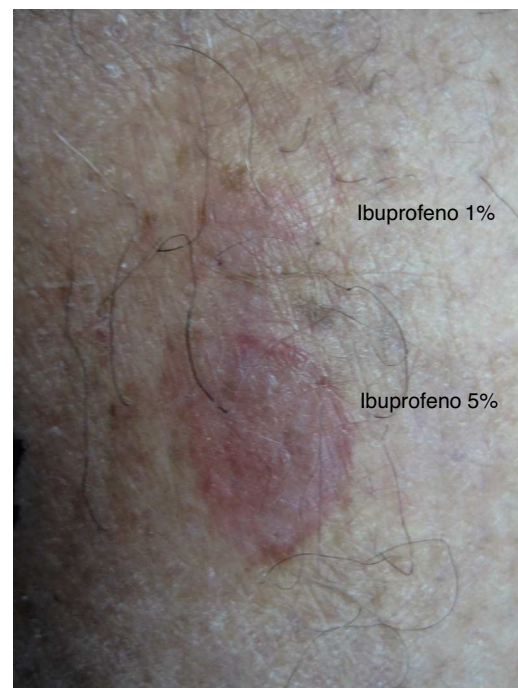


Figure 1 Patch test positive with ibuprofen 1% and 5% on the residual lesion.

ibuprofen was positive in a residual lesion, while patch test with the same drug was negative in upper back.

We were curious to know if our patient was sensitised to the rest of the propionic acid group, but due to the small area affected skin, we could not test these additional drugs. Therefore all propionic acid group drugs were forbidden. The patient tolerated acetylsalicylic acid, and then we recommended the use of the rest of non-steroidal anti-inflammatory drugs.

Díaz-Jara et al.¹ described two children, one of them with a fixed drug eruption after the ingestion of ibuprofen. Patch test was positive with ibuprofen on the residual lesion. Kanwar et al.⁴ analysed 98 cases of fixed drug eruption and in only six of these ibuprofen was the responsible drug. The diagnosis was performed by provocation tests.

Kuligowski et al.⁵ described a patient with a multiple fixed drug eruption with mucosa affectation due to ibuprofen. Patch test was positive on affected skin.

In summary, we report a case of fixed drug eruption due to ibuprofen that was confirmed by positive patch test and skin biopsy. The patient tolerated acetylsalicylic acid, therefore all propionic acid group drugs were forbidden.

Ethical disclosures

Patients' data protection. Confidentiality of data. The authors declare that they have followed the protocols of their work centre on the publication of patient data and that all the patients included in the study have received sufficient information and have given their informed consent in writing to participate in that study.

Right to privacy and informed consent. The authors declare that no patient data appears in this article.

Protection of human subjects and animals in research. Protection of human and animal subjects. The authors declare that no experiments were performed on humans or animals for this investigation.

Conflict of interest

The authors have no conflict of interests to declare.

References

1. Díaz-Jara M, Pérez Montero A, Gracia Bara MT, Cabrerizo S, Zapatero L, Martínez Molero MI. Allergic reactions due to ibuprofen in children. *Pediatric Dermatol.* 2001;18:66-7.
2. Sánchez-Morillas L, Laguna-Martínez JJ, Reaño-Martos M, Gómez-Tembleque P, Rojo-Andrés E. Fixed drug eruption caused by amoxicillin-clavulanic acid. *Ann Allergy Asthma Immunol.* 2008;101:335.
3. Rojas Pérez-Ezquerro P, Sánchez-Morillas L, Santos Alvarez A, Gómez-Tembleque P, Blanco Moratíel H, Laguna Martínez H. Fixed drug eruption caused by amoxicillin-clavulanic acid. *Contact Dermatitis.* 2010;63:294-6.
4. Kanwar AJ, Bharija SC, Singh M, Belhaj MS. Ninety-eight fixed drug eruptions with provocation tests. *Dermatologica.* 1988;177:274-9.
5. Kuligowski ME, Chang A, Rath R. Multiple fixed drug eruption due to ibuprofen. *Contact Dermatitis.* 1991;25:259-60.

L. Sánchez-Morillas^{a,*}, P. Rojas Pérez-Ezquerro^a, M.L. González Morales^b, R. González-Mendiola^a, J.J. Laguna Martínez^a

^a *Allergology Department, Hospital Central de la Cruz Roja, Madrid, Spain*

^b *Anatomy Pathology Department, Hospital Central de la Cruz Roja, Madrid, Spain*

* Corresponding author.

E-mail address: lsanchezmorillas@hotmail.com (L. Sánchez-Morillas).

<http://dx.doi.org/10.1016/j.aller.2012.04.007>

Injection site reaction to adalimumab: Positive skin test and successful rapid desensitisation

To the Editor,

Rheumatoid arthritis (RA) is a chronic and systemic autoimmune disease capable of causing substantial joint damage and disability. Anti-TNF therapeutic agents, such as etanercept, infliximab, and adalimumab, have been reported to be effective treatment alternatives in RA patients who are not well-controlled by conventional anti-rheumatic drugs.^{1,2} Both immediate and delayed type hypersensitivity reactions have been described with etanercept and infliximab since they are considered immunogenic.^{3,4} However, the administration of adalimumab, as a fully humanised anti-TNF- α , has not been expected to cause immune mediated reactions but it has been associated with both a variety of

dermatological reactions, including injection site reaction (ISR) or systemic hypersensitivity reactions.^{3,5} We describe a patient who presented with progressive ISR to adalimumab (Humira[®]) injections, with positive skin test and successful subcutaneous rapid desensitisation.

A 26-year-old woman had an eight-year history of RA, having received hydroxychloroquine, oral steroid, methotrexate, and sulfasalazine without significant benefit and was switched to 100 mg of infliximab, infusion twice monthly. She responded very well to infliximab, but experienced a decrease in the efficacy of the drug after seven years. She was then started on 40 mg/0.8 ml adalimumab subcutaneous injections, twice monthly, with significant improvement. She tolerated injections for five months and then developed pruritus, redness, and swelling 4 cm \times 4 cm in diameter at the site of injection within 1 hour of the 11th injection. The redness and swelling lasted 4-5 days before gradual resolution. A second and third injection of adalimumab again resulted in pruritus, redness, and