

## Source of funding

Bial Aristegui Laboratories funded the study conducted in vitro. The other resources used in this work belong to the Spanish Health System.

## Ethical disclosures

**Protection of human and animal subjects.** The authors declare that the procedures followed were in accordance with the regulations of the responsible Clinical Research Ethics Committee and in accordance with those of the World Medical Association and the Helsinki Declaration.

**Confidentiality of data.** The authors declare that they have followed the protocols of their work centre on the publication of patient data and that all the patients included in the study have received sufficient information and have given their informed consent in writing to participate in the study.

**Right to privacy and informed consent.** The authors have obtained the informed consent of the patients and/or subjects mentioned in the article. The author for correspondence is in possession of this document.

## Acknowledgements

The author specially thanks doctors Cortés, de la Cueva, Echenagusía, Franco, Gómez, Iglesias, Montero, Ortega, Rodríguez-Bernal and Salvatierra for their expert view and helpful discussion of the case.

## References

- Gamboa P, Sanchez-Monge R, Sanz ML, et al. Sensitization to *C. sativa* caused by a novel allergenic lipid transfer protein, Can s 3. *J Allergy Clin Immunol.* 2007;120:1459–60.
- De Larramendi CH, López-Matas MA, Ferrer A, et al. Prevalence of sensitization to cannabis sativa. Lipid-Transfer and Thaumatin-Like proteins are relevant allergens. *Int Arch Allergy Immunol.* 2013;162:115–22.
- Nayak AP, Green BJ, Sussman G, et al. Characterization of *Cannabis sativa* allergens. *Ann Allergy Asthma Immunol.* 2013;111:32–7.
- Laemmli UK. Cleavage of structural proteins during the assembly of the head of bacteriophage T4. *Nature.* 1970;227:680–5.
- Towbin H, Staehelin I, Gordon J. Electrophoretic transfer of proteins from polyacrylamide gels to nitrocellulose sheets: Procedures and some applications. *Proc Natl Acad Sci U S A.* 1979;76:4350–4.
- Majmudar V, Azam NA, Finch T. Contact urticaria to *C. sativa*. *Contact Dermatitis.* 2006;54:127.
- Williams C, Thompstone J, Wilkinson M. Work-related contact urticaria to *C. sativa*. *Contact Dermatitis.* 2008;58:62–3.
- Pastorello EA, Farioli L, Pravettoni V, et al. The maize major allergen, which is responsible for food-induced allergic reactions, is a lipid transfer protein. *J Allergy Clin Immunol.* 2000;106:744–51.
- Ebo DG, Swerts S, Sabato V, Hagendorens MM, et al. New food allergies in a European non-Mediterranean region: is *Cannabis sativa* to blame? *Int Arch Allergy Immunol.* 2013;161:220–8.
- Asero R, Mistrello G, Roncarolo D, et al. Immunological cross-reactivity between lipid transfer proteins from botanically unrelated plant-derived foods: a clinical study. *Allergy.* 2002;57:900–6.

P. Rojas Pérez-Ezquerria<sup>a,\*</sup>, L. Sánchez-Morillas<sup>a</sup>, G. Davila-Ferandez<sup>b</sup>, F.J. Ruiz-Hornillos<sup>c</sup>, I. Carrasco García<sup>a</sup>, M. Herranz Mañas<sup>a</sup>, J.J. Laguna Martínez<sup>a</sup>, B. Bartolomé<sup>d</sup>

<sup>a</sup> Allergy Unit, Hospital Central de la Cruz Roja, Madrid, Spain

<sup>b</sup> Allergy Unit, Hospital Universitario del Henares, Coslada, Madrid, Spain

<sup>c</sup> Allergy Unit, Hospital Infanta Elena, Valdemoro, Madrid, Spain

<sup>d</sup> Research & Development Department, Bial-Aristegui, Bilbao, Spain

\*Corresponding author.

E-mail address: [patricia.rojas@salud.madrid.org](mailto:patricia.rojas@salud.madrid.org) (P. Rojas Pérez-Ezquerria).

<http://dx.doi.org/10.1016/j.aller.2013.10.002>

## DRESS syndrome induced by meropenem

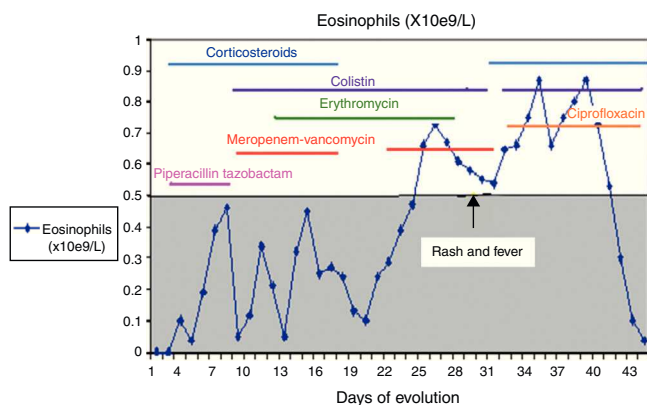


Drug reaction with eosinophilia and systemic symptoms (DRESS) syndrome is just one of the several synonymous terms used to describe a severe, idiosyncratic reaction to a drug, presenting clinically as an extensive cutaneous rash, accompanied by fever, lymphadenopathy, hepatitis, haematological abnormalities with eosinophilia and atypical lymphocytes, and may involve other organs with eosinophilic infiltration, especially the kidneys, heart, lungs and pancreas. This syndrome has been described to be mainly induced by anticonvulsants, allopurinol, sulphonamides,

antiretroviral therapy and some antibiotics.<sup>1</sup> Anticonvulsants and allopurinol were the drugs most commonly associated with DRESS, and almost 20% of the patients had DRESS associated with antibiotics. Recognition of this syndrome is of paramount importance, since the mortality rate is about 10–20% and specific therapy may be necessary.<sup>2</sup>

We describe a case of DRESS syndrome induced by meropenem, with a tolerance to other beta-lactam agents, where epicutaneous test and lymphocyte activation test (LAT) have proved useful as a diagnostic method.

A 53-year-old female, without toxic habits or relevant medical history, was hospitalised 45 days previously due to serious traumatic injuries resulting from a road traffic



**Figure 1** Eosinophilia and antibiotic schedule during hospitalisation.

accident (evacuated mass lesion head injury, closed abdominal and thorax injuries and multiple bone injuries), with resolved septic shock and suffering from acute respiratory failure caused by late-onset nosocomial pneumonia. After stabilisation of haemodynamics and respiratory difficulty, she presented a maculopapular rash forming large plaques and superficial vesicles, predominantly on the limbs, gradually affecting over 50% of the body, with peaks of fever and a tendency towards hypotension and tachycardia.

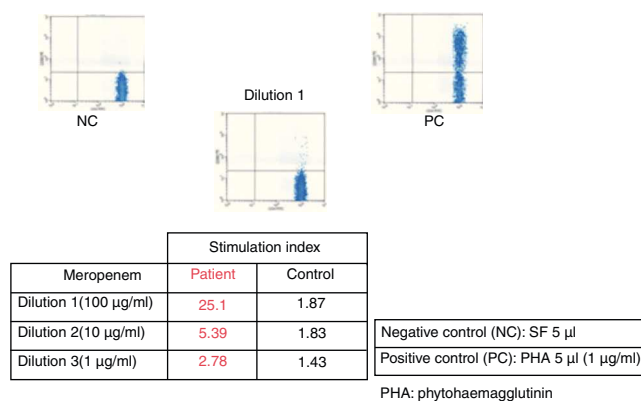
Blood tests revealed 13% eosinophilia with  $0.87 \times 10^9/L$  eosinophils (0.05–0.5),  $15.930 \times 10^9/L$  (3.8–11.5) leukocytes, 460 IU/L (10–50) GPT and normal renal function. A skin biopsy revealed interface dermatitis of vacuolar type, minimal spongiosis with slight superficial lymphocyte infiltration and abundant eosinophils, together with isolated necrotic keratinocytes. These findings were compatible with toxicoderma.

A culture performed on bronchial aspirate revealed ciprofloxacin sensitive *Pseudomonas aeruginosa* and colimycin sensitive *Acinetobacter baumannii*. During hospitalisation, she had required different courses of antibiotics, details of which are given in Fig. 1.

Although her symptoms can partly be explained by the infectious process, a pharmacological adverse reaction was suspected due to the cutaneous rash, the deterioration of her clinical condition, and the results of blood tests and biopsy. Antibiotic treatment with meropenem was interrupted, and treatment with corticoids, antihistamines, ciprofloxacin and colimycin was initiated.

The patient's haemodynamics improved in 24h, and the cutaneous and systemic symptoms cleared over the following two weeks, presenting normal laboratory test results.

After six weeks, epicutaneous tests were performed – rather than prick and intradermal due to the delayed nature of the reaction test – with beta-lactams, (penicillin G, amoxicillin, cefuroxime, ceftriaxone, piperacillin-tazobactam and meropenem) at 10% in petrolatum, with a positive result after 48–96h for meropenem and a negative reading for the remaining antibiotics. A LAT<sup>4</sup> was also completed, (testing three concentrations of the drug: 100, 10 and 1 mcg/ml), with a positive result for meropenem (Fig. 2) and a negative result for vancomycin, ceftriaxone



**Figure 2** Positive lymphocyte activation test with meropenem. PHA: phytohaemagglutinin; NC: negative control; PC: positive control.

and piperacillin-tazobactam. Given the need for subsequent treatment with beta-lactam antibiotics, a controlled exposure test was performed with vancomycin (125, 250 and 500mg) ceftriaxone (0.25, 0.25, 0.5 and 1g) and piperacillin-tazobactam (0.5, 1.5 and 2g) with increasing doses at 1-h intervals, without any reactions being observed.

DRESS syndrome is an uncommon, severe adverse reaction to medicinal drugs, and difficult to diagnose due to its variable clinical presentation and its late onset in relation to the period of introduction of the causative drug, occurring between 3 weeks and 3 months, at an average of 2–8 weeks.<sup>1,2</sup> In this case, diagnosis and treatment were complex due to the presence of severe infections, the need for antibiotic therapy and the multiple drugs administered. The symptoms resolved after suspension of meropenem and by using the RegiSCAR scoring system (fever, maculopapular rash, haematological alternations such as eosinophilia and leucocytosis with liver disorders) we obtained a final score of 5, making the probable diagnosis of DRESS syndrome.<sup>3</sup> The LAT is an in vitro method for the diagnosis of drug allergies measuring the expression of CD69 in peripheral blood CD4+ T lymphocytes using flow cytometry.<sup>4</sup> LAT test and epicutaneous test have proven to be useful in the diagnosis of delayed T-cell lymphocyte mediated drug hypersensitivity. In DRESS syndrome, epicutaneous tests are positive in up to 64% of cases<sup>5</sup>; data from large series with LAT tests are not available.<sup>4</sup> The positivity of both methods for meropenem in the patient confirms meropenem was the culprit drug. Given the high mortality rate in DRESS syndrome, in most cases due to liver failure, the controlled exposure test, the gold standard for the diagnosis for drug allergies, is contraindicated.<sup>6</sup> However, given the clinical condition of the patient and the subsequent need for antibiotics, we decided, with the consent of the patient, to perform controlled exposure tests with the antibiotics piperacillin-tazobactam, vancomycin and ceftriaxone. In this case, the epicutaneous and LAT tests have proven useful not only to confirm that the causative drug was meropenem, but had also negative predictive value for the tolerance of piperacillin-tazobactam, vancomycin and ceftriaxone.

Although the beta-lactam most frequently involved in this syndrome is amoxicillin-clavulanate, other non-amino

penicillin beta-lactams such as piperacillin-tazobactam<sup>7</sup> and ceftriaxone<sup>8</sup> have been reported as the causative drugs in DRESS syndrome, using an in vivo patch test for diagnosis. Two cases of DRESS syndrome with similar results to ours have been reported, one induced by ceftriaxone, obtaining results negative in patch tests and with a positive lymphocyte transformation test (LTT), and another induced by piperacillin-tazobactam with negative patch tests and a positive LTT.<sup>9</sup> Hypersensitivity syndrome due to meropenem and imipenem has been reported by Goto et al.<sup>10</sup> based on clinical course, laboratory data, and results of lymphocyte-stimulation tests. They did not perform epicutaneous test or tolerance challenge of betalactams.

In conclusion, this is the first description in literature, to our knowledge, of a DRESS syndrome to meropenem, and piperacillin-tazobactam and ceftriaxone tolerance, where epicutaneous and LAT tests were a useful diagnostic method.

This article has not received funding.

## Ethical disclosures

**Confidentiality of data.** The authors declare that they have followed the protocols of their work centre on the publication of patient data and that all the patients included in the study have received sufficient information and have given their informed consent in writing to participate in that study.

**Right to privacy and informed consent.** The authors declare that no patient data appear in this article.

**Protection of human subjects and animals in research.** Protection of human and animal subjects. The authors declare that no experiments were performed on humans or animals for this investigation.

## References

1. Walsh SA, Creamer D. Drug reaction with eosinophilia and systemic symptoms (DRESS): a clinical update and review of current thinking. *Clin Exp Dermatol.* 2011;36:6–11.

2. Criado PR, Criado RFJ, Avancini JM, Santi CG. Drug reaction with Eosinophilia and Systemic Symptoms (DRESS)/Drug-induced Hypersensitivity Syndrome (DIHS): a review of current concepts. *An Bras Dermatol.* 2012;87:435–49.
3. Kardaun SH, Sidoroff A, Valeyrie-allanore L, Halevy S, Davidovici BB, Mockenhaupt M, et al. Variability in the clinical pattern of cutaneous side-effects of drugs with systemic symptoms: does a DRESS syndrome really exist. *Br J Dermatol.* 2007;156:609–11.
4. Beeler A, Zaccaria L, Kawabata T, Gerher BO, Pichler WJ. CD 69 upregulation on T cell as an in vitro marker for delayed-type drug hypersensitivity. *Allergy.* 2008;63:181–8.
5. Barbaud A, Collet E, Milpied B, Assier H, Staumont D, Avenel-Audran M, et al. A multicenter study to determine the value and safety of drug patch test for de three main classes of severe cutaneous adverse drug reaction. *Br J Dermatol.* 2012. <http://dx.doi.org/10.1111/bjd.12125>.
6. Romano A, Torres MJ, Castells M, Sanz ML, Blanca M. Diagnosis and management of drug hypersensitivity reactions. *J Allergy Clin Immunol.* 2011;127 3 Suppl.:S67–73.
7. Fahim S, Jain V, Victor G, Pierscianowski T. Piperacillin-tazobactam-induced drug hypersensitivity syndrome. *Cutis.* 2006;77:353–7.
8. Akcam FZ, Aygun FO, Akkaya VB. DRESS like severe drug rash with eosinophilia, atypic lymphocytosis and fever secondary to ceftriaxone. *J Infect.* 2006;53:51–3.
9. Jurado-Palomo J, Cabañas R, Prior N, Bobolea ID, Fiandor-Román AM, López-Serrano MC, et al. Use of the lymphocyte transformation tests in the diagnosis of DRESS syndrome induced by ceftriaxone and piperacillin-tazobactam: two case reports. *J Investig Allergol Clin Immunol.* 2010;20:433–6.
10. Goto M, Shimizu F, Takeo N, Okamoto O, Katagiri K, Ikewaki J, et al. Drug-induced hypersensitivity syndrome due to carbapenem antibiotics. *J Dermatol.* 2010;37:374–7.

M. Prados-Castaño\*, M. Piñero-Saavedra,  
S. Leguísamo-Milla, M. Ortega-Camarero, A. Vega-Rioja

*Allergy Section, Hospital Universitario Virgen del Rocío,  
Avda. Manuel Siurot s/n, Seville 41013, Spain*

\*Corresponding author.

*E-mail addresses:* [pradosmanuel.cas@gmail.com](mailto:pradosmanuel.cas@gmail.com),  
[mpradosc@meditex.es](mailto:mpradosc@meditex.es) (M. Prados-Castaño).

<http://dx.doi.org/10.1016/j.aller.2013.12.004>