



SPECIAL ARTICLE

Diabetes mellitus impact on fetal liver circulation, and new diagnostic options

Impacto de la diabetes mellitus en la circulación hepática fetal y nuevas opciones diagnósticas

Torvid Kiserud^{a,b}✉

^a Research Group for Pregnancy, Fetal Development and Birth. Department of Clinical Science. University of Bergen. Norway

^b Department of Obstetrics and Gynecology. Haukeland University Hospital. Norway

INFORMACIÓN DEL ARTÍCULO

Historia del Artículo:

Recibido: 21 12 2022
Aceptado: 26 01 2023

Key words:

Fetus Development; Fetal Circulation; Umbilical Flow; Left Portal Vein; Ultrasonography; Doppler.

Palabras clave:

Desarrollo del Feto; Circulación Fetal; Flujo Umbilical; Vena Porta Izquierda; Ultrasonografía; Doppler.

ABSTRACT

While biometry and Doppler have proved useful in the management of fetal growth restriction, the same battery has been of less help in diabetic pregnancies. It is not surprising since the underlying pathophysiology is fundamentally different. Recent studies of the fetal liver, a key metabolic organ, have shown that its venous circulation reflects the impact of maternal hyperglycemia. Umbilical return from the placenta is disproportionately distributed to the fetal liver (more than in normally growing fetuses, and more than in non-diabetic macrosomia). However, what is set as a pattern at midtrimester is not followed up in the 3rd trimester when high fetal growth continues but no longer correspondingly supported by the umbilical flow to the liver ($\text{mL min}^{-1} \text{kg}^{-1}$ is low). Thus, the status at 3rd trimester is as follows: umbilical flow does not match fetal growth, but the fetal liver still takes a major proportion of the placental return leaving less for the ductus venosus (DV). A distended DV does not help; rather it indicates reduced residual compensatory mechanisms to face hypoxic challenges. The new insights suggest taking into consideration the fetal liver when assessing risks in diabetic pregnancies at 3rd trimester. Measuring umbilical venous flow and its distribution requires high level of skills and accurate techniques, but in the left portal branch (between the DV inlet and the junction with the portal main stem), the blood velocity is regularly accessible and it reflects the skewed umbilical flow to the liver, and its consequences, in a graded manner.

RESUMEN

Si bien la biometría y el Doppler han demostrado ser útiles en el manejo de la restricción del crecimiento fetal, dichos exámenes han sido de menor ayuda en los embarazos en pacientes diabéticas. Esto no sorprende dado que la fisiopatología subyacente es fundamentalmente diferente. Estudios recientes del hígado fetal, un órgano metabólico clave, han demostrado que su circulación venosa refleja el impacto de la hiperglucemia materna. El retorno umbilical desde la placenta se distribuye de manera desproporcionada al hígado fetal (más que en los fetos de crecimiento normal y más que en la macrosomía no diabética). Sin embargo, lo que se establece como un patrón en el segundo trimestre no persiste en el tercer trimestre cuando al continuar el alto crecimiento no es apoyado proporcionalmente por el flujo umbilical al hígado ($\text{mL min}^{-1} \text{kg}^{-1}$ es bajo). Por lo tanto, el estado en el tercer trimestre es el siguiente:

✉ Autor para correspondencia

Correo electrónico: torvid.kiserud@uib.no

<https://doi.org/10.1016/j.rmcl.2023.01.003>

e-ISSN: 2531-0186/ ISSN: 0716-8640/© 2023 Revista Médica Clínica Las Condes.

Este es un artículo Open Access bajo la licencia CC BY-NC-ND

(<http://creativecommons.org/licenses/by-nc-nd/4.0/>).



el flujo umbilical no coincide con el crecimiento fetal, pero el hígado fetal sigue tomando una proporción importante del retorno placentario, dejando menos para el ductus venoso (DV). Un DV distendido no ayuda; más bien indica mecanismos compensatorios residuales reducidos para enfrentar desafíos hipóxicos. Los nuevos conocimientos sugieren tener en cuenta el hígado fetal al evaluar los riesgos en los embarazos diabéticos en el tercer trimestre. Medir el flujo venoso umbilical y su distribución requiere de un alto nivel de habilidad y técnicas precisas, pero en la rama portal izquierda (entre la entrada del DV y la unión con la vena porta), la velocidad de la sangre es habitualmente accesible y refleja el flujo umbilical sesgado al hígado, y sus consecuencias, de manera medible.

GENERAL BACKGROUND

In 1922, FG Banting and CH Best revolutionized diabetes mellitus (DM) understanding and treatment when they extracted what they called insulin from the pancreas and could show the effect of reducing blood glucose in normal animals¹. The following 100 years of continued research, innovation, and clinical implementations have brought improved treatment and health to millions of patients, but the disease continues to rise globally^{2,3}.

In pregnancy, tight glycemic control has been a cornerstone of care that has reduced the incidence of congenital malformations and perinatal morbidity⁴⁻⁶. The latest improvement was achieved through a glucose monitoring system that led to reduced glucose excursions⁷. However, still today, DM in pregnancy has an increased perinatal mortality and morbidity compared with the background population^{4,5} and researchers strive to understand why and how they can better identify and manage those at risk of stillbirth and perinatal morbidity. In the following article we are prioritizing human research when available, with a pathophysiological and clinical perspective.

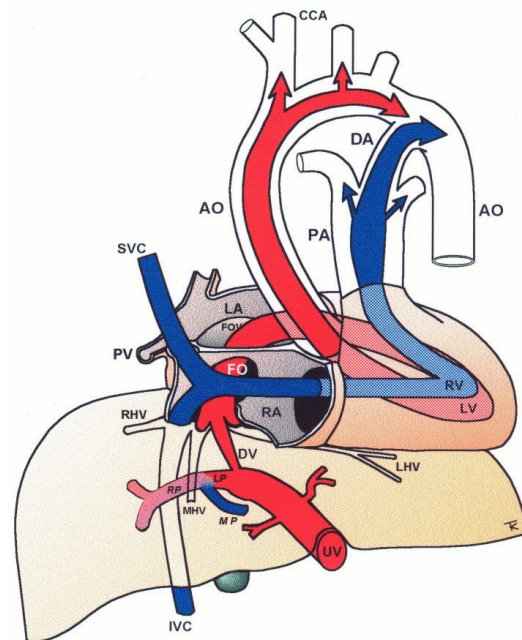
PHYSIOLOGICAL BACKGROUND

Maternal glucose is transmitted through the placenta to the fetus, and an oral glucose load increases fetal glucose and umbilical flow to the fetal liver, affecting fetal abdominal circumference, which reflects fetal liver size⁸. Fetal glucose stimulates insulin secretion and glucose uptake in the fetal liver where roughly 80% of the insulin is received⁹. Insulin also increases glucose uptake in peripheral tissues such as striate muscles and heart. High glucose levels also promote fetal fat accretion and development of macrosomia. Such a drive includes an increased oxidative activity and oxygen consumption, further conditioned by degrees of maternal adiposity and gestational weight gain which has an independent driving effect¹⁰.

The fetal liver has a key role in metabolic adaptation and growth. Under normal conditions it receives 70-80% of the umbilical venous return from the placenta¹¹⁻¹³, the rest being fed into the ductus venosus forming the nutritious central pathway *via sinistra* (Figure 1) ensuring cardiac and cerebral oxygenation, particularly under hypoxic challenges¹⁴⁻¹⁷. Fetal liver growth depends on the volume of umbilical blood perfusing its tissue inducing hepatocyte

proliferation^{18,19}. The liver also produces IGF-1 and IGF-2 directed at differential somatic growth¹⁹. Although degrees of maternal adiposity condition fetal fat accretion, the fetal liver per se is responsible for a basic fetal fat accumulation determined by the amount of umbilical liver perfusion. It ensures some fetal fat formation even in a slim mother²⁰. A certain degree of fetal hepatic auto-regulation seems to operate by increasing its share of umbilical blood when a mother's skinfold is small, or she eats an unbalanced diet²¹.

Figure 1. Central circulatory pathways of the fetus



Via sinistra (red) directs well-oxygenated umbilical blood from the umbilical vein (UV), through the ductus venosus (DV) across the proximal inferior vena cava (IVC) to pass through the foramen ovale (FO) above the foramen ovale valve (FOV) to reach the left atrium (LA) and the left ventricle (LV) to be pumped into the aorta (AO) feeding the coronary arteries, head and arms before reaching the descending AO. *Via dextra* directs low-oxygenated blood (blue) from the superior vena cava (SVC) and inferior vena cava (IVC) through the right atrium (RA) to the right ventricle (RV) where it is pumped into the pulmonary artery (PA) and ductus arteriosus (DA) to reach the descending AO. CCA, common carotid arteries; LHV, left hepatic vein; LP, left portal branch; MHV, medial hepatic vein; MP, main portal vein; PV, pulmonary vein; RHV, right hepatic vein; RP, right portal branch (modified with permission¹¹).

The fetal brain is the highest energy consumer and the heart is equally dependent on a continuous supply of oxygen and energy substrate. The *via sinistra* with the ductus venosus conveys fresh blood with the highest oxygen saturation (typically 85%) constituting, under all circumstances, the essential core of feeding for these prioritized organs¹⁴. All other blood supply represents blood that has recycled in the fetal body before returning for the second or third extraction of oxygen²². The *via sinistra*, however, competes directly with the perfusion of the liver.

When the placenta is compromised, the growth-restricted fetus spares the heart and brain by maintaining the ductus venosus blood flow at the expense of liver growth, general somatic growth, and fat accretion^{17,23,24}. These fetuses have an impaired umbilical circulation with less placental blood reaching the abdominal umbilical vein, but the ductus venosus shunting maintains its flow by enlargement. The bottom line is that the fetal liver receives less, and the distribution liver/ductus venosus shifts from, e.g., 75/25 (%) to 50/50, or worse depending on the severity of the placental dysfunction (Figure 2).

Women with DM may at times experience pregnancies with fetal growth-restriction as pregestational DM (PGDM), in particular, also carries a risk of disruptive pathophysiology. In such cases, the hyperglycemic condition is expected to modify and skew the known adaptive responses of fetal growth-restriction making the clinical interpretation of findings a challenge.

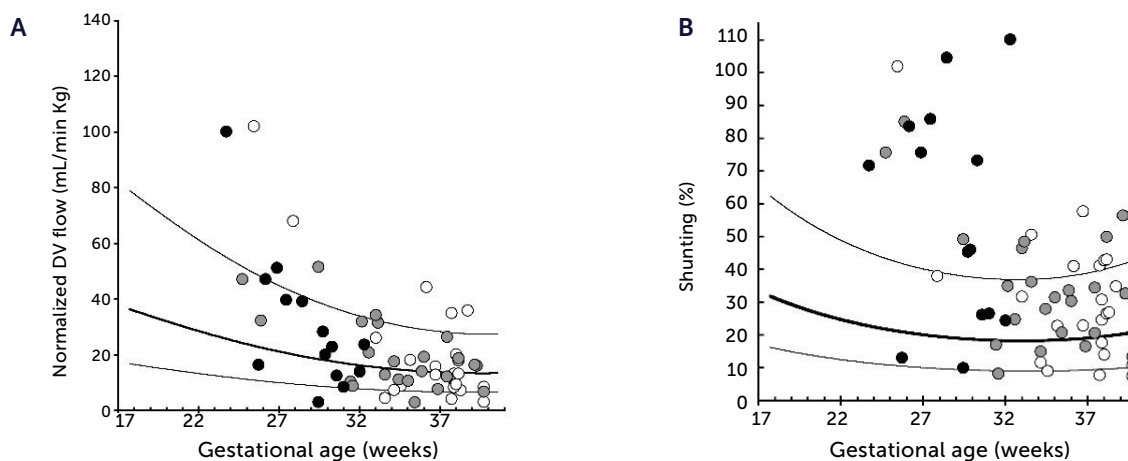
NORMAL MACROSOMIC FETAL GROWTH AND ITS UNDERLYING CIRCULATION

Before jumping at the question of how the underlying circulation in fetal macrosomia develops in diabetic pregnancies, we thought it prudent to understand how the circulation is organized in normal macrosomia, i.e., birthweight >80th centile in pregnancies without DM. Interestingly, the macrosomic fetus has the same circulatory pattern as the rest of the background population, but scaled up to fit their size^{25,26}. This means that the umbilical flow supported macrosomic growth throughout pregnancy and into the last days of pregnancy without *blunting* (Figures 3A and 4A), that the fetal liver perfusion was correspondingly scaled up (Figure 5), and that the ductus venosus blood flow was maintained proportionate to fetal size (Figures 3B and 4B). It is interesting at this point to comment the results of a national birth-registry from a high-income country showing that birthweights at 80-85 centiles are associated with the lowest perinatal mortality and morbidity²⁷. This presumably implies the availability of adequate obstetric services.

EFFECT OF PREGESTATIONAL DM ON UMBILICAL FLOW AND ITS DISTRIBUTION

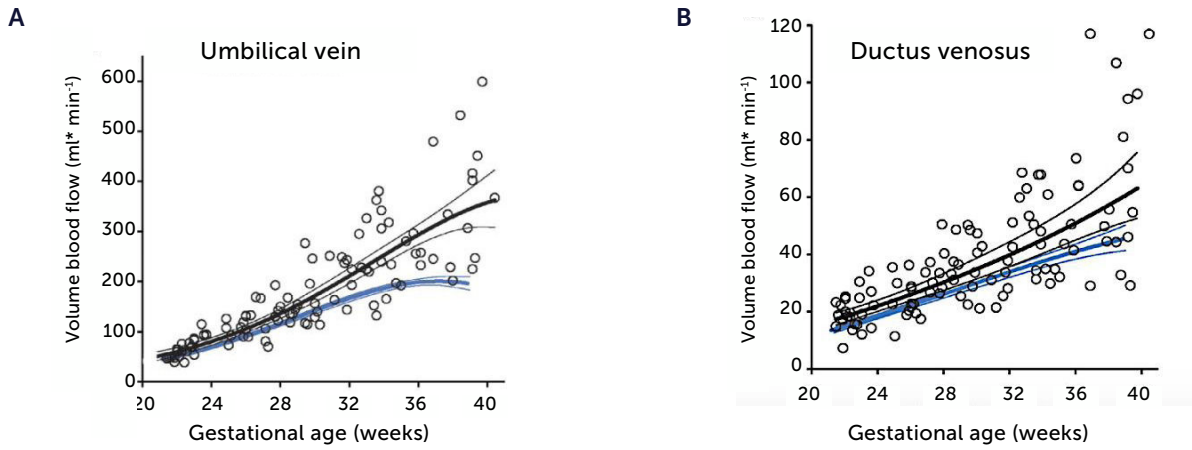
After discussing liver circulation in fetal macrosomia in non-diabetic mothers, we turn to DM and focus primarily on PGDM as it is a more sinister condition than gestational DM, which encompasses pregnancies with various degrees of hyperglycemia and where the cut-off with regards to normal pregnancies has been shifting with time and society.

Figure 2. Ductus venosus flow pr kg and degree of shunting in severe fetal growth restriction (FGR)



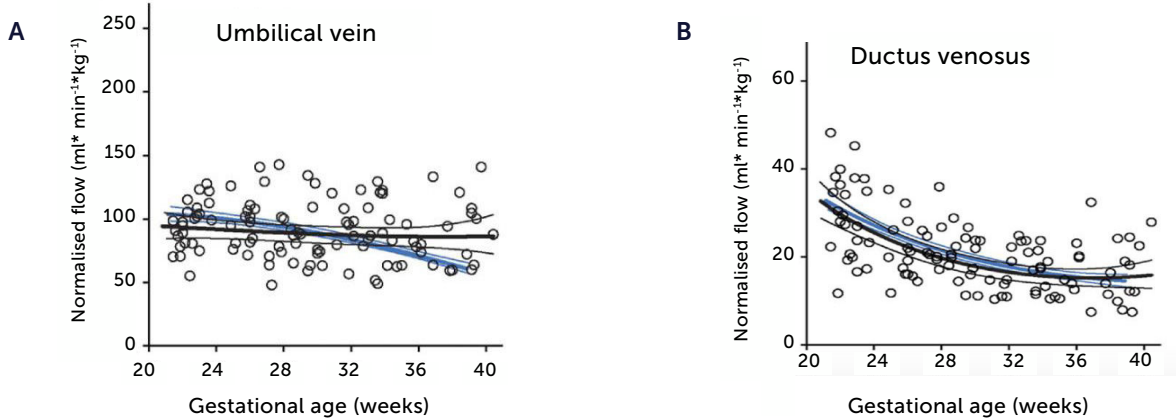
A) Ductus venosus (DV) blood flow normalized for estimated fetal weight in 60 growth-restricted fetuses (≤ 2.5 centile) was not different from background population (10th, 50th, and 90th centile) ($p=0.8$). B) However, since the umbilical flow was low in these fetuses, the degree of DV shunting was increased ($p<0.0001$) leaving correspondingly less for the liver perfusion. White circle, normal umbilical artery PI; grey circle, umbilical artery PI >97.5 centile; black circle, umbilical artery absent or reversed diastolic flow¹⁷.

Figure 3. Blood flow in the umbilical vein and ductus venosus of macrosomic in non-diabetic mothers



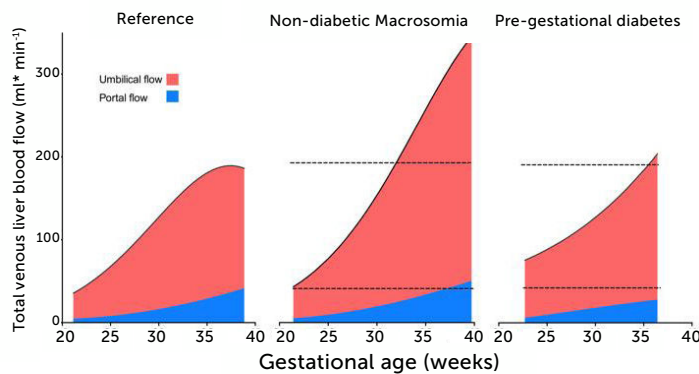
Blood flow in the umbilical vein (A) and ductus venosus (B) of macrosomic fetuses in non-diabetic mothers (black) is upscaled compared with background population (blue), and less blunted towards term. Lines represents mean and 95% CI of the mean²⁵.

Figure 4. Blood flow normalized for estimated fetal weight in the umbilical vein and ductus venosus of macrosomic in non-diabetic mothers



Blood flow normalized for estimated fetal weight in the umbilical vein (A) and ductus venosus (B) of macrosomic fetuses in non-diabetic mothers (black) confirms a proportionate blood flow support of growth until birth, compared with low-risk background population (blue). Lines represent mean and 95% CI of the mean²⁵.

Figure 5. Total venous blood flow to the fetal liver in low-risk pregnancies, fetal macrosomia in non-diabetic pregnancies, and fetuses in mothers with pre-pregnant diabetes mellitus



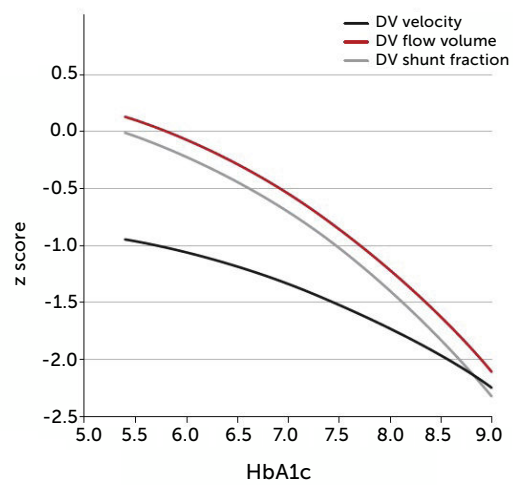
Total venous blood flow to the fetal liver in low-risk pregnancies (left), fetal macrosomia in non-diabetic pregnancies (center), and fetuses in mothers with pre-pregnant diabetes mellitus (right) where 39% had macrosomia. Red color signifies umbilical blood, and blue color splanchnic blood from the portal stem. Data collation from four studies^{25,28,33,43}.

In PGDM, umbilical flow at mid gestation is high with a large volume directed to the fetal liver (Figure 5)²⁸. Together with high fetal glucose concentration, it sets the standard and promises high growth rates. In fact, 39% of these fetuses are born with macrosomia (>80 centile). The umbilical flow, however, does not grow proportionately, resulting in a significantly lower umbilical flow when it is normalized for weight. In other words, the blood volume distributed to the fetal liver does not match fetal growth and is inferior to the circulatory support non-diabetic macrosomic fetuses would have (Figure 5). Apparently, the distributional pattern was set at mid gestation, but the following development failed to follow up as less placental blood reached the intraabdominal umbilical vein possibly due to a diabetic dysfunctional placenta. On the other hand, the vascular regulation in the liver venules is several times more sensitive than in the ductus venosus²⁹ and ensures a continued high fraction of umbilical blood to the liver, at the expense of the ductus venosus. The ductus venosus on its side is significantly distended,

has a low blood velocity and a blunted flow development during 3rd trimester (Figure 6)³⁰. It is likely that this state of distribution constitutes a restrictive capacity to respond to hypoxic challenge, and therefore a correspondingly increased risk for serious events.

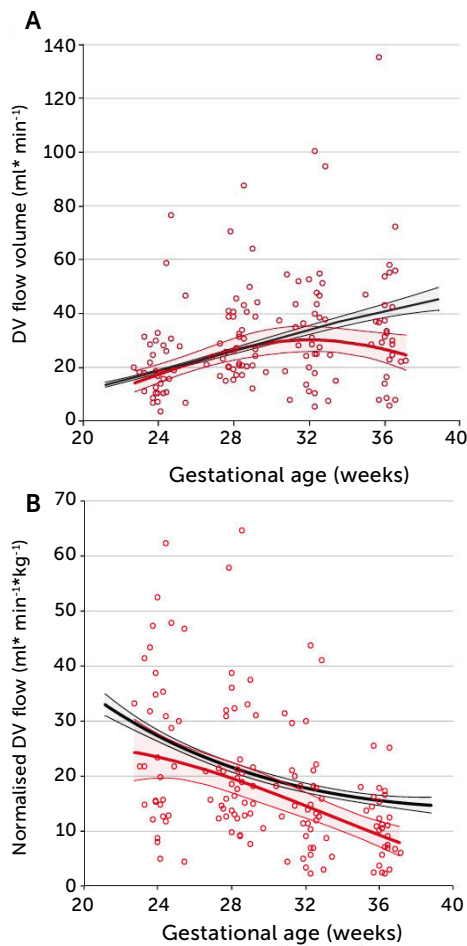
The degree of these circulatory changes (ductus venosus low velocity, low volume flow and low fraction shunted) are directly linked to degree of glycemic control (HbA1c) (Figure 7). At birth, arterial lac-

Figure 7. The degree of ductus venosus shunting impairment in pregnancies with pregestational diabetes mellitus is related to degree of glycemic control (HbA1c)



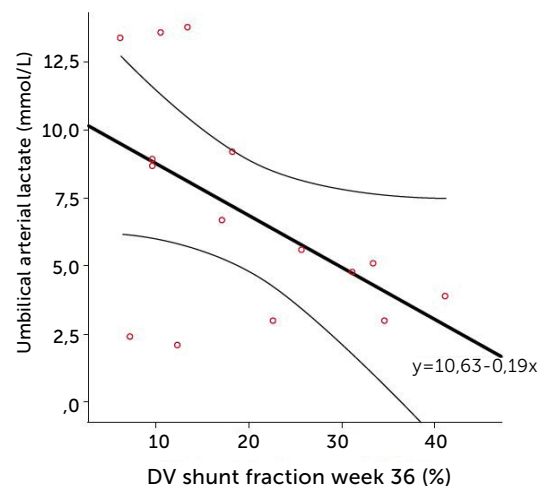
i.e., both shunted fraction of umbilical blood (grey), blood volume shunted (red), and time-averaged maximum blood velocity in the ductus venosus (green), which represents the driving umbilical pressure for perfusing both ductus and liver, are affected in a graded manner³⁰.

Figure 6.



A) Longitudinal observations of ductus venosus blood flow showed a blunted development during 3rd trimester in pregestational diabetes mellitus (red) compared with low-risk background population (black). B) The corresponding ductus venosus flow normalized for estimated fetal weight is less than in the low-risk control group. Lines signify mean and 95% CI of the mean³⁰.

Figure 8.



The relation of cord arterial lactate at birth to degree of ductus venosus shunting (%) at 36 weeks of gestation in pregnancies with pregestational diabetes mellitus. Regression line with 95% CI is shown³⁰.

tate in the cord is linearly related to the degree of shunting through the ductus venosus at 36 weeks of gestation; i.e., low shunting is associated with high lactate levels supporting the notion that these fetuses are at increased risk (Figure 8).

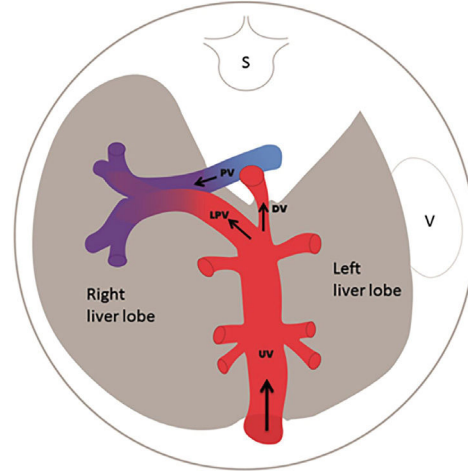
BLOOD FLOW VELOCITY IN THE LEFT PORTAL BRANCH

The left portal branch deserves a particular focus as it serves as a watershed area between the umbilical and splanchnic venous supply to the fetal liver (Figure 9)³¹⁻³³. Thus, it has the potential of gauging an imbalance associated with fetal growth-restriction²³, DM²⁸, twin-twin transfusion syndrome, fetal liver diseases or anomalies of the abdominal venous system^{34,35}.

The intra-abdominal umbilical vein, half embedded in the caudal surface of the fetal liver, feeds the portal branches of the left liver lobe as it heads towards the ductus venosus inlet. Here the umbilical venous flow turns right following the left portal branch to join with the main portal stem and the right portal branch (Figure 10). There has been some discussion of the nomenclature of this venous section, i.e., whether to name according to prenatal developmental origin, postnatal anatomic naming traditions or current clinical needs of simplicity³⁶. The section between the ductus venosus inlet and the junction with the portal stem is, for simplicity reasons, called the 'left portal vein' (Figure 9), also known as the transverse sinus, or portal sinus, particularly when including the somewhat wider portion in front of the ductus venosus inlet. It is readily accessible in a modified transverse scan of the fetal abdomen tilted slightly caudally (Figure 11). The Doppler recording achieves a complete alignment when interrogating at 30-60° to the sagittal plane. The sample volume should be reduced to 2-3mm to avoid interference from the umbilical vein, ductus venosus, portal stem or right portal branch.

In **normal pregnancies** the time-averaged maximum velocity ranges between 7-21 cm/s corresponding to the 2.5-97.5 centile prediction span depending on gestational age (Table 1)³³. During the last days (weeks) before birth the velocity may reduce to near zero or turn negative (i.e., reversed) particularly under the influence of fetal breathing movements (Figure 12)³³. Thus, the effect of breathing is

Figure 9.



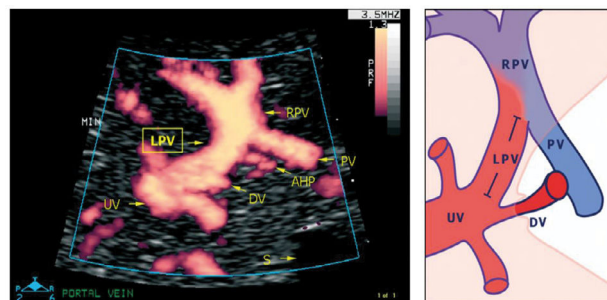
The left portal vein (PV) directs umbilical flow beyond the ductus venosus (DV) towards the right side to the junction with the portal stem, or the main portal vein (PV), where umbilical blood blends in with low-oxygenated splanchnic blood and enters the right portal branch and liver lobe. LPV constitutes a watershed area where blood may even reverse to feed splanchnic blood into the umbilical vein and ductus venosus when perfusion pressure in the umbilical vein is low. After birth when the umbilical vein obliterates, the velocity is permanently reversed, and the portal stem circulates both right and left liver lobes. S, spine; UV, intra-abdominal umbilical vein; V, stomach³³.

to push some of the well-oxygenated umbilical blood to enter the ductus venosus (and via sinistra) rather than the right liver lobe at a time when pCO₂ is elevated and pO₂ is reduced. Additionally, during the last days of pregnancy, it looks like the portal circulation initiates a transition to postnatal pattern as splanchnic blood increasingly flows through the portal stem to feed the right liver lobe¹³.

In **fetal growth-restriction**, however, the velocities are commonly reduced, and may even be reversed in the early weeks of the 3rd trimester when the condition is severe (Figure 13)^{23,37}. The degree of low blood velocity in the left hepatic vein of growth-restricted fetuses tends to be linked to low arterial pO₂ at birth (Figure 14)²³.

In **fetuses with macrosomia in non-diabetic mothers**, blood flow in the left portal vein is increased when compared with background population, but is proportionate to fetal growth²⁵.

Figure 10. Details of the left portal vein connections visualized using power Doppler sonography



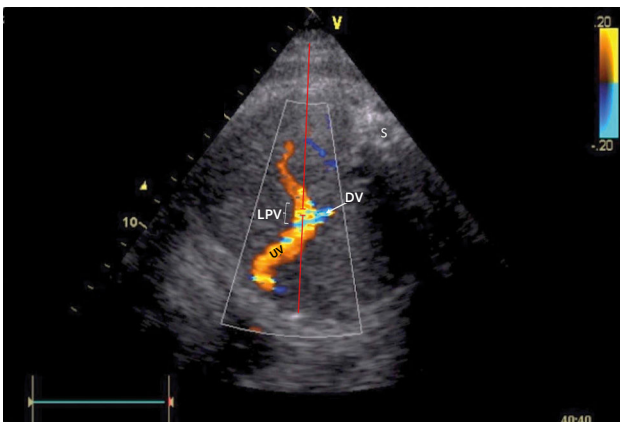
A magnified sketch (right panel) clarifies the details. The site for Doppler recording of the LPV would be the section between the istmus of the ductus venosus (DV) and the junction with the portal vein (PV) and the right portal vein (RPV). The insonation should be aligned and the sample volume reduced to 2-3mm to minimize interference. AHP, arteria hepatica; S, stomach; UV, umbilical vein³³.

Table 1. Reference ranges for time-averaged maximum blood velocity in the fetal left portal vein

Gestation [weeks]	Centile								
	2.5	5	10	25	50	75	90	95	97.5
21	7.3	7.8	8.3	9.4	10.6	12.0	13.4	14.3	15.2
22	7.7	8.2	8.8	9.9	11.2	12.7	14.1	15.1	15.9
23	8.1	8.6	9.2	10.3	11.7	13.2	14.8	15.7	16.6
24	8.5	9.0	9.6	10.8	12.2	13.8	15.4	16.4	17.3
25	8.8	9.3	10.0	11.2	12.6	14.3	15.9	17.0	17.9
26	9.1	9.6	10.3	11.5	13.0	14.7	16.4	17.5	18.5
27	9.3	9.9	10.6	11.8	13.4	15.1	16.9	18.0	19.0
28	9.5	10.1	10.8	12.1	13.7	15.5	17.3	18.4	19.5
29	9.6	10.2	10.9	12.3	13.9	15.7	17.6	18.7	19.8
30	9.7	10.3	11.1	12.4	14.1	15.9	17.8	19.0	20.1
31	9.7	10.3	11.1	12.5	14.2	16.1	18.0	19.2	20.3
32	9.7	10.3	11.1	12.5	14.2	16.1	18.1	19.3	20.5
33	9.6	10.3	11.0	12.4	14.2	16.1	18.1	19.3	20.5
34	9.5	10.2	10.9	12.3	14.1	16.0	18.0	19.3	20.5
35	9.4	10.0	10.8	12.2	13.9	15.9	17.9	19.2	20.3
36	9.1	9.8	10.5	11.9	13.7	15.7	17.7	19.0	20.1
37	8.9	9.5	10.3	11.7	13.4	15.4	17.4	18.7	19.9
38	8.6	9.2	9.9	11.3	13.1	15.0	17.0	18.3	19.5
39	8.2	8.8	9.6	11.0	12.7	14.6	16.6	17.9	19.1

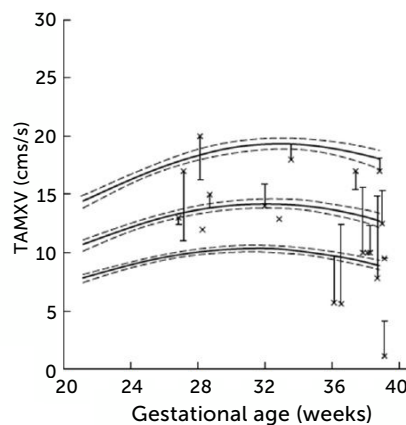
Reference ranges for time-averaged maximum blood velocity (cm s^{-1}) in the fetal left portal vein; based on 554 longitudinal observations in 160 low-risk pregnancies³³.

Figure 11. Doppler insonation of the left portal vein (LPV)



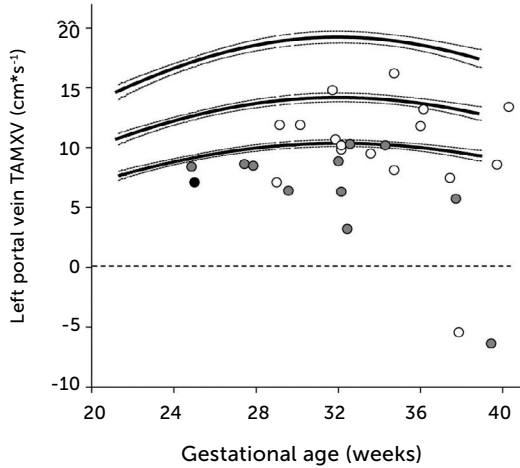
Doppler insonation (red line) of the left portal vein (LPV) in an almost transverse scan at the level of the inlet of the ductus venosus (DV) aligning the Doppler beam with the LPV from the posterior right side of the fetus. Color Doppler optimized for velocities of 10-25 cm/s confirms identification and connection to the umbilical vein (UV). The opposite direction is also favorable, should the fetus rotate 180°. Spine (S).

Figure 12. Left portal vein time-averaged maximum blood velocity (TAMXV)



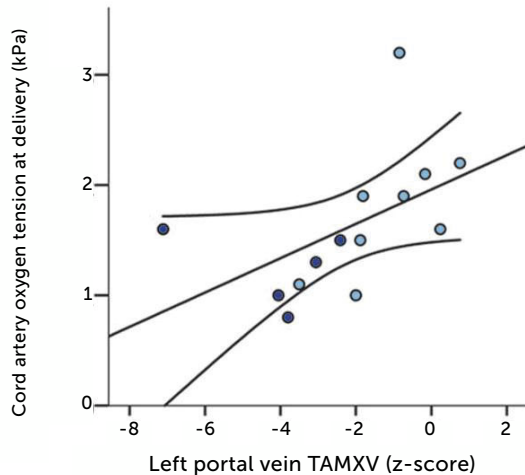
Left portal vein time-averaged maximum blood velocity (TAMXV) development during the second half of pregnancy with 5th, 50th, and 95th centile with their 95% CIs. Individual observations of effect of fetal breathing movement are plotted for quiescence (-) and connected with line to breathing movements (x)³³.

Figure 13. Time-averaged maximum blood velocity



Time-averaged maximum blood velocity in growth-restricted. The effect is more pronounced in those with elevated PI (grey) or absent/reversed end-diastolic velocity (black) in the umbilical artery²³.

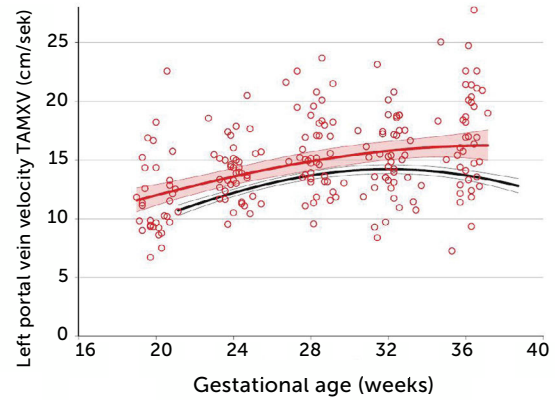
Figure 14.



Low blood velocity in the left portal vein of growth-restricted fetuses tends to be associated with low arterial pO_2 at birth. Regression line with 95% CI. Light blue, normal umbilical artery PI; dark blue, umbilical artery PI >97.5 centile²³.

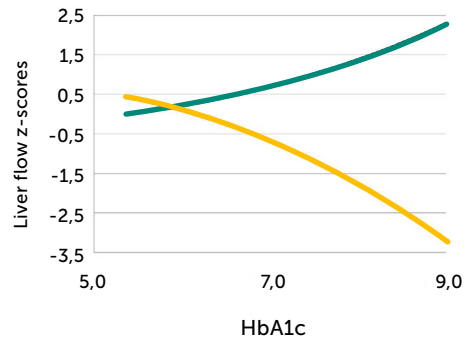
In pregnancies with PGDM, however, the umbilical flow and the amount directed to the fetal liver does not grow to match fetal growth although the fetal liver had been set to maximize umbilical venous intake at mid-gestation^{28,30}. This is reflected in the generally high blood velocity in the left portal vein (Figure 15). It is also reflected in the increasing deficit in ductus venosus flow as the 3rd trimester develops³⁰. This pattern is also related to the degree of maternal hyperglycemia assessed by HbA1c (Figure 16), and to

Figure 15. Time-averaged maximum blood velocity in the fetal left portal vein in pregestational diabetes mellitus



Time-averaged maximum blood velocity (TAMXV) in the fetal left portal vein is significantly increased in pregnancies with pregestational diabetes mellitus (red) compared with a low-risk reference group (black). Lines, mean with 95%CI for the mean²⁸.

Figure 16. Fetal left portal vein blood velocity relation to glycemic control (HA1c)



Fetal left portal vein blood velocity z-score (green) increases with HbA1c while main portal vein fraction (z-score) to the liver reduces (yellow) with HbA1c in pregnancies with pregestational diabetes mellitus²⁸.

the arterial concentration of lactate at birth³⁰. This accumulated evidence of graded relation to maternal HbA1c, neonatal arterial lactate at birth and degree of ductus venosus shunting, makes the increased blood velocity in the left portal vein a candidate for fetal diagnosis and monitoring in DM pregnancies.

• Considerations and limitations

It is obvious that for the future we will also use umbilical and middle cerebral artery pulsatility index (PI), and the ductus venosus PI to assess DM pregnancies, as they sometimes are complicated with placental dysfunction and growth impairment. The set of Doppler examinations that we have discussed in this review, should be interesting to add as they go after the pattern of metabolic effects that DM exerts on the fetal circulation. However, measurement of blood volume flow in the umbilical vein, ductus venosus, left portal vein and main portal stem requires painstaking techniques for Doppler

interrogation and 2D-imaging, as well as consistency in repeating diameter measurement, particularly in the ductus venosus^{38,39}. So far, these techniques have afforded valuable insights, but are less suitable for individual patient assessment in busy clinical settings staffed with sonologists of varying experience working with equipment of varying quality. In the literature, it is sometime possible to observe how results vary between research groups although the various groups produce knowledgeable results due to their internal consistency^{24,40-42}. This is particularly true for the measurement of velocity and diameter of the ductus venosus. Thus, it will take time before these volume flow measurement techniques gain validation in clinical assessments. The umbilical vein flow assessment will probably become the most useful for the individual patient. It is commonly visualized in favorable positions both for Doppler measurement and for the needed repeat diameter measurement. Secondly, this vein has the largest bore in the fetus, thus being more robust against random error compared with the slim ductus venosus³⁹.

Measuring blood velocity in the left portal vein, however, to gauge liver flow without measuring diameters could also be a candidate for clinical use. It is accessible in a transverse scan of the fetal abdomen and not very time-consuming (Figure 11). And, it is linked to status of glycemic control and fetal outcome.

Physicians should use all such insights as far as the present evidence takes her or him, as good doctors always have done.

However, the present evidence has limitations. The findings here stem from studies in PGDM where the physiopathology is expected

to be more pronounced than in gestational DM and cannot easily be generalized. Secondly, prospective studies examining the predictivity of such measurements need to be carried out in order to refine the use and interpretation of the left portal vein Doppler measurement or any other of these measurement (e.g., umbilical flow).

CONCLUSIONS

PGDM in pregnancy does impact the fetal distributional circulation of the umbilical vein causing an augmented share to the fetal liver, but still not sufficient to match fetal growth in the 3rd trimester. Correspondingly, the ductus venosus shunting is blunted in the same period reducing the capacity to buffer off hypoxic events. Blood velocity in the left portal vein is commonly accessible for Doppler recording and reflects the augmented priority of liver perfusion. It is tempting to include this information in clinical management particularly since it has a graded relation to maternal glycaemic control and to arterial lactate in the cord at birth. A refined use of this insight can be expected after prospective studies have been carried out to test its predictivity.

Acknowledgement

I am indebted to Svein Magne Skulstad, Guttorm Haugen, Jörg Kessler, Cathrine Ebbing, and Agnethe Lund, who have engaged deeply in our studies, and, in the present context, been instrumental in perpetuating consistency in techniques and methods through the years.

Conflict of Interest

The author reports no conflict of interest.

REFERENCES

- Banting FG, Best CH, Collip JB, Campbell WR, Fletcher AA. Pancreatic Extracts in the Treatment of Diabetes Mellitus. *Can Med Assoc J.* 1922;12(3):141-146.
- Persson M, Norman M, Hanson U. Obstetric and perinatal outcomes in type 1 diabetic pregnancies: A large, population-based study. *Diabetes Care.* 2009;32(11):2005-2009. doi: 10.2337/dc09-0656
- Liu J, Ren ZH, Qiang H, Wu J, Shen M, Zhang L, et al. Trends in the incidence of diabetes mellitus: results from the Global Burden of Disease Study 2017 and implications for diabetes mellitus prevention. *BMC Public Health.* 2020;20(1):1415. doi: 10.1186/s12889-020-09502-x.
- Eidem I, Vangen S, Hanssen KF, Vollset SE, Henriksen T, Joner G, et al. Perinatal and infant mortality in term and preterm births among women with type 1 diabetes. *Diabetologia.* 2011;54(11):2771-2778. doi: 10.1007/s00125-011-2281-7
- Eidem I, Stene LC, Henriksen T, Hanssen KF, Vangen S, Vollset SE, et al. Congenital anomalies in newborns of women with type 1 diabetes: nationwide population-based study in Norway, 1999-2004. *Acta Obstet Gynecol Scand.* 2010;89(11):1403-1411. doi: 10.3109/00016349.2010.518594
- Hildén K, Magnuson A, Hanson U, Simmons D, Fadl H. Trends in pregnancy outcomes for women with gestational diabetes mellitus in Sweden 1998-2012: a nationwide cohort study. *Diabet Med.* 2020;37(12):2050-2057. doi: 10.1111/dme.14266
- Feig DS, Donovan LE, Corcoy R, Murphy KE, Amiel SA, Hunt KF, et al.; CONCEPT Collaborative Group. Continuous glucose monitoring in pregnant women with type 1 diabetes (CONCEPT): a multicentre international randomised controlled trial. *Lancet.* 2017;390(10110):2347-2359. doi: 10.1016/S0140-6736(17)32400-5. Epub 2017 Sep 15. Erratum in: *Lancet.* 2017;390(10110):2346
- Haugen G, Bollerslev J, Henriksen T. Human fetoplacental and fetal liver blood flow after maternal glucose loading: a cross-sectional observational study. *Acta Obstet Gynecol Scand.* 2014;93(8):778-785. doi: 10.1111/aogs.12419
- Tokarz VL, MacDonald PE, Klip A. The cell biology of systemic insulin function. *J Cell Biol.* 2018;217(7):2273-2289. doi: 10.1083/jcb.201802095
- Desoye G, Carter AM. Fetoplacental oxygen homeostasis in pregnancies with maternal diabetes mellitus and obesity. *Nat Rev Endocrinol.* 2022;18(10):593-607. doi: 10.1038/s41574-022-00717-z

11. Kiserud T, Rasmussen S, Skulstad S. Blood flow and the degree of shunting through the ductus venosus in the human fetus. *Am J Obstet Gynecol.* 2000;182(1 Pt 1):147-153. doi: 10.1016/S0002-9378(00)70504-7
12. Haugen G, Kiserud T, Godfrey K, Crozier S, Hanson M. Portal and umbilical venous blood supply to the liver in the human fetus near term. *Ultrasound Obstet Gynecol.* 2004;24(6):599-605. doi: 10.1002/uog.1744
13. Kessler J, Rasmussen S, Godfrey K, Hanson M, Kiserud T. Longitudinal study of umbilical and portal venous blood flow to the fetal liver: low pregnancy weight gain is associated with preferential supply to the fetal left liver lobe. *Pediatr Res.* 2008;63(3):315-320. doi: 10.1203/pdr.Ob013e318163a1de
14. Behrman RE, Lees MH, Peterson EN, De Lannoy CW, Seeds AE. Distribution of the circulation in the normal and asphyxiated fetal primate. *Am J Obstet Gynecol.* 1970;108(6):956-969. doi: 10.1016/0002-9378(70)90341-8
15. Rudolph AM. Hepatic and ductus venosus blood flows during fetal life. *Hepatology.* 1983;3(2):254-258. doi: 10.1002/hep.1840030220
16. Kiserud T, Eik-Nes SH, Blaas HG, Hellevik LR. Ultrasonographic velocimetry of the fetal ductus venosus. *Lancet.* 1991;338(8780):1412-1414. doi: 10.1016/0140-6736(91)92720-m
17. Kiserud T, Kessler J, Ebbing C, Rasmussen S. Ductus venosus shunting in growth-restricted fetuses and the effect of umbilical circulatory compromise. *Ultrasound Obstet Gynecol.* 2006;28(2):143-149. doi: 10.1002/uog.2784
18. Tchirikov M, Kertschanska S, Schröder HJ. Obstruction of ductus venosus stimulates cell proliferation in organs of fetal sheep. *Placenta.* 2001;22(1):24-31. doi: 10.1053/plac.2000.0585
19. Tchirikov M, Kertschanska S, Stürenberg HJ, Schröder HJ. Liver blood perfusion as a possible instrument for fetal growth regulation. *Placenta.* 2002;23 Suppl A:S153-S158. doi: 10.1053/plac.2002.0810
20. Godfrey KM, Haugen G, Kiserud T, Inskip HM, Cooper C, Harvey NC, et al.; Southampton Women's Survey Study Group; Hanson MA. Fetal liver blood flow distribution: role in human developmental strategy to prioritize fat deposition versus brain development. *PLoS One.* 2012;7(8):e41759. doi: 10.1371/journal.pone.0041759
21. Haugen G, Hanson M, Kiserud T, Crozier S, Inskip H, Godfrey KM. Fetal liver-sparing cardiovascular adaptations linked to mother's slimness and diet. *Circ Res.* 2005;96(1):12-14. doi: 10.1161/01.RES.0000152391.45273.A2
22. Kiserud T, Ebbing C, Kessler J, Rasmussen S. Fetal cardiac output, distribution to the placenta and impact of placental compromise. *Ultrasound Obstet Gynecol.* 2006;28(2):126-136. doi: 10.1002/uog.2832
23. Kessler J, Rasmussen S, Godfrey K, Hanson M, Kiserud T. Fetal growth restriction is associated with prioritization of umbilical blood flow to the left hepatic lobe at the expense of the right lobe. *Pediatr Res.* 2009;66(1):113-117. doi: 10.1203/PDR.Ob013e3181a29077
24. Bellotti M, Pennati G, De Gasperi C, Bozzo M, Battaglia FC, Ferrazzi E. Simultaneous measurements of umbilical venous, fetal hepatic, and ductus venosus blood flow in growth-restricted human fetuses. *Am J Obstet Gynecol.* 2004;190(5):1347-1358. doi: 10.1016/j.ajog.2003.11.018.
25. Kessler J, Rasmussen S, Godfrey K, Hanson M, Kiserud T. Venous liver blood flow and regulation of human fetal growth: evidence from macrosomic fetuses. *Am J Obstet Gynecol.* 2011;204(5):429.e1-7. doi: 10.1016/j.ajog.2010.12.038
26. Ebbing C, Rasmussen S, Kiserud T. Fetal hemodynamic development in macrosomic growth. *Ultrasound Obstet Gynecol.* 2011;38(3):303-308. doi: 10.1002/uog.9046
27. Vasak B, Koenen SV, Koster MP, Hukkelhoven CW, Franx A, Hanson MA, et al. Human fetal growth is constrained below optimal for perinatal survival. *Ultrasound Obstet Gynecol.* 2015;45(2):162-167. doi: 10.1002/uog.14644
28. Lund A, Ebbing C, Rasmussen S, Kiserud T, Hanson M, Kessler J. Altered development of fetal liver perfusion in pregnancies with pregestational diabetes. *PLoS One.* 2019;14(3):e0211788. doi: 10.1371/journal.pone.0211788
29. Tchirikov M, Kertschanska S, Schröder HJ. Differential effects of catecholamines on vascular rings from ductus venosus and intrahepatic veins of fetal sheep. *J Physiol.* 2003;548(Pt 2):519-526. doi: 10.1113/jphysiol.2002.034470
30. Lund A, Ebbing C, Rasmussen S, Kiserud T, Kessler J. Maternal diabetes alters the development of ductus venosus shunting in the fetus. *Acta Obstet Gynecol Scand.* 2018;97(8):1032-1040. doi: 10.1111/aogs.13363
31. Kiserud T, Kilavuz O, Hellevik LR. Venous pulsation in the fetal left portal branch: the effect of pulse and flow direction. *Ultrasound Obstet Gynecol.* 2003;21(4):359-364. doi: 10.1002/uog.78.
32. Kilavuz O, Vetter K, Kiserud T, Vetter P. The left portal vein is the watershed of the fetal venous system. *J Perinat Med.* 2003;31(2):184-187. doi: 10.1515/JPM.2003.025
33. Kessler J, Rasmussen S, Kiserud T. The left portal vein as an indicator of watershed in the fetal circulation: development during the second half of pregnancy and a suggested method of evaluation. *Ultrasound Obstet Gynecol.* 2007;30(5):757-764. doi: 10.1002/uog.5146
34. Jerabek-Klestil S, Brantner C, Nehoda R, D'Costa E, Campe S, Scheier M. Prenatal sonographic diagnosis of intrahepatic portosystemic shunts. *J Ultrasound Med.* 2014;33(3):543-546. doi: 10.7863/ultra.33.3.543
35. Yagel S, Kivilevitch Z, Cohen SM, Valsky DV, Messing B, Shen O, et al. The fetal venous system, Part II: ultrasound evaluation of the fetus with congenital venous system malformation or developing circulatory compromise. *Ultrasound Obstet Gynecol.* 2010;36(1):93-111. doi: 10.1002/uog.7622
36. Kiserud T. Naming veins: by morphology, physiology or sociology. *Ultrasound Obstet Gynecol.* 2001;18(6):562-563. doi: 10.1046/j.0960-7692.2001.00601.x
37. Ebbing C, Rasmussen S, Godfrey KM, Hanson MA, Kiserud T. Redistribution pattern of fetal liver circulation in intrauterine growth restriction. *Acta Obstet Gynecol Scand.* 2009;88(10):1118-1123. doi: 10.1080/00016340903214924
38. Kiserud T, Saito T, Ozaki T, Rasmussen S, Hanson MA. Validation of diameter measurements by ultrasound: intraobserver and interobserver variations assessed in vitro and in fetal sheep. *Ultrasound Obstet Gynecol.* 1999;13(1):52-57. doi: 10.1046/j.1469-0705.1999.13010052.x
39. Kiserud T, Rasmussen S. How repeat measurements affect the mean diameter of the umbilical vein and the ductus venosus. *Ultrasound Obstet Gynecol.* 1998;11(6):419-425. doi: 10.1046/j.1469-0705.1998.11060419.x
40. Tchirikov M, Rybakowski C, Hüneke B, Schröder HJ. Blood flow through the ductus venosus in singleton and multifetal pregnancies and in fetuses with intrauterine growth retardation. *Am J Obstet Gynecol.* 1998;178(5):943-949. doi: 10.1016/S0002-9378(98)70528-9
41. Ikenoue S, Waffarn F, Ohashi M, Sumiyoshi K, Ikenoue C, Buss C, et al. Prospective association of fetal liver blood flow at 30 weeks gestation with newborn adiposity. *Am J Obstet Gynecol.* 2017;217(2):204.e1-204.e8. doi: 10.1016/j.ajog.2017.04.022
42. Bellotti M, Pennati G, De Gasperi C, Battaglia FC, Ferrazzi E. Role of ductus venosus in distribution of umbilical blood flow in human fetuses during second half of pregnancy. *Am J Physiol Heart Circ Physiol.* 2000;279(3):H1256-H1263. doi: 10.1152/ajpheart.2000.279.3.H1256
43. Kessler J, Rasmussen S, Kiserud T. The fetal portal vein: normal blood flow development during the second half of human pregnancy. *Ultrasound Obstet Gynecol.* 2007;30(1):52-60. doi: 10.1002/uog.4054