

recidivas son infrecuentes, y cuando se producen se debe, en la mayoría de los casos, a una enucleación o escisión incompletas de la lesión¹.

En nuestro caso un riguroso curetaje permitió la correcta osificación de la zona tal y como hemos podido ir comprobando con el seguimiento clínico y radiológico de la paciente.

Conclusiones

El oral pulse granuloma es una lesión poco frecuente que se asemeja clínica y radiológicamente a otras lesiones de los maxilares como pueden ser el ameloblastoma, el mixoma o el fibromixoma.

Para pensar en esta afección es muy importante tener en cuenta antecedentes de cirugía oral, procedimientos odontológicos o traumatismos locales previos en pacientes con pobre higiene bucodental.

Ante la inespecificidad de su clínica y radiología, es de gran importancia un estudio histopatológico exhaustivo de la lesión antes de plantearse cualquier tipo de intervención local más agresiva.

Responsabilidades éticas

Protección de personas y animales. Los autores declaran que para esta investigación no se han realizado experimentos en seres humanos ni en animales.

Confidencialidad de los datos. Los autores declaran que en este artículo no aparecen datos de pacientes.

Derecho a la privacidad y consentimiento informado. Los autores declaran que en este artículo no aparecen datos de pacientes.

Agradecimientos

Los autores agradecen al Servicio de Anatomía Patológica del Hospital Universitario 12 de Octubre y al resto de los

integrantes del servicio de cirugía oral y maxilofacial, quienes posibilitaron la realización de este documento.

BIBLIOGRAFÍA

- Lewars PH. Chronic periostitis in the mandible underneath artificial dentures. *Br J Oral Surg.* 1971;8:264-9.
- Philipsen HP, Reichart PA. Pulse or hyaline ring granuloma. Review of the literature on etiopathogenesis of oral and extraoral lesions. *Clin Oral Investig.* 2010;14:121-8.
- Keskin A, Duran S, Alkan A, Gunhan O. Hyaline ring granuloma in inflammatory odontogenic cysts: Report of two cases. *J Oral Maxillofacial Surg.* 2000;58:115-8.
- Chen SY, Fantasia JE, Miller AS. Hyaline bodes in the connective tissue wall of odontogenic cysts. *J Oral Oathol.* 1981;10:147-57.
- McMillan MD, Kardos TB, Edwards JL, Thornburn DN, Adams DB, Palmer DK. Giant cell hyaline angiopathy or pulse granuloma. *Oral Sur Oral Med Oral Pathol.* 1981;52:178-86.
- Chou L, Ficarra G, Hansen LS. Hyaline ring granuloma: A distinct oral entity. *Oral Surg Oral Med Oral Pathol.* 1990;70:318-24.
- Gueiros LA, Santos Silva AR, Romañach MJ, Leon JE, Lopes MA, Jorge J. Distinctive aspects of oral hyaline ring granulomas. *Oral Surg Oral Med Oral Pathol.* 2008;106:35-9.
- Dunlap CI, Barker BF. Giant cell hyaline angiopathy. *Oral Surg Oral Med Oral Pathol.* 1977;44:587-91.
- Talacko AA, Radden BG. The pathogenesis of oral pulse granuloma: An animal model. *J Oral Pathol.* 1988;17:99-105.

Víctor Zafra-Vallejo*, Marta Redondo-Alamillos, Ignacio Zubillaga-Rodríguez y Gregorio Sánchez-Aniceto
Servicio de Cirugía Oral y Maxilofacial, Hospital Universitario 12 de Octubre, Madrid, España

* Autor para correspondencia.

Correo electrónico: victor.zafra.vallejo@gmail.com

(V. Zafra-Vallejo).

1130-0558/

© 2016 SECOM. Publicado por Elsevier España, S.L.U. Este es un artículo Open Access bajo la licencia CC BY-NC-ND (<http://creativecommons.org/licenses/by-nc-nd/4.0/>).

<http://dx.doi.org/10.1016/j.maxilo.2016.09.001>

Leiomyosarcoma of the tongue: A rare case report



Leiomiomasarcoma de la lengua: un caso clínico raro

Introduction

Leiomyosarcomas is rare tumour that arises from smooth muscle cells.^{1,2} They account for 7% of soft tissue sarcomas.¹⁻³ Leiomyosarcoma in the head and neck region account for only 3-10%,^{2,4} and less than 0.1% develops in the oral cavity.² It has been reported that oral leiomyosarcoma shows

a bimodal peak in the third, sixth and seventh decades of life.⁴ Although a possible association with trauma, estrogenic stimulation, ionizing radiation and Epstein-Barr virus has been suggested, its underlying aetiology remains uncertain.^{4,5,9,10} This article describes an additional case of oral leiomyosarcoma affecting the tongue related to ionizing radiation.

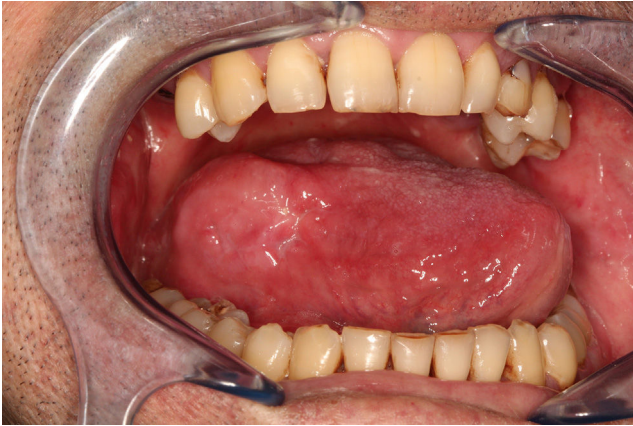

Fig. 1 – Clinical photograph showing the mass within the right side of the tongue.

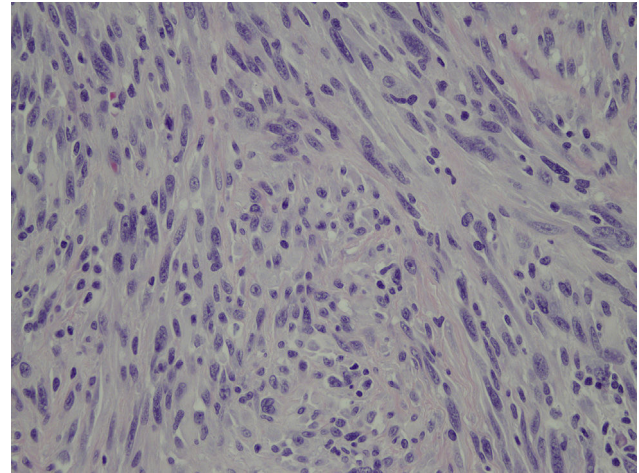


Fig. 2 – Microscopic examination showing interlacing fascicles of spindle-shaped cells (haematoxylin-eosin stain, original magnification, $\times 400$).

Case presentation

A 41-year-old male patient who two years previously had undergone radiotherapy and chemotherapy because of a Cavum Carcinoma, the patient was referred to the maxillofacial department on October of 2014 because a rapidly increasing lesion on the on the right side of the tongue was noticed at the follow-up. Clinical examination showed a well-circumscribed firm, submucosal mass on the right side of the tongue (Fig. 1). No cervical lymphadenopathy was palpable.

As control of his Cavum Carcinoma the patient had a PET/CT scan that only reports a focal uptake on right side of the tongue.

An incisional biopsy was repeated on January 2015 after a first negative result; the histopathology showed an infiltrating spindle cell tumour that stained for smooth muscle actin. The immunohistochemistry stained positively with smooth muscle actin, desmin, and caldesmon (Fig. 2).

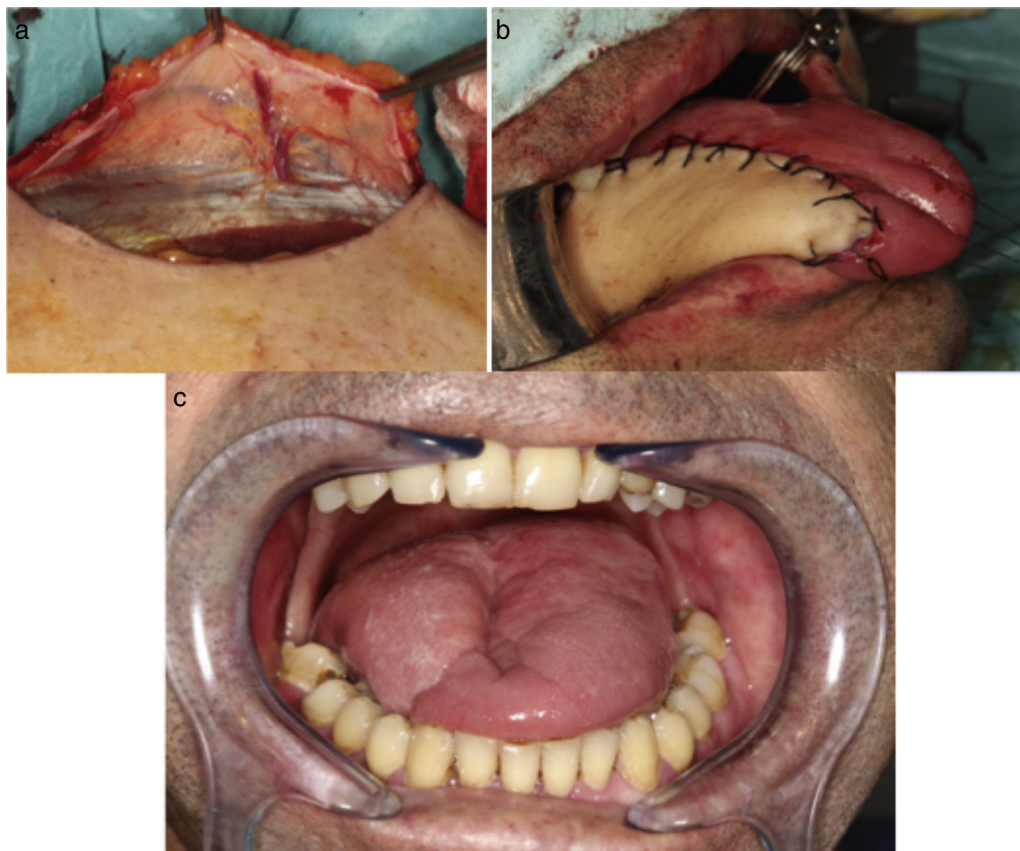

Fig. 3 – (a) Medial sural perforator artery, (b) immediate post-operative reconstruction and (c) postoperative follow up, good cosmetic outcome with a medial sural perforator flap and no recurrence.

Table 1 – Reported cases of primary leiomyosarcoma arising from the tongue.

Study	Year	Gender	Age (yrs)	Site	Metastasis	Treatment	Follow-up (yrs)
Yannopoulos and Stout	1962	M	11 mo	Tip of tongue	No	Excision	4-6
O'Day et al.	1964	M	3	Sublingual	Yes	Excision	2; deceased
O'Day et al.	1964	F	19	Sublingual	Yes	Excision and neck dissection	11
Goldberg et al.	1970	M	54	Sublingual	No	Excision	1.5
Brandjord et al.	1977	F	63	Floor of the mouth	Yes	Excision	2
Mindell et al.	1975	M	59	Tongue - Not specified	No	Excision	3
Lack	1986	M	2.5	Base of tongue	No	Excision and chemotherapy	4
Aydin and Dreyer	1994	M	70	Base and dorsum of tongue	No	Radiotherapy	1.5
Mentzel et al.	1994	F	88	Floor of the mouth	Yes	Excision	10 d, decease
Mayall et al.	1994	M	60	Tip of tongue	No	Excision	1
Piattelli and Artese	1995	F	80	Lateral border of tongue	No	Patient rejected treatment	N/A
Crossman et al.	2008	F	46	Lateral border of tongue	No	Excision	5
Sarra et al.	2009	M	62	Lateral border of tongue	Yes	No treatment	6 mo
Yan et al.	2010	M	48	Floor of mouth	No	Excision and suprahyoid neck dissection	1.5, deceased
Pires et al.	2010	M	55	Lateral border of tongue	No	Excision	4
Ahn et al.	2011	F	54	Lateral border of tongue	Yes	Palliative chemotherapy	1 mo
Toranzo et al.	2012	F	73	Lateral border of tongue	No	Excision	1
Shütz	2013	M	25	Floor of the mouth	No	Excision and neck dissection	6.5
Present case	2016	M	41	Lateral border of tongue	No	Excision	1.5

He was treated with hemiglossectomy. It was reconstructed with a medial sural perforator flap, and no neck dissection was performed on March of 2015 (Fig. 3a-c). The patient had a good functional and cosmetic result with no signs of recurrence in subsequent follow-ups, last one on July 2016.

Review of literature

The cases reported in the literature are summarized in Table 1. We included Oral LMS that only affected the tongue; publish in the English and Spanish literature with all the variables included in the table. The exclusion criteria were LMS not affecting the tongue and publication with incomplete medical reports.

Discussion

Intraoral leiomyosarcoma, particularly in the tongue are extreme rare. They arise from smooth muscle cells.^{1,2,5-11} Intraoral leiomyosarcoma occurs more frequently in males.⁴ Clinically the tumour presents as a well-circumscribed painless mass. The correct diagnosis is only made following a definitive histological examination and confirmed by immunohistochemistry.^{3,6,8,10,11} Immunohistochemical staining has consistently shown positive for desmine, vimentin, and smooth muscle actine, whereas a negative response to S100 protein and the cytokeratins is usually found.¹⁻⁷

Leiomyosarcoma behaves as an aggressive tumour, and has a tendency to infiltrate surrounding tissues. The more frequent distant metastases of leiomyosarcoma are the head and neck region,²⁻⁵ in 15% of the cases.^{2,3} Metastases can also

spread to the regional lymph nodes, and the lung and the liver are prediction sites for distant metastases.²⁻⁵

The cause of leiomyosarcoma remains unknown, although cases associated with trauma, estrogenic stimulation, ionizing radiation and Epstein-Barr virus have been suggested.^{4,5,9,10}

The treatment consists of wide surgical excision with regional lymph node dissection as required, with the goal of histologically clear margins. This determines the true course of the disease and the long-term prognosis.^{2-5,7-11}

Chemotherapy is generally reserved for palliative cases, such as inoperable tumours or metastatic spread.^{2,8,10}

The case that we report of a primary intraoral leiomyosarcoma it could be induced by ionizing radiation. It is essential that the clinician be familiar with the lesion, and anticipates the possible presence of this disease and makes early diagnosis. Treatment of primary leiomyosarcoma is radical tumour resection with histologically clear margins.

Ethical disclosures

Protection of human and animal subjects. The authors state that no experiments were performed on human beings or animals as part of this investigation.

Confidentiality of data. Authors state they have followed the protocols of their workplace about the data publication of patients.

Right to privacy and informed consent. Authors have obtained the informed consent from the patients or subjects referred to

in the article. This document is in possession of the corresponding author.

Conflict of interest

The authors declare that there are no conflicts of interest.

BIBLIOGRAFÍA

- Vilos GA, Rapidis AD, Lagogiannis GD, Apostolidis C. Leiomyosarcomas of the oral tissues: clinicopathologic analysis of 50 cases. *J Oral Maxillofac Surg.* 2005;63:1461-77.
- Schütz A, Smeets R, Driemel O, Hakim SG, Kosmehl H, Hanken H, et al. Primary and secondary Leiomyosarcoma of the oral and perioral region – clinicopathological and immunohistochemical analysis of a rare entity with a review of the literature. *J Oral Maxillofac Surg.* 2013;71:1132-42.
- Ethunandan M, Stokes C, Higgins B, Spedding A, Way C, Brennan P. Primary oral leiomyosarcoma: a clinico-pathologic study and analysis of prognostic factors. *Int J Oral Maxillofac Surg.* 2007;36:409-16.
- Anh JH, Mirza T, Ameerally P. Leiomyosarcoma of the tongue with multiple metastases: a case report and review of literature. *J Oral Maxillofac Surg.* 2012;70:1745-50.
- Yang S-W, Chen T-M, Tsai C-Y, Lin C-Y. A peculiar site of leiomyosarcoma: the tongue tip—report of a case. *Int J Oral Maxillofac Surg.* 2006;35:469-71.
- Sakamoto K, Matsuzaka K, Yama M, Kakizawa T, Inoue T. A case of leiomyosarcoma arising from the tongue. *Oral Oncol Extra.* 2005;41:49-52.
- Ketabchi A, Kalavrezos N, Newman L. Sarcomas of the head and neck: a 10-year retrospective of 25 patients to evaluate treatment modalities, function and survival. *Br J Oral Maxillofac Surg.* 2011;49:116-20.
- Amarapala H, Tilakaratne WM. Leiomyosarcoma of the oral cavity: report of seven cases and review of literature. *Oral Oncol Extra.* 2006;42:14-7.
- Crossman T, Ward P, Herold J. Leiomyosarcoma of the tongue: a case report. *Br J Oral Maxillofac Surg.* 2008;46:e69-70.
- Toranzo-Fernández JM, Colunga R, González-Valdez LG. Leiomyosarcoma del borde lateral de la lengua: reporte de un caso. *Rev Esp Cir Maxilofac.* 2014;36:27-31.
- Lo Muzio L, Favia G, Mignogna MD, Piattelli A, Maiorano E. Primary intraoral leiomyosarcoma of the tongue: an immunohistochemical study and review of the literature. *Oral Oncol.* 2000;36:519-24.

Carlos Alberto Salcedo-Gil*,
 Víctor Alejandro Lasa-Menéndez,
 María Josefa Pastor-Fortea, José Ignacio Iriarte-Ortabe
 Department of Oral and Maxillofacial Surgery, Son Espases
 University Hospital, Carretera Valldemossa 79, Planta 0 módulo Q.
 Sala 004, 07120 Palma de Mallorca, Spain

* Corresponding author.

E-mail address: salcedocarlosmd@hotmail.com
 (C.A. Salcedo-Gil).
 1130-0558/

© 2016 SECOM. Published by Elsevier España, S.L.U. This is an open access article under the CC BY-NC-ND license (<http://creativecommons.org/licenses/by-nc-nd/4.0/>).
<http://dx.doi.org/10.1016/j.maxilo.2016.10.004>

Giant trabecular type juvenile ossifying fibroma of the maxilla – A case report



Fibroma osificante gigante trabecular del maxilar de tipo juvenil. Presentación de un caso

Introduction

Juvenile ossifying fibromas (JOF) are rare, locally aggressive tumours with high potentials of recurrence. The present case is that of a JOF involving the maxilla causing facial deformity, proptosis and visual impairment in a 12-year-old child which was managed successfully by surgical excision via transfacial approach, with review of the literature.

Case report

A 12-year-old female child presented to our outpatient department with history of a progressive right sided facial swelling, causing facial deformity and proptosis for the past four years. The swelling pushed the right eye outwards and upwards,

causing a painless, progressive diminution of vision and watering in the right eye. There was also a history of progressive nasal obstruction initially in the right nostril, which then went on to involve the left nostril (Fig. 1A and B). At presentation, the patient could only breathe through the mouth due to complete obstruction of both nostrils. She also gave a history of one episode of epistaxis which required hospital admission and conservative management. The past medical record of the child revealed that two years ago, the patient had undergone a biopsy of the mass at an outside hospital and diagnosed as having fibrous dysplasia. On examination the swelling was of the size 18 cm × 15 cm, extending superiorly to the right eyebrow, displacing the right eye supero-laterally; inferiorly till the angle of the mandible; medially till the left side of the nasolabial fold; and laterally till the right zygomatic arch. The swelling was non-tender, with no local rise in