



Note

Disease progression of dermatophytic pseudomycetoma in a Persian cat

Márcia de Oliveira Nobre^{a,*}, Eduardo Negri Mueller^b, Mariana Teixeira Tillmann^b, Cristiano da Silva Rosa^a, Thomas Normanton Guim^c, Patrícia Vives^a, Matheus Fernandes^a, Isabel Martins Madrid^c, Cristina Gevehr Fernandes^d and Mario Carlos Araújo Meireles^e

^a Departamento de Clínicas Veterinárias/Hospital Veterinário, Faculdade de Veterinária, Universidade Federal de Pelotas, Pelotas/RS, Brazil

^b Programa de Pós-Graduação em Veterinária, Mestrado, Universidade Federal de Pelotas, Pelotas/RS, Brazil

^c Programa de Pós-Graduação em Veterinária, Doutorado, Universidade Federal de Pelotas, Pelotas/RS, Brazil

^d Departamento de Patologia Animal, Faculdade de Veterinária, Universidade Federal de Pelotas, Pelotas-RS-Brazil

^e Setor de Micologia, Departamento de Veterinária Preventiva, Universidade Federal de Pelotas, Pelotas-RS, Brazil

ARTICLE INFO

Article history:

Received 10 July 2009

Accepted 23 December 2009

Available online 24 de marzo de 2010

Keywords:

Pseudomycetoma

Mycetoma

Cats

Griseofulvin

A B S T R A C T

Background: Dermatophytic pseudomycetoma is a subcutaneous fungal infection by *Microsporum canis*.

Aims: This work describes a case of dermatophytic pseudomycetoma in a Persian cat.

Patient and methods: A 3-year old female Persian cat showing alopecia, scaling and ulcerated nodules throughout the body, with presence of ulcerated nodules with yellow granular discharges on the dorsum, close to the tail. Mycological and histopathological examinations were realized.

Results: Diagnosis of dermatophytic pseudomycetoma was established. The cat was treated with griseofulvin, and surgical excision was carried out. Response to therapy was effective during the first months, during which a reduction in nodule frequency was observed. However, despite maintaining the therapy levels, the lesions relapsed and progressed to the point of causing the animal's death.

Conclusion: The clinic evolution showed the progressive and recurrent character of dermatophytic pseudomycetoma.

© 2009 Revista Iberoamericana de Micología. Published by Elsevier España, S.L. All rights reserved.

Evolución de un pseudomicetoma dermatofítico en una gata persa

R E S U M E N

Antecedentes: El pseudomicetoma dermatofítico es una infección fúngica subcutánea causada por *Microsporum canis*.

Objetivos: Este trabajo describe un caso de pseudomicetoma dermatofítico presentado por un gato persa.

Paciente y método: Una gata de raza Persa, de 3 años de edad, con signos de alopecia, eritema y nódulos ulcerados, los dos primeros distribuidos en todo el cuerpo, presentó exudado granuloso de color amarillento en los nódulos ulcerados de la región dorsal, próxima a la cola. Fueron realizados exámenes micológicos e histopatológicos.

Resultados: El diagnóstico de pseudomicetoma dermatofítico fue confirmado a través del cultivo y examen histopatológico de las muestras extraídas. El tratamiento se basó en el suministro de griseofulvina y extirpación quirúrgica, obteniéndose una respuesta eficaz durante los primeros meses con reducción en el número de nódulos observados. Con el transcurso del tiempo, y aún bajo tratamiento, fue constatada la reincidencia de las lesiones que finalmente llevaron a la muerte del animal.

Conclusiones: La evolución clínica evidenció el carácter progresivo y recurrente del pseudomicetoma dermatofítico.

© 2009 Revista Iberoamericana de Micología. Publicado por Elsevier España, S.L. Todos los derechos reservados.

Palabras clave:

Pseudomicetoma

Micetoma

Gatos

Griseofulvina

Dermatophytic pseudomycetoma is a subcutaneous fungal infection by *Microsporum canis*, during which the epidermal

stratum corneum is invaded, causing granulomatous dermatitis and panniculitis. In the majority of cases the lesions are characterized clinically by the presence of firm or soft nodules, which can be ulcerated and show granular discharges.^{1,5,7,10}

A 3-year old female Persian cat showing alopecia, scaling and ulcerated nodules was studied. When clinically examined, the

* Corresponding author.

E-mail address: mo-nobre@uol.com.br (M. Nobre de Oliveira).

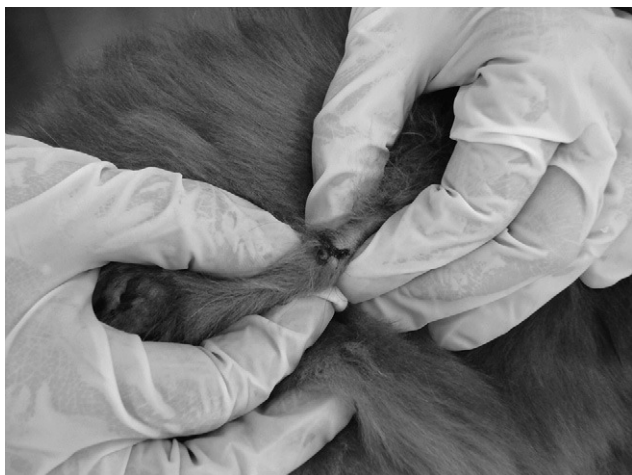

Fig. 1. Relapse of dermatophytic pseudomycetoma lesions showing small nodules throughout the dorsum region with bloody and granular discharges.

feline was considered to be in good condition and remained alert but presented focal areas of alopecia throughout the body. The dorsum region showed small nodules with one of a larger size (3 cm \varnothing) near the tail, ulcerated and presenting a yellow granular discharge. After the clinical examination, exudates were vacuum collected directly from the lesions. Tests were run to determine the hematological profile as well as for the detection of the feline leukemia virus. Isolates of *M. canis* were obtained from exudates, skin and hair specimens.

The results from the hematological profile were found to be within the normal range of values, whilst the feline leukemia virus tested negative, all of which confirmed the dermatophytic pseudomycetoma diagnosis. Therapy with griseofulvin 25 mg kg^{-1} every 12 h and weekly immersions with ketoconazole reduced the frequency of lesions within 2 months, but they did not disappear completely.

After approximately 5 months of therapy the clinical symptoms became more severe and the animal showed an evident discomfort, due essentially to scaling and the formation of several coalescent nodules. The latter were of various diameters (2.5–5.0 cm), whether on the rear dorsum (Fig. 1) or at the tail's base, from which yellow granular exudates were discharged. The adjacent ventral region had a non-ulcerated nodule close to the left inguinal tit.

Surgery therapy was recommended for the excision of the larger nodules, after which they underwent fungal culture and histopathological examination. Fragments and exudates from the inner parts of nodules were collected and cultured on Sabouraud agar mixed with cyclohexamide and chloramphenicol and incubated at 37 °C for 10 days, after which macroscopic and microscopic isolate identifications were carried out. The specimens were stained with haematoxylin-eosin, the periodic acid Schiff (PAS) and silver-metamine Gomori to identify the fungal elements.

Histopathological examinations showed granulomatous inflammation with presence of giant foreign cells, neutrophils and lymphocytes, which surrounded fungal masses with irregular hyphae and bulbous dilatations resembling spores. All these were suspended within an abundant amorphous eosinophilic matrix, typical of the Splendore–Hoepli reaction (Fig. 2). In the cultures, flat, cottony and white with yellow reverse colonies were obtained. In the microscopic examination, hyaline, septate and branched hyphae with plenty of spindle-shaped macroconidia were observed, with asymmetrical apexes and thick walls with

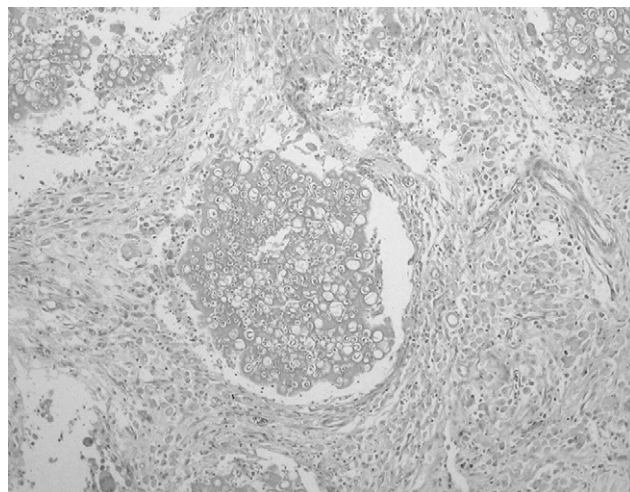


Fig. 2. Presence of granule composed of fungal aggregates embedded in abundant Splendore–Hoepli reaction. At periphery, there are infiltrations of macrophages, lymphocytes and plasma cells, an intense fibroblastic reaction and angiogenesis.



Fig. 3. Formation of several coalesced nodules of different diameters (2.5–5.0 cm) on the dorsum region and base of tail. Nodules show granular discharges.

thin septa, containing 6–15. These findings made the identification of *M. canis* possible.

After surgical excision and with the results from the mycological and histopathological tests, griseofulvin therapy was resumed (25 mg kg^{-1}) and within 30 days the animal showed clear symptoms of clinical recovery. Weight gain, decrease in scaling, better hair appearance and complete healing of the surgery scar were observed. The antifungal agent was administered for 4 months and pulse therapy on griseofulvin (25 mg kg^{-1} 12/12 h, 1 week per month) and weekly immersions with ketoconazole to control dermatophytes on skin and hair were established.

Approximately 6 months after surgery several small nodules reappeared on the dorsum region, from the cervical region across to the base of the tail (Fig. 3). These did not respond to therapy and due to their large number surgical excision was considered impractical. The clinical symptoms progressed to weight loss, apathy, fever and the appearance of several ulcerated, coalesced nodules on the rear dorsum region and the base of the tail (2.5–5.0 cm \varnothing), which showed yellow granular exudates. Scaling was so severe that it eventually led to auto-mutilation. Once again

granular discharge specimens were collected and delivered for mycological examination, which confirmed the pseudomycetoma diagnosis.

Hematological examinations indicated left deviation leukocytosis. Neutraceuticals were employed and therapy involving cephalexine (20 mg kg⁻¹ 12/12 h, 10 days) and griseofulvin (25 mg kg⁻¹ 12/12 h, 90 days) was recommended, but did not yield positive results. Thus, the prescription was shifted to therapy with itraconazole (10 mg kg⁻¹ every 24 h, 30 days), which did not result in improvement, either. The mycosis progressed, with the animal showing obvious discomfort, inappetence and progressive weight loss, eventually leading to the animal's death. Necropsy was performed but no further alterations could be observed.

The majority of studies on this pathology have involved Persian cats^{2,3,6,8,10}; however, some studies have dealt with common, short-haired domestic cats.⁹ Skin lesions are most commonly located on the dorsum region and on the base of the tail^{3,6,9} and it has been suggested that pseudomycetoma in cats may reflect immunodeficiency or aberrant immune response.⁴ In this work the feline tested negative for the feline leukemia virus, which was also the outcome reported in other works and likewise for the feline immunodeficiency virus.^{2,6}

The results from the mycological and histopathological examinations are in agreement with much of the reviewed information regarding the identification of *M. canis*, presence of histiocytic giant cells and the Splendore–Hoeppli reaction.^{2,6,9,10} Isolations of *M. canis* from hair and skin specimens were observed,⁶ which identified ectothrix arthroconidia through direct hair examination.

For the majority of cases of follow up therapy, lesion relapse occurred after variable time periods, even in cases where surgical excision was performed. Similar results were reported for therapies based on antifungal agents, e.g. griseofulvin, itraconazole and/or terbinafine.^{2,9} The presence of granulomas may make difficult drug access to the inner nodule, rich in fungi structures difficult, which may result in a reduction of the efficacy of these

antifungals on *M. canis*. Its use combined with antibiotic therapy was successful in the case of secondary pododermatitis, resulting in reduced number of lesions.⁹ However, progression to death or euthanasia has been common.^{2,9} A recent case of sublumbar pseudomycetoma leading to mechanical obstruction of the colon and rectum was recorded.⁸

The clinic evolution showed the progressive and recurrent character of dermatophytic pseudomycetoma.

Acknowledgments

We thank CNPq for award of a scholarship and Capes for financial support.

References

1. Abramo F, Vercelli A, Mancianti F. Two cases of dermatophytic pseudomycetoma in the dog: an immunohistochemical study. *Vet Dermatol.* 2001;12:203–7.
2. Bond R, Pocknell AM, Toze CE. Pseudomycetoma caused by *Microsporum canis* in a Persian cat: lack of response to oral terbinafine. *J Small Anim Pract.* 2001;42:557–60.
3. Kano R, Edamura K, Yumikura H, Maryuama H, Asano K, Tanaka S, et al. Confirmed case of feline mycetoma due to *Microsporum canis*. *Mycoses.* 2008;52:80–3.
4. Miller WH, Goldschmit MH. Mycetomas in the cat caused by a dermatophyte: case report. *J Am Anim Hosp Assoc.* 1986;22:255–60.
5. Moraes MAP, Machado AAL, Medeiros Filho P, Reis CMS. Pseudomycetoma dermatofítico: relato de um caso devido ao *Trichophyton tonsurans*. *Rev Soc Bras Med Trop.* 2001;34:291–4.
6. Pereira AN, Damico CB, Souza HJM, Corgozinho KB, Graça R, Almeida ECP, et al. Pseudomycetoma Dermatofítico causado por *Microsporum canis* em gato da raça Persa. *Acta Sci Vet.* 2006;34:193–6.
7. Pérez J, Carrasco L. Diagnóstico histopatológico de micosis em patologia veterinária. *Rev Iberoam Micol.* 2000;17:18–22.
8. Stanley SW, Fischetti AJ, Jensen HE. Imaging diagnosis—sublumbar pseudomycetoma in a Persian cat. *Vet Radiol Ultrasound.* 2008;49:176–8.
9. Tostes RA, Giuffrida R. Pseudomycetoma dermatofítico em felinos. *Cienc Rural.* 2003;33:363–5.
10. Zimmerman K, Feldman B, Robertson J, Herring ES, Manning T. Dermal mass aspirate from a Persian cat. *Vet Clin Pathol.* 2003;32:213–7.