



Original article

## Disseminated fusariosis and hematologic malignancies, a still devastating association. Report of three new cases



Juan Carlos García-Ruiz<sup>a</sup>, Iñigo Olazábal<sup>a</sup>, Rosa María Adán Pedroso<sup>b</sup>, Leyre López-Soria<sup>c</sup>,  
Verónica Velasco-Benito<sup>d</sup>, José Antonio Sánchez-Aparicio<sup>e</sup>, Aurora Navajas<sup>b</sup>,  
Miguel Montejo<sup>f</sup>, María-Dolores Moragues<sup>g,\*</sup>

<sup>a</sup> Servicio de Hematología y Hemoterapia, BioCruces Health Research Institute, Hospital Universitario Cruces, Plaza de Cruces s/n, 48903 Barakaldo, Bizkaia, Spain

<sup>b</sup> Servicio de Pediatría, BioCruces Health Research Institute, Hospital Universitario Cruces, Barakaldo, Bizkaia, Spain

<sup>c</sup> Servicio de Microbiología, Hospital Universitario Cruces, Barakaldo, Bizkaia, Spain

<sup>d</sup> Servicio de Anatomía Patológica, BioCruces Health Research Institute, Hospital Universitario Cruces, Barakaldo, Bizkaia, Spain

<sup>e</sup> Servicio de Oftalmología, Hospital Universitario Cruces, Barakaldo, Bizkaia, Spain

<sup>f</sup> Unidad de Enfermedades Infecciosas, Hospital Universitario Cruces, BioCruces Health Research Institute, Universidad del País Vasco (UPV/EHU), Barakaldo, Bizkaia, Spain

<sup>g</sup> Departamento de Enfermería, Escuela de Enfermería, Universidad del País Vasco UPV/EHU, Leioa, Bizkaia, Spain

### ARTICLE INFO

#### Article history:

Received 13 August 2014

Accepted 21 November 2014

Available online 25 March 2015

#### Keywords:

Disseminated fusariosis  
Hematologic malignancies  
*Fusarium oxysporum*  
*Fusarium solani*  
*Fusarium keratoplasticum*  
*Fusarium dimerum*

### ABSTRACT

**Background:** Fungi of the genus *Fusarium* are primarily plant pathogens and saprobes that produce disseminated infections in immunologically deficient humans. After aspergillosis, disseminated fusariosis is the second most common cause of invasive infection by filamentous fungi in patients with hematologic malignancies or those undergoing transplants of hematopoietic progenitors.

**Aims:** Disseminated fusariosis (DF) is considered an extremely rare infection and has reached a stable incidence rate, but its high mortality rate and the lack of an optimal management protocol have raised increasing interest in this mycosis.

**Methods:** We present three cases of DF produced by *Fusarium oxysporum* species complex, *Fusarium solani* species complex and the highly unusual *Fusarium dimerum* in patients with advanced hematological malignancies diagnosed in our hospital between 2007 and 2011. The species level identification of the *Fusarium* isolates was established by sequencing their *TEF1* gene.

**Results:** The isolates showed low susceptibility to most of the antifungal agents analyzed, except that observed for *F. dimerum* to amphotericin B (AmB) and terbinafine, and *F. oxysporum* species complex to AmB. Interestingly, the strain of *F. solani* species complex exhibited high MIC values for AmB and voriconazole, notwithstanding these drugs were used for treatment with good results. Other relevant aspects to be considered in the treatment of DF are surgically cleaning foci of infection, withdrawing presumably contaminated catheters and recovery from neutropenia.

**Conclusions:** The prevention of infection in colonized patients, the maintenance of a high level of diagnostic suspicion for early diagnosis, and the combined, vigorous and prolonged use of L-AmB and voriconazole are essential to decrease the mortality rate of this devastating infection.

© 2014 Revista Iberoamericana de Micología. Published by Elsevier España, S.L.U. All rights reserved.

## Fusariosis diseminada y neoplasias hematológicas, una asociación devastadora todavía. Tres nuevos casos

### RESUMEN

**Antecedentes:** Los hongos del género *Fusarium* son principalmente patógenos vegetales que producen infecciones diseminadas en personas con deficiencias inmunológicas. Tras la aspergilosis, la fusariosis diseminada es la segunda causa de infección invasora por hongos filamentosos en pacientes con enfermedades hematológicas malignas o en receptores de trasplantes de progenitores hematopoyéticos.

#### Palabras clave:

Fusariosis diseminada  
Neoplasias hematológicas  
*Fusarium oxysporum*

\* Corresponding author.

E-mail address: [lola.moragues@ehu.es](mailto:lola.moragues@ehu.es) (M.-D. Moragues).

*Fusarium solani*  
*Fusarium keratoplasticum*  
*Fusarium dimerum*

**Objetivos:** La fusariosis diseminada es muy infrecuente y ha alcanzado una tasa de incidencia estable. Sin embargo, el interés por estas micosis se ha incrementado debido a su alta tasa de mortalidad y a la falta de un tratamiento óptimo.

**Métodos:** Se presentan tres casos de fusariosis diseminada por *Fusarium oxysporum* species complex (SC), *Fusarium solani* SC y *Fusarium dimerum* en pacientes de nuestro hospital con enfermedades hematológicas avanzadas, diagnosticados entre 2007 y 2011. Los aislamientos de *Fusarium* se identificaron mediante secuenciación del gen *TEF1*.

**Resultados:** La sensibilidad a los antifúngicos ensayados fue baja salvo a la anfotericina B (AmB) y la terbinafina en *F. dimerum*, y a la AmB en *F. oxysporum* SC. Aunque *F. solani* SC mostró valores altos de CMI para la AmB y el voriconazol, su uso para el tratamiento del paciente dio buenos resultados. Otros aspectos relevantes para el tratamiento de la fusariosis diseminada son la limpieza quirúrgica de los focos de infección, la retirada de catéteres presumiblemente contaminados y la recuperación de la neutropenia.

**Conclusiones:** La prevención de la infección en pacientes colonizados, el mantenimiento de un alto grado de sospecha para un diagnóstico temprano y el uso combinado, vigoroso y prolongado de L-AmB y voriconazol son esenciales para disminuir la mortalidad de esta infección devastadora.

© 2014 Revista Iberoamericana de Micología. Publicado por Elsevier España, S.L.U. Todos los derechos reservados.

Fungi of the genus *Fusarium* are primarily recognized as plant pathogens since they are responsible for a wide variety of diseases in the plant kingdom, sometimes with devastating socioeconomic impact.<sup>29</sup> Under favorable environmental conditions, they can also produce mycotoxins, with remarkable implications for animal and human health.<sup>29</sup> Regarding human beings, *Fusarium* spp. can produce syndromes ranging from allergic sinusitis, food poisoning, or surface infections such as onychomycosis or keratitis, to locally invasive or disseminated infections depending on the immunological competence of the host.<sup>15,29,32</sup> Like other invasive fungal infections (IFIs), disseminated fusariosis (DF) is observed most frequently in patients with hematologic malignancies or those undergoing hematopoietic stem cell transplant (HSCT).<sup>14,25,33,34</sup> According to some authors, DF is, after aspergillosis, the second most prevalent cause of IFIs by filamentous fungi in this group of patients.<sup>8,13</sup> Despite being considered an extremely rare infection and having reached a stable incidence rate,<sup>6,9,30,38–41</sup> this IFI has attracted growing interest in recent years due to its high mortality rate and the lack of an optimal treatment protocol.<sup>9,22,32</sup> Here we present three cases of DF produced by *Fusarium oxysporum* species complex, *Fusarium solani* species complex and the extremely rare *Fusarium dimerum* in three patients with advanced hematological malignancies observed in our hospital during the period between 2007 and 2011. We also review the current state of the art for the clinical diagnosis and treatment of this devastating infection.

## Patients and methods

### Patient 1

A 55-year-old man diagnosed with advanced cutaneous lymphoma, mycosis fungoides type, with fever and painful oral ulcers was admitted to our unit in April 2007. He had received the third cycle of treatment with denileukin diftitox (Ontak, anti-CD25) (day 0) for rescue therapy due to resistance to bexarotene, psoralen+ultraviolet A light, interferon, and polychemotherapy (nitrogen mustard, gemcitabine, fludarabine, methotrexate, cisplatin, etoposide and cytarabine). He presented an extensive skin involvement due to lymphoma and a large ulceration with necrotic background on the left area of his calf. Cutaneous lesions and blood cultures rendered mixed cultures of *Stenotrophomonas maltophilia* and *Enterobacter cloacae*, and a high viral load of cytomegalovirus was also detected in the blood. *Fusarium* sp. was identified in the wound on his left leg on day 18 since hospital admission. The use of imipenem, vancomycin, metronidazole, ganciclovir and surgical debridement of the ulceration temporarily restored the

clinical stability of the patient. However, on days 26 and 29 he presented a new febrile ascent and *Fusarium* sp. was identified in blood cultures (Bactec 9240, Becton Dickinson). The isolate was later identified as *F. oxysporum* species complex. Despite adding liposomal amphotericin B (L-AmB) (5 mg/kg of body weight, intravenously every 24 h) to the antimicrobial regimen the clinical picture evolved to bilateral pneumonia that ended with the death of the patient on day 53 of follow-up. The halo sign was not detected in chest X-ray images and necropsy was not performed. Retrospective determinations of  $\beta(1-3)$ -D-glucan (Fungitell; Associates of Cape Cod, East Falmouth, MA, USA) in sera on days 45, 49 and 51 gave positive results with the following values: 212, 421 and 460 pg/ml, respectively. The observed sensitivity of the *F. oxysporum* isolate to various antifungal agents is shown in Table 1.

### Patient 2

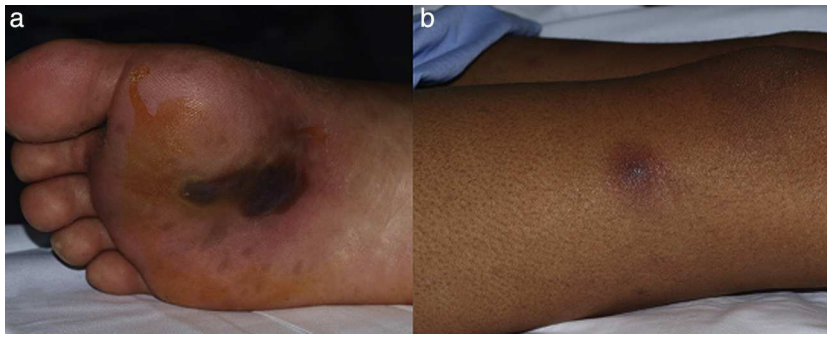
A 29-year-old male patient, recently arrived from Brazil, was diagnosed with an acute myelogenous leukemia (AML) in April 2010. Referred from another center, he was subjected to re-induction treatment in June 2010 (day 0) with cytarabine, idarubicin and etoposide due to lack of response to an earlier administered treatment. To prevent cerebral relapse, intrathecal chemotherapy with methotrexate, cytarabine and hydrocortisone was administered on day 1. He received oral prophylactic fluconazole (200 mg/day). On day 12 postchemotherapy, with profound neutropenia ( $<0.1$  neutrophils  $\times 10^9/l$ ), he presented an erythematous and indurated lesion on the sole of his foot (Fig. 1a) and treatment with vancomycin and meropenem was started. Fever appeared on day 14, and on day 16 subcutaneous

**Table 1**

In vitro antifungal susceptibility of *Fusarium* spp. isolated from patients. Minimal inhibitory concentration (MIC) values were estimated following the EUCAST-AFST broth microdilution method.<sup>11</sup>

Antifungal agent	MIC ( $\mu$ g/ml) of <i>Fusarium</i> spp. isolates		
	Patient 1 <i>F. oxysporum</i> SC	Patient 2 <i>F. solani</i> SC	Patient 3 <i>F. dimerum</i>
Amphotericin B	1	4	0.25
Itraconazole	>8	>8	>8
Voriconazole	8	>8	4
Posaconazole	2	>8	>8
Caspofungin	>16	>16	>16
Terbinafina	8	>16	1

SC: species complex.



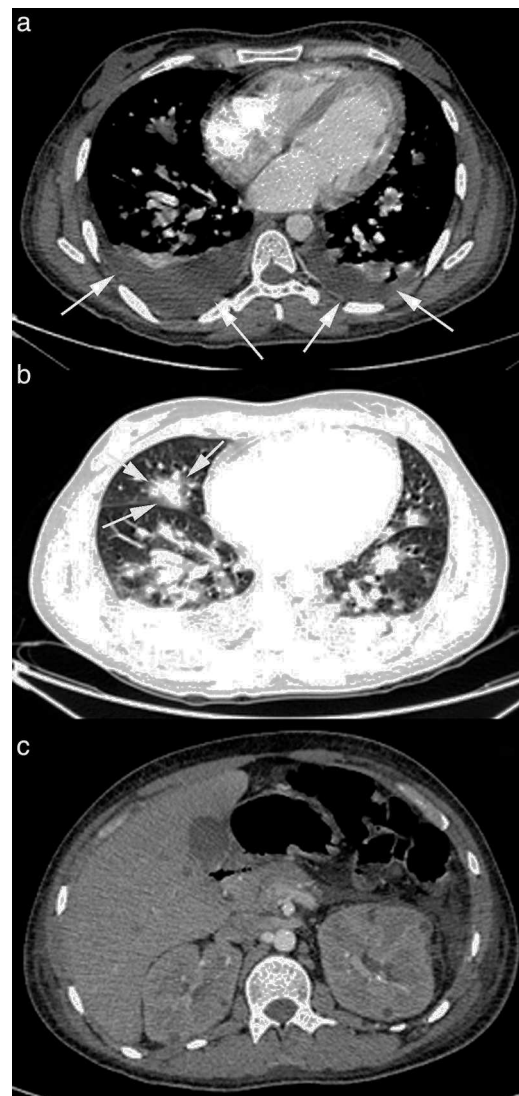
**Fig. 1.** Lesions of patient 2 due to *Fusarium solani* species complex infection. (a) Erythematous lesion on a hemorrhagic background on the sole of his right foot, the probable gateway of the invasion, and (b) subcutaneous nodule with central necrosis surrounded by spreading erythema, reminiscent of ecthyma gangrenosum, on his right limb.

nodules and lesions with central necrosis surrounded by spreading erythema, reminiscent of ecthyma gangrenosum, erupted on his limbs and scalp (Fig. 1b). L-AmB (5 mg/kg every 24 h) was started and biopsies of skin lesions were taken. A computer tomography (CT) of the chest, abdomen and pelvis showed bilateral pleural effusions, pulmonary nodules without lobar predominance, and hypodense lesions in renal, hepatic and splenic parenchyma suggesting microabscesses (Fig. 2). There was an incipient sign of halo surrounding a nodule in the right lung (Fig. 2b). Skin biopsy revealed dermis infiltration by septated, non-pigmented fungal hyphae with vascular invasion (Fig. 3). On day 18, after 52 h of cultivation, *Fusarium* sp. was detected in skin sample cultures. The strains isolated in three blood cultures (Bactec 9240, Becton Dickinson) were identified as *F. solani* species complex. Granulocyte colony-stimulating factor (G-CSF) was administered every other day (300 µg/48 h subcutaneously) to prevent immune reconstitution syndrome, together with voriconazole (VRZ; two doses 6 mg/kg i.v. every 12 h, followed by 4 mg/kg every 12 h) despite the antifungigram results that indicated high MIC values for VRZ (>8 µg/ml) and AmB (4 µg/ml) (Table 1). On day 33, coincident with recovery from neutropenia, he presented a sudden loss of visual acuity in his right eye being subsequently diagnosed as endogenous endophthalmitis (Fig. 4). After vitrectomy and intravitreal instillation with VRZ (0.01% w/v), the patient experienced a complete recovery of visual acuity and clinical restitution. Galactomannan determinations (Platelia Aspergillus EIA test, Bio-Rad) in the sera on days 20, 27, 34, 55, 59, 64 and 70 were negative (index <0.5). After a prolonged treatment with L-AmB and VRZ (80 and 93 days, respectively) the patient consulted for headache and fever and died a few hours later, after hospital admission (day 103). The necropsy study revealed multiple foci of leukemic meningitis in the cerebral parenchyma. Fungal hyphae were observed in the pulmonary parenchyma but cultures were negative. No fungus was found in the skin, brain tissue, cerebrospinal fluid or any other parenchyma studied.

### Patient 3

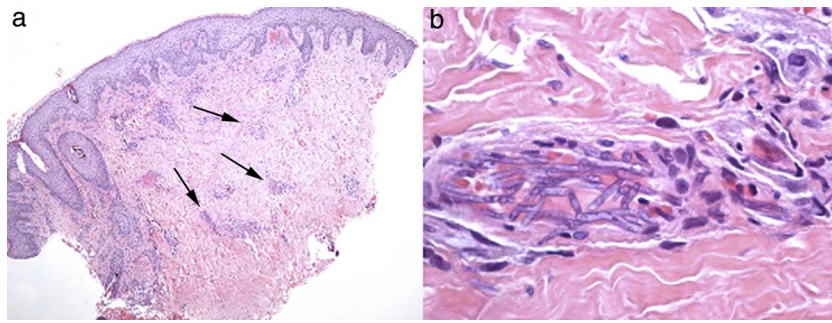
A 15-year-old male patient diagnosed with acute myeloid leukemia (AML) in September 2010 suffered an early relapse of his disease after autologous peripheral blood stem cell transplantation. A second salvage chemotherapy course was started with cytarabine and clofarabine in June 2011 (day 0) due to persistent AML after a previous treatment with fludarabine and cytarabine at high doses with G-CSF priming. He received antifungal prophylaxis with oral fluconazole (200 mg/day), and intrathecal therapy with methotrexate, cytarabine and hydrocortisone was given during intensive treatment to prevent CNS leukemia. During deep neutropenia he presented with fever, and coagulase-negative *Staphylococcus* was isolated in blood cultures. The lack of response

to imipenem, gentamicin and vancomycin advised the addition of L-AmB (5 mg/kg/day) to the antimicrobial regimen. On day 14 postchemotherapy, erythematous and painful nodular lesions were observed on both legs. Hyphal structures were detected in the skin biopsy treated with 10% KOH and a filamentous fungus

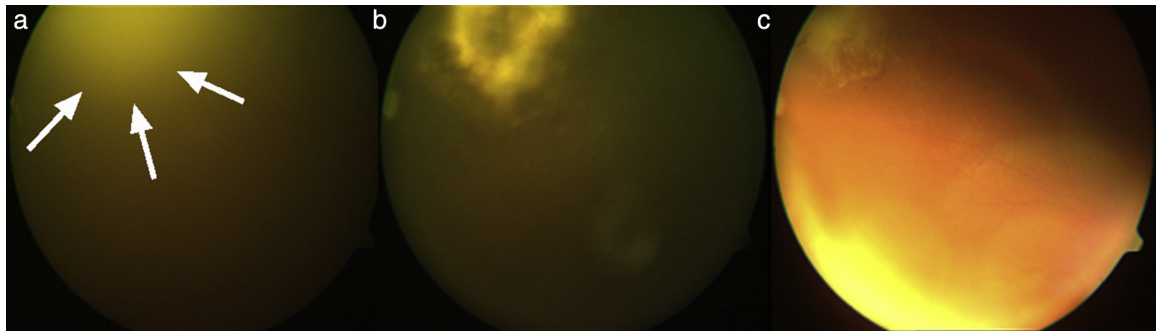


**Fig. 2.** CT scan images of patient 2 infected with *Fusarium solani* species complex. Bilateral pleural effusion (panel a, arrows) and multiple pulmonary nodules, some of them with an incipient “halo sign” (panel b, arrows). Renal and liver microabscesses (panel c).





**Fig. 3.** Skin biopsy of patient 2. (a) Low power image of skin biopsy showing patchy inflammatory infiltrates in the dermis, and (b) high power image of a cutaneous artery showing intraluminal accumulations of *Fusarium solani* species complex hyphae.



**Fig. 4.** Evolution of endogenous fungal endophthalmitis corresponding to patient 2. (a) Severe vitritis with "headlight in the fog" sign due to underlying chorioretinitis caused by *Fusarium solani* species complex; (b) chorioretinitis area in the temporo-superior quadrant of the right eye after vitrectomy, and (c) resolving chorioretinitis one month after therapy with liposomal amphotericin B and voriconazole.

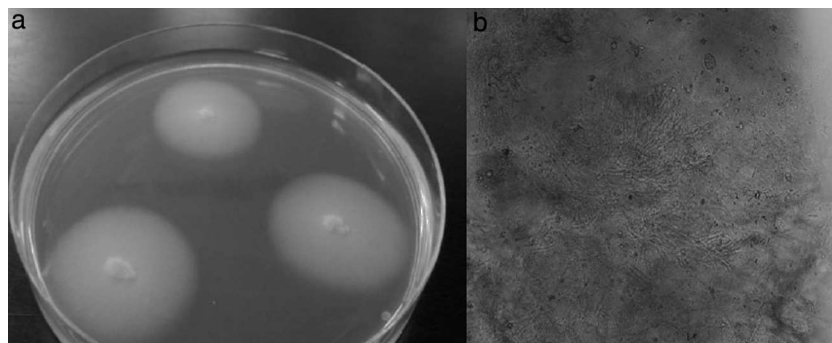
was isolated four days later. The appearance of the colonies was filamentous with a smooth and elevated central area, and the isolate was identified as *F. dimerum* (Fig. 5). Serum *Aspergillus* galactomannan determination was negative on day 14. VRZ was added to the antimicrobial regimen (two doses of 6 mg/kg i.v. at 12 h intervals, followed by 4 mg/kg every 12 h). Chest, abdominal and pelvic CT showed hypodense nodular lesions suggestive of microabscesses in lungs, kidneys, paraspinal muscles and spleen. The halo sign was not seen. Fundus examination was normal. The use of G-CSF (300 µg/24 h subcutaneously) and recovery from neutropenia were accompanied by the disappearance of fever on day 28 and clinical restitution of the patient. As a consequence of persistent leukemia (25% blast cells in bone marrow), the patient received a third course of reinduction treatment similar to the previous one on day 41. A new CT study, carried out prior to chemotherapy, revealed no new lesions while the previously observed pulmonary, renal and splenic nodular lesions were reduced in size. Nevertheless, on day 78, the emergence of new and painful skin nodules was observed and histopathological study and cultivation led to *F. dimerum* isolation. Unfortunately,

our patient died a few days later (day 98). The antifungal treatment consisted of L-AmB for two days followed by combination with VRZ for 33 days, and finally VRZ alone the following 39 days. The antifungal sensitivity of the *F. dimerum* isolate is shown in Table 1.

#### Identification of fungal isolates and antifungal susceptibility tests

The fungal isolates were identified as *Fusarium* spp. based on the characteristics of colonies grown on potato-dextrose agar (PDA) at 35 °C, and microscopic observation of fungal structures stained with lactophenol blue.

Species level identification was accomplished by partial sequencing of the *TEF1* gene. DNA extraction from a seven-day old culture on PDA was accomplished with the UltraClean Microbial DNA isolation kit (MoBio Laboratories, USA) following the manufacturer's instructions with some modifications; after adding the MD1 solution, cells were maintained in liquid nitrogen for 15 min



**Fig. 5.** *Fusarium dimerum* strain isolated from patient 3. (a) Culture on Sabouraud agar, and (b) microscopic observation of a cutaneous biopsy treated with KOH.

followed by another 15-min period in a water bath at 56°C. The extracted DNA was quantified (BioPhotometer plus; Eppendorf AG, Germany) and stored at –70°C. The primers for DNA amplification were EF1 (5'-ATGGGTAAGGA(A/G)GACAAGAC-3') and EF2 (5'-GGA(G/A)GTACCAGT(G/C)ATCATGTT-3').<sup>23</sup> The 50- $\mu$ l final volume of the PCR mix contained 250  $\mu$ M each of deoxynucleotide triphosphates (Applied Biosystems, USA), 0.25  $\mu$ M of each primer EF1 and EF2, 1.5 units of *AmpliTaq*<sup>®</sup> DNA Polymerase (Applied Biosystems), 5  $\mu$ l of *GeneAmp*<sup>®</sup> 10X PCR Buffer (Applied Biosystems) and 10  $\mu$ l of DNA extract. Amplification was performed in a Perkin Elmer GeneAmp PCR System 2400 (Roche Diagnostics Systems, USA), and the cycling conditions were 94°C for 5 min, followed by 30 cycles of 94°C for 30 s, 52°C for 30 s and 72°C for 90 s, and a final extension step at 72°C for 10 min.<sup>23</sup> Amplicons were checked by electrophoresis and PCR products were purified with the commercial NucleoSpin<sup>®</sup> Extract II kit (Macherey-Nagel, Germany) and stored at –20°C until processing. PCR amplicons were sequenced using the BigDye Terminators v3.1 (Applied Biosystems) and the following conditions: 94°C for 3 min, followed by 25 cycles of 96°C for 10 s, 50°C for 5 s, and 60°C for 4 min. DNA samples were processed in an ABI 3130XL sequencer (Applied Biosystems), analyzed with the software program Sequence Scanner v1.0 (Applied Biosystems), and the consensus sequence calculated with the Multiple Sequence Alignment ClustalW2 (UCB, Ireland) program. These sequences were then compared with the BLAST program in GenBank to establish the isolates' identity. The sequences were incorporated into the GenBank database with reference numbers KJ534573 for *F. solani* species complex, KJ534574 for *F. oxysporum* species complex, and KJ534575 for *F. dimerum*. The amplified *TEF* gene sequence of *F. solani* species complex isolate matched that of the recently described species *Fusarium keratoplasticum*<sup>45</sup> included in the *Fusarium* MLST database (<http://www.cbs.knaw.nl/fusarium/>).<sup>37</sup>

In vitro antifungal susceptibility tests for *Fusarium* isolates were performed according to the EUCAST broth microdilution technique<sup>11,50</sup> at the Unidad de Micología del Centro Nacional de Microbiología (Instituto de Salud Carlos III, Madrid, Spain).

## Discussion

*Fusarium* species are ubiquitous fungi in soils rich in organic substrates all over the world, from tropical or temperate regions to the desert, or even Arctic areas, as a consequence of their high adaptability.<sup>19,29</sup> They travel great distances using wind or rain and, like *Aspergillus*, their main portal of entry to the human body is the inhalation of fungal conidia. Wounds in the skin, catheter insertion and cellulite adjacent to paronychia or onychomycosis are also common ways of acquiring a spreading infection,<sup>59</sup> which may apply to cases of patients 1 and 2. *Fusarium* has been identified in the water supplies of hospitals, where showers may contribute as a very effective aerosol system facilitating the inhalation of conidia.<sup>2</sup> Under permissive local conditions, *Fusarium* shows a high capacity to invade blood vessels causing hemorrhagic infarction and tissue necrosis (Fig. 3), and to spread further from there. This characteristic of *Fusarium* could be related to their recognized capacity for adventitious sporulation, resulting in production of blastoconidia in tissues.<sup>21</sup> In addition, it is relatively easy to retrieve it from biological samples since it grows well in culture media, including necropsy material.<sup>51</sup>

Unlike immunocompetent hosts where onychomycosis and keratitis are the most common *Fusarium* infections,<sup>32</sup> disseminated forms are the most frequent clinical presentation of fusariosis in patients with hematologic neoplasms or subjected to hematopoietic stem cell transplant (HSCT), representing 79% and 90% of the observed *Fusarium* infections, respectively.<sup>33,34</sup> The most common

DF pattern shows cutaneous papules or nodules with central necrosis, giving the lesions an ecthyma gangrenosum-like appearance, combined with the isolation of the organism from blood cultures,<sup>32</sup> as observed in patients 2 and 3. In contrast to *Aspergillus* spp. or zygomycetes infections, the presence of *Fusarium* in blood is commonly observed in 40–60% of DF patients.<sup>9,22,32,59</sup> In addition, DF may be accompanied by sinusitis, necrotizing pneumonia or endophthalmitis, clinically indistinguishable from other IFIs,<sup>32</sup> as observed in patients 1 and 2. The cultivation and histopathological analysis of cutaneous lesions are cost-efficient diagnostic tools of DF, as evidenced in Nucci and Anaissie's series that showed that in 76 of 148 patients (51%) with disseminated skin lesions, analysis of this unique location allowed the diagnosis of the infection.<sup>31</sup> In our patients, analysis of cutaneous lesions was the only diagnostic source in patient 3. In contrast, although patients 1 and 2 had cutaneous lesions as well, the *Fusarium* isolates were only identified in blood cultures.

An early diagnosis is critical for infection control. Thoracic CT dramatically improves the sensitivity of simple X-ray to diagnose pulmonary involvement of DF, and consequently it is highly recommended for suspected fungal pneumonia. Similar to aspergillosis, the presence of nodules or masses is the most frequent finding but, in contrast, according to Marom et al.<sup>24</sup> "the halo sign" is not usually found. This situation was observed in patients 1 and 3 of this study, but patient 2 showed an incipient sign of halo in the thoracic CT scan that may reflect a different stage of the infection (Fig. 2b). Serum determination of fungal antigens such as galactomannan and/or  $\beta(1-3)$ -D-glucan has limited value in the diagnosis of DF. However, some authors believe it may be useful in a highly suggestive clinical context of IFI, where positive  $\beta(1-3)$ -D-glucan and negative galactomannan would force the possibility of DF to be considered.<sup>32</sup> Nevertheless, the usefulness of the Platelia *Aspergillus* EIA assay for discriminating against fusariosis has been recently called into question, since positive results have been reported for DF patients as well.<sup>55</sup> In the present work, determinations of  $\beta(1-3)$ -D-glucan in patient 1 sera showed very high values, while galactomannan tests for patients 2 and 3 were negative, reflecting the 'conventional' serological pattern of DF. In our opinion, the value of these tests for DF still remains to be determined.

The first cases of DF in hematological patients were described in children in the 1970s,<sup>10</sup> and later in adults. Despite the medical developments in subsequent years and the use of new antifungal compounds, no significant changes in its high mortality rate have been observed. Recent studies claim values between 63% and 79% on days 90 and 120, respectively, after the microbiological diagnosis. The variables influencing the mortality rate include persistent neutropenia, pulmonary or CNS involvement, fungemia and recent treatment with corticosteroids.<sup>9,22,33,34</sup> According to the series of Nucci et al.<sup>33,34</sup> patients undergoing HSCT achieve even higher mortality rates of 87%, 90 days after DF diagnosis. The species most frequently involved are *F. solani* species complex (50% of cases), *F. oxysporum* species complex (20%) and *Gibberella fujikuroi* species complex (20%), where *Fusarium verticillioides* and *Fusarium proliferatum* are the most representative of the latter.<sup>28,29,32</sup> Other species more rarely involved in DF are *F. dimerum*, *Fusarium chlamydosporum*, *Fusarium sacchari*, *Fusarium nygamai*, *Fusarium napiforme*, *Fusarium antophilum* and *Fusarium vasinfectum* (the latter is a formae specialis of *F. oxysporum* so not a separate species).<sup>32</sup> The low frequency of DF and its relative resistance to most antifungal compounds have not allowed an ideal treatment to be established. However, the observed susceptibility of the isolates to various antifungal agents and the accumulated clinical experience have led to a series of recommendations. Terbinafine has proved a high in vitro activity against strains of *F. dimerum*<sup>4</sup> and *F. verticillioides*<sup>5</sup>; however, Spader et al.<sup>47</sup> did not corroborate this observation for the latter species. The combination of voriconazole and terbinafine

exhibited in vitro synergism against 84% of strains of *F. chlamydosporum*, *F. oxysporum*, *F. proliferatum* and *F. solani*,<sup>47</sup> and Inano et al.<sup>17</sup> have recently reported the first case of disseminated *F. solani* infection successfully treated by combination therapy of VRZ and terbinafine accompanied by surgical resection of endocardial lesions. Terbinafine may be administered topically or orally, however it is not recommended for hematology patients due to its toxic effects on the liver and bone marrow.<sup>18</sup> Fluconazole and echinocandins have apparently no in vitro activity against most *Fusarium* spp. while other azoles such as VRZ, posaconazole and itraconazole show a variable activity according to species.<sup>4,12,43,53</sup>; nevertheless, the strains of *F. solani* SC exhibit high MICs for these azoles.<sup>1,56</sup> These data do not match those published for Nucci's series in 2007,<sup>32</sup> and we still do not know the true meaning of MIC values in the clinical practice.<sup>36</sup> In this way, voriconazole, the most often used azole in recent years, appears clinically effective despite its high MIC values, especially against *F. solani*,<sup>22,35</sup> and even more in combination with AmB.<sup>20</sup> AmB inhibits the fungal growth of most *Fusarium* isolates, including the majority of the strains belonging to the *F. solani* species complex (MIC  $\leq 1 \mu\text{g/ml}$ ) while MICs are higher for *F. verticillioides*.<sup>1,56</sup> Although there are no conclusive data supporting the use of L-AmB together with VRZ, this combination has shown synergistic in vitro activity<sup>46</sup> and has been used successfully in severely compromised patients with DF undergoing allogeneic HSCT.<sup>16,49,52</sup>

Altogether, there is still some degree of consensus that the most active antifungal agents against *Fusarium* in the clinical setting are L-AmB, VRZ and posaconazole.<sup>13,22,26,28,32,40,48,53</sup> The most recent ESCMID & ECMM joint guidelines on diagnosis and management of *Fusarium* spp. mycoses recommend voriconazole and lipid-based amphotericin B formulations, with strong (AII) and moderate (BII) support of the recommendation, respectively.<sup>57</sup> Posaconazole has been proposed in DF patients refractory to conventional therapy, or in patients who show intolerance to AmB<sup>44</sup>; however, this proposal must be taken with reservations since there have been two recent case reports of DF after prophylactic treatment with this triazole derivative.<sup>7</sup>

In agreement with the aforementioned studies of antifungal susceptibility, our three isolates showed low susceptibility to most antifungal agents analyzed, except *F. dimerum* SC (patient 3) to AmB and terbinafine, and *F. oxysporum* SC (patient 1) to AmB (Table 1). Interestingly, despite the *F. solani* SC (*F. keratoplasticum*) isolate exhibiting high MIC values for AmB and VRZ, both drugs were used with good results for the treatment of patient 2. This situation underscores the frequent discrepancy between the clinical evolution of patients and susceptibility test results.

Other relevant aspects to be considered in the treatment of DF are surgically cleaning foci of infection when possible, withdrawing presumably contaminated catheters and recovery from neutropenia with the administration of G-CSF, GM-CSF and granulocyte transfusions. It is noteworthy to highlight the unknown impact that DF pulmonary complications induced by immune reconstitution syndrome may represent for the mortality.<sup>42</sup> The inflammatory reaction triggered by a vigorous and rapid recovery from neutropenia in patients with fungal pneumonia due to *Aspergillus* may cause life-threatening complications such as massive hemoptysis or refractory dyspnea in a significant number of patients.<sup>54</sup> Thus, in patient 2, we tried to modulate the recovery from neutropenia by administering G-CSF on alternate days, since this patient had an extensive lung involvement. In addition, frequent transfusions of platelets, achieving figures higher than 50.000/ $\mu\text{l}$ , were administered to prevent pulmonary bleeding that otherwise would make gaseous exchange difficult. These measures seemed to contribute to the clinical restitution of the patient.

Muhammed et al.<sup>27</sup> remarked that skin lesions in immunocompromised patients should raise the suspicion for skin or

disseminated fusariosis. A recent review by Nucci et al.<sup>36</sup> stated that 14 out of 21 cases of invasive fusariosis showed a primary cutaneous portal of entry. The frequent involvement of the skin in the development of DF makes prevention a hallmark to be kept in mind with some special considerations. It is essential to warn patients, notably those from temperate or tropical countries, of possible skin wounds derived from inadequate footwear or nail care, especially if there are adjacent areas of paronychia or onychomycosis. If such lesions occur, they require surgical cleaning, the administration of topical antifungal agents against *Fusarium* and other filamentous fungi, and microbiological culture before undergoing chemotherapy treatment and/or HSCT.<sup>31</sup> Performing new chemotherapy rounds or HSCTs is controversial since persistent sources of infection might be responsible for a new episode of dissemination, which unfortunately happened to patient 3. Nonetheless, in this case, the activity of the AML forced the treatment. In such a situation, the patient's clinical stability, an absence of new lesions and an intensive treatment with the appropriate antifungal agent should not delay chemotherapy if required.<sup>3,58</sup>

Controlling the hematologic disease and recovering the patient's immune competence are critical for the control of DF; otherwise, the fatality rate of this infection is high. Anyway, the mortality rate of this IFI is still very high in patients with hematologic malignancies, especially for those in advanced stages. In our experience, the management of fusariosis is not well defined and is highly individualized. In our opinion, the prevention of infection in colonized patients, the maintenance of a high level of diagnostic suspicion for early diagnosis, and the combined, vigorous and prolonged use of L-AmB and VRZ are essential to decrease the mortality rate of this devastating infection.

### Conflict of interest

The authors declare no conflict of interest.

### Acknowledgments

This work was supported by the Departamento de Educación, Política lingüística y Cultura del Gobierno Vasco [Basque Government-Spain, grant number IT788-13 to M.-D.M., J.-C.G.R. and I.O.], and the University of the Basque Country [UPV/EHU, grant number UFI11/25 to M.-D.M.].

### References

- Alastruey-Izquierdo A, Cuenca-Estrella M, Monzón A, Mellado E, Rodríguez-Tudela JL. Antifungal susceptibility profile of clinical *Fusarium* spp. isolates identified by molecular methods. *J Antimicrob Chemother.* 2008;61:805–9.
- Anaissie EJ, Kuchar RT, Rex JH, Francesconi A, Kasai M, Muller FM, et al. Fusariosis associated with pathogenic *Fusarium* species colonization of a hospital water system: a new paradigm for the epidemiology of opportunistic mold infections. *Clin Infect Dis.* 2001;33:1871–8.
- Avivi I, Oren I, Haddad N, Rowe JM, Dann EJ. Stem cell transplantation post invasive fungal infection is a feasible task. *Am J Hematol.* 2004;75:6–11.
- Azor M, Gené J, Cano J, Manikandan P, Venkatapathy N, Guarro J. Less-frequent *Fusarium* species of clinical interest: correlation between morphological and molecular identification and antifungal susceptibility. *J Clin Microbiol.* 2009;47:1463–8.
- Azor M, Gené J, Cano J, Sutton DA, Fotherhill AW, Rinaldi MG, et al. In vitro antifungal susceptibility and molecular characterization of clinical isolates of *Fusarium verticillioides* (*F. moniliforme*) and *Fusarium thapsinum*. *Antimicrob Agents Chemother.* 2008;52:2228–31.
- Binder U, Lass-Flörl C. Epidemiology of invasive fungal infections in the mediterranean area. *Mediterr J Hematol Infect Dis.* 2011;3:e20110016, available at <http://www.ncbi.nlm.nih.gov/pmc/articles/PMC3103242/>
- Bose P, Parekh HD, Holter JL, Greenfield RA. Disseminated fusariosis occurring in two patients despite posaconazole prophylaxis. *J Clin Microbiol.* 2011;49:1674–5.
- Boutati EI, Anaissie EJ. *Fusarium*, a significant emerging pathogen in patients with hematologic malignancy: ten years' experience at a cancer center and implications for management. *Blood.* 1997;90:999–1008.



9. Campo M, Lewis RE, Kontoyiannis DP. Invasive fusariosis in patients with hematologic malignancies at a cancer center: 1998–2009. *J Infect.* 2010;60:331–7.
10. Cho CT, Vats TS, Lowman JT, Brandsberg JW, Tosh FE. *Fusarium solani* infection during treatment for acute leukemia. *J Pediatr.* 1973;83:1028–31.
11. Chryssanthou E, Cuenca-Estrella M. Comparison of the EUCAST-AFST broth dilution method with the CLSI reference broth dilution method (M38-A) for susceptibility testing of posaconazole and voriconazole against *Aspergillus* spp. *Clin Microbiol Infect.* 2006;12:901–4.
12. Diekema DJ, Messer SA, Hollis RJ, Jones RN, Pfaller MA. Activities of caspofungin, itraconazole, posaconazole, ravuconazole, voriconazole, and amphotericin B against 448 recent clinical isolates of filamentous fungi. *J Clin Microbiol.* 2003;41:3623–6.
13. Dignani MC, Anaissie E. Human fusariosis. *Clin Microbiol Infect.* 2004;10 Suppl. 1:67–75.
14. Girmenia C, Pagano L, Corvatta L, Mele L, del Favero A, Martino P. The epidemiology of fusariosis in patients with haematological diseases. *Gimema Infection Programme.* Br J Haematol. 2000;111:272–6.
15. Guarro J, Pastor FJ. Fusariosis. In: Pontón J, Quindós G, editors. *Micosis invasoras en los pacientes oncohematológicos.* Bilbao, Spain: Asociación Española de Micología; 2009. p. 57–63.
16. Ho DY, Lee JD, Rosso F, Montoya JG. Treating disseminated fusariosis: amphotericin B, voriconazole or both. *Mycoses.* 2007;50:27–31.
17. Inano S, Kimura M, Iida J, Arima N. Combination therapy of voriconazole and terbinafine for disseminated fusariosis: case report and literature review. *J Infect Chemother.* 2013;19:1173–80.
18. Iverson SL, Uetrecht JP. Identification of a reactive metabolite of terbinafine: insights into terbinafine-induced hepatotoxicity. *Chem Res Toxicol.* 2001;14:175–81.
19. Jensen TG, Gahrn-Hansen B, Arendrup M, Bruun B. *Fusarium* fungaemia in immunocompromised patients. *Clin Microbiol Infect.* 2004;10:499–501.
20. Liu J-Y, Chen W-T, Ko B-S, Yao M, Hsueh P-R, Hsiao C-H, et al. Combination antifungal therapy for disseminated fusariosis in immunocompromised patients: a case report and literature review. *Med Mycol.* 2011;49:872–8.
21. Liu K, Howell DN, Perfect JR, Schell WA. Morphologic criteria for the preliminary identification of *Fusarium*, *Paecilomyces*, and *Acremonium* species by histopathology. *Am J Clin Pathol.* 1998;109:45–54.
22. Lortholary O, Obenga G, Biswas P, Caillot D, Chachaty E, Bienvenu AL, et al. International retrospective analysis of 73 cases of invasive fusariosis treated with voriconazole. *Antimicrob Agents Chemother.* 2010;54:4446–50.
23. Marinach-Patrice C, Lethuillier A, Marly A, Brossas JY, Gene J, Symoens F, et al. Use of mass spectrometry to identify clinical *Fusarium* isolates. *Clin Microbiol Infect.* 2009;15:634–42.
24. Marom EM, Holmes AM, Bruzzi JF, Truong MT, O'Sullivan PJ, Kontoyiannis DP. Imaging of pulmonary fusariosis in patients with hematologic malignancies. *Am J Roentgenol.* 2008;190:1605–9.
25. Marr KA, Carter RA, Crippa F, Wald A, Corey L. Epidemiology and outcome of mould infections in hematopoietic stem cell transplant recipients. *Clin Infect Dis.* 2002;34:909–17.
26. Miceli MH, Lee SA. Emerging moulds: epidemiological trends and antifungal resistance. *Mycoses.* 2011;54:e666–78.
27. Muhammed M, Anagnostou T, Desalermos A, Kourkoumpetis TK, Carneiro HA, Glavis-Bloom J, et al. *Fusarium* infection: report of 26 cases and review of 97 cases from the literature. *Medicine (Baltimore).* 2013;92:305–16.
28. Muhammed M, Coleman JJ, Carneiro HA, Mylonakis E. The challenge of managing fusariosis. *Virulence.* 2011;2:91–6.
29. Nelson PE, Dignani MC, Anaissie EJ. Taxonomy, biology, and clinical aspects of *Fusarium* species. *Clin Microbiol Rev.* 1994;7:479–504.
30. Neofytos D, Horn D, Anaissie E, Steinbach W, Olyaei A, Fishman J, et al. Epidemiology and outcome of invasive fungal infection in adult hematopoietic stem cell transplant recipients: analysis of Multicenter Prospective Antifungal Therapy (PATH) Alliance registry. *Clin Infect Dis.* 2009;48:265–73.
31. Nucci M, Anaissie E. Cutaneous infection by *Fusarium* species in healthy and immunocompromised hosts: implications for diagnosis and management. *Clin Infect Dis.* 2002;35:909–20.
32. Nucci M, Anaissie E. *Fusarium* infections in immunocompromised patients. *Clin Microbiol Rev.* 2007;20:695–704.
33. Nucci M, Anaissie EJ, Queiroz-Telles F, Martins CA, Trabasso P, Solza C, et al. Outcome predictors of 84 patients with hematologic malignancies and *Fusarium* infection. *Cancer.* 2003;98:315–9.
34. Nucci M, Marr KA, Queiroz-Telles F, Martins CA, Trabasso P, Costa S, et al. *Fusarium* infection in hematopoietic stem cell transplant recipients. *Clin Infect Dis.* 2004;38:1237–42.
35. Nucci M, Marr KA, Vehreschild MJ, de Souza CA, Velasco E, Cappellano P, et al. Improvement in the outcome of invasive fusariosis in the last decade. *Clin Microbiol Infect.* 2014;20:580–5.
36. Nucci M, Varon AG, Garnica M, Akita T, Barreiros G, Trope BM, et al. Increased incidence of invasive fusariosis with cutaneous portal of entry, Brazil. *Emerg Infect Dis.* 2013;19:1567–72.
37. O'Donnell K, Sutton DA, Rinaldi MG, Sarver BAJ, Balajee SA, Schroers HJ, et al. Internet-accessible DNA sequence database for identifying *Fusaria* from human and animal infections. *J Clin Microbiol.* 2010;48:3708–18.
38. Pagano L, Caira M, Candoni A, Offidani M, Fianchi L, Martino B, et al. The epidemiology of fungal infections in patients with hematologic malignancies: the SEIFEM-2004 study. *Haematologica.* 2006;91:1068–75.
39. Pagano L, Caira M, Nosari A, Van Lint MT, Candoni A, Offidani M, et al. Fungal infections in recipients of hematopoietic stem cell transplants: results of the SEIFEM B-2004 study – Sorveglianza Epidemiologica Infezioni Fungine Nelle Emopatie Maligne. *Clin Infect Dis.* 2007;45:1161–70.
40. Pagano L, Caira M, Valentini CG, Posteraro B, Fianchi L. Current therapeutic approaches to fungal infections in immunocompromised hematological patients. *Blood Rev.* 2010;24:51–61.
41. Park BJ, Pappas PG, Wannemuehler KA, Alexander BD, Anaissie EJ, Andes DR, et al. Invasive non-*Aspergillus* mold infections in transplant recipients, United States, 2001–2006. *Emerg Infect Dis.* 2011;17:1855–64.
42. Perfect JR. The impact of the host on fungal infections. *Am J Med.* 2012;125:S39–51.
43. Pfaller MA, Diekema DJ. Rare and emerging opportunistic fungal pathogens: concern for resistance beyond *Candida albicans* and *Aspergillus fumigatus*. *J Clin Microbiol.* 2004;42:4419–31.
44. Raad II, Hachem RY, Herbrecht R, Graybill JR, Hare R, Corcoran G, et al. Posaconazole as salvage treatment for invasive fusariosis in patients with underlying hematologic malignancy and other conditions. *Clin Infect Dis.* 2006;42:1398–403.
45. Short DP, O'Donnell K, Thrane U, Nielsen KF, Zhang N, Juba JH, et al. Phylogenetic relationships among members of the *Fusarium solani* species complex in human infections and the descriptions of *F. keratoplasticum* sp. nov. and *F. petroliophilum* stat nov. *Fungal Genet Biol.* 2013;53:59–70.
46. Spader TB, Venturini TP, Cavalheiro AS, Mahl CD, Mario DN, Lara VM, et al. In vitro interactions between amphotericin B and other antifungal agents and rifampin against *Fusarium* spp. *Mycoses.* 2011;54:131–6.
47. Spader TB, Venturini TP, Rossato L, Denardi LB, Cavalheiro PB, Botton SA, et al. Synergism of voriconazole or itraconazole with other antifungal agents against species of *Fusarium*. *Rev Iberoam Micol.* 2013;30:200–4.
48. Stanzani M, Tumietto F, Vianelli N, Baccarani M. Update on the treatment of disseminated fusariosis: focus on voriconazole. *Ther Clin Risk Manag.* 2007;3:1165–73.
49. Stanzani M, Vianelli N, Bandini G, Paolini S, Arpinati M, Bonifazi F, et al. Successful treatment of disseminated fusariosis after allogeneic hematopoietic stem cell transplantation with the combination of voriconazole and liposomal amphotericin B. *J Infect.* 2006;53:e243–6.
50. Subcommittee on Antifungal Susceptibility Testing of the ESCMID European Committee for Antimicrobial Susceptibility Testing. EUCAST Technical Note on the method for the determination of broth dilution minimum inhibitory concentrations of antifungal agents for conidia-forming moulds. *Clin Microbiol Infect.* 2008;14:982–4.
51. Tarrand JJ, Lichtenfeld M, Warraich I, Luna M, Han XY, May GS, et al. Diagnosis of invasive septate mold infections. A correlation of microbiological culture and histologic or cytologic examination. *Am J Clin Pathol.* 2003;119:854–8.
52. Tezcan G, Ozhak-Baysan B, Alastruey-Izquierdo A, Ogunc D, Ongut G, Yildiran ST, et al. Disseminated fusariosis caused by *Fusarium verticillioides* in an acute lymphoblastic leukemia patient after allogeneic hematopoietic stem cell transplantation. *J Clin Microbiol.* 2009;47:278–81.
53. Thursky KA, Playford EG, Seymour JF, Sorrell TC, Ellis DH, Guy SD, et al. Recommendations for the treatment of established fungal infections. *Intern Med J.* 2008;38:496–520.
54. Todeschini G, Murari C, Bonesi R, Pizzolo G, Verlato G, Tecchio C, et al. Invasive aspergillosis in neutropenic patients: rapid neutrophil recovery is a risk factor for severe pulmonary complications. *Eur J Clin Invest.* 1999;29:453–7.
55. Tortorano AM, Esposto MC, Prigitano A, Grancini A, Ossi C, Cavanna C, et al. Cross-reactivity of *Fusarium* spp. in the *Aspergillus* galactomannan enzyme-linked immunosorbent assay. *J Clin Microbiol.* 2012;50:1051–3.
56. Tortorano AM, Prigitano A, Esposto MC, Arsic Arsenijevic V, Kolarovic J, Ivanovic D, et al. European Confederation of Medical Mycology (ECMM) epidemiological survey on invasive infections due to *Fusarium* species in Europe. *Eur J Clin Microbiol Infect Dis.* 2014;33:1623–30.
57. Tortorano AM, Richardson M, Roilides E, van Diepeningen A, Caira M, Munoz P, et al. ESCMID & ECMM Joint Guidelines on Diagnosis and Management of Hyalohyphomycosis: *Fusarium* spp., *Scedosporium* spp. and others. *Clin Microbiol Infect.* 2014;20 Suppl. 3:27–46.
58. Vaidya SJ, Ortin M, Lopez-Duarte M, Sirohi B, Powles R, Treleaven J, et al. Haemopoietic progenitor cell transplantation in patients with previous history of invasive fungal infection. *Leuk Lymphoma.* 2005;46:1143–50.
59. Walsh TJ, Groll A, Hiemenz J, Fleming R, Roilides E, Anaissie E. Infections due to emerging and uncommon medically important fungal pathogens. *Clin Microbiol Infect.* 2004;10 Suppl. 1:48–66.