

Injertos arteriales múltiples en cirugía coronaria: razonamiento e importancia

James Tatoulis

Cardiothoracic Surgery
Royal Melbourne Hospital. Australia

El desarrollo progresivo de ateromatosis y el fracaso a largo plazo de los injertos venosos ha conducido a la utilización de injertos arteriales en cirugía coronaria. La arteria mamaria interna izquierda para revascularizar la arteria descendente anterior, pero los injertos arteriales múltiples son todavía infrecuentes. Las limitaciones son un tiempo operatorio prolongado y la posible influencia sobre la morbilidad peroperatoria, en especial sobre la infección esternal, así como la capacidad de los injertos arteriales para proporcionar flujo adecuado.

La evidencia acumulada apoya el uso de injertos arteriales múltiples; hay comunicaciones que confirman que dos arterias mamarias son mejor que una, y que la revascularización arterial completa podría ser, incluso, mejor. Estas estrategias arteriales resultarían en una supervivencia a 10 años un 10% superior, asociándose a una tasa inferior de eventos cardíacos. La introducción de la arteria radial y de la arteria gastroepiploica ha ampliado la aplicabilidad de los injertos arteriales en intervenciones primarias y reintervenciones. La preferencia por los injertos arteriales evita las complicaciones de la extremidad inferior y facilita una deambulación precoz. Su permeabilidad es superior a cualquier intervalo postoperatorio y la diferencia y superioridad sobre las venas aumenta con el tiempo.

Los injertos arteriales en la enfermedad multivascular pueden utilizarse en la cirugía coronaria con y sin circulación extracorpórea. La revascularización arterial completa también ofrece resultados superiores en comparación con los dispositivos endocoronarios liberadores de fármacos en el segui-

Multiple arterial grafting in coronary surgery: rationale and importance

concern over the progressive development of atheroma and long-term failure of saphenous vein grafts in coronary surgery has led to the use of arterial grafts. Though the left internal thoracic artery is widely used to revascularize the left anterior descending, multiple arterial grafting remains uncommon. Barriers include prolonging operation and anesthetic times, and concerns regarding perioperative morbidity, particularly increased sternal infection, and the ability of arterial grafts to provide adequate flow.

However, the accumulated evidence supports the use of multiple arterial grafts, with multiple reports indicating that two internal thoracic artery grafts are better than one, and that total arterial grafting may be better still. These arterial strategies may result in superior survivals of 10% or more after 10 years of follow-up, and additionally are associated with fewer interval major cardiac adverse events. The introduction of radial artery, and to a lesser extent gastroepiploic artery conduits, has widened the applicability of arterial grafting in both routine primary surgeries, but also in reoperations. Preference for arterial over vein grafts avoids leg wound complications and ensures earlier ambulation. Patencies of arterial grafts are superior at every interval postoperatively, and the difference (and superiority) over vein grafts increases progressively with time.

Correspondencia:
James Tatoulis
Cardiothoracic Surgery
Royal Melbourne Hospital
Victoria 3050, Australia
E-mail: james.tatoulis@mh.org.au

Recibido 17 octubre 2007
Aceptado 20 noviembre 2007

miento superior a 3 años, con menor tasa de reintervenciones y coste y mejor supervivencia.

Palabras clave: Injertos arteriales coronarios. Revascularización miocárdica. Arteria radial. Stents coronarios.

Arterial grafting for multi-vessel coronary disease can be used for either on-pump or off-pump surgery. It also yields superior results compared to multi-vessel drug eluting stents for follow-ups three years and beyond, with fewer re-interventions, lower costs, and better survival.

Key words: Arterial coronary graft conduits. Myocardial revascularization. Radial artery. Coronary stents.

INTRODUCTION

The use of arterial conduits is one of the most significant advances in coronary artery bypass grafting (CABG) since its inception in 1967. Although improved myocardial protection and off-pump techniques have been additional major advances, these have largely improved the immediate perioperative results. Arterial conduits can be used in addition to optimum myocardial protection, on- or off-pump strategies, and have a profound influence on the long-term prognosis, with less symptom recurrence, fewer myocardial infarctions, hospital admissions, and reoperations, and result in superior long-term graft patencies and patient survival¹⁻³.

This article will consider the barriers to arterial/coronary revascularization (including total arterial revascularization), and present the rationale for arterial grafting, its role in special circumstances, and the opportunities to compete with percutaneous coronary intervention and coronary stenting.

REQUIREMENTS FOR ARTERIAL GRAFTING

Arterial conduits must be harvested atraumatically. Spasm due to handling and the cool temperature of the operating room should be minimized and reversed⁴. We use topical papaverine 0.5% (papaverine 30 mg in 60 ml of the patients' heparinized arterial blood at 37° C together with Ringer's lactate), intravenous nitroglycerine (30-200 µg/min) intraoperatively and for the first 24 hours, and amlodipine, a once-daily oral calcium channel blocker, 5 mg for six months⁵. In addition to papaverine, phenoxybenzamine and glyceryl trinitrate/verapamil solutions are also effective topically^{6,7}.

Competitive flow must be avoided and will be addressed later. In general, "string signs" secondary to competitive flow will occur if an internal thoracic artery (ITA) graft is anastomosed to a coronary artery that has a stenosis of < 50%. Radial artery (RA) and right gas-

troepiploic artery (RGEA) grafts have a higher incidence of failure if the native coronary stenosis is < 80%⁸.

Arterial grafting must be achieved with optimum contemporary results (perioperative mortality of 1%, and an incidence of major morbidities of 1% or less each) using the most effective myocardial, cerebral, and renal protective strategies available in CABG practice. In a recent multicentre 10-year analysis of over 70,000 patients, Baskett, et al. reported an increase of complete arterial grafting from 3 to 12% with no change in perioperative mortality (1.5% for left ITA plus vein graft vs. 1.7% for all arterial; p = 0.56)⁹.

BARRIERS TO TOTAL ARTERIAL GRAFTING

The left ITA (LITA) for the left anterior descending (LAD), and saphenous vein grafts (SVG) for all other vessels, remains the universal CABG strategy in over 90% of cases. Even as recently as 2003, the Society of Thoracic Surgeons database showed only 80% of patients received one arterial graft, and < 4% received two arterial grafts. In the UK, < 10% of patients received two arterial grafts. This prompts the question, why are multiple arterial grafts not more frequently used?

Undoubtedly, extra time is required. Whilst the left RA can be harvested simultaneously with the left ITA, harvesting of the right ITA, or the right RA (as part of a bilateral RA procedure) takes an additional 30-45 minutes.

There is a perception of increased perioperative mortality and morbidity associated with multiple arterial grafting; however, with due care, this has not been the case (Table I). Concerns regarding increased rates of sternal wound infection can be overcome by using skeletonized ITA and, if necessary, avoiding bilateral ITA in grossly obese, insulin-dependent diabetic patients with significant chronic obstructive airways disease. Excellent glycemic control is also important and can be readily achieved by insulin infusions^{5,10,11}. However bilateral ITA could still be appropriate to consider for the majority of patients.

TABLE I. MULTIPLE ARTERIAL GRAFTING – PERIOPERATIVE RESULTS

Group	Operative mortality %	Stroke %	Deep sternal infection %
Cleveland Clinic	0.7	1.1	2.3
Tatoulis/Buxton	0.9	1.2	0.9
Mayo Clinic	0.0	1.2	2.2
Calafiore	1.2	1.2	1.5
Tector	0.9		
Stevens	1.2		1.3
Baskett	1.7		
Berrekouw	1.0	1.0	0.0
Schmidt	1.8		1.0
Galbut	2.7	1.4	1.4
Dion	2.0	0.5	4.1
Barner	0.0	2.2	0.0
Mohr	3.0	1.6	2.2
Bical	1.6	1.1	1.1
Average	1.3%	1.1%	1.7%

The lack of large randomized studies comparing single ITA and bilateral ITA are also of a concern, which undermines the longer and more complex operation. Arterial grafting is also considered to be more technically demanding, but this is unlikely as all surgeons use the left ITA daily in their practice. The right ITA is no different (and in most right-handed people often larger), and the RA are larger still and more robust. Arterial grafts are always of larger caliber than the coronary to be grafted, except occasionally for the right coronary artery. It is a matter of patience rather than additional technical skill¹²⁻¹⁵.

A further concern is that the flow through arterial grafts may be insufficient to meet the myocardial demands. This is unfounded (providing the grafts are not in spasm, not damaged). Measured flows into coronary territories range from 30-60 ml/minute, whereas free flow from an ITA usually exceeds 100 ml/min and is even greater for skeletonized ITA and for an RA^{16,17}.

EVIDENCE AND RATIONALE FOR (TOTAL) ARTERIAL GRAFTING

One internal thoracic artery is better than none

Since 1986, it has been widely recognized that a left ITA to the LAD conferred superior long-term prognosis, with fewer subsequent cardiac events, hospital readmissions, reoperations, and better survival, linked to better left ITA to LAD patencies as compared to SVG patencies^{1,2,9,18}.

Additionally, using the left ITA in all patients under both elective and urgent circumstances, even in the elderly (though this lengthened the procedure) was associated with improved perioperative mortality in all patients as well. Leavitt, et al. found that in a cohort of almost 22,000 pa-

tients, operative mortality was 2.2% when the left ITA was used as opposed to 4.9% when only vein graft was used ($p < 0.001$). Left ITA grafts were protective across all patient ages, and disease subgroups¹⁹. In the large cohort (70,000 patients) studied by Baskett, et al., operative mortality was 1.5% when one or more arterial grafts were used compared to 6.9% for vein grafts only ($p < 0.001$)⁹.

Two internal thoracic artery grafts are better than one

Multiple studies from centers in different countries and continents have consistently reported, in large groups of patients, that two ITA grafts, particularly to the LAD and circumflex, were associated with even better long-term results (Table II)^{3,10,12,13,15,17,20-24}.

For bilateral ITA, 10-year survival is 87-90%. For single ITA, 10-year survival is 78-80%. Put alternatively, a patient with two ITA grafts (especially to the left side) has a 28% less chance of dying over 10 years compared to when only a single ITA is used (Fig. 1). These differences take 10 years or more to become apparent, and become progressively divergent with time (10-20 years postoperative). Use of bilateral ITA is also associated with a greater freedom from reoperation or re-intervention as compared to one ITA. Freedom from re-intervention at 10 years is 80% for bilateral ITA and 60% for single ITA, i.e. a 50% less chance of re-intervention over 10 years (Fig. 2). The magnitude of the difference becomes extremely important to patients who are less than 70 years old at the time of CABG.

Total arterial grafting maybe better still

Total arterial revascularization with the two ITA, or the addition of an RA(s) or RGEA to bilateral ITA, appears to confer an additional advantage. Thus far there are reported trends towards this. Total arterial

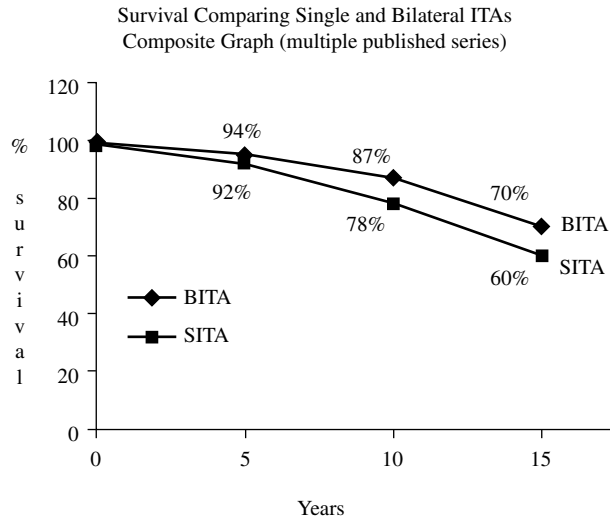


Figure 1. Composite survival graph from referenced studies, comparing bilateral internal thoracic artery graft patients (BITA) to single internal thoracic artery patients (SITA). Those with BITA have a 28% less chance of dying over 10 years.

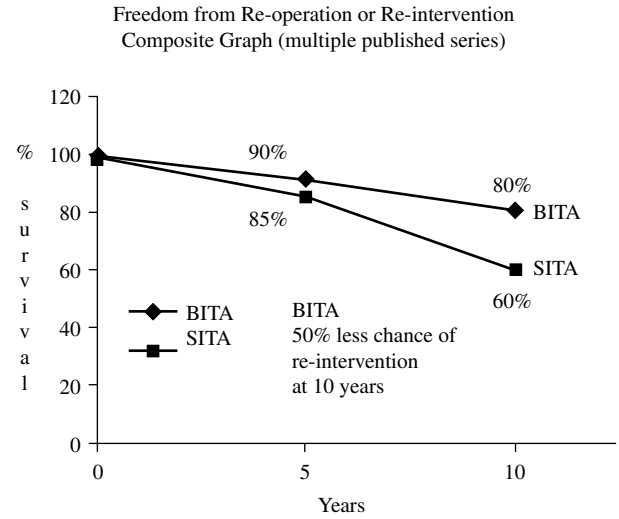


Figure 2. Composite graph from the referenced studies showing freedom from reoperation for patients having bilateral internal thoracic arteries (BITA) versus those with only a single internal thoracic artery (SITA). At 10 years, there is a 50% less chance of re-intervention for those having BITA.

TABLE II. RATIONALE/EVIDENCE FOR ARTERIAL GRAFTING: TWO INTERNAL THORACIC ARTERY GRAFTS ARE BETTER THAN ONE

Lytle, Sabik, et al.	Cleveland Clinic
Buxton, Tatoulis	Melbourne
Schaff, et al.	Mayo Clinic
Tector	Milwaukee
Barner	St Louis
Calafiore, et al.	Chieti/Milan
Dion	Brussels
Taggart	Oxford, UK
Steven, et al.	Montreal
Berrekouw	Netherlands

revascularization can be achieved with the same excellent perioperative results as for single ITA and bilateral ITA^{5,9,11,13,17,19,25}. In our Melbourne experience, perioperative mortality for total arterial revascularization was 0.7%⁵ and unadjusted survival was 92% at 10 years compared to 72% for those patients having only a left ITA plus vein graft (Fig. 3).

Arterial graft patencies are always better

Saphenous vein graft patencies are generally good in the short and intermediate term (90-95% at one month, 80-85% at 3-5 years). Patencies, however, decline as subendothelial and medial fibrotic and proliferative changes occur in the 3-5 year timeframe and are then followed by atherothrombotic changes, five years and beyond¹⁸ (Fig. 4).

Some optimism for better SVG patencies is present with the use of improved vein harvesting techniques, which include the perivascular tissues so that the vasa-vasorum are not interrupted, avoidance of distension

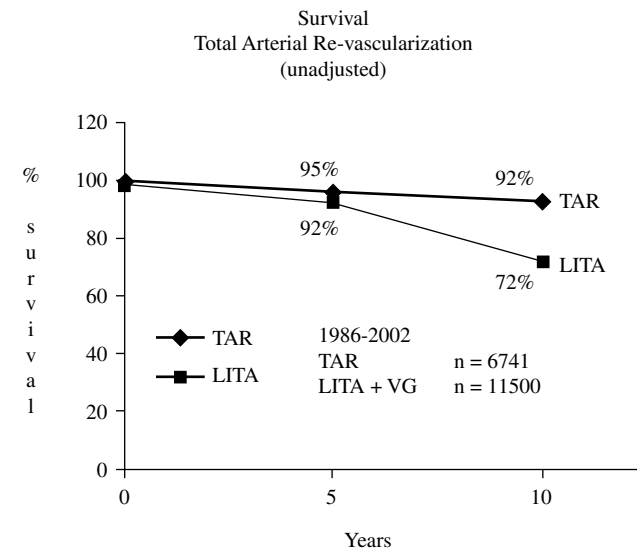


Figure 3. Unadjusted survival curves from the University of Melbourne experience 1986-2002. Comparing patients having total arterial revascularization (TAR) to those patients having a left internal thoracic artery (LITA) plus saphenous vein grafts (VG). An unadjusted 20% superior survival for total arterial revascularization at 10 years.

trauma, and aggressive use of statin anticholesterol drugs.

However, in all reports, arterial graft patencies are always superior to those of SVG at the same timeframes and in the same patients. This applies to even contemporary experiences. Importantly, patency results diverge and significantly advantage arterial grafts with time.

- Left ITA 90-95% patency at 10-20 years^{1,2,5,8,12,14,15,17,26,27}
- Right ITA 80-90% patency at 10 years

RA
VG

Figure 4. Angiograms, 10 years post-op in the same patient. Left panel shows atheromatous disease in a saphenous vein graft to the first circumflex marginal. Right panel shows a smooth aortocoronary radial artery graft to an inferior circumflex marginal. RA: radial artery; OM: obtuse marginal; VG: vein graft.

90-95% patency when used to LAD at 10 years^{8,12,14,15,17}

- RA 90% at 5 years, 80% at 10 years^{8,17,25,28-32}
- RGEA 90% at 5 years, 60% at 10 years³³
- SVG 70-80% at 5 years, 50% at 10 years, 30% at 15 years^{1,8,18,25,26}

Figure 5 shows graft patencies that have been amalgamated from the referenced publications.

In all angiograms, arterial grafts are smooth and do not show atheromatous and thrombotic changes (unlike SVG). Abnormalities in arterial grafts, when they occur, are confined to localized stenosis, string signs, or complete occlusions (Fig. 6).

Multiple arterial coronary artery bypass grafting is better than stents

Although periprocedural mortality and morbidity is similar to percutaneous coronary intervention/stents, CABG is superior within three years of follow-up, being more cost effective, with fewer major adverse cardiac events, fewer re-interventions, and better survival³⁴⁻³⁶.

Advantages in cardiac reoperations

The presence of an *in situ* functioning arterial graft, particularly the left ITA to LAD in a patient having a reoperation (for progression of coronary artery disease, graft failure, or development of interval aortic stenosis), confers a significant benefit in perioperative mortality and morbidity. Multiple reports from multiple centers with an aggregate of over 3,000 coronary reoperations

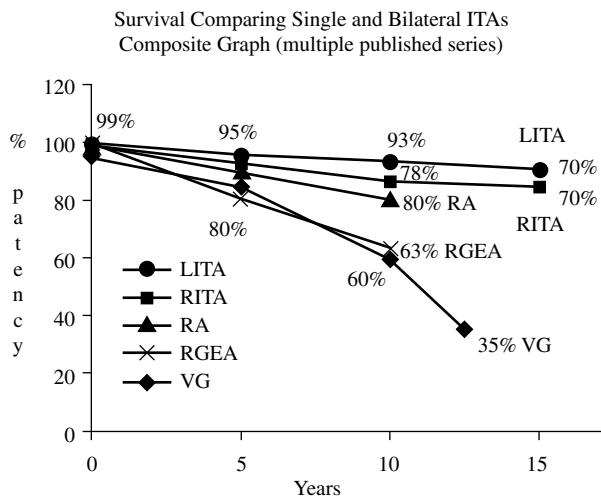


Figure 5. Composite graph, from the referenced papers, showing patency for different coronary conduits up to 15 years post-op. Left internal thoracic artery (LITA), right internal thoracic artery (RITA), radial artery (RA), right gastroepiploic artery (RGEA), saphenous vein graft (VG).

string sign
RA Graft

50%
Moderate stenosis
in Large RCA

Figure 6. The left panel shows the radial artery (RA) graft to be a string sign when it was grafted to a large dominant right coronary artery (RCA) with only a moderate 50% stenosis. Angiogram three years post-op.

show a benefit in operative mortality when arterial grafts are either previously present or used: a mean operative mortality of 1.9% for arterial grafts versus 5% when arterial grafts are not previously present nor used at the reoperation (Table III)³⁷.

As arterial grafts do not develop atherothrombotic disease, there is much less risk of distal coronary atheroembolism (which is often fatal) in the pre-bypass period or during subsequent cardiac mobilization (Fig. 7).

Additional and better conduits will be available at the reoperation. If the first operation was a left ITA/SVG procedure, then presumably the best SVG conduits were used. Hence, it would not be logical to use further SVG conduits as the original ones would have failed, leading to the reoperation, and the residual SVG would be the

TABLE III. OPERATIVE MORTALITY IN REOPERATIONS: ARTERIAL GRAFTS USED VS. VEIN GRAFTS

2.1 vs. 4.9%	(n = 1,663)	Lytle	JTCVS. 1994;107:675.
0.0 vs. 4.8%	(n = 189)	Christenson	Cardiovasc Surg. 1995;3:163.
2.3 vs. 5.0%	(n = 1,331)	Tatoulis	J Card Surg. 2004;19:296.
0.0 vs. 5.4%	(n = 59)	Cameron	Adv Cardiol. 1988;36:84.

RCA Vein Graft

Figure 7. A patent but diseased right coronary artery (RCA) vein graft. Intraoperative distal atheroembolism during cardiac mobilization resulted in acute inferior ischemia. Fortunately, this was reversed by retrograde flushing of the coronaries with retrograde cardioplegia and distal posterior descending artery coronary grafting.

least desirable. Alternatively, the right ITA (if appropriate) and one or both radial arteries could be available providing significant amounts of additional, new, good quality conduit³⁸.

The primary use of certain arterial grafts at reoperation may simplify the procedure and produce better results. The right ITA may be used to the right coronary system, either directly or as a composite extended graft using the RA. The RGEA may be used to the posterior descending artery³³, and an RA may be used from the descending thoracic aorta to the lateral wall of the heart via left thoracotomy³⁸. All these new arterial grafts can be placed in these reoperations using off-pump techniques, simplifying the reoperation and reducing perioperative mortality and morbidity (Fig. 8).

The use of arterial grafts has resulted in fewer reoperations. At 10 years post-op, those with a bilateral ITA have an approximate chance of a 20% re-intervention rate (2% per year), whereas those with a single ITA have a 40% chance of a re-intervention at 10 years (4% per year)^{10,21-24}. In our own experience, the rate of reoperations has reduced from 7% of our annual case load in 1990 to 1995, to < 3% of our case load per annum in 2005³⁸. It is acknowledged that SVG stenting and statins may have played a role; nevertheless, it also coincides with the application of widespread total arterial revascularization from 1995 onwards.

A further advantage is that the 10-year survival following a reoperation is superior (75-85%) when an ITA or arterial graft is used at the reoperation by comparison to when only vein graft is used (66-71%; $p = 0.004$)^{39,40}.

Other general advantages

Less infection

As legs and thighs are avoided (by not using SVG) the incidence of sternal infection and mediastinitis can be reduced.

Better healing

The forearms are well vascularized, muscular, with a minimum of subcutaneous adipose tissue, and heal well by comparison to thigh wounds or leg wounds, particularly in diabetic patients. Although SVG can be harvested by endoscopic techniques to reduce wound problems, they still have a limited application and the hardware is expensive.

Earlier ambulation

The avoidance of leg incisions enables patients, particularly the elderly, to ambulate and be discharged earlier^{25,30,38}.

Competitive flow for arterial grafts

This is the Achilles heel of arterial grafting, especially with RA and RGEA. For the ITA, native coronary artery stenosis should be at least 50% to avoid string signs^{8,26}. However, for the RA and RGEA, the native coronary artery stenosis should be at least 80% to ensure excellent long-term patency^{8,28-30,33}. When LAD stenosis was < 60%, left ITA patency was 92% compared to 97% when LAD stenosis was > 60% ($p = 0.008$). Radial artery patency was 83% when native coronary artery stenosis was < 80% compared to 92% when it was > 80% ($p = 0.04$)⁸.

One should avoid an SVG in the same system with a left ITA, without a 90% stenosis isolating the two grafts (e.g. left ITA to a 70% LAD, and a vein graft to a 70% diagonal). This may result in the larger SVG taking over the revascularization of both the diagonal and LAD territories with a subsequent string sign in the left ITA⁸.

Similarly, replacing a diseased but functioning SVG to the LAD at reoperation with a left ITA should be avoided unless:

- the left ITA is large with a free flow of > 100 ml/min
- there is a > 80% stenosis in the SVG

Posterior
descending
artery

Gastro-
epiploic
artery

Figure 8. Gastroepiploic artery brought anterior to the stomach through the diaphragm for anastomosis to the posterior descending artery can be performed on- or off-pump.

- or the diseased SVG is left *in situ* in addition to the new left ITA^{37,38,40}.

Radial artery, or RGEA to the circumflex, or right coronary artery/posterior descending artery should be avoided if the native coronary stenosis is < 80%^{8,17,25-30,32,33,41}.

Approach to a moderately stenosed (50-70%) large right coronary artery

There is no evidence that arterial grafts in this setting are important or that they will confer any particular benefit. Hence, a pragmatic approach is required:

- Large right coronary artery, < 80% stenosis. A bare metal stent for younger patients (< 70 years).
- Bare metal stent or SVG for older patients (> 70 years).
- Large right coronary artery, > 80% stenosis. Either a radial artery or an RGEA would be appropriate in younger patients and an SVG would be reasonable in older patients.

Y grafts and their limitations

Left ITA/right ITA, and left ITA/RA composite Y grafts are excellent approaches to off-pump coronary

surgery, so one can avoid proximal anastomoses to the aorta, particularly if it is atheromatous, and ensure efficient use of conduit^{17,25,29,38}.

Excellent results and patencies can be achieved when the left ITA is confined to the LAD, and the RA to the circumflex branches. Extending the reach of the Y RA to the posterior descending artery may result in inferior patencies (Fig. 9). Hence, unless there was a conduit shortage, a separate graft to the posterior descending artery is recommended^{8,41}.

Proximal arterial graft anastomoses to the aorta

Some are concerned that this may be a technical problem. In general, the proximal end of the right ITA and RA are of excellent size (3-4 mm) with a robust wall. The construction of the proximal anastomoses is no different to that of a SVG to aorta proximal anastomosis. In an experience of over 10,000 CABG, a vein patch-enhanced proximal anastomosis has only been required once. There is also concern that by constructing a free right ITA or an RA as an aorta to coronary conduit, it transposes these vessels from a third or fourth order branch to a first order branch, and the abrupt direct effects of arterial systolic pressure may induce a greater reactivity and medial proliferation and reduce patency. This has been shown not to be true. Radial artery patencies are identical and excellent whether they be in composite pedicled grafts, or aortocoronary grafts^{8,17,25,28-32}. Possati, et al. found in 90 patients with angiogram a mean of 105 months post-op, RA patency rates of 91.6 versus 97.5% for left ITA and 67% for SVG³¹. They also noted patent arterial grafts, including RA, were always smooth and free of any atheroma or intimal disease, even at 10 years post-op, unlike SVG. This has been reported by others^{8,17,25-31}. Typical angiograms of arterial grafts, all more than 10 years post-op, are shown in figure 10.

RECOMMENDED GRAFT STRATEGIES

Patients less than 70 years old

Left ITA to LAD. Free or *in situ* right ITA to circumflex obtuse marginal, RA to posterior descending artery.

Patients more than 70 years old

Left ITA to LAD, RA to circumflex obtuse marginal, RA or SVG to posterior descending artery (we have

Figure 9. A string sign in the terminal part of the radial artery as it passes from the inferior marginal to the posterior descending artery. The radial artery (RA) inflow is from the left internal thoracic artery (LITA). The right coronary artery and posterior descending vessels in this instance only had a 50% stenosis, hence resulting in competitive flow, and a string sign, by comparison to the occluded circumflex system.

preferred RA, i.e. a second RA to posterior descending artery). However RGEA to posterior descending artery for either group (providing tight native coronary stenosis) is most reasonable.

Total arterial grafting is readily feasible in over 80% of CABG (Fig. 11).

PRACTICAL TIPS

Right internal thoracic artery

In situ right ITA will only readily reach the right coronary artery up to the acute margin (even skeletonized). If one needs to go beyond this, particularly to beyond the crux, it is wiser to use the right ITA as a free graft.

The *in situ* right ITA, either anterior to the aorta or through the transverse sinus, will only readily reach the first circumflex marginal in most patients (even as a skeletonized graft). To go beyond this, the right ITA should be used as a free graft or as a Y graft from the left ITA.

The *in situ* right ITA should be passed behind the lobes of the thymus to protect from sternal infection or trauma.

The right internal thoracic vein should be divided, to prevent compression of the *in situ* right ITA.

Radial artery

An Allen's test or one of its modifications should always be performed prior to RA use. The RA should be

Figure 10. Angiograms of *in situ* right internal thoracic artery graft (RITA), free right internal thoracic artery graft (FRITA), used as a Y graft with a radial (RA) and radial artery grafts (RA). All angiograms are 10 or more years post-op. In all instances the patent grafts are smooth and free of any atheromatous or luminal disease.

avoided in patients with Raynaud's disease, scleroderma, or any other known collagen disease. Radial artery use should also be avoided if it is anticipated that there may be a requirement for high-dose vasopressors.

ARTERIAL GRAFTS ARE SUPERIOR TO DRUG-ELUTING STENTS

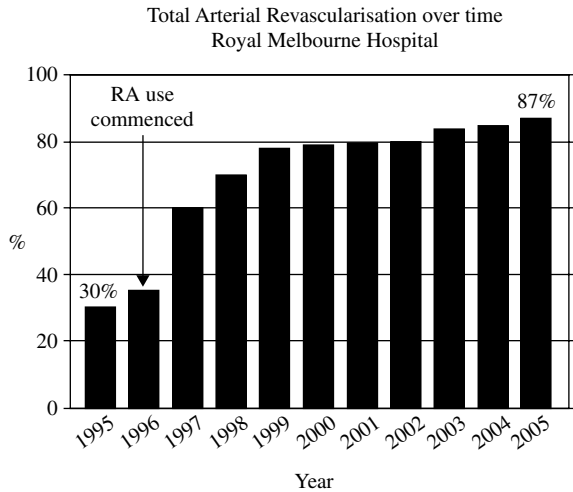
Arterial CABG produce equivalent short-term and superior mid-term (three years and beyond) outcomes with fewer major adverse cardiac events, fewer re-interventions, lower costs, and better survival³⁴⁻³⁶.

Importantly, two new complications associated with drug-eluting stents have become recognized.

First, the need for possible life-long clopidogrel. Acute thrombosis of the drug-eluting stent on withdrawal of clopidogrel occurs in 1-5% of cases and is associated with a 50% mortality⁴².

Second, coronary artery aneurysms associated with drug-eluting stents have also been recently reported, most likely due to the antimitotic effects of sirolimus and rapamycin, which inhibit smooth muscle cells and fibroblasts, resulting in a failure of vessel wall repair after balloon dilatation (Fig. 12).

The increasing awareness of the limitations and problems associated with drug-eluting stents, and the greater awareness of informed patient consent afford a window of opportunity, in multi-vessel coronary disease, to establish the superiority of CABG, particularly by using multiple or total arterial grafting.



2 or more Arterial Grafts can be achieved in > 80% of cases

Figure 11. The incidence of total arterial revascularization in isolated coronary artery surgery at the Royal Melbourne Hospital, University of Melbourne for the decade 1995 to 2005.

CONCLUSIONS

Coronary artery bypass grafting with multiple or total arterial grafting has a perioperative mortality and morbidity similar to or better than left ITA to LAD and SVG to others. The patencies of arterial grafts are superior at 10 years and beyond. There is less recurrent angina, cardiac events, myocardial infarctions, hospitalizations, and coronary re-interventions, and long-term survival is superior. Multiple arterial revascularization is a powerful technique to compete with and trump angioplasty and stenting in patients with multi-vessel coronary disease.

REFERENCES

1. Loop FD, Lytle BW, Cosgrove DM, et al. Influence of the internal mammary-artery graft on 10 year survival and other cardiac events. *N Eng J Med.* 1986;314:1-6.
2. Cameron A, Davis KB, Green G, Schaff HV. Coronary bypass surgery with ITA grafts – effects on survival over a 15 year period. *N Eng J Med.* 1996;334:216-9.
3. Taggart DP, D'Amico R, Altman DG. Effect of arterial revascularization on survival: a systemic review of studies comparing bilateral and single internal mammary arteries. *Lancet.* 2001;358:870.
4. He GW. Arterial grafts for coronary surgery: Vasospasm and patency rates. *J Thorac Cardiovasc Surg.* 2001;121:431-3.
5. Tatoulis J, Buxton BF, Fuller JA, Royse AG. Total arterial coronary revascularization: techniques and results in 3,220 patients. *Ann Thorac Surg.* 1999;68:2093-9.
6. Mussa S, Guzik TJ, Black E, Dipp MA, Channon KM, Taggart DP. Comparative efficacies and durations of action of phenoxylbenzamine, verapamil/nitroglycerine solution, and papaverine as topical antispasmodics for radial artery coronary bypass grafting. *J Thorac Cardiovasc Surg.* 2003;126:1798-805.
7. Mills NL. Preparation of the internal mammary artery graft with intraluminal papaverine. *J Card Surg.* 1991;6:318.

Figure 12. Aneurysms in the left anterior descending artery following angioplasty, and drug-eluting stent deployment, in two separate patients, two and three years post-stenting.

8. Tatoulis J, Buxton BF, Fuller JA. Patencies of 2,127 arterial to coronary conduits over 15 years. *Ann Thorac Surg.* 2004; 77:93-101.
9. Baskett RJF, Cafferty FH, Powell SJ, Kinsman R, Keogh BE, Nashef SAM. Total arterial revascularization is safe: Multi-center 10 year analysis of 71,470 coronary procedures. *Ann Thorac Surg.* 2006;81:1243-8.
10. Buxton BF, Komeda M, Fuller J. Bilateral ITA grafting may improve late outcome of coronary artery surgery. *Circulation.* 1998;98(Suppl):III-6.
11. Lev-Ran O, Mohr R, Pevni D, et al. Bilateral ITA grafting in diabetic patients: Short-term and long-term results in a 515 patient series. *J Thorac Cardiovasc Surg.* 2004;127:1145-50.
12. Tatoulis J, Buxton BF, Fuller JA. Results of 1545 free right ITA-to-coronary artery grafts. *Ann Thorac Surg.* 1997;64:1263-9.
13. Tector AJ, McDonald ML, Kress DC, et al. Purely internal thoracic artery grafts: outcomes. *Ann Thorac Surg.* 2001; 72:450.
14. Loop FD, Lytle BW, Cosgrove DM, et al. Free (aorta-coronary) internal mammary artery graft: late results. *J Thorac Cardiovasc Surg.* 1986;92:827.
15. Buxton BF, Ruengsakulrach P, Fuller JA, Rosalian A, Reid CM, Tatoulis J. The right ITA graft – benefits of grafting the left coronary system and native vessels with a high grade stenosis. *Eur J Cardiothorac Surg.* 2000;18:255-61.
16. Choi JB, Lee SY. Skeletonized and pedicled ITA grafts: Effect on free flow during bypass. *Ann Thorac Surg.* 1996;61: 909-13.
17. Calafiore AM, Di Mauro M, D'Alessandro S, et al. Revascularization of the lateral wall: long-term angiographic and clinical results of radial artery versus right ITA grafting. *J Thorac Cardiovasc Surg.* 2002;123:225.
18. Campeau L, Enjalbert M, Lesperance J, et al. The relation of risk factors to the development of atherosclerosis in saphenous-vein bypass grafts and the progression of disease in the native circulation: a study 10 years after aortocoronary bypass surgery. *N Eng J Med.* 1984;311:1329.
19. Leavitt BJ, O'Connor GT, Olmstead EM, et al. Use of the internal mammary artery graft and in-hospital mortality and other adverse outcomes associated with coronary artery bypass surgery. *Circulation.* 2001;103:507.
20. Berreklouw E, Rademakers PP, Koster JM et al. Better ischemic event-free survival after two ITA grafts: 13 years follow-up. *Ann Thorac Surg.* 2001;72:1535.

21. Pick AW, Orszulak TA, Anderson BJ, Schaff HV. Single versus bilateral internal mammary artery grafts: 10 year outcome analysis. *Ann Thorac Surg.* 1997;64:599-605.
22. Schmidt, SE, Jones JW, Thornby JI, Miller CC, Beal AC. Improved survival with multiple left sided bilateral ITA grafts. *Ann Thorac Surg.* 1997;64:9-15.
23. Lytle BW, Blackstone EH, Sabik JF, Houghtaling P, Loop FD, Cosgrove DM. The effect of bilateral ITA grafting on survival during 20 postoperative years. *Ann Thorac Surg.* 2004;78:2005-14.
24. Christenson JT, Vlebit V, Maurice J, et al. Risks, benefits, and results of reoperative coronary surgery with internal mammary grafts. *Cardiovasc Surg.* 1995;3:163-9.
25. Verma S, Szmítko PE, Weisel RD, et al. Should radial arteries be used routinely for coronary artery bypass grafting? *Circulation.* 2004;110:e40-6.
26. Sabik JF, Lytle BW, Blackstone EH, et al. Comparison of SVG and ITA graft patency by coronary system. *Ann Thorac Surg.* 2005;79:544-51.
27. Barner HB, Barnett M. Fifteen to 21 year angiographic assessment of ITA as a bypass conduit. *Ann Thorac Surg.* 1994;57:1526.
28. Acar C, Ramsheyi A, Pagny JY, et al. The radial artery for coronary artery bypass grafting: clinical and angiographic results at five years. *J Thorac Cardiovasc Surg.* 1998;116:981.
29. Iaco AL, Teodori G, Di Giammarco G, et al. Radial artery myocardial revascularization: long-term clinical and angiographic results. *Ann Thorac Surg.* 2001;72:464.
30. Tatoulis J, Roysse AG, Buxton BF, et al. The radial artery in coronary surgery: A 5 year experience – clinical and angiographic results. *Ann Thorac Surg.* 2002;73:143-8.
31. Possati G, Gaudino M, Prati F, et al. Long-term results of radial artery use for myocardial revascularization. *Circulation.* 2003;108:1350-4.
32. Zacharias A, Habib RH, Schwann TA, et al. Improved survival with radial artery versus vein conduits in coronary bypass surgery with left ITA to left anterior descending artery grafting. *Circulation.* 2004;109:1489-96.
33. Suma H, Isomura T, Horii T, Sato T. Late angiographic result of using the RGEA as a graft. *J Thorac Cardiovasc Surg.* 2000;120:496-8.
34. Taggart DP. Coronary artery bypass grafting is still the best treatment for multi-vessel and left main disease, that patients need to know. *Ann Thorac Surg.* 2006;82:1966-75.
35. Guyton RA. Coronary artery bypass is superior to drug-eluting stents in multivessel coronary artery disease – Editorial review. *Ann Thorac Surg.* 2006;81:1949-57.
36. Smith PK, Califf RM, Tuttle RH, et al. Selection of surgical or percutaneous coronary intervention provides differential longevity benefit. *Ann Thorac Surg.* 2006;82:1420-9.
37. Lytle BW, McElroy D, McCarthy PM, et al. The influence of arterial coronary bypass grafts on the mortality of coronary re-operations. *J Thorac Cardiovasc Surg.* 1994;107:675-84.
38. Tatoulis J, Buxton BF, Fuller JA. The radial artery in reoperative coronary bypass surgery: A 5-year experience. *J Card Surg.* 2004;19:296-302.
39. Dougenis D, Brown AH. Long-term results of reoperations for recurrent angina with internal mammary artery versus SVG. *Heart.* 1998;80:9-13.
40. Loop FD, Lytle BW, Cosgrove DM, et al. Reoperation for coronary atherosclerosis: Change in practice in 2,509 consecutive patients. *Ann Surg.* 1990;212:378-86.
41. Maniar HS, Sundt TM III, Barner HB. Effect of target stenosis and location on radial artery graft patency. *J Thorac Cardiovasc Surg.* 2002;123:45-52.
42. Iakovou I, Schmidt T, Bonizzoni E, et al. Incidence, predictors, and outcomes of thrombosis after successful implantation of drug eluting stents. *JAMA.* 2005;293:2126-30.