

IMAGE IN CARDIOLOGY

Infective endocarditis and caseous calcification of the mitral annulus: The odd couple

Esmeralda Capín, Diego León, María Luisa Rodríguez, Cecilia Corros, Ana García-Campos, Jesús de la Hera, María Martín*

Unidad de Imagen, Área del Corazón, Hospital Universitario Central de Asturias, Oviedo, Asturias, Spain

Received 21 August 2013; accepted 16 December 2013

KEYWORDS

Caseous calcification of the mitral annulus;
Endocarditis;
3D echocardiography

PALABRAS CLAVE

Calcificación caseosa del anillo mitral;
Endocarditis;
Ecocardiograma 3D

Abstract Caseous calcification of the mitral annulus is an infrequent echocardiographic finding. The differential diagnosis includes other entities like tumors, abscess or thrombus. Both cardiac CT and cardiac MRI may be useful for its definitive diagnosis.

© 2013 Instituto Nacional de Cardiología Ignacio Chávez. Published by Masson Doyma México S.A. All rights reserved.

La endocarditis infecciosa y la calcificación caseosa del anillo mitral: la extraña pareja

Resumen La calcificación caseosa del anillo mitral es un hallazgo ecocardiográfico poco frecuente. Debe hacerse el diagnóstico diferencial con otras entidades tales como tumores, abscesos o trombos. Para su diagnóstico definitivo además del ecocardiograma tanto el TC cardiaco como la Cardio RM pueden ser de utilidad.

© 2013 Instituto Nacional de Cardiología Ignacio Chávez. Publicado por Masson Doyma México S.A. Todos los derechos reservados.

A 69-year-old woman with morbid obesity and positive blood cultures for *Streptococcus agalactiae* was subjected to echocardiographic analysis. It revealed a caseous calcification (CC) of the mitral annulus and mobile images attached to it. Transesophageal study confirmed endocarditis without

mitral regurgitation (Fig. 1A–D). Antibiotic treatment was successful.

CC occurs in less than 0.07% of patients who undergo echocardiography. It can be misdiagnosed with other entities such as tumors and thrombus in cases like the one we report, it can be also misdiagnosed with an abscess. Other techniques such as cardiac CT or MRI are very useful to confirm this rare diagnosis; in our patient, morbid obesity prevented the use of further diagnostic tools.^{1,2}

* Corresponding author at: Av. Julián Clavería s/n, 33006 Oviedo, Asturias, Spain. Tel.: +34 985108000-36173.

E-mail address: mmartinf7@hotmail.com (M. Martín).

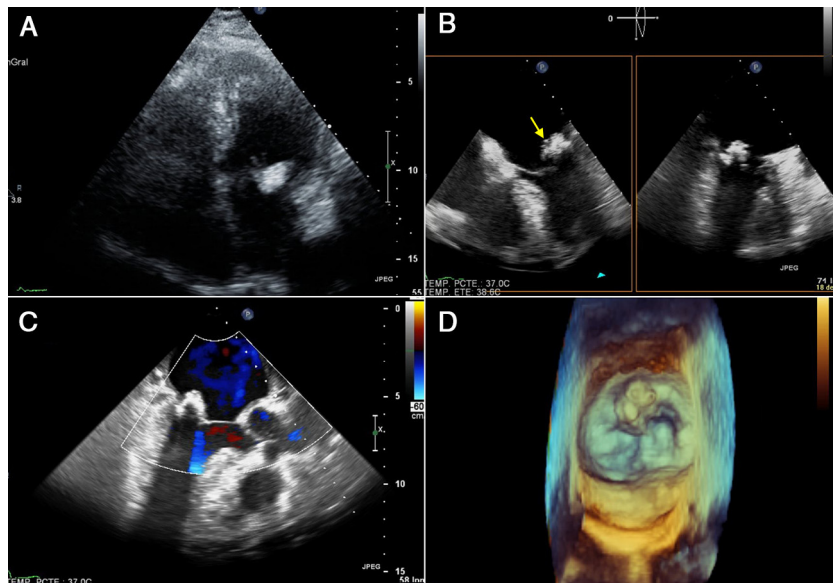


Figure 1 (A) Transthoracic echocardiogram showing a 2.5 cm × 1.5 cm echolucent, crescent-shaped, semilunar mass in the posterior mitral annulus. Caseous calcification of the mitral valve was diagnosed. (B) Transesophageal echocardiogram showing mobile images attached to the mitral annulus (arrow). (C) Transesophageal echocardiogram color Doppler without mitral regurgitation. (D) 3D images showing the CC of the annulus and the vegetations. Differential diagnosis with an abscess was fundamental as treatment would have been completely different (medical treatment vs. surgery).

Funding

There was no funding for this job.

Conflict of interests

Authors do not have any conflict of interests.

References

1. Wynn GJ, Ruthven S, Fabri BM, Chenzbraun A. Caseous calcification of the anterior mitral leaflet: an unusual presentation of a rare pathology-role of 3D TEE. *Eur Heart J Cardiovasc Imaging*. 2012;13:624.
2. Ribeiro S, Salgado A, Salomé N, et al. Critical multi-organ emboli originating from collapsed, vulnerable caseous mitral annular calcification. *Rev Port Cardiol*. 2012;31:313–6.