

Mientras que los anillos incompletos asintomáticos pueden mantenerse bajo vigilancia<sup>9,10</sup>.

La asociación de RTS y anillo vascular completo es poco frecuente. Es importante que ante la sospecha de anomalías cromosómicas los pacientes sean valorados por el cardiólogo pediatra para su diagnóstico. Las técnicas de imagen no invasivas son de ayuda para la delimitación de la anatomía precisa y la planificación quirúrgica.

## Bibliografía

- Allanson JE. Síndrome de Rubinstein-Taybi: la cara cambiante. *Am J Med Genet Suppl.* 1990;6:38-41.
- Stevens CA, Bhakta MG. Cardiac abnormalities in the Rubinstein-Taybi syndrome. *Am J Med Genet.* 1995;59:346-8.
- Magillo P, della Rocca M, Ricardo Campus R, et al. Congenital tracheal stenosis in a boy with Rubinstein-Taybi syndrome. *Can J Anesth.* 2005;52:990-1.
- Shashi V, Fryburg JS. Vascular ring leading to tracheoesophageal compression in patient with Rubinstein-Taybi syndrome. *Clin Genet.* 1995;48:324-7.
- Doff B, McElhinney, Bernard J, et al. Association of chromosome 22q11 deletion with isolated anomalies of aortic arch laterality and branching. *J Am Coll Cardiol.* 2001;37:2114-9.
- Tuo G, Volpe P, Bava GL, et al. Prenatal diagnosis and outcome of isolated vascular rings. *Am J Cardiol.* 2009;103:416-9.
- Stojanovska J, Cascade PN, Chong S, et al. Embryology and imaging review of aortic arch anomalies. *J8 Thorac Imaging.* 2012;27:73-84.
- Kir M, Saylam GS, Karadas U, et al. Vascular rings: Presentation, imaging strategies, treatment and outcome. *Pediatr Cardiol.* 2012;33:607-17.
- Vázquez Antona CA, Muñoz Castellanos L, Kuri-Nivón M, et al. Anillo vascular por doble arco aórtico simétrico. Reporte de un caso. *Arch Cardiol Méx.* 2005;75:178-2181.
- Kussman BD, Geva T, McGowan FX. Cardiovascular causes of airway compression. *Pediatr Anesth.* 2004;14:60-74.

Claudia Fariás-Serratos<sup>a,\*</sup>, Luis García-Guereta<sup>b</sup>,  
Montserrat Bret-Zurita<sup>c</sup> y Federico Gutiérrez-Larraya<sup>b</sup>

<sup>a</sup> *Departamento de Cardiología Pediátrica, Hospital Regional de Alta Especialidad del Bajío, León, Guanajuato, México*

<sup>b</sup> *Departamento de Cardiología Pediátrica, Hospital Universitario La Paz, Madrid, España*

<sup>c</sup> *Departamento de Resonancia Magnética, Hospital Universitario La Paz, Madrid, España*

\* Autor para correspondencia: Blvd. Milenio n.º 130, San Carlos la Roncha. CP 37660. León, Guanajuato, México.  
Teléfono: +477 267 2000, ext 1366.  
Correo electrónico: [claudiafaser@live.com.mx](mailto:claudiafaser@live.com.mx)  
(C. Fariás-Serratos).

<http://dx.doi.org/10.1016/j.acmx.2013.09.003>

## Electrophysiological interventions without using femoral approach

### Estudios electrofisiológicos invasivos sin usar el abordaje femoral

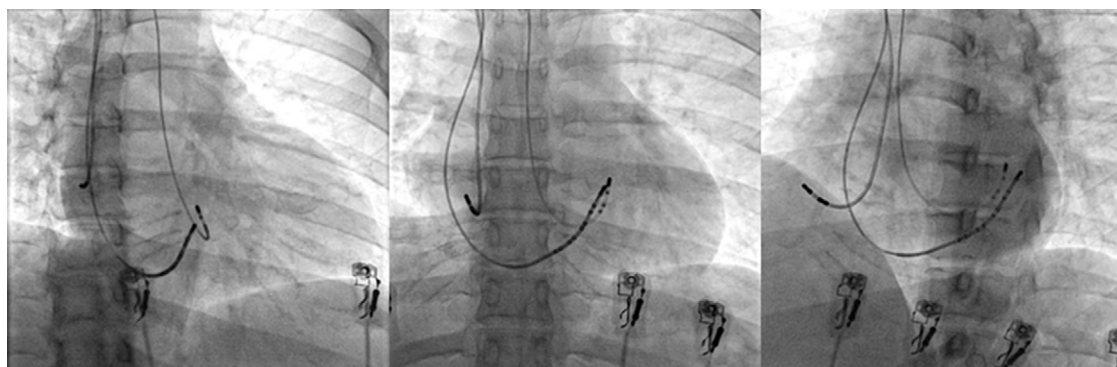
Dear Editor,

In cardiology, the current trend regarding invasive procedures is to maximize patients' comfort without compromising their safety. This is the reason why, in some centers, radial artery puncture is the preferred approach for both coronary angiogram and angioplasty procedures as opposed to femoral access, due to fewer rates of complications.<sup>1</sup> While performing electrophysiology (EP) procedures we often saw ourselves in the need to use several catheters in order to demonstrate the different pathways involved in the development of a tachycardia. However, nowadays this is not necessary for the vast majority of simple EP procedures. Others groups and we believed that with one or at most three catheters is enough to perform basic EP studies as well as ablations,<sup>2,3</sup> allowing us to explore other vascular approaches instead of the traditional femoral access (Fig. 1). The latter could represent a practical alternative especially in patients in whom the femoral access is hard to find due to a variety of conditions such as obesity, tortuosity or vein occlusion, thereby allowing the patient to move soon after the surgery rather than lying in bed for a long period of time. The jugular and subclavian approaches had been suggested

as alternative means to ablate anteroseptal accessory pathways, for both first intervention or recurrences.<sup>4-6</sup> Also by using these alternative accesses we can achieve an ambulatory EP procedure discharging the patient just a few hours later, without the need to wait until the next day. Here we describe a case series by systematically using alternative vascular accesses instead of the traditional femoral approach with some novel technical improvements including AV nodal re-entry tachycardia (AVNRT) ablation, which to our knowledge has not been reported previously.

### Case series

During a 4 month period (from October 2012 to February 2013), 30 patients sent to our center for simple electrophysiological procedures such as: electrophysiological studies (EP), AV nodal ablation or supraventricular tachycardias (SVT) ablation with the exception of typical atrial flutter, were included prospectively and consecutively. Complex arrhythmias such as atrial fibrillation, atypical atrial flutter or ventricular tachycardia, were excluded. Informed consent was obtained from all patients. In order to get vein access, we performed one or two subclavian vein punctures, in the same site, using a 6 and 7 Fr introducer sheath for diagnostic and also therapeutic catheters respectively. Artery access was achieved by puncturing the radial artery with a special 6 Fr introducer sheath (Terumo Co.). Once the artery patency was assured and the sheath introduced, we administered 2.5 mg of verapamil once or twice depending



**Figure 1** Projections of RAO, PA and LAO in one patient with three catheters, a radial artery approach and two subclavian right punctures. RAO, right anterioroblique; PA, posteroanterior; LAO, left anterior oblique.

on the presence of vasospasm, and then switch for a 7 Fr conventional sheath. After that, 5000 U of non-fractionated I.V. heparin were administered. All ablations were performed with a red, blue or orange curve 4 mm tip ablation catheter (Biosense Webster Co.).

## Results

Thirty procedures (6 EP studies and 24 ablations) were completed (Table 1). Patient's mean age was  $39 \pm 15$  years, 60% (18 patients) were males; 5 EP studies were for TV induction in patients with dilated cardiomyopathy after transradial angiography, using only one deflectable diagnostic catheter through the radial artery. The remaining EP study was for treatment of symptomatic non-documented palpitations; in this case, we used 2 catheters through the subclavian vein approach. The ablations were performed to 13 patients with Wolff–Parkinson–White (WPW) syndrome (7 from right and 6 from left origin); 5 patients with a concealed accessory (CA) pathway (1 from right and 4 from left origin); 3 patients with AVNRT and 3 patients with AV nodal ablation for rate control because permanent AF. In those patients with left accessory pathway (10 patients) we used 3 catheters, in 11 patients we used 2 catheters and in 9 patients we used 1 catheter; for the ablation of the left tachycardias we used 3 catheters, for the ablation of right tachycardias we used 2 vein punctures for 2 catheters; also for the EP study we used 2 catheters, and finally we

used 1 catheter for ventricular stimulations taking advantage of the prior radial artery puncture for the coronary angiogram. All the ablations were successfully done during the first procedure. Only one patient with a WPW syndrome and Ebstein's anomaly presented an early recurrence within the first 24 h after successful ablation. We performed the study again, this time through the femoral access using an irrigated tip catheter. After this second intervention the patient had again an early recurrence, which suggests that regardless of the approach used, this was a very difficult case. The mean follow up was  $108 \pm 34$  days and until now there has not been early or late complications in the subclavian or radial puncture sites. Because there was no previous experience in our center with the use of 7 Fr transradial catheters for EP procedures, in the first 5 cases we followed up the radial punctures with arterial Doppler, but thereafter this was not necessary due to the good evolution and the difficulty that represented the follow-up of all patients with this procedure in our center (data not shown). The mean fluoroscopy time was  $27 \pm 23$  min, and the procedure duration was  $128 \pm 69$  min. There was no significant difference in the duration of our procedures in comparison with the traditional transfemoral ones.

## Discussion

The alternative vascular accesses without using the traditional femoral approach are not a novel procedure.

**Table 1** The relationship of the 30 procedures, including diagnosis, time of fluoroscopy, procedure, outcome and follow up.

Procedure	n	Catheters	Fluoroscopic time	Procedure time	Acute success	Early recurrency	Complications	Follow up (days)
EP studies	6	1	$10 \pm 6$	$96 \pm 45$	6	0	0	$137 \pm 29$
WPW								
Right	7	2	$27 \pm 24$	$152 \pm 67$	7	1	0	$99 \pm 39$
Left	6	3	$25 \pm 31$	$125 \pm 80$	6	0	0	$115 \pm 24$
AP concealed								
Right	1	2	68	240	1	0	0	107
Left	4	3	$30 \pm 17$	$151 \pm 25$	4	0	0	$114 \pm 37$
AVNRT	3	2	$42 \pm 19$	$160 \pm 34$	3	0	0	$85 \pm 27$
AV nodal ablation	3	1	$7 \pm 6.2$	$46 \pm 5$	5	0	0	$97 \pm 50$

There are few communications that have reported jugular or subclavian accesses to perform anteroseptal right accessory pathway ablations<sup>6,7</sup> and there are some case reports and systematical ablations of left accessory pathways through transradial artery puncture.<sup>8-10</sup> The novelty in our study is that we performed all consecutive EP procedures employing these alternative vascular approaches at all times, including the first AVNR tachycardias and right posteroseptal accessory pathways reported with acute success and without complications. Also we used a 7Fr ablation catheter in all radial procedures, which has been described before but it is not the usual size used due to a possible risk of vasospasm (we did not encounter this complication in our series). The main reason why we decided to find an alternative vascular approach instead of the traditional femoral one is because we wanted to keep the patient's comfort, allowing an early movement; only a few hours after the procedure instead of lying in bed feeling such discomfort this is also the reason why the radial artery via is increasingly used for coronary procedures with excellent outcome. The subclavian vein via is widely used for pacemaker implantation and also it has been reported as an alternative way in those cases with WPW syndrome with an anteroseptal or midseptal right ventricular pathways;<sup>5</sup> we choose to use this approach and not the jugular one because we are more accustomed to this via, due to our experience with pacemaker implantations.

In our study no complications in the artery or vein punctures occurred. In the first 5 cases of radial artery puncture patients were followed up with Doppler, but this was not necessary in subsequent procedures due to the good outcome; up to 3% of complications in femoral puncture has been reported, that includes thrombosis, fistula and hematomas<sup>1</sup>; we are not excluding the possibility of vascular complications in this alternative approach but, such complications would be the same regardless of the approach used, and probably less for not using the femoral access.<sup>9,10</sup>

We are aware that with every new technique there is a need for a learning curve, but once it has been reached, the procedures are as easy as the standard technique employed without significantly increasing fluoroscopic or procedure times. In the near future we may use this alternative approach in order to avoid unnecessary and uncomfortable bed rest in those patients with mild or high risk of venous thrombosis; and perhaps we could perform simple EP procedures on an outpatient basis. Nowadays a cardiac electrophysiologist must be trained with the newest techniques available, including transeptal and epicardial puncture or all other available alternatives, in order to perform and securely resolve complex problems for the best interest and outcome of our patients.

Our results demonstrate an alternative approach that is as safe as the customary one for performing simple EP studies and ablations with good acute success rates and without complications.

## Funding

There was no funding for this job.

## Conflicts of interest

The authors do not have any conflicts of interest.

## Acknowledgements

To the fellows and the people who work in the Department of Electrophysiology and Hemodynamic in the CMN 20 de Noviembre for their support.

## Bibliografía

1. Jang JS, Jin HY, Seo JS, et al. The transradial vs the transfemoral approach for primary percutaneous coronary intervention in patients with acute myocardial infarction: a systematic review and meta-analysis. *Eurointervention*. 2012;8:501-10.
2. Femenia F, Arce M, Arrieta M, et al. Long-term results of slow pathway ablation in patients with atrioventricular nodal reentrant tachycardia: simple approach. *J Electrocardiol*. 2012;45:203-8.
3. Femenia F, Sarquella-Brugada G, Brugada J. Single catheter radiofrequency ablation of a permanent junctional reciprocating tachycardia in a premature neonate. *Cardiol Young*. 2012:1-4.
4. Mandapati R, Berul CI, Tiredman JK, et al. Radiofrequency catheter ablation of septal accessory pathways in the pediatric group. *Am J Cardiol*. 2003;92:947-50.
5. Sacher F, Wright M, Tedrow UB. Wolff-Parkinson-White ablation after prior failure: 7 year multicentre experience. *Europace*. 2010;12:835-41.
6. DiLorenzo MP, Pass RH, Nappo L, et al. Ablating the anteroseptal accessory pathway ablation via the right internal jugular vein may improve safety and efficacy. *J Interv Card Electrophysiol*. 2012;35:293-9.
7. Ibarra-Castillo R, Amores-Arellano N. Radiofrequency ablation of a left free wall accessory pathway by transradial approach. *Arch Cardiol Mex*. 2012;82:131-4.
8. Jiang H, Zhang M, He B, et al. New access for radiofrequency catheter ablation of left sided atrioventricular accessory pathways—safety and efficacy of the transradial approach. *Circ J*. 2009;73:833-7.
9. Ferreira E, Santiago G, Santiago Filho G. Ablación por radiofrecuencia a través de la técnica transradial: una nueva opción de acceso en la ablación de vías anómalas izquierdas. *Relampa*. 2009;22:258.
10. He B, Jiang H, Lu Z, et al. Feasibility and safety of transradial approach for catheter ablation of idiopathic left ventricular tachycardia. *Clin Res Cardiol*. 2011;100:37-43.

Martín Ortiz-Ávalos, Gerardo Rodríguez-Diez\*, Mauricio Cortés, Marco Alcántara-Meléndez, Rogelio Robledo-Nolasco

*Department of Electrophysiology and Hemodynamic, Centro Médico Nacional 20 de Noviembre, ISSSTE, México DF, Mexico*

\*Corresponding author at: Félix Cuevas # 540, Colonia del Valle, Delegación Benito Juárez, C.P. 03229, México DF, Mexico.

*E-mail addresses:* [gerardorodriguezdiez@yahoo.com.mx](mailto:gerardorodriguezdiez@yahoo.com.mx), [gerardorodriguezdiez@icloud.com](mailto:gerardorodriguezdiez@icloud.com) (G. Rodríguez-Diez).

<http://dx.doi.org/10.1016/j.acmx.2013.12.004>