

Roser Querol Ripoll^{a,*}, Rosa Cámara Gómez^a,
Maribel del Olmo García^a, Juan Antonio Simal Julián^b
y Juan Francisco Merino Torres^a

^a Servicio de Endocrinología y Nutrición, Hospital
Universitario y Politécnico La Fe, Valencia, España

^b Servicio de Neurocirugía, Hospital Universitario y
Politécnico La Fe, Valencia, España

* Autor para correspondencia.
Correo electrónico: Roserquerol86@gmail.com
(R. Querol Ripoll).

<http://dx.doi.org/10.1016/j.endonu.2015.01.007>

18F-DOPA vs. 18F-FDG PET/CT in the ectopic ACTH syndrome due to pulmonary carcinoid tumor



18F-DOPA vs. 18F-FDG PET/CT en el síndrome de producción ectópica de ACTH por tumor carcinóide pulmonar

Overproduction of corticotropin by the pituitary gland or extrapituitary tumors leads to ACTH-dependent Cushing's syndrome; 10% of these are due to ectopic production. These tumors often suppose a difficult diagnostic challenge because of their small size and multiplicity.

The pulmonary neuroendocrine-tumors (NET) originate from the enterochromaffin-cells which are diffusely distributed in the body. Their incidence has increased significantly in recent decades due to the available diagnostic resources; they represent about 1–2% of all lung tumors and 20–30% of all NET.¹

6-Fluoro-(18F)-L-3,4-dihydroxyphenylalanine (18F-DOPA) is an aminoacid-analog for positron emission-tomography (PET) imaging which has been registered since 2006 in several European Union countries and by several pharmaceutical firms. NET imaging is part of its registered indications.

18F-DOPA offers distinct advantage over fluorodeoxyglucose (18F-FDG) for the detection of carcinoids especially since many of these tumors are indolent with low proliferation activity and good differentiation. Furthermore, 18F-DOPA was able to detect more lesions, more positive regions, and more lesions per region than combined somatostatin receptor scintigraphy (SRS) and CT.²

We present the case of a 33-years-old male with a history of ACTH-dependent Cushing's syndrome. Dynamic testing of hypothalamo-pituitary-adrenal axis and high levels of ACTH (131 pg/ml) led to diagnosis of ectopic ACTH secretion. Chest X-ray showed a solitary pulmonary nodule in the anterior-segment of the right-upper-lobe. First PET/CT was performed after injection of 259 MBq of 18F-FDG, and revealed a pulmonary nodule located in the right-upper-lobe (Fig. 1a). The maximum standardized uptake value (SUVmax) measured was 1.9. Furthermore, a second pleural-based pulmonary nodule was observed in the left-upper-lobe with SUVmax 10.3 (Fig. 1b). According to these findings, contralateral or pleural involvement could not be dismissed. In order to better characterize the areas of increased radiopharmaceutical uptake, the patient underwent an 18F-DOPA-PET/CT after the injection of 233 MBq of radio-tracer, which revealed a solitary pulmonary node in the

right-upper-lobe (Fig. 1d) with SUVmax 1.1. 18F-DOPA-PET/CT allowed discarding the contralateral and pleural involvement (Fig. 1e).

An atypical resection of the left-upper-nodule was performed by minithoracotomy approach. Lobectomy was discouraged after histopathology revealed alveolar hemorrhage, organizing pneumonia and areas of necrotizing granulomatous inflammation. Right-upper-lobectomy including video-assisted mediastinal lymphadenectomy was performed at a second time. Histology demonstrated a low grade well-differentiated ACTH-producing pulmonary NET with low mitotic and proliferative indices (<2 mitoses per 10 high power fields and Ki67 <1%, respectively), chromogranin/sinaptophysin/CD56 and ACTH positive; TTF1 negative; pT1aN2 stage according to TNM classification. Only 1/8 mediastinal lymph nodes were affected.

The patient recovered rapidly, with normalization of serum ACTH levels. The symptoms of hypercortisolism were resolved 6 months after lobectomy.

Functional imaging based on radiolabeled-analogs targeting overexpressed receptors and transporters is playing a pivotal role in imaging of cancer. SRS, (123I)-metaiodobenzylguanidine (MIBG) scintigraphy and 18F-FDG-PET/CT remain the 3 molecular imaging techniques most widely available and with the most comprehensive clinical experience for NET.³

Published results indicated that 18F-FDG-PET/CT could be valuable for selecting treatment, monitoring therapy and determining prognosis, especially in poorly differentiated NET.⁴ On the other hand, 18F-DOPA has been used for PET imaging in humans for more than two decades, initially for Parkinson's syndrome, and later in oncology for brain tumors or NET; it has proved to be an excellent tool for staging and restaging patients with documented carcinoid tumor.

The efficacy of 18F-DOPA-PET imaging in identifying carcinoid tumors depends on the ability of tumor cells to uptake, decarboxylate, and store aminoacids. 18F-DOPA offers distinct advantages over 18F-FDG for detection of carcinoids, especially since many of these tumors are indolent, with low proliferation activity and good differentiation.⁵

18F-DOPA-PET is useful for detecting primary and metastatic neoplasia with neuroendocrine differentiation, such as carcinoid, gastroenteropancreatic tumors, glomus tumors, medullary thyroid cancer, small cell lung cancer, and pheochromocytoma/paraganglioma.^{6,7}

When compared with other available functional imaging, 18F-DOPA-PET/CT was able to detect more lesions, more positive regions, and more lesions per region than combined SRS and CT in catecholamine-producing tumors with a low aggressiveness and in well-differentiated tumors.^{2,8}

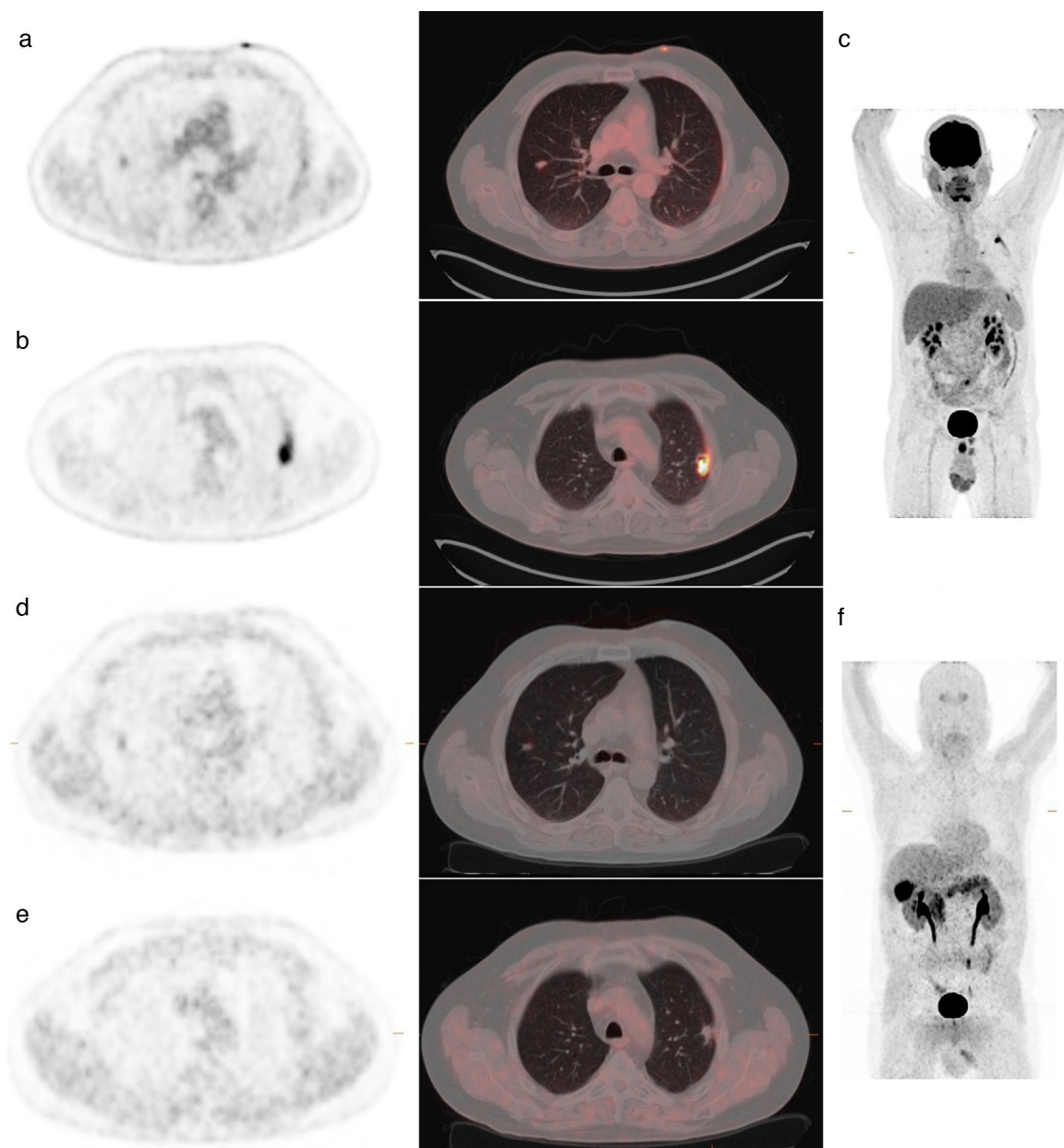


Figure 1 Upper panel. 18F-FDG-PET/CT performed after the injection of 259 MBq of radiotracer. (a) Pulmonary nodule located in the right-upper-lobe with SUVmax 1.9. (b) A second pleural-based pulmonary nodule was located in the left-upper-lobe with SUVmax 10.3. (c) Maximum intensity projection of 18F-FDG-PET/CT scan. Lower panel. 18F-DOPA-PET/CT acquired after the injection of a dose of 233 MBq. (d) Solitary pulmonary node showed in the right-upper-lobe with SUVmax 1.1. (e) 18F-DOPA-PET/CT allowed discarding the contralateral and pleural involvement. (f) Maximum intensity projection of 18F-DOPA-PET/CT scan revealing pancreatic physiological uptake due to no administration of carbidopa before the injection of radiotracer.

While the practice of 18F-FDG-PET/CT is fully standardized, up to now this has not been accomplished for 18F-DOPA-PET/CT protocol for NET. A 4 h fast is recommended by all groups. The oral premedication with the carbidopa, which was introduced to block the aromatic aminoacid-decarboxylase enzyme, is less common than for brain 18F-DOPA imaging. Furthermore, the range of injected activity of 18F-DOPA is 2–4 MBq/kg of body mass. The 18F-DOPA uptake by most organs and target lesions has been described as a plateau between 30 and 90 min post-injection.

In the case we describe, both PET/CT were performed according to the scientific community recommendations. Concordantly, we do not consider the administration of carbidopa before the injection of 18F-DOPA, so pancreatic physiological uptake can be observed (Fig. 1f). Both scans were acquired 60 min post-injection of radiotracer in a Biograph-16-PET/CT camera (Siemens/CTI).

The increasing number of therapeutic options and diagnostic procedures available for this disease requires a multidisciplinary approach and decision-making in tumor committees to ensure a personalized treatment.

Whenever possible, once hypercortisolemia is under control with medical therapy, the final treatment consists in the surgical excision of the tumor.

Surgery is the mainstay of treatment, based on the general principle of complete resection with preservation of as much normal lung tissue as possible. The treatment of choice for carcinoid tumors remains surgery and consists of a lobectomy supplemented by lymph node dissection.⁹

Bibliografía

1. Sayeg Y, Sayeg M, Baum RP, Kulkarni HR, Presselt N, Mäder I, et al. Neuroendokrine Neoplasien der Lunge. *Pneumologie*. 2014;68:456–77.
2. Koopmans KP, de Vries EG, Kema IP, Elsinga PH, Neels OC, Sluiter WJ, et al. Staging of carcinoid tumours with 18F-DOPA PET: a prospective, diagnostic accuracy study. *Lancet Oncol*. 2006;7:728–34.
3. Binderup T, Knigge U, Loft A, Mortensen J, Pfeifer A, Federspiel B, et al. Functional imaging of neuroendocrine tumors: a head-to-head comparison of somatostatin receptor scintigraphy, 123I-MIBG scintigraphy, and 18F-FDG PET. *J Nucl Med*. 2010;51:704–12.
4. Lin JH, Yen RF, Hung GU, Chieng PU, Kao CH. Pulmonary carcinoid tumor on fluorine-18-FDG PET imaging. *Ann Nucl Med Sci*. 2000;13:67–70.
5. Yakemchuk VN, Jager PL, Chirakal R, Reid R, Major P, Gulenchyn KY. PET/CT using 18F-FDOPA provides improved staging of carcinoid tumor patients in a Canadian setting. *Nucl Med Commun*. 2012;33:322–30.
6. Nanni C, Fanti S, Rubello D. 18F-DOPA PET and PET/CT. *J Nucl Med*. 2007;48:1577–9.
7. Santhanam P, Taïeb D. Role of 18F-DOPA PET/CT imaging in endocrinology. *Clin Endocrinol*. 2010;81:789–98.
8. Balogova S, Talbot JN, Nataf V, Michaud L, Huchet V, Kerrou K, et al. 18F-fluorodihydroxyphenylalanine vs other radiopharmaceuticals for imaging neuroendocrine tumours according to their type. *Eur J Nucl Med Mol Imaging*. 2013;40:943–66.
9. Noel-Savina E, Descourt R. Focus on treatment of lung carcinoid tumor. *Onco Targets Ther*. 2013;6:1533–7.

Irene Acevedo-Báñez^a, Juan Luis Tirado-Hospital^a, Ovidio Muñoz-Grijalvo^b, Miguel Angel Mangas-Cruz^c, Francisco Javier García-Gómez^{a,*}

^a Department of Nuclear Medicine, Virgen del Rocío University Hospital, Seville, Spain

^b Department of Internal Medicine, Virgen del Rocío University Hospital, Seville, Spain

^c Department of Endocrinology, Virgen del Rocío University Hospital, Seville, Spain

* Corresponding author.

E-mail address: javier191185@gmail.com (F.J. García-Gómez).

<http://dx.doi.org/10.1016/j.endonu.2015.01.006>

Absceso tiroideo por *Lactococcus lactis* en paciente inmunocompetente



Lactococcus lactis thyroid abscess in an immunocompetent patient

Caso clínico

La tiroiditis aguda supurativa (TAS) es un enfermedad infrecuente, predominantemente pediátrica y potencialmente grave. La baja prevalencia de abscesos tiroideos se relaciona con la resistencia de la glándula tiroidea a las infecciones debido a su cápsula fibrosa, la elevada perfusión sanguínea, el elevado contenido en yodo, el importante drenaje linfático y la separación anatómica de la glándula respecto a la vía aérea¹.

La TAS puede originarse a partir de una diseminación hematológica o linfática, por continuidad de órganos adyacentes o por inoculación directa tras una punción aspiración con aguja fina (PAAF)². Los factores predisponentes varían en función de la edad de presentación. En niños, el más frecuente es la existencia de una fístula del seno piriforme (FSP) que aparece por un desarrollo anómalo del tercer o cuarto arco branquial. En el 87-95% de los casos, aparece en el lado izquierdo, lo que se explica por la asimetría del cuarto arco branquial^{3,4}. En adultos, la existencia de FSP es

poco frecuente, siendo más relevantes otros factores como la existencia de enfermedad tiroidea previa (tiroiditis de Hashimoto, cáncer diferenciado de tiroides, bocio multinodular) y la presencia de un estado de inmunosupresión, que favorece a su vez la infección por microorganismos poco frecuentes⁵.

Se trata de una mujer de 17 años con antecedente de ansiedad nerviosa que acudió a Urgencias por cuadro de un mes de evolución consistente en fiebre, dolor en cara anterior del cuello y aumento de tamaño de celda tiroidea izquierda. Ante la sospecha clínica de tiroiditis subaguda se inició tratamiento antiinflamatorio (ibuprofeno 600 mg/8 h). Seis días después acudió de nuevo a Urgencias por ausencia de mejoría, por lo que se añadió prednisona (30 mg/24 h) en pauta descendente y fue remitida a la consulta de Endocrinología por persistencia del cuadro.

En la exploración física destacaba aumento de la dimensión de la glándula tiroidea a expensas del lóbulo izquierdo con dolor y empastamiento a la palpación y aumento de temperatura.

En la analítica destacaba: leucocitosis (leucocitos: 13.500/mm³, con 79,3% de neutrófilos) con elevación de reactantes de fase aguda (proteína C reactiva: 108,40 mg/l (rango: 0,1-10,0) y VSG: 122,00 mm (rango: 0,0-25,0) junto con función tiroidea normal (TSH: 1,97 μIU/mL (rango: 0,35-5,0), T4 libre 1,40 ng/dl (rango: 0,7-1,98) y T3 libre 2,54 pg/ml (rango: 2,3-4,2) y autoinmunidad tiroidea negativa.