



SCIENTIFIC LETTERS

Complete pituitary infarction associated with hypothermia and brain death



Infarto hipofisario completo asociado con hipotermia y muerte cerebral

Necrosis in a normal anterior pituitary, although rare, can be seen in routine autopsy series (1–5%), and is more common in patients who have been supported with artificial ventilation before death (~20%).^{1–3} In brain-dead patients, pituitary necrosis is invariably observed.^{4–7} In virtually all cases where pituitary necrosis is found at autopsy, the main histological feature of the necrosis is coagulative infarction, which is only partial and mostly in the center of the anterior pituitary. Here we report complete anterior pituitary infarction in a patient with hypothermia, cardiovascular arrest, and brain death.

A 61-year-old African American female was admitted for resection of multifocal colorectal cancer. She had had no significant past medical history; preoperative physical examination had been unremarkable except for low body mass index (BMI, 17.4 kg/m²). The surgical resection was open and extensive, and lasted for 8.5 h. Total estimated blood loss was 1050 mL and 8000 mL of lactated Ringers solution were given cumulatively. At the beginning of anesthesia, her temporal temperature was 36.6 °C. Forty minutes later, her esophageal temperature was 35.5 °C. A steady drop of temperature started at 5 h into the anesthesia, reaching a nadir of 32.3 °C near the end of anesthesia, in spite of the use of a warming blanket and raising the room temperature as much as possible. The patient, however, was reportedly able to open eyes and follow simple commands and otherwise stable after anesthesia completion. She remained intubated and was transferred to intensive care unit within 20 min. Upon arrival she was bradycardic and severely hypothermic with a temperature of 27.8 °C. She was given atropine; within a few minutes she became pulseless with narrow-complex ventricular tachycardia, requiring cardiopulmonary resuscitation for 4 min with 5 cardioversions. She resumed normal sinus rhythm but remained comatose. Cardiac arrest was believed to be due to hypothermia rather

than primarily cardiogenic. Coagulopathy, acidosis, bilateral pleural effusions and acute congestive heart failure developed within a few hours after cardiopulmonary resuscitation, and required pressor support. Her core temperature rose to about 36.7 °C after 5 h of warming measures. Cortisol levels were not measured and she did not receive corticosteroids. On postoperative day 1, the neurological team determined that the patient had suffered from brain death, attributed to multiple causes including advanced cancer, anesthesia, pain medications, hypoxia, electrolyte abnormality and hypothermia, but not hypoperfusion during cardiac arrest. Head CT was considered but the patient was too unstable to be taken to the imaging department to undergo the procedure. On postoperative day 3, she was extubated and expired shortly thereafter (extubation was delayed to give the family time to accept the brain death).

An autopsy was performed within 10 h after bodily death to search for the cause of profound hypothermia. General autopsy results were unremarkable; there was no evidence of coronary events; the thyroid and adrenal glands showed no signs of atrophy. Grossly, the brain exhibited diffuse cerebral edema and gray discoloration without focal lesions identified in hypothalamus; the pituitary gland appeared unremarkable. Microscopically, the brain exhibited diffuse anoxic or ischemic changes. The pituitary gland showed complete infarction of the anterior lobe (Fig. 1). There was no evidence of pituitary adenoma, as demonstrated by the preservation of acinar architecture with reticulum stain (not shown) and the presence of mixed population of pyknotic anterior pituitary cells. Although immunostaining for FSH, LH, ACTH, and TSH were largely preserved (FSH and ACTH are shown) and prolactin was nearly absent as expected in a postmenopausal woman, GH staining was completely lost (Fig. 1). There was no hemorrhage or infiltration by neutrophils or macrophages.

We have thus described complete anterior pituitary infarction in an adult female patient with hypothermia, cardiovascular arrest, and brain death. Pituitary infarction per se is not surprising in this brain-dead patient who has been on artificial ventilation for 3 days before autopsy, as pituitary coagulative infarction (necrosis) is well known in all brain-dead patients and in nearly one fifth of all patients who have been on artificial ventilation before death.^{3–7}

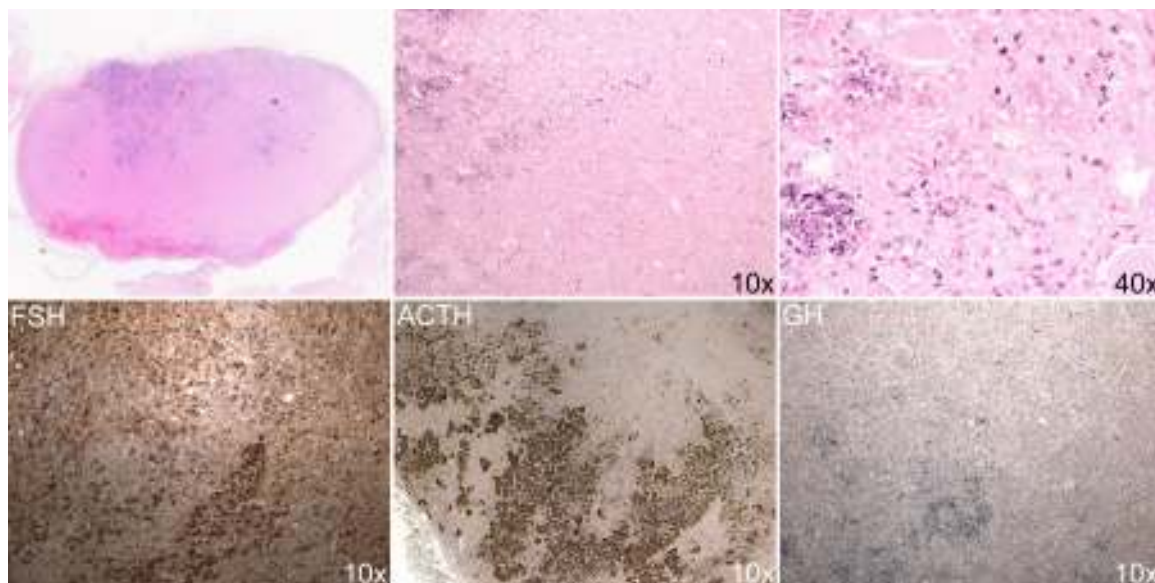


Figure 1 Histology of the postmortem pituitary. Upper panels: hematoxylin and eosin staining. Upper left: whole anterior pituitary which measured 10 mm × 6 mm. The whole anterior pituitary was replaced by amorphous material (upper left and upper middle panels) and pyknotic cells (upper right panel). Lower panels: immunostains for FSH, ACTH and GH.

To the best of our knowledge, complete pituitary infarction has not been reported previously together with relatively well-preserved brain structure, or in a patient who has been brain dead for only a few days; the finding is surprising as pituitary should be well preserved even after 21 days of brain death, and its total necrosis seems to occur only after 28 days of brain death.⁶ The exact timing of her complete pituitary infarction deserves consideration. As the patient was clinically well preoperatively and both thyroid and adrenal glands were normal at autopsy, she most likely had normal pituitary preoperatively. It is possible that pituitary necrosis occurred intraoperatively. Although the patient had a few risk factors for intraoperative hypothermia such as low body mass index, prolonged anesthesia, and complicated surgery,⁸ appropriate intraoperative warming measures were provided and the extent of hypothermia is very unusual. No hypothalamic lesions that could explain the hypothermia were found in autopsy. Adrenal insufficiency and hypopituitarism are well known but rare causes of hypothermia.⁹ The patient's complete pituitary infarction, if occurring intraoperatively, could certainly cause hypopituitarism and acute adrenal insufficiency and contribute to the profound hypothermia.

Alternatively, the complete pituitary infarction may have occurred postoperatively. Both artificial ventilation and brain death experienced by the patient are known to be associated with pituitary infarction.³⁻⁷ The mechanisms for ventilator-associated pituitary infarction are not clear, while in brain death it is suggested to be due to the absence of blood supply to the center of pituitary due to increased intracranial pressure secondary to brain edema; the preservation of the glandular periphery is explained by its extracranial blood supply.^{3,5} The patient's complete pituitary infarction would require stoppage of any blood supply to the gland, including extracranial components. As pituitary hormone immunostaining is preserved beyond a

week after brain death,⁷ this patient's intact pituitary hormone staining cannot be used as evidence of recent pituitary infarction. The patient's profound hypothermia may have contributed to the complete pituitary infarction as serum GH levels, a potential marker of pituitary necrosis, are higher in patients who died of hypothermia,^{5,10} and she indeed had total lack of GH-positive cells in the pituitary.

In summary, we here report a very unusual complete pituitary infarction in a patient with profound intraoperative hypothermia and brain death. If it occurred intraoperatively, the complete pituitary infarction could partly explain the intraoperative hypothermia; if it occurred postoperatively, the complete pituitary infarction may be attributed to hypothermia, the full causes of which would remain obscure.

References

1. Kovacs K. Adenohypophysial necrosis in routine autopsies. *Endokrinologie*. 1972;60:309-16.
2. Sandte S, Saeger W, Hanke DK. Pituitary necrosis. Decreasing incidence due to modern intensive therapy? *Pathologe*. 2000;21:292-5.
3. Kovacs K, Bilbao JM. Adenohypophysial necrosis in respirator-maintained patients. *Pathol Microbiol (Basel)*. 1974;41:275-82.
4. Yokota H, Nakazawa S, Shimura T, Kimura A, Yamamoto Y, Otsuka T. Hypothalamic and pituitary function in brain death. *Neurol Med Chir (Tokyo)*. 1991;31:881-6.
5. Sugimoto T, Sakano T, Kinoshita Y, Masui M, Yoshioka T. Morphological and functional alterations of the hypothalamic-pituitary system in brain death with long-term bodily living. *Acta Neurochir (Wien)*. 1992;115:31-6.
6. Arita K, Uozumi T, Oki S, Kurisu K, Ohtani M, Mikami T. The function of the hypothalamo-pituitary axis in brain dead patients. *Acta Neurochir (Wien)*. 1993;123:64-75.
7. Ishikawa T, Michiue T, Quan L, Zhao D, Komatsu A, Bessho Y, et al. Morphological and functional alterations in the

- adenohypophysis in cases of brain death. *Leg Med (Tokyo)*. 2009;11 Suppl. 1:S234-7.
8. Mehta OH, Barclay KL. Perioperative hypothermia in patients undergoing major colorectal surgery. *ANZ J Surg*. 2014;84:550-5.
 9. Burke CW. Adrenocortical insufficiency. *Clin Endocrinol Metab*. 1985;14:947-76.
 10. Ishikawa T, Michiue T, Maeda H. Evaluation of postmortem serum and cerebrospinal fluid growth hormone levels in relation to the cause of death in forensic autopsy. *Hum Cell*. 2011;24:74-7.

Run Yu^{a,*}, Xuemo Fan^b, Serguei I. Bannykh^b

^a *Division of Endocrinology, Cedars-Sinai Medical Center, Los Angeles, CA 90048, United States*

^b *Department of Pathology, Cedars-Sinai Medical Center, Los Angeles, CA 90048, United States*

* Corresponding author.

E-mail address: run.yu@cshs.org (R. Yu).

<http://dx.doi.org/10.1016/j.endonu.2016.01.003>

Estado hiperglucémico hiperosmolar: una forma poco frecuente de inicio de la diabetes mellitus tipo 1 en la infancia



Hiperglycemic hyperosmolar state: An unusual way of first appearance of type 1 diabetes in children

El estado hiperglucémico hiperosmolar (EHH) es una forma de debut o descompensación diabética muy infrecuente en la infancia, aunque su incidencia está aumentando en los últimos años, probablemente por el incremento de la obesidad y de la diabetes mellitus tipo 2 (DM2), en ese grupo poblacional^{1,2}. De los casos del EHH en niños, comunicados hasta 2008, solo uno se produjo como descompensación de una diabetes mellitus tipo 1 (DM1) previa, mientras que en el resto fue la forma de debut de la diabetes tanto tipo 1 como, más frecuentemente, tipo 2².

Sus principales manifestaciones clínicas, la poliuria y la polidipsia, pueden pasar semanas desapercibidas, retrasando la búsqueda de atención médica, y derivando en un estado de deshidratación severa. Su importancia estriba en las diferencias terapéuticas frente a la cetoacidosis diabética (CAD), forma más frecuente de debut y descompensación de una diabetes en la infancia, y generalmente, de diagnóstico más precoz por acompañarse de sintomatología más florida.

Son características típicas del EHH: hiperglucemia marcada, hiperosmolaridad y cetosis leve. Sus criterios diagnósticos se recogen en la [tabla 1](#)³.

Se presenta el caso de un varón de 13 años y 3 meses, que acude a urgencias por dolor abdominal de 15 días de evolución, y estreñimiento pertinaz. Asocia poliuria y polidipsia de 2-3 semanas de evolución, sin pérdida de peso. Refiere ingesta abundante de bebidas carbonatadas para aliviar la sed.

Antecedentes familiares: padre con DM1 (mal control glucémico); madre y 2 hermanos sanos.

Antecedentes personales: TDAH tratado con metilfenidato.

Exploración física inicial: peso 36 kg, TA 128/80 mmHg, T.^a 35,9°C, buen estado general, consciente, orientado, colaborador, sin focalidad neurológica, normocoloreado y normohidratado.

Pruebas complementarias:

- Bioquímica: glucemia 1.138 mg/dl, cetonemia 0,8 mmol/l, natremia 125 mmol/l (corregida por glucemia: 142 mmol/l), kalemia 5,1 mmol/l, urea 25 mg/dl, osmolaridad plasmática 320 mOsm/kg (osmolaridad efectiva 323,4 mOsm/kg), pH venoso 7,31, bicarbonato 27 mmol/l, lactato 1,3 mmol/l y PCR < 0,1 mg/dl. Resto normal.
- Orina: glucosuria+++ y cetonuria+.

Ante la sospecha de debut diabético, en urgencias se inició reposición con suero salino fisiológico (bolo inicial de 10 ml/kg; después a 14 ml/kg/h) con aportes de potasio (1 mEq/l), consiguiendo descender progresivamente la glucemia y normalizar el ionograma. A las 4h, cuando la glucemia fue < 300 mg/dl, se añadió suero glucosado al 5%. Por otra parte, dado el buen estado general del paciente, la adecuada tolerancia a la ingesta oral y la mínima cetosis que presentaba, se comenzó terapia con insulina regular subcutánea (0,7 UI/kg/día) según cifras de glucemia capilar, y a las 12 h del ingreso se substituyó por múltiples dosis de insulina subcutánea (aspártica y glargina) a 0,6 UI/kg/día, con buena evolución clínica. Se instauró dieta con control de la ingesta de hidratos de carbono por raciones; se instruyó al paciente y a la familia en el manejo de la diabetes, siendo dado de alta en una semana, sin incidencias.

El estudio de DM basal mostró: HbA1c 12,3% (normal: < 6%), péptido-C 0,03 mmol/l (normal: > 0,16 nmol/l), insulina 8 mUI/l (normal: 2-16 mUI/l), anticuerpos: anti-IA2 1.537,6 U/ml (normal: < 1 U/ml), anti-GAD-65 68,34 U/ml (normal: ≤ 1 U/ml) y anti-insulina negativos, confirmándose el diagnóstico de DM1.

Actualmente el paciente sigue revisiones en consultas externas, manteniendo buen control glucémico (última HbA1c realizada: 6,5%).

La identificación precoz de los cuadros de descompensación diabética puede ser compleja, particularmente cuando se trata del debut de una diabetes no conocida. Una pronta detección y manejo pueden evitar complicaciones severas.

Al ser el EHH una forma poco habitual de debut en la infancia, se hace más difícil su sospecha (es más frecuente en pacientes mayores, pacientes con sobrepeso u obesidad y como forma de debut o descompensación de una DM2). Además, el EHH suele revestir mayor morbimortalidad que la CAD, según la severidad de la deshidratación y la