



## Original article

# Contrast imaging techniques to diagnose hepatocellular carcinoma in cirrhotics outside regular surveillance



Massimo Iavarone<sup>a,\*</sup>, Mauro Viganò<sup>b</sup>, Nicole Piazza<sup>a</sup>, Vincenzo Occhipinti<sup>b</sup>, Angelo Sangiovanni<sup>a</sup>, Marco Maggioni<sup>c</sup>, Gioacchino D'Ambrosio<sup>d</sup>, Laura V. Forzenigo<sup>e</sup>, Fabio Motta<sup>f</sup>, Pietro Lampertico<sup>a</sup>, Maria-Grazia Rumi<sup>b</sup>, Massimo Colombo<sup>g</sup>

<sup>a</sup> C.R.C. "A.M. & A. Migliavacca Center for Liver Disease" and Division of Gastroenterology and Hepatology, University of Milan and Fondazione IRCCS Ca' Granda Maggiore Hospital, Milan, Italy

<sup>b</sup> Hepatology Unit, Ospedale San Giuseppe, Università di Milano, Milan, Italy

<sup>c</sup> Department of Pathology, Fondazione IRCCS Ca' Granda, Milan, Italy

<sup>d</sup> Department of Pathology, Ospedale Multimedica, Milan, Italy

<sup>e</sup> Radiology Unit, Fondazione IRCCS Ca' Granda, Milan, Italy

<sup>f</sup> Radiology Unit, Ospedale San Giuseppe, Milan, Italy

<sup>g</sup> Center for Translational Hepatology Research, Clinical and Research Center Humanitas Hospital, Rozzano, Italy

## ARTICLE INFO

## Article history:

Received 14 March 2018

Accepted 28 September 2018

Available online 17 April 2019

## Keywords:

Intra-hepatic cholangiocarcinoma

Contrast-enhanced CT-scan

Magnetic resonance

Fine needle liver biopsy

Abdominal ultrasound

## ABSTRACT

**Introduction and aim:** The American Association for the Study of the Liver (AASLD) recommends contrast computerized tomography (CT-scan) and magnetic resonance (MRI) to diagnose hepatocellular carcinoma (HCC) arising in cirrhotic patients under semiannual surveillance with abdominal ultrasound (US). A US guided fine needle biopsy (FNB) serves the same purpose in radiologically undiagnosed tumors and incidentally detected nodules in cirrhotics outside surveillance. In this population, we evaluated the performance of radiological diagnosis of HCC according to 2010 AASLD recommendations.

**Materials and methods:** All cirrhotic patients with a liver nodule incidentally detected by US were prospectively investigated with a sequential application of CT-scan/MRI examination and a FNB.

**Results:** Between 2011 and 2015, 94 patients (mean age 67 years) had a liver nodule (total 120) detected by US in the context of histologically confirmed cirrhosis. Mean nodules diameter was 40 (10–160) mm, 87 (73%) <5 cm. At histology, 84 (70%) nodules were HCC, 8 (7%) intrahepatic cholangiocarcinoma, 6 (5%) metastases, 2 (2%) neuroendocrine tumors and 20 (16%) benign lesions. Hyperenhancement in arterial phase followed by wash-out in venous phases on at least one radiological technique was demonstrated in 62 nodules (61 HCC, 1 high grade dysplastic nodule), with a specificity of 97% (IC95%: 85–100%), sensitivity 73% (IC95%: 62–81%) and diagnostic accuracy 80%, being 64% for  $\geq 5$  cm HCC. Sensitivity of AFP >200 ng/mL was 12% (IC95%: 6–23%).

**Conclusion:** A single contrast imaging technique showing a typical contrast pattern confidently identifies HCC also in cirrhotic patients with an incidental liver nodule, thereby reducing the need for FNB examinations.

© 2019 Fundación Clínica Médica Sur, A.C. Published by Elsevier España, S.L.U. This is an open access article under the CC BY-NC-ND license (<http://creativecommons.org/licenses/by-nc-nd/4.0/>).

## 1. Introduction

The detection through a semiannual surveillance program with abdominal ultrasound (US) of a small hepatocellular carcinoma (HCC) in cirrhotic patients is associated with measurable clinical

\* Corresponding author at: C.R.C. "A.M. & A. Migliavacca Center for Liver Disease", Division of Gastroenterology and Hepatology, University of Milan, Fondazione IRCCS Ca' Granda Maggiore Hospital, Via F. Sforza 28, 20122 Milan, Italy.  
E-mail address: [massimo.iavarone@gmail.com](mailto:massimo.iavarone@gmail.com) (M. Iavarone).

benefits, including improved survival [1–4]. On the contrary, the limited access worldwide to a screening program for an early diagnosis can restrain the access to curative treatments in populations at risk (i.e. patients with non-alcoholic fatty liver disease (NAFLD) and alcoholic liver disease) [5–8]. Adherence to surveillance with US has important diagnostic implications too, since the radiological diagnosis of HCC with a single positive technique (i.e. computed tomography – CT-scan or magnetic resonance imaging – MRI) has not been extensively validated in nodules detected outside regular surveillance [3,4]. In fact, these radiological criteria were built on prospectively collected databases of patients with a de-novo

liver nodule detected during surveillance [9–11], while the same algorithm was never validated in the management of liver nodules incidentally detected in patients outside of any surveillance program. Indeed, the only two studies testing the diagnostic accuracy of contrast imaging in cirrhotics with an incidental HCC, omitted to provide separate figures of sensitivity and specificity of contrast imaging for incidental tumors alone [12,13]. For instance, the dimensional increase of nodules in surveillance or the change in the appearance of pre-existing nodules to either ultrasound or TC/MRI are suspect criteria that cannot be applied to non-surveillance patients. In addition, there are benign lesions, relatively frequent in the healthy liver, theoretically rare in the cirrhotic liver, presenting a similar contrast-enhanced pattern. Finally, the American College of Gastroenterology in their guideline for the management of focal liver lesions applied the non-invasive criteria on the basis of expert opinion and their diagnostic algorithm needs validation for patients with risk for HCC outside surveillance programs [14].

In a cohort of prospectively recruited cirrhotic patients with an incidentally detected liver nodule outside of any surveillance program, we investigated sensitivity, specificity and diagnostic accuracy of the recall policy for HCC based on sequential application of contrast CT-scan, MRI and echo-guided fine needle biopsy (FNB) as recommended by the 2010 American Association for the Study of the Liver (AASLD) guidelines.

## 2. Patients and methods

This prospective study started in January 2011 and included patients with compensated cirrhosis outside surveillance programs with US who were incidentally found to have a liver nodule during clinical examination with abdominal US and were therefore referred to the liver centers at Policlinic Hospital or San Giuseppe Hospital, University of Milan (Fig. 1). All patients referred from other centers for a liver nodule, underwent a new US in our Centers to be confirmed after the first visit and thereafter the protocol started. The study protocol is conforming to the ethical guidelines of the 1975 Declaration of Helsinki and it was approved by the Institutional Review Board of the Hospital. After giving an informed consent in the presence of an independent witness, patients were assessed following the collection of a detailed medical history, a physical examination, complete blood count and biochemical tests, including serum alpha-fetoprotein (AFP), and markers for viral hepatitis and autoimmunity, to define the underlying liver disease if previously unknown, and finally enrolled.

Cirrhosis was diagnosed by histology or on clinical grounds by using abdominal US features of blunted, nodular liver edge accompanied by splenomegaly (>13 cm) and  $<100 \times 10^3/\mu\text{L}$  platelets, esophageal varices. Excluded were patients under US-surveillance, patients with a previously diagnosed HCC and patients with decompensated liver disease, i.e. Child–Pugh C. Patients – with recently diagnosed cirrhosis in whom a liver nodule was detected during their first US – were considered recruitable into the study, since they were not considered under-surveillance program.

### 2.1. Study design

Abdominal CT scan was carried out within 1 month from the first US detection or confirmation (for patients referred from other centers) of a liver nodule. If CT scan showed a typical vascular pattern in  $\geq 1$  cm nodules, patients underwent FNB directly to confirm the diagnosis of HCC; otherwise MRI was performed after the CT scan. In all patients, a US-guided FNB was carried out for the definitive diagnosis within 2 months from the initial detection (Fig. 1). We arbitrarily introduced CT-scan as first imaging technique for cost effectiveness reasons [9,15].

### 2.2. Characterization of the liver nodules

The diagnostic reference was histology through a FNB performed within the nodule and the surrounding liver parenchyma. All visible nodules by abdominal US underwent histological characterization. The procedure was repeated in all patients with unsolved histological diagnosis, i.e. patients showing similar histological features within and outside the liver nodule. All patients with nodules lacking histological features of malignancy, repeated US at 3 months' intervals and an abdominal CT/MRI at 6 months' intervals to assess changes in size and in the vascular pattern of the nodule at imaging. All nodules either enlarging or showing changes in the vascular pattern, underwent a repeated FNB examination. The clinical impact of the diagnosis of HCC using serum AFP level  $>200$  ng/mL in patients with a  $>2$  cm nodule, according to the 2005 AASLD recommendations was evaluated as well [16].

### 2.3. Definition of vascular pattern of the nodules

Arterial hypervascularization was defined as an increased contrast enhancement of the nodule (hyperdensity on CT, hyperintensity on MRI), taking place during the arterial phase of examination, as compared to the surrounding liver parenchyma (wash-in). Portal/venous contrast wash-out was a hypoenhanced pattern of the nodule (hypodensity on CT, hypointensity on MRI) with respect to the surrounding liver parenchyma taking place during the portal/venous and late equilibrium phases. The typical radiological pattern of HCC was the hyperenhancement during the arterial phase followed by contrast wash-out of the nodule during portal/venous and late equilibrium phases [17].

We considered typical only those nodules with a complete and homogeneous hyperenhancement in the arterial phase, otherwise we considered the incomplete enhancement as inhomogeneous. CT and MRI images were blindly read, firstly independently and in a few cases jointly whenever a discordant result was obtained by two experienced radiologists (LVF and FM). Patients with a discrepant result were re-evaluated in a dedicated reading session by the two radiologists – unaware of the liver biopsy results – to reach a shared final radiological description.

The radiological pattern has been also evaluated for all nodules according to Li-RADS v2017 guidelines [18].

### 2.4. CT-scan and MRI

CT-scan was performed with a 64 detector MDCT (Definition Siemens, Erlangen, Germany). In all patients, we used a bolus tracking technique to determine the optimal delay time to start arterial acquisition.

MRI was performed with a 1.5-T system (Avanto, Siemens Medical Systems, Erlangen, Germany) using a six-channel phased-array body coil for signal detection and gadolinium (Gadobenate Dimeglutamine 0.5 mmol/L, Multihance, Bracco, Milan, Italy) as contrast medium. All patients underwent multiphasic contrast-enhanced dynamic 3-dimensional MRI of the whole liver with fat suppression. In all patients we used bolus tracking technique to optimize the delay time to acquire arterial phase.

Both the techniques were performed in accordance with the technical indications of the American College of Gastroenterology guidelines and as previously published by our group [9,14].

### 2.5. Liver histology

The FNB procedure was performed using a 21-gauge trenchant needle for microhistology (Biomol, HS Hospital Service, Italy) to examine both intra- and extra-nodule liver parenchyma tissue: the comparative evaluation of the nodule and the surrounding

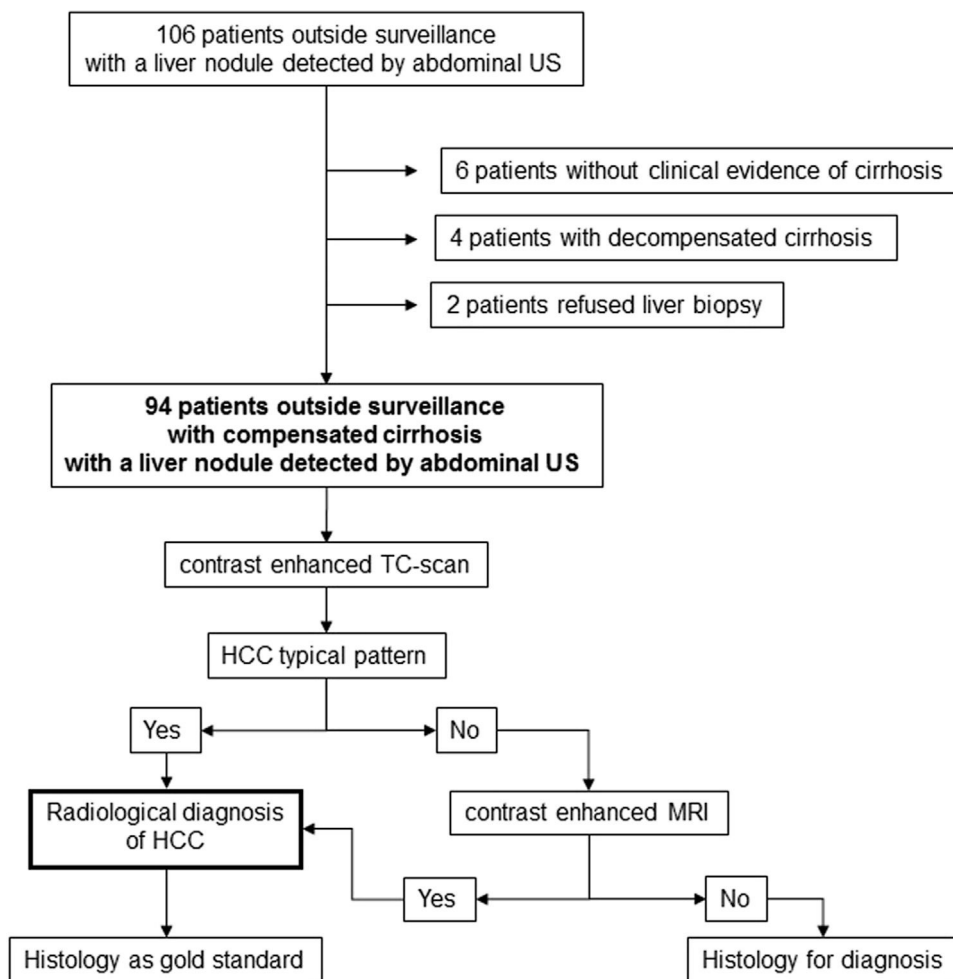


Fig. 1. Study flow-chart.

parenchyma has been shown to increase the diagnostic accuracy of histology. In the study the evaluation of the surrounding liver parenchyma would also confirm the diagnosis of cirrhosis if deemed necessary. The diagnosis was made according to the International Working Party criteria [19]. Formalin fixed paraffin embedded liver sections were examined separately and then jointly by two experienced liver pathologists (MM and GD) who were unaware of the result of radiological examinations.

## 2.6. Liver disease

Patients were classified according to the following categories for the cause of cirrhosis: (1) hepatitis B virus (HBV) infection – patients with a positive serum test for hepatitis B surface antigen only; (2) hepatitis C virus (HCV) infection – patients positive only for both the antibody to hepatitis C virus and HCV-RNA; (3) alcohol abuse – a daily intake >60 g of ethanol in women or >80 g in men, for more than 10 years, only; (4) NAFLD – according to the AASLD practice guidelines [20]; (5) multiple causes – this category included patients with a combination of the above factors.

## 2.7. Statistical analysis

The baseline characteristics of the patients are expressed as median and range or count and proportion. Comparison of patients with a HCC and patients with non-HCC nodules was done by the Student's *t* test or the Mann–Whitney test for continuous variables and Fisher's exact test for categorical variables. A conventional *p*

value <0.05 was considered statistically significant. Calculations were done with Stata 10.0 statistical package (Stata 1944–2007, College Station, TX, USA).

## 3. Results

Ninety-four patients with a Child–Pugh A or B cirrhosis and an incidentally detected liver nodule, were included. The indications to US examination, which lead to the identification of a liver nodule, were: abnormal liver enzymes or first detection of HCV-Ab/HBsAg positivity in 30 (32%), abdominal pain in 16 (17%), weight loss or anemia in 5 (5%), a previous non-HCC cancer in 10 (11%), occasional abdominal US in 18 (19%) and other reasons in 15 (16%).

### 3.1. Diagnosis of liver nodule

A total of 120 nodules were identified by abdominal US and confirmed by CT-scan/MRI examinations (Table 1). Liver nodule size ranged from 10 to 160 mm (mean 40 mm), with 87 (73%) nodules being smaller than 50 mm. An FNB was successfully carried out in all patients. Four out of 120 nodules showed histological features similar within and outside the nodule at first biopsy (corresponding to a total of 3% false-negative results at the first biopsy) underwent a second FNB to reach the final diagnosis. At histology, 84 (70%) nodules were HCC in 70 patients, 8 (7%) intrahepatic cholangiocarcinoma (ICC), 6 (5%) metastases of either colon or lung cancer or lymphoma and 2 (2%) neuroendocrine tumors.

**Table 1**  
Demography of patients with compensated cirrhosis with a liver nodule detected by abdominal ultrasound outside surveillance.

	All patients	HCC	Non HCC	p value
Patients, no.	94	70	24	
Nodules, no.	120	84	36	
Males, no. (%)	73 (78)	58 (83)	15 (63)	0.05
Age, yrs <sup>a</sup>	70 (44–85)	67 (44–83)	73 (48–85)	0.24
Risk factors, no. (%)				
HBV	8 (9)	8 (11)	0	0.1
HCV	28 (30)	23 (33)	5 (21)	0.3
Alcohol	22 (23)	18 (26)	4 (17)	0.4
NAFLD	16 (17)	8 (11)	8 (33)	0.02
Mixed	20 (21)	13 (19)	7 (29)	0.4
Diabetes, no. (%)	30 (32)	24 (34)	6 (25)	0.46
Child–Pugh class A, no. (%)	87 (93)	64 (91)	23 (96)	1.0
AFP, ng/mL <sup>a</sup>	9 (1–60,000)	11 (1–60,000)	4 (1–101)	0.24
AFP >200 ng/mL, no. (%)	8 (9)	8 (11)	0	0.10
Nodule size, mm <sup>a</sup>	40 (10–160)	40 (10–160)	30 (10–100)	0.4
10–20 mm, no. (%)	29 (24)	15 (18)	14 (39)	0.02
21–49 mm, no. (%)	58 (48)	46 (55)	12 (33)	0.05
≥50 mm, no. (%)	33 (28)	23 (27)	10 (28)	1.0
Nodules number				
Single, no. (%)	60 (64)	52 (74)	8 (33)	0.0005
2–3, no. (%)	20 (21)	10 (14)	10 (42)	0.008
Multiple, no. (%)	13 (14)	7 (10)	6 (25)	0.09

HBV, hepatitis B virus; HCV, hepatitis C virus; NAFLD, non-alcoholic fatty liver disease; AFP, alpha-fetoprotein.

<sup>a</sup> Median (range).

**Table 2**  
Final diagnosis of 120 liver nodules detected outside regular surveillance stratified by size.

Nodule size	No.	HCC	iCC	MTX	NET	HGDN	LGDN	MRN	Other <sup>a</sup>
10–20 mm	29	15 (52%)	2 (7%)	0	0	2 (7%)	4 (14%)	2 (7%)	4 (14%)
21–49 mm	58	46 (79%)	1 (2%)	3 (5%)	2 (3%)	1 (2%)	1 (2%)	3 (5%)	1 (2%)
≥50 mm	33	23 (70%)	5 (15%)	3 (9%)	0	0	0	0	2 (6%)
Total	120	84 (70%)	8 (7%)	6 (5%)	2 (2%)	3 (2%)	5 (4%)	5 (4%)	7 (6%)

HCC, hepatocellular carcinoma; iCC, intrahepatic cholangiocarcinoma; MTX, metastasis; NET, neuroendocrine tumor; HGDN, high grade dysplastic nodule; LGDN, low grade dysplastic nodule; MRN, macroregenerative nodule.

<sup>a</sup> 5 steatotic nodules, 2 granulomas.

According to safety concerns, no seeding has been reported in our cohort, among these nodules with a final diagnosis of malignancy. The remaining 20 nodules were non-malignant lesions: 3 (2%) high grade dysplastic nodules (HGDN), 5 (4%) low grade dysplastic nodules, 5 (4%) macroregenerative nodules, 5 (4%) steatotic lesions and two (2%) granulomas (Table 2). One-hundred and seventeen (98%) nodules yielded concordant readings, whereas in the 3 nodules with discordant results, a final univocal interpretation was reached by discussion between the two pathologists (2 with a final diagnosis of HCC and 1 with a final diagnosis of iCC). HCC and non-HCC nodules were equally distributed in terms of patient age, size, Child–Pugh and AFP levels. The etiologies of liver disease were equally distributed between patients with HCC and non-HCC nodules, yet NAFLD was a more frequent diagnosis among non-HCC nodules (Table 1). Among non-HCC nodules non-malignant lesions contributed 12 out of 14 ≤2 cm nodules, while iCC and metastases were found in 8/10 ≥5 cm nodules and 4/6 >3 cm nodules at presentation. All the eight patients with an AFP >200 ng/mL had HCC; of them six had at least a nodule >2 cm accomplishing both the criteria for the AFP-based HCC diagnosis according to the 2005 AASLD recommendations: the rates of sensitivity, specificity, positive and negative predictive values and accuracy of AFP for the diagnosis of HCC were 12% (IC95% 6–23%), 100% (IC95% 75–100%), 100%, 22% and 29%, respectively.

Among the 70 patients with a diagnosis of HCC, 39 were staged BCLC 0/A, 16 BCLC B and 15 in an advanced stage. Among the 6 iCC, only one was classified T1N0M0 while one was classified T2N0M0 according to the TNM classification; the other four tumors were already metastatic in their first presentation.

### 3.2. Radiological investigations

Contrast CT and/or MRI confirmed all nodules detected by US. By CT-scan, the typical contrast enhancement pattern for HCC was detected in 50 (42%) nodules. Twelve (10%) nodules lacking a typical vascular pattern for HCC at CT-scan were subsequently classified as HCC by MRI. A US-guided FNB was deemed necessary to obtain a diagnosis in the remaining 58 (48%) nodules lacking the typical features for HCC at both radiological techniques. One-hundred and eight (90%) nodules yielded concordant readings, whereas in the 12 nodules with discordant results, a final univocal interpretation was reached by discussion between the two radiologists (2 out of 62 wash-in and wash-out pattern and 4 without the typical pattern for HCC).

According to AASLD, sequentially applying the two radiological techniques, a typical contrast enhancement pattern for HCC was shown in 62 nodules (61 HCC, 1 HGDN) with a specificity of 97% (IC95% 85–100%), and a sensitivity of 73% (IC95% 62–81%) and a diagnostic accuracy of 80% (Table 3), without any difference with respect to risk factors. When considering only CT-scan (first radiological method used in all nodules for diagnosis) the specificity was 100% (IC95% 91.4–100%), and sensitivity 56.8% (IC95% 45.8–67.3%) and a diagnostic accuracy of 70.5%.

HCC ≥5 cm in size less frequently showed the characteristic radiological features compared to both small (1–2 cm) and 2–5 cm HCC, showing a diagnostic sensitivity as low as 48% (IC95% 29–67%, Table 3). Table 4 shows the different radiological patterns of atypical ≥5 cm HCC whereas Fig. 2 shows a frequently detected pattern of inhomogeneous hyperenhancement followed by wash-out in a

**Table 3**  
Sensitivity and specificity of the typical vascular pattern (wash in + wash out) of a single radiological technique for the diagnosis of HCC in 94 patients with >1 cm nodules, stratified by nodule size.

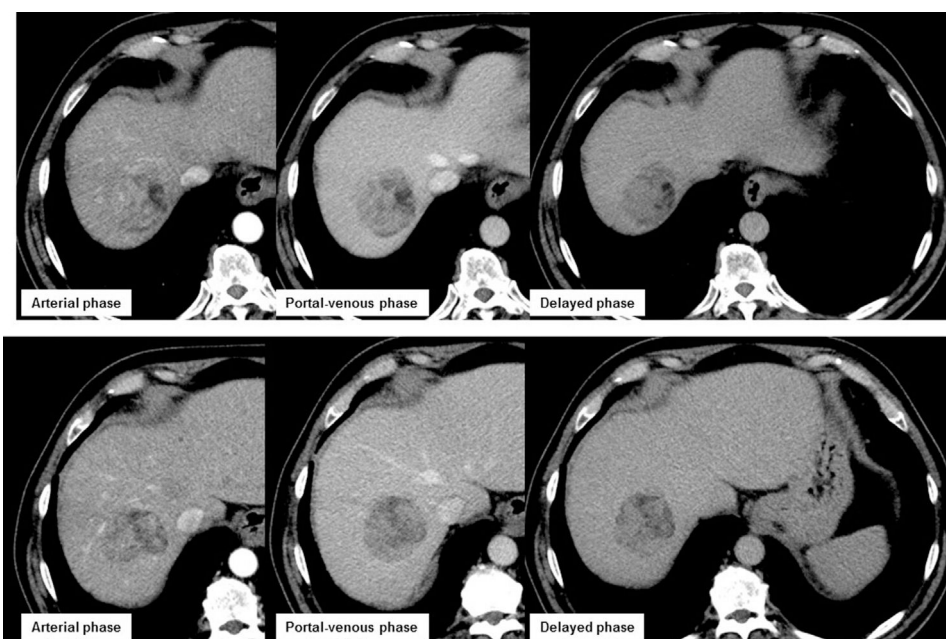Nodule size	Prevalence of HCC	Sensitivity (IC95)	Specificity (IC95)	PPV	NPV	Accuracy
10–20 mm	15 (52%)	0.733(0.476–0.895)	0.928(0.665–0.999)	0.917	0.762	0.828
21–49 mm	46 (79%)	0.847(0.715–0.927)	1.0 (0.718–1.0)	1.0	0.635	0.879
≥50 mm	23 (70%)	0.478(0.292–0.670)	1.0 (0.679–1.0)	1.0	0.451	0.636
Overall	84 (70%)	0.726(0.622–0.811)	0.972(0.846–0.999)	0.984	0.603	0.800

HCC, hepatocellular carcinoma; IC, interval of confidence; PPT, positive predictive value; NPV, negative predictive value.

**Table 4**  
Atypical features of MRI/CT-scan imaging and serum AFP levels in 12 HCC ≥5 cm.

Size (mm)	Arterial phase	Portal venous phase	Delayed phase	AFP value (ng/mL)
60	Inhomogeneous hyperenhancement	No wash-out	No wash-out	29
78	Inhomogeneous hyperenhancement	Inhomogeneous wash-out	Inhomogeneous wash-out	16
50	Hyperenhancement	No wash-out	No wash-out	7
90	Inhomogeneous hyperenhancement	Inhomogeneous wash-out	Inhomogeneous wash-out	60,000
100	Inhomogeneous hyperenhancement	Inhomogeneous wash-out	Inhomogeneous wash-out	549
55	Inhomogeneous hyperenhancement	Wash-out	Wash-out	7
68	No hyperenhancement	Wash-out	Wash-out	2593
55	Inhomogeneous hyperenhancement	Wash-out	Wash-out	914
51	Inhomogeneous hyperenhancement	Wash-out	Wash-out	32
80	Inhomogeneous hyperenhancement	No wash-out	No wash-out	15
68	No hyperenhancement	Wash-out	Wash-out	17
55	Hyperenhancement	No wash-out	No wash-out	29

AFP, alpha-fetoprotein.



**Fig. 2.** Atypical CT-scan results in a HCC nodule 51 mm in size. Not homogeneous contrast uptake during the arterial, portal-venous and delayed phase.

5.5 cm HCC. The sensitivity increased to 77% (IC95% 69–86%) considering typical contrast enhancement pattern for HCC also an inhomogeneous hyperenhancement followed by wash-out, without any change in specificity, with a diagnostic accuracy increased to 83%. This approach further decreased the need for histological characterization to 45% of all US-detected nodules.

The 16 non-HCC malignant nodules showed heterogeneous arterial patterns on CT-scan/MRI, without evidence of wash-out in portal/venous and delayed phases (Table 5). According to the Li-RADS criteria, the 120 nodules were categorized as LR-2 in 8, as LR-3 in 35, as LR-4 in 9, as LR-4/LR-5 in 17 and as LR-5 in 51 (Supplementary Table 1).

### 3.3. Additional nodules missed by US

CT-scan and MRI were able to detect 45 additional nodules that were initially missed by abdominal-US in 14 (15%) patients. There were 8 (57%) synchronous HCC, 3 (21%) iCC, 1 metastatic colon cancer, 1 neuroendocrine tumor and 1 multiple granulomas. Thirty-seven (82%) were ≥1 cm nodules, all with the same radiological pattern compared to the histologically characterized nodules. However, these nodules were not counted for the sensitivity and specificity analyses. HCC was single in 52 (74%) patients, including 36 (69%) <5 cm tumors in size, and multiple in 18 (17%), including 3 (17%) patients with ≤3 nodules ≤3 cm in size.

**Table 5**  
MRI/CT-scan features and serum AFP levels of 16 non-HCC malignant nodules.

Size (mm)	Arterial phase	Portal venous phase	Delayed phase	AFP value (ng/mL)	Risk factor	Diagnosis
100	"Ring-like" hyperenhancement	"Ring-like" hyperenhancement	"Ring-like" hyperenhancement	8	NAFLD	Colon MTX
90	Inhomogeneous hyperenhancement	No wash-out	No wash-out	2	HCV	Colon MTX
25	No wash-in	"Ring-like" hyperenhancement	"Ring-like" hyperenhancement	8	Multiple	Lung MTX
30	Hyperenhancement	Hyperenhancement	Hyperenhancement	1	Multiple	NHLa
55	Hyperenhancement	Hyperenhancement	Hyperenhancement	24	HCV	Colon MTX
25	"Ring-like" hyperenhancement	"Ring-like" hyperenhancement	"Ring-like" hyperenhancement	–	–	Colon MTX
55	"Ring-like" hyperenhancement	"Ring-like" hyperenhancement	"Ring-like" hyperenhancement	4	Multiple	iCC
50	"Ring-like" hyperenhancement	No wash-out	No wash-out	2	Multiple	iCC
55	"Ring-like" hyperenhancement	"Ring-like" hyperenhancement	"Ring-like" hyperenhancement	2	NAFLD	iCC
60	"Ring-like" hyperenhancement	Inhomogeneous wash-in	Inhomogeneous wash-in	3	NAFLD	iCC
20	"Ring-like" hyperenhancement	No wash-out	No wash-out	13	HCV	iCC
98	No wash-in	"Ring-like" hyperenhancement	"Ring-like" hyperenhancement	3	Alcohol	iCC
35	"Ring-like" hyperenhancement	Inhomogeneous wash-in	Inhomogeneous wash-in	–	–	iCC
55	No wash-in	"Ring-like" hyperenhancement	"Ring-like" hyperenhancement	–	–	iCC
30	Hyperenhancement	Hyperenhancement	Hyperenhancement	6	NAFLD	NET
25	Hyperenhancement	Hyperenhancement	Hyperenhancement	–	–	NET

MTX, metastasis; iCC, intrahepatic cholangiocarcinoma; NET, neuroendocrine tumor; AFP, alpha-fetoprotein; HCV, hepatitis C virus; NAFLD, non-alcoholic fatty liver disease; NHL, non Hodgkin lymphoma.

#### 4. Discussion

This study suggests that the 2010 AASLD recall algorithm for the diagnosis of HCC in cirrhotic patients under surveillance successfully applies also to the diagnosis of a HCC nodule incidentally detected in cirrhotic patients who had never been subjected to abdominal ultrasound previously. Thus we proved a diagnostic hypothesis on which the guidelines left freedom of interpretation and the clinical practice was not uniform. The rates of incidentally detected liver nodules in this study were similar to those previously reported in other geographical areas [14], thus confirming that HCC is the prevalent (70%) liver nodule found in cirrhotics independently on the indications of US examination [9,10,21,22]. At the same time, the relatively higher rates of iCC and secondary tumors in our cohort compared to previous reports [9–11,13,23], probably reflect the enrollment of patients with reasons for US examination other than liver-related diseases, like abdominal pain, anemia, or unexplained weight loss, together with a previous history of non-HCC tumors, more frequently related to iCC or metastatic cancers.

Our finding that non-invasive radiological algorithm of 2010 AASLD recommendations led to a conclusive diagnosis of HCC in half of patients with an incidentally detected tumor, is clinically meaningful, especially considering the increasing incidence of HCC in groups where surveillance is seldom undertaken or less effective (i.e. in patients with NAFLD or alcoholic liver disease) [5,6,24]. While our observations fill a gap of liver societies recommendations restricting the use of non-invasive criteria for HCC diagnosis to patients under surveillance only [9–11], at the same time they comprise with the AGA recommendations that endorse non-invasive criteria for the diagnosis of HCC in patients with risk factors for liver cancer, independently on the uptake of surveillance [14]. In our study, the diagnosis of HCC by the AASLD algorithm based on a single contrast imaging technique was as accurate as that reported in patients under US surveillance, thus confidently reducing the need for FNB procedures by 52%. In our study, in fact, only 58 nodules (eventually decreased to 54 if inhomogeneous hyperenhancing nodules followed by wash out are considered) required a FNB examination, compared to 120 nodules in the scenario where the AASLD criteria are exclusively applied to cirrhotic patients under surveillance. As a matter of fact, the application of our algorithm would result in a trivial rate (1%, a patient with HGDN) of false positive diagnosis – as previously reported – [10,13] where HGDN is a premalignant lesion considered by several specialists worth to be treated with local ablation, as well [25]. It is worth to outline that in previous studies the rates of misdiagnosis of HGDN with CT and MRI scan were higher than in our cohort, reaching approximately

10% [13], thereby fueling the discussion on the cost effectiveness of over treating benign liver lesions that however have a malignant potential. Importantly, in analogy with surveillance studies, we confirmed that the diagnosis of HCC based on "wash-in and wash-out" pattern of the contrast at CT and MRI could confidently separate HCC from iCC nodules and secondary tumors of the liver [26,27]. Moreover, our data confirmed previous studies for iCC, showing the "ring-like hyperenhancement" in arterial phase without wash-out, as a frequent vascular pattern for these tumors also in cirrhotic livers [26,27]. The evaluation of the 120 nodules according to the Li-RADS criteria turned to be feasible and reliable particularly in those nodules with a reference diagnosis of HCC by histology: 71 (85%) HCC nodules were categorized as probably or definitely HCC according to the Li-RADS criteria with only 3 (14%) benign nodules wrongly attributed to this category [18].

The diagnostic accuracy of radiology was suboptimal (64%) in a few patients with a nodule larger than 5 cm compared to patients with smaller lesions. Such a discrepancy may be the consequence of the stringent criteria we adopted, having considered "non-typical" those nodules with an inhomogeneous contrast up-take in the arterial phase. Large HCC nodules may show an inhomogeneous wash-in during the arterial phase of a CT or MRI in consequence of immature vascularization of rapid proliferating tumor cells favoring spontaneous tumor cell necrosis [28]. Thus, a less stringent approach would have lead us to obtain a radiological diagnosis of HCC in three more HCC nodules larger than 5 cm, further reducing the need for histology in nodules characterized by inhomogeneous contrast up-take in the arterial phase with wash-out during the portal-venous phases. In contrast with the vast majority (82%) of 1–2 cm nodules that are detected following surveillance [9,10], only 22 (23%) patients of our cohort had similar small nodules whereas 72 (77%) had larger than 2 cm tumors including 30 (32%) with a nodule equal or larger than 5 cm. Serum AFP had no added diagnostic value even in the setting of patients with larger HCC nodules, in particular those  $\geq 5$  cm, a combination of AFP  $\geq 200$  ng/mL and wash-out resulted in a sensitivity of 8% and a diagnostic accuracy of 34%. Further outlining the greater diagnostic accuracy of CT and MRI with respect to US, 15% of our patients had additional HCC nodules detected by contrast imaging that had escaped detection with US.

The prevalence of HCC nodules was lower (52%) among nodules  $\leq 2$  cm compared to the other size categories with a higher diagnostic accuracy (88%) and a higher NPV (76%) of the typical HCC pattern by imaging techniques, suggesting a lower risk of false negative results. However, considering the risk of delay the diagnosis of small and curable HCC and even of iCC, we suggest an aggressive

diagnostic policy with histological characterization after negative CT-scan and MRI.

As expected, the rate of patients with a single nodule larger than 5 cm in size or with more than 3 nodules larger than 3 cm in size [29], was higher than the prevalence (1%) of de-novo HCC in cirrhotic patients under US-surveillance [23]. All in all, our findings lend indirect support to surveillance as an effective approach to enhance access of cirrhotic patients to curative treatment of HCC [1,2], only 17 (14%) of our patients received curative treatments, compared to 25% of historical series of patients with a HCC detected during surveillance between 1987 and 2001 [30].

We recognize that our study has some limitations. In particular, we have conducted the study in two tertiary level centers with a high quality equipment and interpreted by radiologists dedicated to liver diseases assessment: probably a multicenter study involving less specialized centers is needed to confirm the data we have obtained in terms of specificity and sensitivity.

In conclusion, the accuracy of the 2010 AASLD algorithm for the diagnosis of HCC with a single contrast imaging was validated in cirrhotic patients with a >1 cm nodule detected outside any US surveillance, leading to a significant saving of FNB procedures.

#### Abbreviations

HCC	hepatocellular carcinoma
NAFLD	non-alcoholic fatty liver disease
US	abdominal ultrasound
CT	computed tomography
MRI	magnetic resonance imaging
FNB	fine needle biopsy
AASLD	American Association for the Study of the Liver
AFP	alpha-fetoprotein
HBV	hepatitis B virus
HCV	hepatitis C virus
iCC	intra-hepatic cholangiocarcinoma
HGDN	high grade dysplastic nodules
LGDN	low grade dysplastic nodules

#### Funding

None.

#### Conflict of interest

None relevant to the manuscript.

#### Appendix A. Supplementary data

Supplementary data associated with this article can be found, in the online version, at [doi:10.1016/j.aohep.2018.09.002](https://doi.org/10.1016/j.aohep.2018.09.002).

#### References

- [1] Wu CY, Hsu YC, Ho HJ, Chen YJ, Lee TY, Lin JT. Association between ultrasonography screening and mortality in patients with hepatocellular carcinoma: a nationwide cohort study. *Gut* 2016;65(4):693–701.
- [2] Singal AG, Pillai A, Tiro J. Early detection, curative treatment, and survival rates for hepatocellular carcinoma surveillance in patients with cirrhosis: a meta-analysis. *Ann Intern Med* 2014;161:261–9.
- [3] Bruix J, Sherman M. Management of hepatocellular carcinoma: an update. *Hepatology* 2011;53:1020–2.
- [4] EASL-EORTC clinical practice guidelines: management of hepatocellular carcinoma. *J Hepatol* 2012;56:908–43.
- [5] Davila JA, Morgan RO, Richardson PA, Du XL, McGlynn KA, El-Serag HB. Use of surveillance for hepatocellular carcinoma among patients with cirrhosis in the United States. *Hepatology* 2010;52:132–41.
- [6] Stroffolini T, Trevisani F, Pinzello G, Brunello F, Tommasini MA, Iavarone M, et al. Changing aetiological factors of hepatocellular carcinoma and their potential impact on the effectiveness of surveillance. *Dig Liver Dis* 2011;43:875–80.
- [7] Singal AG, Li X, Tiro J, Kandunoori P, Adams-Huet B, Nehra MS, et al. Racial, social, and clinical determinants of hepatocellular carcinoma surveillance. *Am J Med* 2015;128,90.e1–7.
- [8] Edenvik P, Davidsdottir L, Oksanen A, Isaksson B, Hultcrantz R, Stål P. Application of hepatocellular carcinoma surveillance in a European setting. What can we learn from clinical practice? *Liver Int* 2015;35:1862–71.
- [9] Sangiovanni A, Manini MA, Iavarone M, Romeo R, Forzenigo LV, Fraquelli M, et al. The diagnostic and economic impact of contrast imaging techniques in the diagnosis of small hepatocellular carcinoma in cirrhosis. *Gut* 2010;59:638–44.
- [10] Forner A, Vilana R, Ayuso C, Bianchi L, Solé M, Ayuso JR, et al. Diagnosis of hepatic nodules 20 mm or smaller in cirrhosis: prospective validation of the noninvasive diagnostic criteria for hepatocellular carcinoma. *Hepatology* 2008;47:97–104.
- [11] Leoni S, Piscaglia F, Golfieri R, Camaggi V, Vidili G, Pini P, et al. The impact of vascular and nonvascular findings on the noninvasive diagnosis of small hepatocellular carcinoma based on the EASL and AASLD criteria. *Am J Gastroenterol* 2010;105:599–609.
- [12] Yu NC, Chaudhari V, Raman SS, Lassman C, Tong MJ, Busuttill RW, et al. CT and MRI improve detection of hepatocellular carcinoma, compared with ultrasound alone, in patients with cirrhosis. *Clin Gastroenterol Hepatol* 2011;9:161–7.
- [13] Sersté T, Barrau V, Ozenne V, Vullierme MP, Bedossa P, Farges O, et al. Accuracy and disagreement of CT and MRI for the diagnosis of small hepatocellular carcinoma and dysplastic nodules: role of biopsy. *Hepatology* 2012;55:800–6.
- [14] Marrero JA, Ahn J, Rajender Reddy K, American College of Gastroenterology. ACG clinical guideline: the diagnosis and management of focal liver lesions. *Am J Gastroenterol* 2014;109:1328–47.
- [15] Borzio M, Fornari F, De Sio I, Andriulli A, Terracciano F, Parisi G, et al., EpaHCC Group. Adherence to American Association for the Study of Liver Diseases guidelines for the management of hepatocellular carcinoma: results of an Italian field practice multicenter study. *Future Oncol* 2013;9:283–94.
- [16] Bruix J, Sherman M, Practice Guidelines Committee, American Association for the Study of Liver Diseases. Management of hepatocellular carcinoma. *Hepatology* 2005;42:1208–36.
- [17] Marrero JA, Hussain HK, Nghiem HV, Umar R, Fontana RJ, Lok AS. Improving the prediction of hepatocellular carcinoma in cirrhotic patients with an arterially-enhancing liver mass. *Liver Transpl* 2005;11:281–9.
- [18] Schima W, Heiken J, LI-RADS v2017 for liver nodules: how we read and report. *Cancer Imaging* 2018;18:14.
- [19] International Working Party. Terminology of nodular hepatocellular lesions. *Hepatology* 1995;22:983–93.
- [20] Chalasani N, Younossi Z, Lavine JE, Diehl AM, Brunt EM, Cusi K, et al., American Gastroenterological Association, American Association for the Study of Liver Diseases, American College of Gastroenterology: the diagnosis and management of non-alcoholic fatty liver disease: practice guideline by the American Gastroenterological Association, American Association for the Study of Liver Diseases, and American College of Gastroenterology. *Gastroenterology* 2012;142:1592–609.
- [21] Khalili K, Kim TK, Jang HJ, Haider MA, Khan L, Guindi M, et al. Optimization of imaging diagnosis of 1–2 cm hepatocellular carcinoma: an analysis of diagnostic performance and resource utilization. *J Hepatol* 2011;54:723–8.
- [22] Darnell A, Forner A, Rimola J, Reig M, García-Criado Á, Ayuso C, et al. Liver imaging reporting and data system with MR imaging: evaluation in nodules 20 mm or smaller detected in cirrhosis at screening US. *Radiology* 2015;275:698–707.
- [23] Manini MA, Sangiovanni A, Fornari F, Piscaglia F, Biolato M, Fanigliulo L, et al. Clinical and economical impact of 2010 AASLD guidelines for the diagnosis of hepatocellular carcinoma. *J Hepatol* 2014;60:995–1001.
- [24] Bucci L, Garuti F, Lenzi B, Pecorelli A, Farinati F, Giannini EG, et al. The evolutionary scenario of hepatocellular carcinoma in Italy: an update. *Liver Int* 2017;37:259–70.
- [25] Cho YK, Wook Chung J, Kim Y, Je Cho H, Hyun Yang S. Radiofrequency ablation of high-grade dysplastic nodules. *Hepatology* 2011;54:2005–11.
- [26] Rimola J, Forner A, Reig M, Vilana R, de Lope CR, Ayuso C, et al. Cholangiocarcinoma in cirrhosis: absence of contrast washout in delayed phases by magnetic resonance imaging avoids misdiagnosis of hepatocellular carcinoma. *Hepatology* 2009;50:791–8.
- [27] Iavarone M, Piscaglia F, Vavassori S, Galassi M, Sangiovanni A, Venerandi L, et al. Contrast enhanced CT-scan to diagnose intrahepatic cholangiocarcinoma in patients with cirrhosis. *J Hepatol* 2013;58:1188–93.
- [28] Asayama Y, Yoshimitsu K, Nishihara Y, Irie H, Aishima S, Taketomi A, et al. Arterial blood supply of hepatocellular carcinoma and histologic grading: radiologic–pathologic correlation. *Am J Roentgenol* 2008;190:28–34.
- [29] Mazzaferro V, Regalia E, Doci R, Andreola S, Pulvirenti A, Bozzetti F, et al. Liver transplantation for the treatment of small hepatocellular carcinomas in patients with cirrhosis. *N Engl J Med* 1996;334:693–9.
- [30] Sangiovanni A, Prati GM, Fasani P, Ronchi G, Romeo R, Manini M, et al. The natural history of compensated cirrhosis due to hepatitis C virus: a 17-year cohort study of 214 patients. *Hepatology* 2006;43:1303–10.