

Trans-arterial ⁹⁰yttrium radioembolization for patients with unresectable tumors originating from the biliary tree

Joost W. Wijlemans,* Karel J. Van Erpecum,** Marnix G.E.H. Lam,*** Beatrijs A. Seinstra,*
Maarten L.J. Smits,* Bernard A. Zonnenberg,*** Maurice A.A.J. Van Den Bosch*

* Department of Radiology, University Medical Center Utrecht, The Netherlands.

** Department of Gastroenterology and Hepatology, University Medical Center Utrecht, The Netherlands.

*** Department of Nuclear Medicine, University Medical Center Utrecht, The Netherlands.

ABSTRACT

Patients with malignant tumors originating from the biliary tree have a poor prognosis, since only a minority of tumors can be resected and most palliative regimens have shown only limited success. We present two patients with unresectable tumors, who were treated with trans-arterial ⁹⁰yttrium radioembolization: a patient with an infiltrating gallbladder carcinoma and a patient with an extensive intrahepatic cholangiocarcinoma. In both cases the treatment was technically feasible, effective in controlling tumor growth, and without significant side effects. In conclusion, the presented cases demonstrate the potential of ⁹⁰yttrium radioembolization as a palliative treatment option for malignant tumors of the biliary tree.

Key words. Intrahepatic cholangiocarcinoma. Gallbladder carcinoma. ⁹⁰yttrium radioembolization.

WHAT WAS KNOWN ON THIS TOPIC?

⁹⁰yttrium radioembolization has been investigated mainly for treatment of HCC and secondary liver tumors. So far, little is known on treatment of tumors originating from the gallbladder with radioembolization. Two publications describe treatment of a small series of patients with an intrahepatic cholangiocarcinoma.

WHAT DOES THIS CASE ADD?

The two presented cases show the feasibility and potential of ⁹⁰yttrium radioembolization as palliative treatment option for locally advanced gallbladder carcinoma and inoperable, extensive intrahepatic cholangiocarcinoma.

INTRODUCTION

Malignant tumors of the biliary tract originate from the bile duct epithelium or from the epithelium

lining the gallbladder. Although intrahepatic cholangiocarcinomas (ICC), extrahepatic cholangiocarcinomas (ECC) and gallbladder carcinoma are pathologically and clinically different entities, they share one important characteristic: they generally have a grim prognosis, mostly due to their late presentation.¹⁻³

Surgical resection is the only curative treatment option. Unfortunately, only 10-40% of all patients can be considered for surgery.²⁻⁴ For non-surgical patients the 5-year survival rate for cholangiocarcinoma and gallbladder carcinoma is poor, and in general less than 5%.⁵⁻⁸ Due to co-morbidities, unresectable or metastatic disease, palliative therapies are the only option for most patients with malignant tumors of the biliary tract.^{1,6} Palliative treatment with systemic chemotherapy has had limited success, with partial response rates ranging from 20-40%.^{9,10}

External beam radiation therapy for cholangiocarcinomas has demonstrated a modest survival benefit (11 months vs. 6 months for surgery alone), but only after surgery.¹¹ Studies examining radiotherapy in gallbladder carcinoma have shown ambiguous results, but there may be a slight survival benefit with this treatment modality.¹²

A developing palliative strategy for cholangiocarcinoma is Photodynamic Therapy (PDT), which is used combined with biliary stenting. It uses a photo-

Correspondence and reprint request: Maurice A.A.J. van den Bosch, MD, PhD
Department of Radiology, Room E.01.132, University Medical Center Utrecht
Heidelberglaan 100, 3584 CX Utrecht, The Netherlands
Ph.: +3188-7556687, Fax: +3130-3581098
E-mail: mbosch@umcutrecht.nl

Manuscript received: November 01, 2010.

Manuscript accepted: December 28, 2010.

sensitizing agent that preferentially concentrates in malignant cells. Endoscopically delivered light of specific wave lengths activates the agent, which achieves tumor cell necrosis with a penetration depth of 4-6 mm. This provides a survival benefit along with a quality of life benefit (493 days for PDT plus stenting vs. 98 days for stenting alone).³ Lastly, an important issue in the palliative setting is the prevention of cholestasis, a major cause of morbidity in these patients, which can cause jaundice, pruritus, pain, cholangitis and cholestatic liver failure.⁶ Biliary drainage is preferably performed endoscopically, but can also be performed percutaneously or surgically.^{13,14}

Tumors originating from the biliary tree are primarily vascularized by the hepatic artery, while hepatocytes are primarily supplied by the portal vein.^{15,16} This provides the rationale for trans-arterial delivery of anti-tumor agents, allowing selective biliary tumor targeting with few systemic effects. In recent years, trans-arterial chemoembolization (TACE) has shown to improve median survival of patients with unresectable ICC from 5-12 months to 13-23 months.¹⁷⁻¹⁹

More recently, trans-arterial radioembolization (TARE) with ⁹⁰yttrium microspheres has become available for treatment of both primary and secondary liver malignancies.^{20,21} Radioembolization implements trans-arterial administration of microspheres, based on either glass (Theraspheres, MDS Nordion, Ottawa, Ontario, Canada) or resin (SIR-Spheres®; SIRTeX Medical Ltd., Sydney, Australia). These microspheres are charged with ⁹⁰yttrium, a β -emitting isotope, delivering selective internal radiation to the tumor, while exposure of healthy liver parenchyma is limited.¹⁵ In this case report we present two cases of ⁹⁰yttrium radioembolization for treatment of a tumor originating from the biliary tree.

CASE 1

The first patient presented as a 66-year old male, diagnosed with a gallbladder carcinoma with infiltration into the liver parenchyma (Figure 1). He had no clinical signs of the presence of a malignancy; the tumor was discovered during a routine laparoscopic cholecystectomy which was indicated by colic pains, diagnosed as cholelithiasis. The patient's ECOG performance score was 1.

Histopathologic examination of liver and gallbladder tissue obtained at incision biopsy showed a moderately-differentiated adenocarcinoma, which was unresectable because of technical reasons.

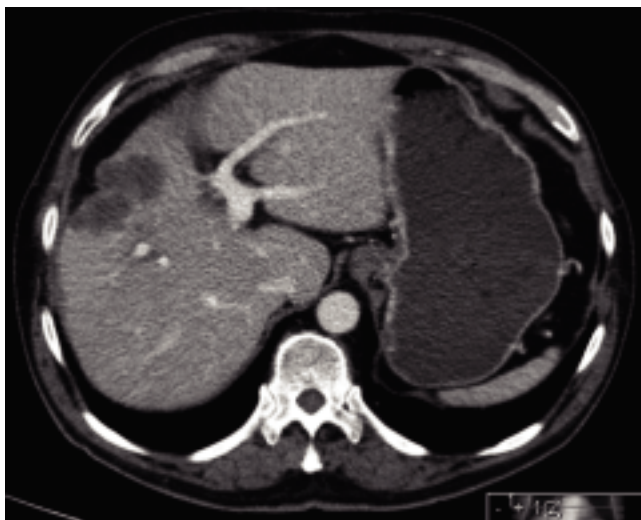


Figure 1. CT image in porto-venous phase showing the gallbladder carcinoma, growing from the gallbladder bed in cranial direction into the liver parenchyma (segment 4a).

No additional treatments such as systemic chemotherapy or external beam radiotherapy were performed.

Work-up before radioembolization included full blood count, liver biochemistry tests, tumor markers, CT scan of thorax and abdomen, and an MRI scan of the liver. The baseline liver biochemistry tests showed, apart from a slightly elevated γ -glutamyltransferase (53 U/L), no abnormalities. The serum cancer antigen 19-9 (CA19-9) level was 220 U/mL and carcinoembryonic antigen (CEA) level was 3.7 μ g/L. A four-phase contrast-enhanced CT scan showed a tumor of 56 mm in segment 4a of the liver without contrast enhancement.

In compliance with the Dutch Act on Medical Treatment Agreements, the patient orally consented to the off-label use of the ⁹⁰yttrium microspheres. Prior to radioembolization with ⁹⁰yttrium microspheres, the patient underwent pre-treatment angiography for mapping of the visceral vasculature, embolization of non-target vessels and injection of Technetium-99m-labelled MacroAggregated Albumin (^{99m}Tc-MAA). CT and angiography showed a normal visceral anatomy, and on SPECT imaging, the ^{99m}Tc-MAA (used to predict the distribution of the ⁹⁰yttrium microspheres) showed a high uptake within the tumor and no extra-hepatic deposits (Figure 2). Two weeks after the MAA procedure, 951 MBq of ⁹⁰yttrium microspheres (SIR-Spheres) were injected into the common hepatic artery. No complications occurred and the patient reported no side effects.

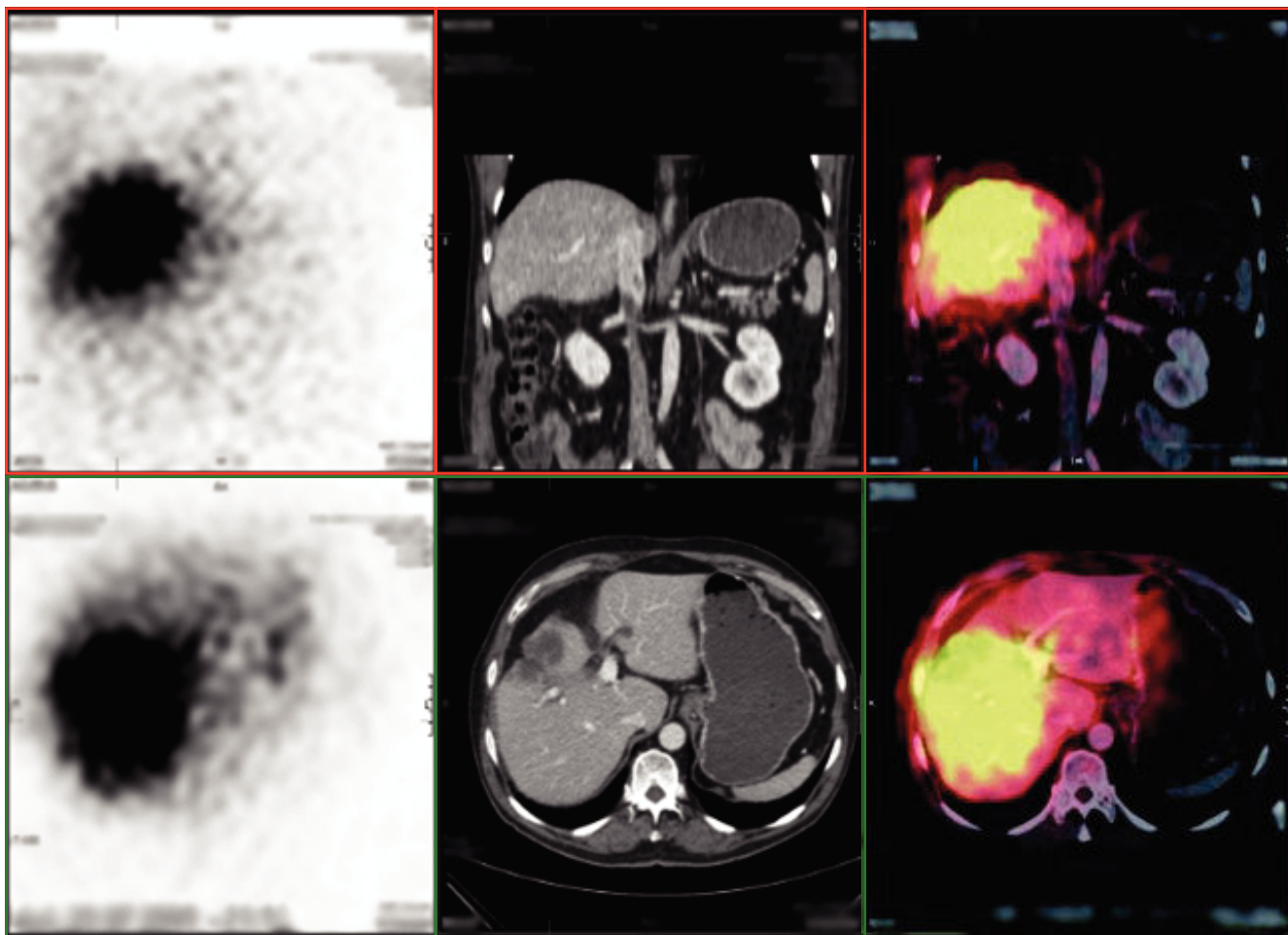


Figure 2. SPECT image, showing the distribution of ^{99m}Tc -MAA, which is used to predict the distribution of the $^{90}\text{yttrium}$ microspheres.

The six weeks follow-up CT scan showed stable disease according to the RECIST 1.1 criteria (largest diameter 52 mm) (Figure 3). The EASL criteria, which additionally assess absence of contrast-enhancement due to necrosis, were not used since these apply to hypervascular tumors such as hepatocellular carcinoma on MRI.^{22,23} Five months after treatment, CT scanning showed stable disease (tumor diameter 51 mm). Liver biochemistry tests showed, apart from a minor increase in γ -glutamyl-transferase (to 122 U/L), no significant changes. Tumor marker CA 19.9 had decreased to 46 U/mL, whereas CEA remained stable.

At that time, the clinical condition of the patient had remained acceptable, with an ECOG performance score of 1. No additional treatments were performed. However, the nine months follow-up CT scan showed progressive disease (tumor diameter 73 mm)

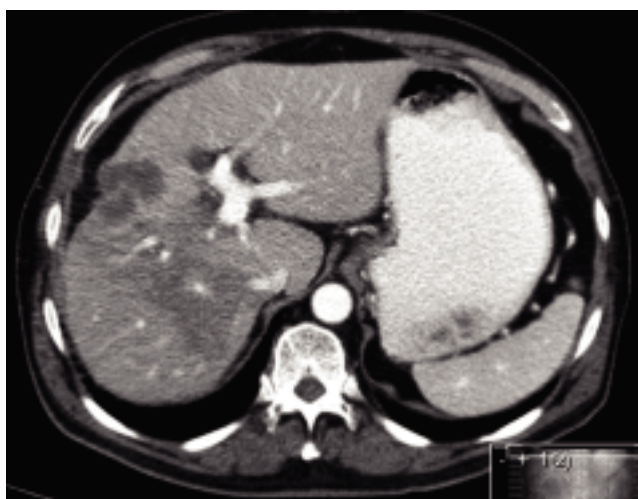


Figure 3. Six weeks follow-up CT image, showing stable disease according to the RECIST 1.1 criteria.

with intrusion into the liver capsule and a new liver metastasis. Unfortunately, soon hereafter the patient was lost from our follow-up program.

CASE 2

This was a 60 year-old male with a large intrahepatic cholangiocarcinoma. His main complaints were fatigue and weight loss; his general condition was moderate with an (ECOG) performance score of 1. Physical examination showed a slight jaundice and a liver that extended 8 cm under the ribs. Baseline liver function tests showed a raised total bilirubin ($110 \mu\text{mol/L}$), γ -glutamyltransferase (948 U/L) and alkaline phosphatase (555 U/L). A four-phase contrast-enhanced MRI of the liver showed a lesion suspect for cholangiocarcinoma measuring 146 x 130 x 109 mm in size (Figure 4). Large-core needle biopsy confirmed the diagnosis intrahepatic cholangiocarcinoma (tumor stage T3N1M0). Due to the infiltrative growth pattern of the tumor surgical resection was not feasible.

The patient underwent a pre-treatment angiography with injection of $^{99\text{m}}\text{Tc-MAA}$. There was a normal visceral anatomy and the tumor was supplied by both the right and left hepatic artery. No extra-hepatic deposits were detected with SPECT imaging. Although there was some shunting to the lungs (18% on the right and 9% on the left), a dose reduction was not needed since the maximum allowable radiation dose for the lungs (600 MBq) would not be reached.

Because of the large tumor size, treatment was planned in two phases, starting with the left hepatic artery (386 MBq), followed by the right hepatic artery two weeks later (1789 MBq). The

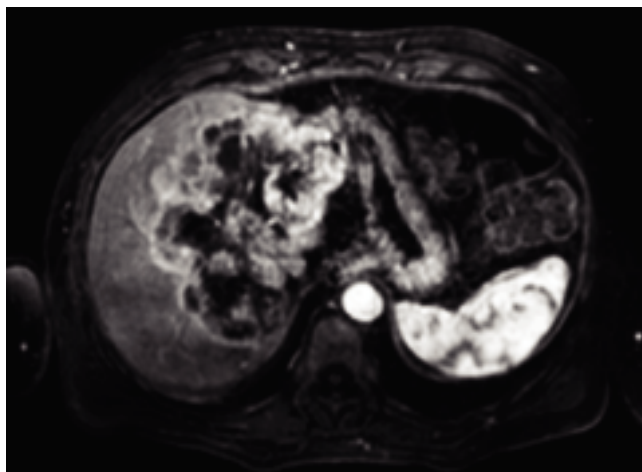


Figure 4. Contrast-enhanced MRI of the liver showing the intrahepatic cholangiocarcinoma (before treatment).

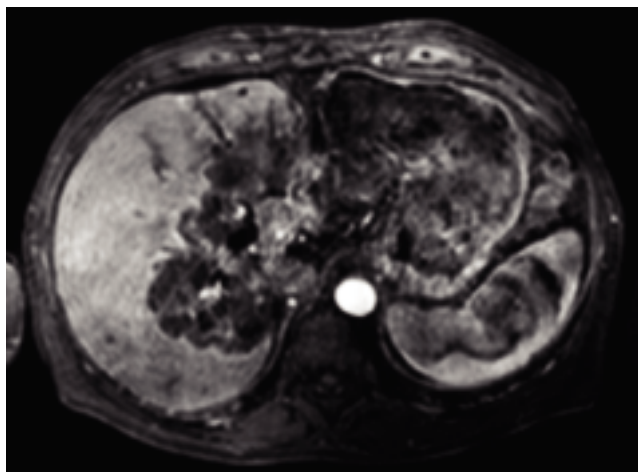


Figure 5. Contrast-enhanced MRI of the liver with the intrahepatic cholangiocarcinoma (three months after treatment), showing partial response according to the EASL criteria.

only reported side effect was a self-limiting fatigue for 5 days.

The one month follow-up MRI scan showed stable disease according to both RECIST 1.1 and EASL criteria. At three months, the maximum tumor diameter had decreased from 150 to 120 mm on MRI. When using the RECIST 1.1 criteria, this corresponds to stable disease. However, since there was extensive intra-tumoral necrosis (absence of contrast enhancement on MRI), the EASL criteria classify this as partial response (Figure 5).

Seven months after treatment, MRI showed stable disease compared to the 3-month follow-up scan. Liver function tests showed a slight increase in total bilirubin (to $143 \mu\text{mol/L}$), γ -glutamyltransferase (to 1410 U/L) and alkaline phosphatase (to 1041 U/L).

The patient's clinical condition was, apart from a mild jaundice, satisfactory. No additional treatments were performed and follow-up and supportive care was continued at our out-patient clinic. The patient died due to local progressive disease nearly two years after the initial radioembolization.

DISCUSSION

These cases suggest that both inoperable gallbladder carcinoma and intrahepatic cholangiocarcinoma can be safely treated with trans-arterial $^{90}\text{yttrium}$ radioembolization. The first presented case suggests that $^{90}\text{yttrium}$ radioembolization can be a feasible palliative treatment option for patients with locally advanced gallbladder carcinoma.

Generally, the survival prognosis for gallbladder carcinoma patients is grim (9.2 months), although patients with an incidentally discovered gallbladder carcinomas have a somewhat better survival (26.5 months).⁸ Conventional palliative treatment regimens have had limited success in the past.^{2,8} To our best knowledge there are no published studies that focus on the outcome of ⁹⁰yttrium radioembolization for treatment of patients with gallbladder carcinoma infiltrating into the liver. During the ten months follow-up, the presented patient remained in acceptable condition. Although to the end he suffered from fatigue and recurrent pain in the right upper quadrant, this rarely limited his daily activities. Unfortunately the patient was lost to follow-up after the confirmation of local progressive disease.

The second presented case demonstrates an intrahepatic cholangiocarcinoma as large as 15 cm in diameter that has been controlled successfully by radioembolization. This treatment modality also contributed to prolonged survival of the patient, who was provided with a prognosis of 4-6 weeks by the referring oncologist. For a considerable time, his quality of life was preserved and he even worked part-time, before he began to suffer from fatigue and, during his last weeks, from ascites. He succumbed to local progressive disease, nearly two year after the initial reference to our hospital. Considering the abysmal prognosis of non-surgical intrahepatic cholangiocarcinoma patients (the overall 1-year survival is 27.6%, and is probably much lower for non-surgical patients⁵), these results are very promising, and might lead the way to an established palliative treatment option for non-surgical candidates.

Two other groups have reported on the outcome of ⁹⁰yttrium radioembolization for treatment of ICC. Saxena, *et al.*,²⁴ treated 25 patients; all patients had a non-resectable intrahepatic cholangiocarcinoma (60% peripheral tumors, 40% infiltrative tumors). For 23 patients the RECIST-score was determined. A partial response was observed in 6 patients (24%), stable disease in 11 patients (48%), and progressive disease in 5 patients (20%). The median survival after treatment was 8.1 months for all patients. Prognostic factors were tumor type (median survival of 18.3 months in patients with peripheral tumor type vs. 4.5 months in patients with an infiltrative tumor) and ECOG performance score (18.3 months survival in patients with an ECOG score of 0 vs. 2.4 months in patients with an ECOG score \geq 1).

Ibrahim, *et al.* treated 24 patients with ICC during a 4-year period.²⁵ Eight patients had limited ex-

trahepatic metastases; the rest had disease confined to the liver. Median survival was stratified by ECOG performance score and was 31.8 months for ECOG 0 patients, 6.1 months for ECOG 1 patients, and 1 month for ECOG 2 patients. The authors conclude that ⁹⁰yttrium radioembolization appears to be safe and effective in selected patients, although survival benefits highly depend on baseline characteristics such as tumor morphology, the presence of cancer-related symptoms and general condition of the patient.

CONCLUSION

The in this paper presented cases show the feasibility and potential of ⁹⁰yttrium radioembolization as a palliative treatment option for patients with tumors originating from the biliary tree. Considering the abysmal prognosis of these patients and the limited effectiveness of current palliative treatments options, further investigation into this topic is indicated.

REFERENCES

1. Khan SA, Thomas HC, Davidson BR, Taylor-Robinson SD. Cholangiocarcinoma. *Lancet* 2005; 366: 1303-14.
2. Misra S, Chaturvedi A, Misra NC, Sharma ID. Carcinoma of the gallbladder. *Lancet Oncol* 2003; 4: 167-76.
3. Ortner MA. Photodynamic therapy for cholangiocarcinoma: Overview and new developments. *Current Opinion in Gastroenterol* 2009; 25: 472-6.
4. Khan SA, Davidson BR, Goldin R, Pereira SP, Rosenberg WM, Taylor-Robinson SD, Thillainayagam AV, et al. Guidelines for the diagnosis and treatment of cholangiocarcinoma: Consensus document. *Gut* 2002; 51(Suppl. 6):V11-V19.
5. Shaib Y, El-Serag HB. The epidemiology of cholangiocarcinoma. *Seminars in Liver Dis* 2004; 24: 115-25.
6. Aljiffry M, Walsh MJ, Molinari M. Advances in diagnosis, treatment and palliation of cholangiocarcinoma: 1990-2009. *World J Gastroenterol* 2009; 15: 4240-62.
7. DeOliveira ML, Cunningham SC, Cameron JL, Kamangar F, Winter JM, Lillmoie KD, Choti MA, et al. Cholangiocarcinoma: Thirty-one-year experience with 564 patients at a single institution. *Ann Surg* 2007; 245: 755-62.
8. Gourgiotis S, Kocher HM, Solaini L, Yarollahi A, Tsiambas E, Salemis NS. Gallbladder cancer. *Am J Surg* 2008; 196: 252-64.
9. Nehls O, Klump B, Arkenauer HT, Hass HG, Greschniok A, Gregor M, Porschen R. Oxaliplatin, fluorouracil and leucovorin for advanced biliary system adenocarcinomas: A prospective phase II trial. *British J Cancer* 2002; 87: 702-4.
10. Papakostas P, Kouroussis C, Androulakis N, Samelis G, Aravantinos G, Kalbakis K, Sarra E, et al. First-line chemotherapy with docetaxel for unresectable or metastatic carcinoma of the biliary tract. A multicentre phase II study. *European J Cancer* 2001; 37: 1833-8.
11. Shinohara ET, Mitra N, Guo M, Metz JM. Radiation therapy is associated with improved survival in the adjuvant and definitive treatment of intrahepatic cholangiocarcinoma. *International J Radiation Oncol, Biol, Physics* 2008; 72: 1495-501.

12. Houry S, Haccart V, Huguier M, Schlienger M. Gallbladder cancer: role of radiation therapy. *Hepatogastroenterology* 1999; 46: 1578-84.
13. Abu-Hamda EM, Baron TH. Endoscopic management of cholangiocarcinoma. *Seminars in Liver Dis* 2004; 24: 165-75.
14. Misra S, Chaturvedi A, Misra NC, Sharma ID. Carcinoma of the gallbladder. *Lancet Oncol* 2003; 4: 167-76.
15. Bilbao JI, Reiser MF. Liver radioembolization with Y-90 microspheres. Berlin: Heidelberg; 2008.
16. Buscombe JR. Interventional nuclear medicine in hepatocellular carcinoma and other tumours. *Nuclear Med Communications* 2002; 23: 837-41.
17. Aliberti C, Benea G, Tilli M, Fiorentini G. Chemoembolization (TACE) of unresectable intrahepatic cholangiocarcinoma with slow-release doxorubicin-eluting beads: Preliminary results. *Cardiovasc and Intervent Radiol* 2008; 31: 883-8.
18. Gusani NJ, Balaa FK, Steel JL, Geller DA, Marsh JW, Zajko AB, Carr BI, et al. Treatment of unresectable cholangiocarcinoma with gemcitabine-based transcatheter arterial chemoembolization (TACE): A single-institution experience. *J Gastrointestinal Surg* 2008; 12: 129-37.
19. Burger I, Hong K, Schulick R, Georgiades C, Thuluvath P, Choti M, Kamel I, et al. Transcatheter arterial chemoembolization in unresectable cholangiocarcinoma: Initial experience in a single institution. *J Vasc Intervent Radiol* 2005; 16: 353-61.
20. Vente MA, Wondergem M, van der Tweel I, van den Bosch MA, Zonnenberg BA, Lam MG, van het Schip AD, et al. Yttrium-90 microsphere radioembolization for the treatment of liver malignancies: A structured meta-analysis. *European Radiol* 2009; 19: 951-9.
21. Salem R, Thurston KG. Radioembolization with yttrium-90 microspheres: A state-of-the-art brachytherapy treatment for primary and secondary liver malignancies: Part 3: Comprehensive literature review and future direction. *J Vasc Intervent Radiol* 2006; 17: 1571-93.
22. Eisenhauer EA, Therasse P, Bogaerts J, Schwartz LH, Sargent D, Ford R, Dancey J, et al. New response evaluation criteria in solid tumours: Revised RECIST guideline (version 1.1). *European J Cancer* 2009; 45: 228-47.
23. Bruix J, Sherman M, Llovet JM, Beaugrand M, Lencioni R, Burroughs AK, Christensen E, et al. Clinical management of hepatocellular carcinoma. Conclusions of the Barcelona-2000 EASL conference. *J Hepatology* 2001; 35: 421-30.
24. Saxena A, Bester L, Chua TC, Chu FC, Morris DL. Yttrium-90 radiotherapy for unresectable intrahepatic cholangiocarcinoma: A preliminary assessment of this novel treatment option. *Ann Surg Oncol* 2010; 17: 484-91.
25. Ibrahim SM, Mulcahy MF, Lewandowski RJ, Sato KT, Ryu RK, Masterson EJ, Newman SB, et al. Treatment of unresectable cholangiocarcinoma using yttrium-90 microspheres: Results from a pilot study. *Cancer* 2008; 113: 2119-28.