

Course of a HBsAg positive liver transplantation in a hepatitis B and D virus coinfecting recipient

Ralf Bahde,* Jens P. Hölzen,* Heiner H. Wolters,* Hartmut H. J. Schmidt,†
C. Thomas Bock,‡ Andreas Lügering,§ Tilmann Speiker,|| Norbert Senninger,* Jens G. Brockmann*

* Department of General and Visceral Surgery, University Hospital of Muenster, Muenster, Germany.

† Klinik und Poliklinik für Transplantationsmedizin, University Hospital of Muenster, Muenster, Germany.

‡ Department of Molecular Pathology, Institute of Pathology, University Hospital of Tuebingen, Tuebingen, Germany.

§ Department of Medicine B, University Hospital of Muenster, Muenster, Germany.

|| Gerhard-Domagk Institute of Pathology, University Hospital of Muenster, Muenster, Germany.

ABSTRACT

The increasing demand for transplantation has led to consideration of liver grafts from donors exposed to hepatitis B virus (HBV). Six transplantations of liver grafts from hepatitis B surface antigen (HBsAg) positive donors have been reported; two recipients suffered from HBV/HDV (hepatitis Delta virus) coinfection and were followed up for 10-12 months. Here, we report a 56 months follow-up of a HBV/HDV-coinfecting recipient of a HBsAg positive liver graft. Posttransplant combination prophylaxis consisted of hepatitis immunoglobulin, lamivudine and adefovir dipivoxil. HBsAg remained positive during stable posttransplant follow-up and subclinical HDV reinfection with low replication rate was detected at 1 month. Pegylated interferon therapy was introduced after documentation of histological evidence of mild chronic hepatitis, but without virological response after 48 weeks. Finally, antiviral treatment was switched to tenofovir disoproxil fumarate. More than 50 months posttransplant the recipient revealed clinical symptoms of decompensated liver cirrhosis and has been relisted for liver transplantation. In conclusion HBsAg positive liver grafts in HBsAg positive recipients with HDV coinfection may result in virological recurrence and rapid development of liver cirrhosis.

Key words. Liver transplantation. Hepatitis B. Hepatitis D.

INTRODUCTION

The shortage of organ donors extended waiting lists and increased morbidity and mortality during the waiting period has led to the acceptance of marginal grafts for liver transplantation. The allocation of hepatitis B core antibody (anti-HBc) positive livers preferentially in recipients with previous exposure to hepatitis B virus (HBV) has been increasingly applied. To prevent the associated risk of hepatitis B reactivation in the allograft many centers provide an-

tiviral and/or hepatitis B immunoglobulin (HBIG) prophylaxis to the recipient.¹ Using antiviral prophylaxis such as lamivudine or adefovir dipivoxil even grafts from hepatitis B surface antigen (HBsAg) carriers without significant liver disease have been considered for HBsAg positive recipients. Six transplantations of HBsAg positive liver grafts have been reported; in two cases the recipients had a HBV/HDV coinfection with prompt postoperative HDV reinfection.²⁻⁵ Hepatitis delta virus (HDV) consists of a single-stranded RNA molecule which is associated with delta antigen. This ribonucleoprotein complex is enveloped by HBsAg. Thereby, HDV is dependent for its life cycle on HBV. The prevalence of HDV varies between different parts of the world. HDV is highly endemic in Mediterranean countries, the Middle East, Central Africa, and northern parts of South America, ranging in some regions to over 27% among chronic HBV carriers.⁶ In Northern-Europe, approximately 7-8.5% of HBsAg carriers are also coinfecting

Correspondence and reprint request: Dr. Hartmut Schmidt
Klinik und Poliklinik für Transplantationsmedizin
University Hospital of Muenster
Domagkstr. 3A, D-48149 Muenster, Germany
Tel.: +49-251-8357770, Fax: +49-251-8357771
E-mail: hepar@ukmuenster.de

Manuscript received: November 08, 2010.

Manuscript accepted: March 08, 2011.

with HDV.⁷ Chronic HDV infections are more severe and progressive than HBV infections alone leading to cirrhosis in about 80% of the cases.^{8,9} The situation is different after transplantation, where HBV/HDV coinfection of the recipient can lead to an ameliorated course of disease.¹⁰ There is evidence that HDV may actually protect against HBV reinfection by inhibiting HBV replication.^{11,12}

In this report, we describe a 56 months follow-up of a patient with HBV/HDV related cirrhosis who underwent liver transplantation receiving a HBsAg-positive donor liver. Furthermore, we discuss this case in reflection to the reported cases, where HBsAg-positive grafts were transplanted.

CASE REPORT

A 45-year-old male patient with a diagnosis of chronic hepatitis B (genotype D) and concurrent hepatitis D-1 infection was admitted to our hospital. The patient had been diagnosed with hepatitis B five years previously and revealed evidence of ascites not responding to antidiuretic treatment, general fatigue, deranged liver function (prothrombin time 47%) and liver cirrhosis child B. He received repeated ligation of his esophageal varices due to repeated acute varical bleeding events. Therefore liver transplantation was urgently indicated, however, this urgency was not sufficiently well reflected in the allocation system. Serum HBV markers were positive for HBsAg, anti-HBs (2 IU/l), anti-HBc IgG, anti-HBe and negative for HBeAg. HBV DNA serum levels were positive but below measurable range. Until then the patient was not treated with any antiviral agent. He was enlisted for liver transplantation in November 2005. To increase the chance of allocating a liver, we received informed consent to accept a HBsAg positive organ in the case of an unremarkable liver histology.

Patient underwent orthotopic liver transplantation using the piggyback technique in January 2006. The transplanted liver was retrieved from a 48-year-old deceased donor with both normal liver enzymes (AST 34 U/l ALT 26 U/l,) and normal prothrombin time (INR 1.01). Donor viral markers were positive for HBsAg and anti-HBc IgG, negative for Anti-HBs. There were no noticeable pathologic changes in donor liver morphology. At the time of liver allocation donor received adefovir prior explant.

During the anhepatic phase of the recipient, 10,000 IU of hepatitis B immunoglobulin (HBIG) was infused. 2,000 IU of HBIG was administered daily for two weeks and then HBIG was conti-

nued for the next 6 month. Combined prophylaxis with lamivudine (100 mg/day) and adefovir dipivoxil (10 mg/day) started on the first day after transplant. Initially, immunosuppression consisted of tacrolimus, mycophenolate mofetil and steroids, but steroids were tapered in the following months. Postoperatively the recipient recovered quickly and he was discharged on day 17 post-transplantation with excellent liver function (bilirubin 0.8 mg/dL, AST 18 IU/l, ALT 55 IU/l, prothrombin time 104%). On day 17 very low levels of HBV DNA (< 50 copies/mL) were retrospectively detected, but disappeared at about the same time HDV reinfection (< 50 copies/mL) was assessed by PCR (day 31). Serum HDV level remained low in subsequent follow-ups. Despite antiviral treatment serum HBsAg was increased compared to preoperative values and reached baseline levels 6 months after transplantation; however serum HBV DNA was negative. Anti-HBsAg was continuously below 10 IU/l, HBeAg negative and Anti-HBe positive. A sudden rise of liver enzymes (AST 645 IU/l, ALT 673 IU/l) and bilirubin (4.7 mg/dL) at 9 months forced a liver biopsy which was negative for HBsAg and HBcAg. Treatment of a cytomegalovirus infection with ganciclovir showed clinical resolution. After 15 and 18 months low levels of HBV DNA (242 and 327 IU/mL, respectively) were detected without evidence of recurrent hepatitis B in liver biopsy. Viral resistance to adefovir dipivoxil (A181V and N236T) or lamivudine (L180M and M204V) by determination of HBV polymerase mutations were excluded. Liver function profiles remained stable and HBV DNA became spontaneously negative again. Two years post-transplantation a routine check-up detected 1.5×10^3 HDV copies/mL serum by quantitative RT-PCR, but there was no evidence of HB viremia. A liver biopsy revealed mild periportal and lobular hepatitis with advanced micronodular cirrhosis (HBcAg positive, HBsAg negative). Due to intermittent leukopenia and the patient's lack of compliance pegylated interferon-alpha2b therapy was delayed. Because viral markers remained unchanged interferon treatment was discontinued after 48 weeks and switched to tenofovir disoproxil fumarate (450 mg/d Viread®, Gilead). However, a biopsy at 45 months showed advanced cirrhosis with chronic transplant hepatitis. More than 50 months posttransplant the patient suffered from decompensated cirrhosis with ascites, portal hypertension, esophageal varices and encephalopathy requiring repeated hospital admittance. The patient was enlisted for liver re-transplantation in June 2010 (MELD 16).

DISCUSSION

We report an almost five year follow-up of liver transplantation for HBV/HDV-related cirrhosis using a HBsAg positive graft. To date, the patient has been enlisted to re-transplantation. HDV recurred and HBsAg persisted under prophylaxis with HBIG, lamivudine and adefovir dipivoxil. Subsequent treatment with interferon and tenofovir did not attenuate disease progression. So far, 6 cases of transplantation of HBsAg positive donor liver grafts have been reported (Table 1).²⁻⁵ In 1994 an emergency transplant of a HBsAg positive donor liver into a HBsAg negative recipient was reported. Despite perioperative HBIG prophylaxis the patient became seropositive, developed chronic active hepatitis B, but showed spontaneous seroconversion after 2 years.² More recently 5 cases were reported from Italy, Korea and Japan. The Japanese and Korean group described a four- and five-year follow-up, respectively, of HBsAg positive patients receiving HBsAg positive living donor liver grafts.^{4,5} Prophylaxis with HBIG, lamivudine, famciclovir or adefovir, respectively, was performed, but serum levels of HBsAg became positive in both cases. Transplantations of HBsAg-positive cadaveric grafts in three HBsAg-positive recipients, two of them with HDV coinfection, were reported from Italy and followed up for 10-13 months. HBIG and lamivudine treatment could not prevent persistence of HBV infection in all patients. Whereas the non-HDV-infected patient showed an uneventful follow-up, in both patients with HBV/HDV coinfection a prompt HDV reinfection was observed. In one of them several hepatitis flares occurred, but HDV RNA became negative at 9 months. The other patient developed chronic hepatitis with ascitic decompensation requiring retransplantation at 10 months.³

Antiviral prophylaxis with HBIG failed to prevent posttransplant HBsAg positivity in all HBsAg positive recipients. Suppression of HBsAg production is a crucial factor in prevention of hepatitis D recurrence. Consequently, hepatitis D reinfection was seen in all reported patients with HBV/HDV coinfection including our case. HBsAg reappearance after liver transplantation of "healthy" (HBsAg negative) grafts in HBV/HDV patients with cirrhosis who received long-term HBIG is low.¹³ A European multicenter study in patients with HDV cirrhosis showed that the rate of HBV recurrence was 70, 56, and 17% in patients receiving no immunoprophylaxis, short-term immunoprophylaxis and long-term immunoprophylaxis, respectively.¹¹ Accordingly, Samuel et al. reported that only in 10.3% of patients receiving HBs immunoprophylaxis HBsAg reappeared after a mean of 39 ± 17 months, but was associated with HBV and HDV reactivation. A possible relationship with the initial amount of immunoglobulins administered was suggested.¹⁴ Studies reporting low recurrence rates aimed to maintain anti-HBs titers ranging from 50 to 200 IU/mL.^{11,15,16} In the present case HBsAg was elevated in the first six months posttransplant and anti-HBs below therapeutic range despite similar HBIG dosing regimen (Figure 1). Adaption of HBIG dosage to anti-HBs titers was not performed and could have resulted in better outcome. Immunoglobulins were suspended after 6 month due to the lack of their neutralizing effect. On the other hand, low-dose intramuscular (i.m.) HBIG (400 or 800 IU i.m. daily for 1 week and monthly thereafter) and lamivudine regimen for prophylaxis against HBV recurrence have been well established.^{17,18} Actually, Angus et al. reported that switching hepatitis B prophylaxis to adefovir plus lamivudine at 12 months posttransplantation in patients receiving low-dose i.m. HBIG plus lamivudine

Table 1. Previously published cases of liver transplantation (LT) using a hepatitis B surface antigen (HBsAg) positive graft.

Reference	Recipient's HBV/HDV status	Donor liver graft	Follow-up	HBV prophylaxis		Outcome			Status
						HBsAg	HBV DNA	HDV RNA	
Gonzalez-Peralta 1994 Franchello 2005	-	Deceased	2 yrs	HBIG + cipro	Post-op:	+	+		Alive
	HBV/HDV	Deceased	12 m	HBIG + lam	2 yrs:	-	-		
					post-op:	+	+		
					12 m:	+	-	+	
HBV/HDV HBV	Deceased	10 m	13 m	HBIG + lam HBIG + lam + adv	post-op:	+	+	+	Alive (re-LT)
					post-op:	+	+		
Hwang 2006	HBV	Living	5 yrs	HBIG + lam + fam/adv	13 m:	+	-		Alive
					post-op:	+	+		
Soejima 2007	HBV	Living	4 yrs	HBIG + lam + adv	5 yrs:	+	-		Alive
					post-op:	+	-		
					4 yrs:	+	-		Alive

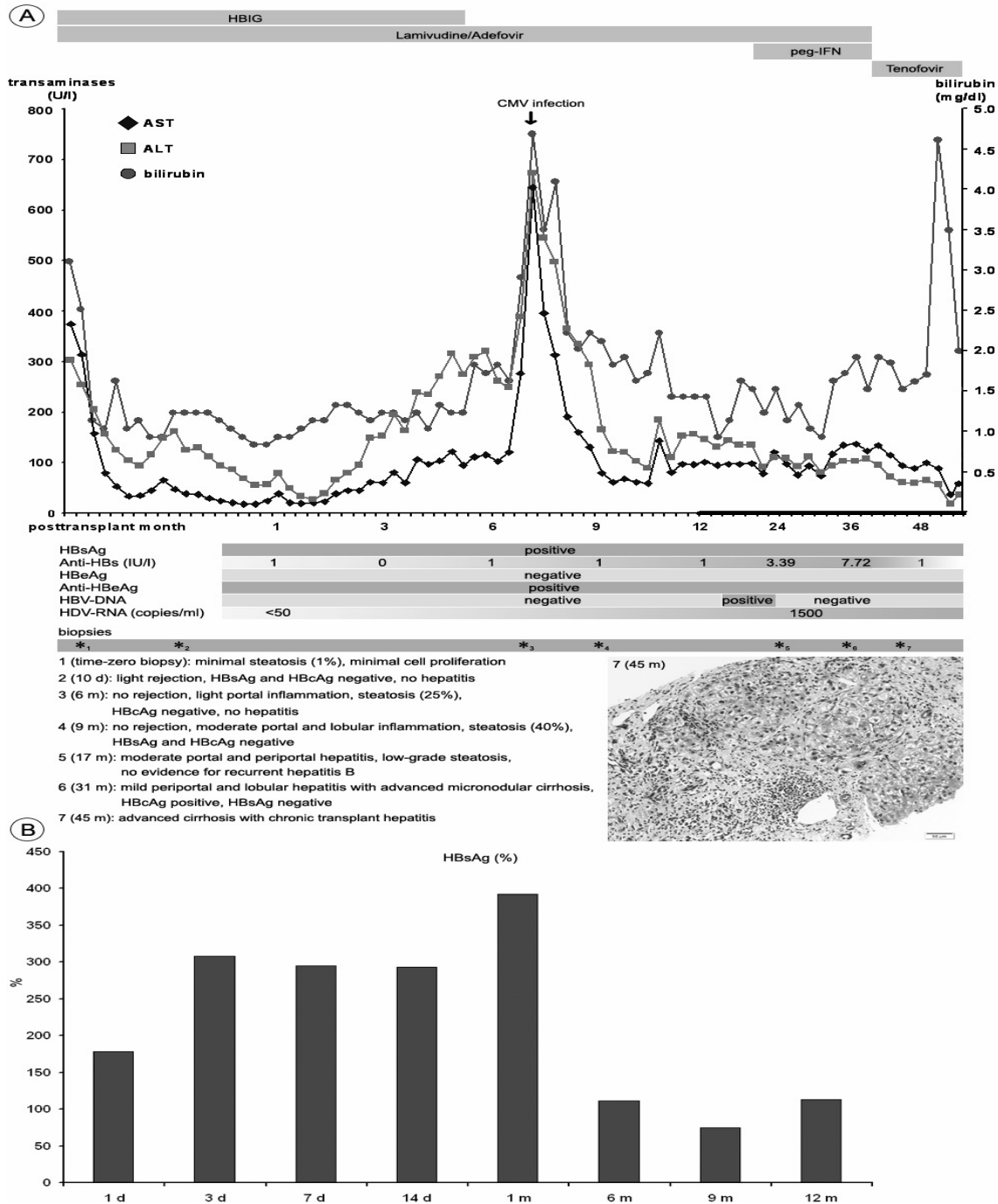


Figure 1. A. Clinical sequence after transplantation of a HBsAg positive liver into a patient with HBV/HDV related cirrhosis. Time course of antiviral treatment with hepatitis B immunoglobulin (HBIG), lamivudine, adefovir dipivoxil, pegylated interferon (peg-IFN) and tenofovir is illustrated at the top. Below, serum parameters of liver function showed one episode of deterioration with an increase of aspartate aminotransferase (AST), alanine aminotransferase (ALT) and total bilirubin at 8 months, which was attributed to a cytomegalovirus (CMV) infection and successfully treated with ganciclovir. Biopsy revealed advanced cirrhosis 45 months after transplantation (lower right panel: Masson-Goldner staining); clinical signs of decompensated cirrhosis with elevated bilirubin levels were most evident at 52 months. During follow-up hepatitis B surface antigen (HBsAg) was continuously positive and HBs antibodies (Anti-HBs) below therapeutic range. Hepatitis B virus (HBV) DNA became positive with low values at 15-18 months (242-327 IU/mL), hepatitis delta virus (HDV) RNA was detected at 1 month. Further abbreviations: hepatitis B envelope antigen (HBeAg), HBeAg antibodies (Anti-HBeAg), day (d), month (m) **B.** Time course of serum HBsAg (in % of pretransplant values).

provided equivalent protection compared with continuation of therapy.¹⁵ We performed a combined prophylaxis with lamivudine and adefovir to prevent escape mutants and hepatitis B recurrence. HBV DNA was continuously negative, except for one episode which might be due to overimmunosuppression. Unfortunately, nucleoside analogues that potently suppress HBV replication have no or little effect on HDV replication.¹⁹ In contrast to nucleoside analogues interferon showed more promising results in clinical studies. A sustained virological response in 17-43 % of non-immunocompromised patients with chronic hepatitis D was reported.^{20,21} In our case interferon therapy was introduced after detection of a considerable level of HDV replication and a histological pattern of mild chronic hepatitis, but did not show any beneficial effect and was therefore discontinued. Modern HBV inhibitors such as tenofovir are much more effective than lamivudine and adefovir and offer therapeutic options, especially in patients who failed to improve with other nucleoside analogues.^{22,23} Treatment at an earlier time point or tenofovir combined with interferon could have been more effective in our case.²⁴

In conclusion, our observation revealed that a HBV/HDV positive recipient of an HBsAg-positive liver graft may maintain liver function for several years, but may suffer from reinfection with rapid development of cirrhosis. Adaption of HBIG dosage according to anti-HBs levels might have resulted in better outcome. Since there was no sufficient anti-HBs level, the infection of the transplant by circulating residual HDV could not be prevented. Further evaluation of anti-HBV/HDV prophylaxis schemes is required. So far, efficiency of therapy for HDV is still limited. Novel HDV inhibitors such as prenylation inhibitors, which experimentally obtained results have been encouraging, may open further perspectives for treatment in such cases.²⁵ At the moment candidates on the waiting list with HBV infection without HDV coinfection should be considered with priority when a HBsAg positive graft is available as HBV can be better controlled nowadays than HDV.

ABBREVIATIONS

- **HBV:** Hepatitis B virus.
- **HDV:** Hepatitis D virus.
- **HBIG:** Hepatitis immunoglobulin.
- **lam:** Lamivudine.
- **adv:** Adefovir dipivoxil.
- **fam:** Famciclovir.
- **cipro:** Ciprofloxacin.

- **yrs:** Years.
- **m:** Month.
- **d:** Day.

REFERENCES

1. Perrillo R. Hepatitis B virus prevention strategies for antibody to hepatitis B core antigen-positive liver donation: A survey of North American, European, and Asian-Pacific transplant programs. *Liver Transpl* 2009; 15: 223-32.
2. Gonzalez-Peralta RP, Andres JM, Tung FY, Fang JW, Brunson ME, Davis GL, Lau JY. Transplantation of a hepatitis B surface antigen-positive donor liver into a hepatitis B virus-negative recipient. *Transplantation* 1994; 58: 114-16.
3. Franchello A, Ghisetti V, Marzano A, Romagnoli R, Salizzoni M. Transplantation of hepatitis B surface antigen-positive livers into hepatitis B virus-positive recipients and the role of hepatitis delta coinfection. *Liver Transpl* 2005; 11: 922-8.
4. Hwang SH, Lee SG, Park KM, Kim KH, Ahn CS, Oh HB, Moon DB, et al. Five-year follow-up of a hepatitis B virus-positive recipient of a hepatitis B surface antigen-positive living donor liver graft. *Liver Transpl* 2006; 12: 993-7.
5. Soejima Y, Shimada M, Taketomi A, Yoshizumi T, Uchiyama H, Ikegami T, Nakamura M, et al. Successful living donor liver transplantation using a graft from a hepatitis B surface antigen-positive donor. *Liver Int* 2007; 27: 1282-6.
6. Wedemeyer H, Manns MP. Epidemiology, pathogenesis and management of hepatitis D: update and challenges ahead. *Nat Rev Gastroenterol Hepatol* 2010; 7: 31-40.
7. Rizzetto M. Hepatitis D: Clinical features and therapy. *Dig Dis* 2010; 28: 139-43.
8. Farci P. Delta hepatitis: an update. *J Hepatol* 2003; 39: S212-S19.
9. Rizzetto M, Verme G, Recchia S, Bonino F, Farci P, Aricò S, Calzia R, et al. Chronic hepatitis in carriers of hepatitis B surface antigen, with intrahepatic expression of the delta antigen. An active and progressive disease unresponsive to immunosuppressive treatment. *Ann Intern Med* 1983; 98: 437-41.
10. Rifai K, Wedemeyer H, Rosenau J, Klempnauer J, Strassburg CP, Manns MP, Tillmann HL. Longer survival of liver transplant recipients with hepatitis virus coinfections. *Clin Transplant* 2007; 21: 258-64.
11. Samuel D, Muller R, Alexander G, Fassati L, Ducot B, Benhamou JP, Bismuth H. Liver transplantation in European patients with the hepatitis B surface antigen. *N Eng J Med* 1993; 329: 1842-7.
12. Marzano A, Gaia S, Ghisetti V, Carezzi S, Premoli A, Debernardi-Venon W, Alessandria C, et al. Viral load at the time of liver transplantation and risk of hepatitis B virus recurrence. *Liver Transplant* 2005; 11: 402-9.
13. Roche B, Samuel D. Evolving strategies to prevent HBV recurrence. *Liver Transpl* 2004; 10: S74-S85.
14. Samuel D, Zignego AL, Reynes M, Feray C, Arulnaden JL, David MF, Gigou M, et al. Long-term clinical and virological outcome after liver transplantation for cirrhosis caused by chronic delta hepatitis. *Hepatology* 1995; 21: 333-9.
15. Angus PW, Patterson SJ, Strasser SI, McCaughan GW, Gane E. A randomized study of adefovir dipivoxil in place of HBIG in combination with lamivudine as post-liver transplantation hepatitis B prophylaxis. *Hepatology* 2008; 48: 1460-6.
16. Smedile A, Casey JL, Cote PJ, Durazzo M, Lavezzo B, Purcell RH, Rizzetto M, et al. Hepatitis D viremia following or-

- thotopic liver transplantation involves a typical HDV viron with a hepatitis B surface antigen envelope. *Hepatology* 1998; 27: 1723-9.
17. McCaughan GW, Spencer J, Koorey D, Bowden S, Bartholomeusz A, Littlejohn M, Verran D, et al. Lamivudine therapy in patients undergoing liver transplantation for hepatitis B virus precore mutant-associated infection: high resistance rates in treatment of recurrence but universal prevention if used as prophylaxis with very low dose hepatitis B immune globuline. *Liver Transpl Surg* 1999; 5: 512-19.
 18. Angus PW, McCaughan GW, Gane EJ, Crawford DH, Harley H. Combination low-dose hepatitis B immune globulin and lamivudine therapy provides effective prophylaxis against posttransplantation hepatitis B. *Liver Transpl* 2000; 6: 429-33.
 19. Niro GA, Rosina F, Rizzetto M. Treatment of hepatitis D. *J Viral Hepat* 2005; 12: 2-9.
 20. Castelnau C, Le Gal F, Ripault MP, Gordien E, Martinot-Peignoux M, Boyer N, Pham BN, et al. Efficacy of peginterferon alpha-2b in chronic hepatitis delta: relevance of quantitative RT-PCR for follow-up. *Hepatology* 2006; 44: 728-35.
 21. Erhardt A, Gerlich W, Starke C, Wend U, Donner A, Sagir A, Heintges T, et al. Treatment of chronic hepatitis delta with pegylated interferon-alpha2b. *Liver Int* 2006; 26: 805-10.
 22. van Bömmel F, de Man RA, Wedemeyer H, Deterding K, Petersen J, Buggisch P, Erhardt A, et al. Long-term efficacy of tenofovir monotherapy for hepatitis B virus-monoinfected patients after failure of nucleoside/nucleotide analogues. *Hepatology* 2010; 51: 73-80.
 23. Dakin H, Fidler C, Harper C. Mixed treatment comparison meta-analysis evaluating the relative efficacy of nucleos(t)ides for treatment of nucleos(t)ide-naïve patients with chronic hepatitis B. *Value Health* 2010 Sep 3 (Epub ahead of print).
 24. Mansour W, Ducancelle A, Le Gal F, Le Guillou-Guillemette H, Abgueuen P, Pivert A, Calès P, et al. Resolution of chronic hepatitis delta after 1 year of combined therapy with pegylated interferon, tenofovir and emtricitabine. *J Clin Virol* 2010; 47: 97-9.
 25. Bordier BB, Ohkanda J, Liu P, Lee SY, Salazar FH, Marion PL, Ohashi K, et al. In vivo antiviral efficacy of prenylation inhibitors against hepatitis delta virus (HDV). *J Clin Invest* 2003; 112: 407-14.