

Endovascular treatment of a hepatic artery aneurysm causing chronic abdominal pain; a case report

Gabrielle L de Ruiter-Derksen,* Rutger CG Bruijnen,** Frank Joosten,** Michel MPJ Reijnen*

Alysis Zorggroep, Location Rijnstate, Departments of * Surgery and **Radiology, Arnhem, The Netherlands.

ABSTRACT

Background. Aneurysms of the visceral arteries are rare but potentially lethal lesions. We describe a case of a successful endovascular exclusion of a hepatic artery aneurysm in a patient that suffered from chronic abdominal pain. **Case Report.** A 68-year old man presented with chronic abdominal pain that had existed for 10 months. A diagnostic contrast-enhanced CT scan showed an 18 mm atherosclerotic aneurysm of the hepatic artery. When other pathology was excluded the aneurysm was excluded using an ePTFE-covered nitinol stent graft. Post-deployment angiograms showed a complete exclusion of the aneurysm. The abdominal complaints immediately resolved. After a follow-up period of 18 months patient had a patent endograft and remained free of symptoms. **Conclusions.** Small hepatic artery aneurysms may cause chronic recurrent abdominal pain and can be safely excluded using a covered stent graft.

Key words. Hepatic artery aneurysm. Stent graft. Symptomatic. Abdominal pain.

INTRODUCTION

Aneurysms of the visceral arteries are rare but potentially life-threatening lesions. The estimated incidence is between 0.1% and 0.2%, as observed in routine autopsies.¹ The etiology of visceral artery aneurysms is mostly atherosclerotic. Trauma and inflammation may cause pseudoaneurysm formation, such as in case of an acute pancreatitis causing periarterial inflammation or vessel erosion from an adjacent pseudocyst.^{2,3} Other conditions which are associated with hepatic artery aneurysms are medial degeneration, fibromuscular dysplasia and vasculitis.⁴ Atherosclerotic aneurysms are typically extrahepatic while traumatic aneurysms or pseudoaneurysms are more commonly intrahepatic.⁵

Aneurysms of the hepatic artery represent 20-40% of all visceral artery aneurysms.^{6,7} As with other visceral artery aneurysms, they are mostly asymptomatic but may present as a life-threatening emergency.⁷ A hepatic artery aneurysm may be diagnosed by duplex scanning, that may demonstra-

te flow in the lesion, confirming its vascular origin, its dimensions and the eventual presence of thrombus. Contrast-enhanced CT scanning is effective in providing additional information regarding the vascular anatomic variations, collateral circulation and the relation between the aneurysm and adjacent organs. Digital subtraction angiography is still considered the gold standard for diagnosis and pre-operative planning.⁴

Historically, visceral artery aneurysms have been treated with either surveillance or open surgical reconstruction. Endovascular approaches may offer an alternative to conventional open surgery with the benefit of low procedural morbidity and mortality.⁸ We report the case of successful endovascular exclusion of a hepatic artery aneurysm that caused chronic abdominal pain.

CASE REPORT

A 68-year-old man was admitted for chronic abdominal pain that had existed for ten months. It was a recurrent right-sided abdominal pain that was unrelated to eating. There were no other abdominal symptoms. Patient had a history of hypertension, inguinal hernia repair, hernia nuclei pulposi, myocardial infarction and coronary artery bypass surgery. Extensive analysis, including abdominal

Correspondence and reprint request: Dr. M.M.P.J. Reijnen, Department of Surgery, Alysis Zorggroep, Location Rijnstate, Wagnerlaan 55, 6815 AD Arnhem, The Netherlands, Tel: 0031-263786908, Fax: 0031-263786627, E-mail: mmpj.reijnen@gmail.com.

Manuscript received: October 27, 2009.

Manuscript accepted: December 6, 2009.

ultrasound, gastroscopy and colonoscopy did not reveal a diagnosis. A diagnostic contrast-enhanced CT scan showed an 18 mm atherosclerotic aneurysm of the hepatic artery (Figure 1). Initially, the aneurysm was considered to be too small to explain his abdominal complaints. When all other pathology was excluded, however, it was decided to exclude the aneurysm endovascular.

The patient received 5000 I.U. heparin and 1 gram cefazolin intravenously. The right femoral artery was punctured to position a catheter into the celiac trunk. The aneurysm was localized distally from the origin of the splenic artery and left gastric artery and proximally from the origin of the duodenal artery (Figure 2A). A stiff Terumo guidewire was positioned distally of the hepatic artery aneurysm and the hepatic artery was pre-dilated with a 5 mm balloon angioplasty. Subsequently, an ePTFE-

covered nitinol stent graft (5 mm, 25 mm Viabahn, W.L. Gore & associates, Flagstaff, AZ) was positioned and deployed under fluoroscopy. Control angiography showed a distal type-1 endoleak and therefore an additional bare stent (6 mm, 40 mm, Misago, Terumo, Ann Arbor, MI) was deployed more distally. Post-deployment angiograms showed a complete exclusion of the aneurysm (Figure 2B). There was no flow in the gastroduodenal artery originating just distally of the aneurysm. Immediately after the procedure the abdominal pain completely resolved. There were no postoperative complications and

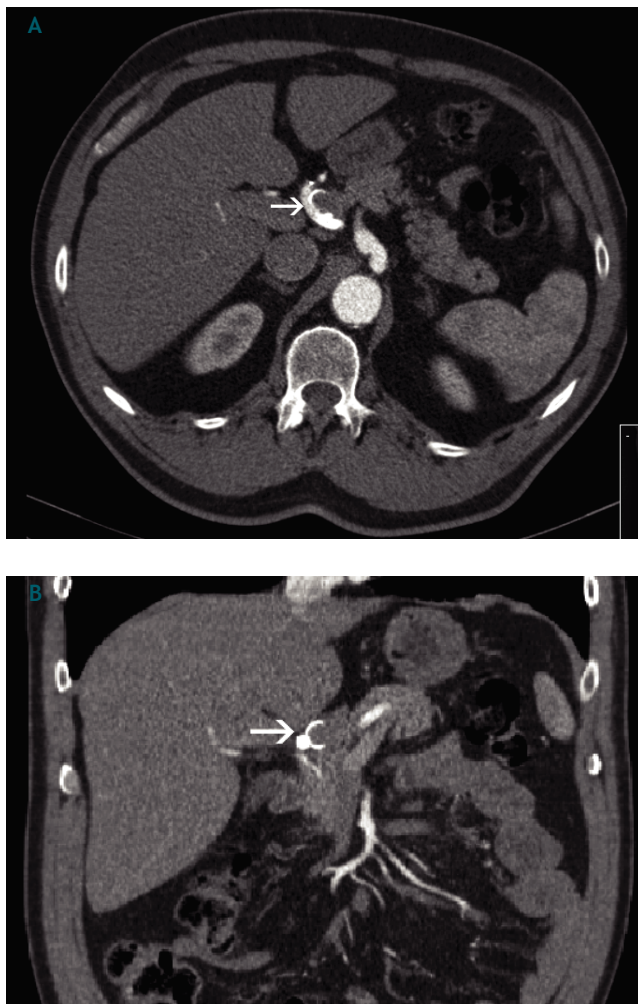


Figure 1. Atherosclerotic aneurysm of the hepatic artery
A. Transversal view (arrow). B. Coronal view .

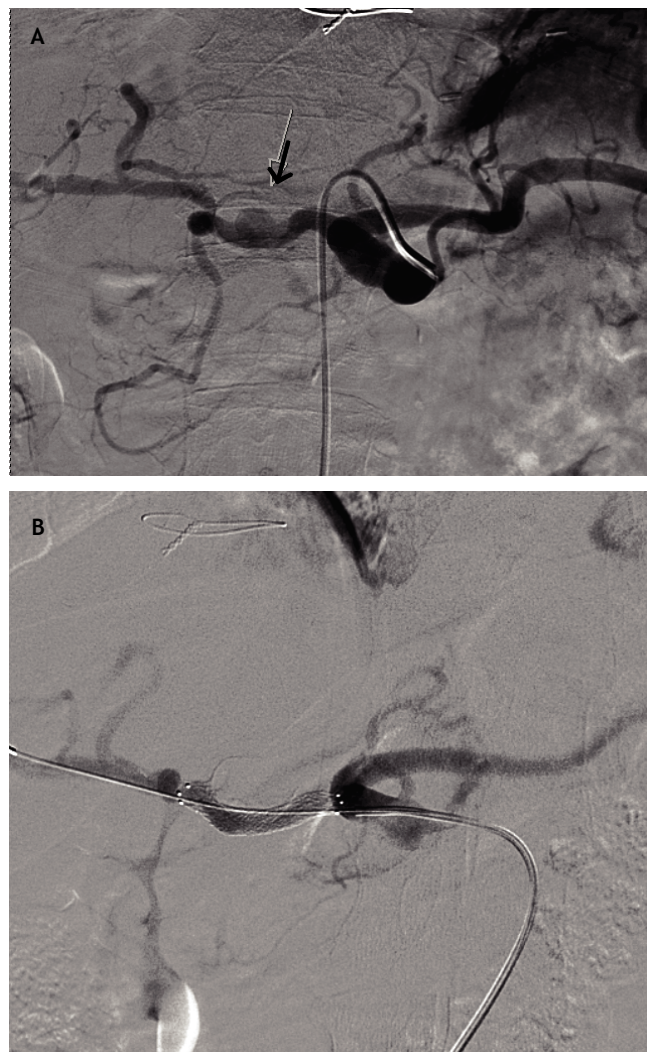


Figure 2. A. The aneurysm (arrow) was localized distally from the origin of the splenic artery and left gastric artery and proximally from the origin of the duodenal artery. B. An ePTFE covered nitinol stentgraft was positioned and deployed under fluoroscopy. Because of type-1 endoleak an additional bare stent was deployed. Post-deployment angiograms showed a complete exclusion of the aneurysm.

the patient was discharged after 3 days. Post-procedural pharmacotherapy consisted of carbasalaatcalcium 100 mg and simvastatin 40 mg daily for life.

Follow-up consisted of clinical examination and contrast-enhanced CT study after 1 month, showing a completely thrombosed aneurysm and a patent stent-graft. The gastroduodenal artery was vascularized by collaterals. After 18 months of follow-up the patient had not suffered from recurrent abdominal pain, supporting the diagnosis that the abdominal pain was aneurysm-related. Duplex ultrasound scanning showed a patent stent graft.

DISCUSSION

Although very rare, hepatic artery aneurysms are the second commonest visceral aneurysms, after splenic artery aneurysms.⁴ They usually are asymptomatic and discovered as an incidental finding during diagnostic imaging procedures performed for other reasons. Some patients, however, experience abdominal pain, and others are diagnosed during surgery for rupture. These patients usually are in hemorrhagic shock and reported survival rates are as low as 50%.² The risk of rupture appears to be related to the size of the aneurysm. The size threshold at which treatment becomes advisable is controversial, although it has been suggested that aneurysms less than 2 cm may not require treatment.⁵

The clinical presentation of a hepatic artery aneurysm may be non-specific and variable. The classic triad is epigastric pain, hemobilia and obstructive jaundice, although only one-third of patients with hepatic artery aneurysm present with all three symptoms.⁴ Our patient only suffered from chronic recurrent pain in the abdominal right upper quadrant, that completely resolved immediately after exclusion of the aneurysm. The latter confirmed the presumption that the abdominal complaints were indeed caused by the 18 mm aneurysm.

Open surgical treatment of visceral artery aneurysms is safe and effective, and offers satisfactory early and long-term results.⁹ Recently, Grotemeyer et al. have described a series of 23 patients with a visceral artery aneurysm of which 14 patients presented with symptoms attributable to their aneurysms, 4 presented with a rupture and 9 were asymptomatic. In their series the morbidity and mortality rate associated with surgical treatment

was low. After a mean follow-up of 55 months, the patency rate of the reconstructed visceral arteries was 90.4% and re-interventions were rare. Nevertheless, the minimal invasive character of endovascular repair might provide a benefit in both elective and emergency interventions.⁸ Endovascular exclusion may be accomplished by coil embolization or the selective use of N-butyl-2-cyanoacrylate.⁸ Coil embolization has been used in anatomically difficult cases due to its relative simplicity. Stent-grafting offers a more physiologic repair in its ability to maintain blood flow through the affected artery.³ In our opinion an anatomic reconstruction, preserving flow through the affected artery, should always be preferred. In our patient we managed to remain flow through the hepatic artery, although the gastroduodenal artery was occluded, not causing clinical symptoms.

In conclusion we have shown that small hepatic artery aneurysms may cause chronic recurrent abdominal pain and that they may be safely excluded using an ePTFE covered nitinol stent graft.

REFERENCES

1. Grotemeijer D, Duran M, Park E-J, Hoffmann N, et al. Visceral artery aneurysms - follow up of 23 patients with 31 aneurysms after surgical or interventional therapy. *Langenbecks Arch Surg* 2009; 12 March.
2. Carr SC, Mahvi DM, Hoch JR, Archer CW, et al. Visceral artery aneurysm rupture. *J Vasc Surg* 2001; 33: 806-11.
3. Jenssen GL, Wirsching J, Pedersen G, Amundsen SR, et al. Treatment of a hepatic artery aneurysm by endovascular stent-grafting. *Cardiovasc Intervent Radiol* 2007; 30: 523-5.
4. Kim J-H, Rha SE, Chun HJ, Kim YS, et al. Giant aneurysm of the common hepatic artery: US and CT imaging findings. *Abdom Imaging* 2009; 13 March.
5. Bratby MJ, Lehmann ED, Bottomley J, Kessel DO, et al. Endovascular embolisation of visceral artery aneurysms with ethylene-vinyl alcohol (Onyx): a case series. *Cardiovasc Intervent Radiol* 2006; 29: 1125-8.
6. Sessa C, Tinelli G, Porcu P, Aubert A, et al. Treatment of visceral artery aneurysms: description of a retrospective series of 42 aneurysms in 34 patients. *Ann Vasc Surg* 2004; 18(6): 695-703.
7. Shanley CJ, Shah NL, Messina LM. Uncommon splanchnic artery aneurysms: pancreaticoduodenal, gastroduodenal, superior mesenteric, inferior mesenteric and colic. *Ann Vasc Surg* 1996; 10(5): 506-15.
8. Pulli R, Dorigo W, Troisi N, Pratesi G, et al. Surgical treatment of visceral artery aneurysms: a 25-year experience. *J Vasc Surg* 2008; 48(2): 334-42.
9. Tulsyan N, Kashyap VS, Greenberg RK, Sarac TP, et al. The endovascular management of visceral artery aneurysms and pseudoaneurysms. *J Vasc Surg* 2007; 45(2): 276-83.