

# De-novo cholangiocarcinoma in native common bile duct remnant following OLT for primary sclerosing cholangitis

Carmen Landaverde,\* Vivian Ng,\* Alisa Sato,\* James Tabibian,\* Francisco Durazo,\*,\*\* Ronald Busuttil\*\*

\* University of California, Los Angeles, Department of Medicine. \*\* University of California, Los Angeles, Department of Surgery.

## ABSTRACT

Primary sclerosing cholangitis (PSC) is a chronic, progressive, inflammatory and obstructive disease of the intra- and extra-hepatic bile ducts of unknown etiology. Currently, orthotopic liver transplantation (OLT) is the only definitive treatment for PSC-related end-stage liver disease. However, PSC has been known to recur in the grafted liver. Roux-en-Y hepaticojejunostomy is more commonly performed than choledochocholedochostomy for PSC, although choledochocholedochostomy has been found to be safe and efficacious for PSC if the distal common bile duct is uninvolved at the time of OLT. Our case is unique in that it describes a patient who developed de-novo cholangiocarcinoma in the remnant portion of the native common bile duct six years after OLT with choledochocholedochostomy for PSC-associated end-stage liver disease without having PSC recurrence. In conclusion, our case report indicates that choledochocholedochostomy may not be desirable in PSC due to an increased risk of developing cholangiocarcinoma in the native common bile duct. This risk exists as well with a Roux-en-Y hepaticojejunostomy in the remaining intra-duodenal and intra-pancreatic biliary epithelium, although in theory to a lesser extent. Therefore, the risk of developing cholangiocarcinoma in the recipient common bile duct can only be completely eliminated by performing a Whipple procedure at the time of OLT.

**Key words.** Primary sclerosing cholangitis. Orthotopic liver transplantation. Choledochocholedochostomy.

## INTRODUCTION

The median survival of patients with primary sclerosing cholangitis (PSC) after diagnosis is only 10 to 12 years.<sup>1,2</sup> The lifetime risk of developing cholangiocarcinoma in patients with PSC varies in different studies between 10 to 20%.<sup>2-4</sup> Currently, orthotopic liver transplantation (OLT) is the only definitive treatment for PSC-related end-stage liver disease with post-transplant 5- and 10-year survival rates as high as 85% and 70%, respectively.<sup>5,6</sup> Biliary complications following OLT are a major cause of morbidity and are more common in PSC patients than in those who have undergone OLT for other indications.<sup>7-9</sup> Additionally, PSC has been known to

recur with significant frequency with rates between 8.6% and 20% in the grafted liver.<sup>10-12</sup> The general approach for OLT patients with PSC is to perform a Roux-en-Y hepaticojejunostomy rather than choledochocholedochostomy, presumably to reduce the risk of recurrent PSC, possible stricture formation, and cholangiocarcinoma in the remnant common bile duct. It can be postulated that leaving behind less biliary epithelium likely translates to a lower risk of developing cholangiocarcinoma.

The following case describes a patient who developed de-novo cholangiocarcinoma in the remnant portion of the native common bile duct after OLT with choledochocholedochostomy for PSC-associated end-stage liver disease. This case is exceptional in that it is the first case in the literature, to our knowledge, in which a PSC patient 6 years post-OLT develops cholangiocarcinoma in the recipient common bile duct in the absence of PSC recurrence.

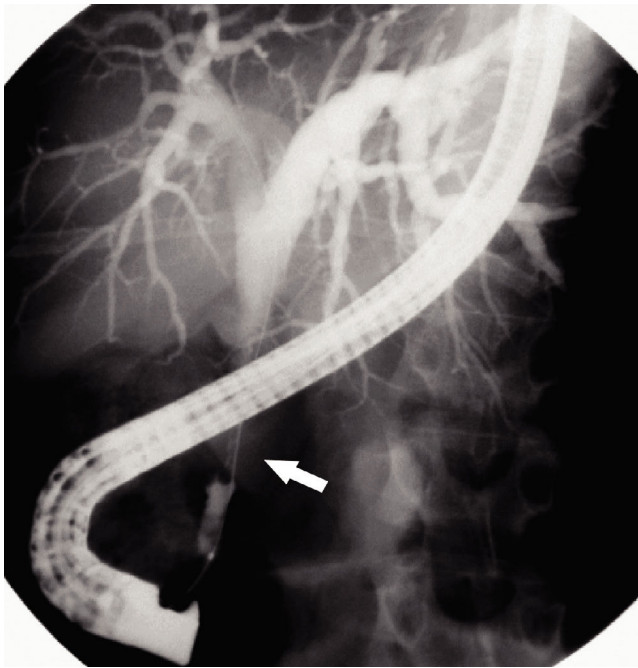
## CASE REPORT

A 49-year-old female was first diagnosed to have PSC in 1997 when she presented with jaundice, pru-

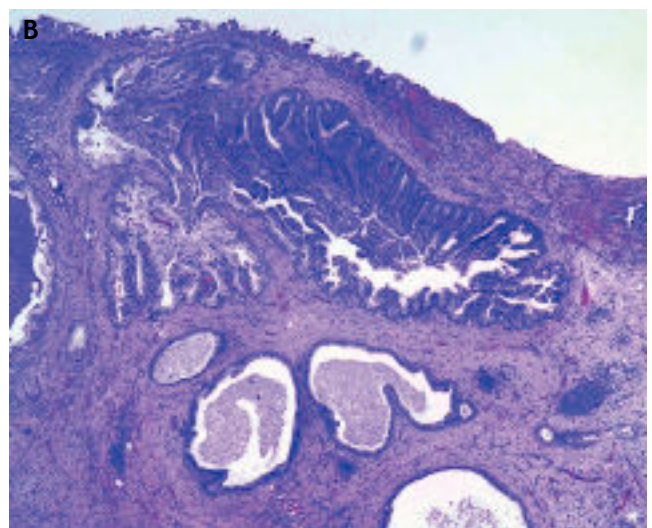
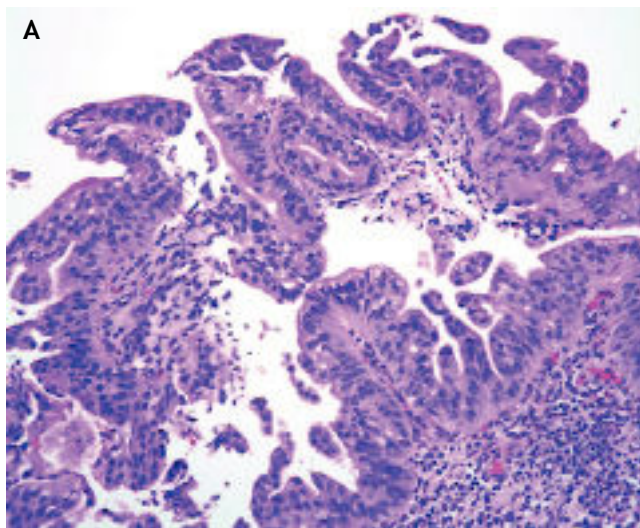
**Correspondence and reprint request:** Francisco Durazo, M.D.  
Pfleger Liver Institute, UCLA Medical Center  
200 Medical Plaza, Suite 214  
Los Angeles, CA 90095-7302  
Phone: 310-206-6705, Fax: 310-206-4197  
E-mail: FDurazo@mednet.ucla.edu

*Manuscript received: October 11, 2009.  
Manuscript accepted: November 6, 2009.*

ritis, and elevated liver tests. Over the course of her disease, she had three endoscopic retrograde cholangiopancreatographies (ERCPs) revealing severe biliary



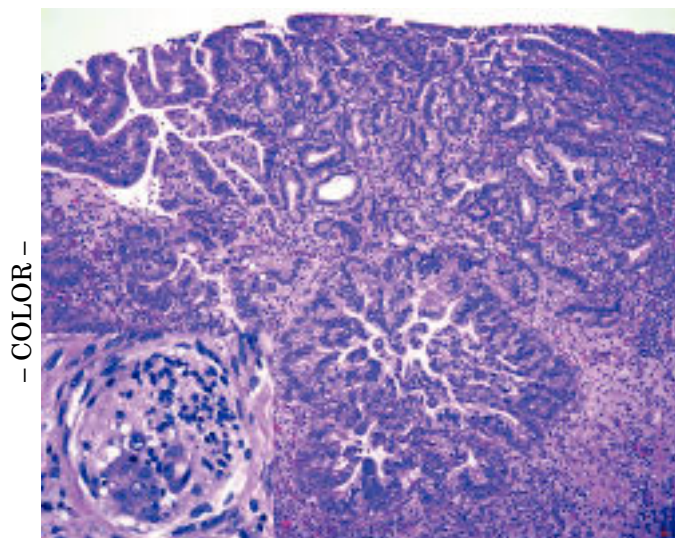
**Figure 1.** ERCP image demonstrating biliary dilatation. ERCP demonstrating marked intra- and extra-hepatic biliary dilatation to the level of the ductal anastomosis, with a sharp transition in ductal caliber from the donor to the native duct and a long segment of narrowed native common bile duct near the pancreatic head.



**Figure 2 (A & B).** Common bile duct biopsy. Common bile duct biopsy reveals micropapillary proliferation of the biliary epithelium with some small budding cluster into the lumen. Abnormal large nuclei with hyperchromasia and loss of nuclear polarity are present. Multiple biopsies of the stricture and native common bile duct showed biliary intraepithelial neoplasia 3 with suspicious area of invasive adenocarcinoma.

teral intra- and extra-hepatic biliary strictures, with the last ERCP in 2000 showing equivocal dysplastic cells on brushings of the biliary system. In 2001, she underwent urgent OLT following esophageal variceal bleeding and hepatorenal syndrome. No evidence of malignancy or dysplasia was seen on frozen sections from intraoperative biopsies of the native liver, three different areas of the recipient common bile duct (including the distal duct), and the peri-hilar lymph nodes. The distal common bile duct appeared grossly normal. As a result, it was decided to proceed with a choledochocholedochostomy. She had an uncomplicated post-operative course and for the next five years she had normal liver enzyme tests on FK 506, mycophenolate mofetil, and prednisone.

In June 2007, she returned with an asymptomatic elevation of liver enzymes (aspartate aminotransferase 222 U/L, alanine aminotransferase 270 U/L, and alkaline phosphatase 210 U/L). Magnetic resonance cholangiopancreatogram (MRCP) identified a long stricture of the native common bile duct. A subsequent ERCP demonstrated marked intra- and extra-hepatic biliary dilatation to the level of the ductal anastomosis, with a sharp transition in ductal caliber from the donor to the native duct and a long segment of narrowed native common bile duct near the pancreatic head (Figure 1). Multiple biopsies of the stricture and native common bile duct showed biliary intraepithelial neoplasia 3 with a suspicious area of invasive adenocarcinoma (Figures 2A, 2B). Balloon dilatation, stent placement, and sphinctero-



**Figure 3.** Distal common bile duct biopsy. Distal common bile duct biopsy from Whipple procedure shows high-grade biliary dysplasia with invasive adenocarcinoma and perineural invasion (inset).

tomy were performed. In addition, her carbohydrate antigen 19-9 (CA 19-9) was noted to be elevated at 80 U/mL (normal range 0-37 U/mL).

Subsequently, the patient underwent a Whipple procedure. Macroscopic examination demonstrated a 1.4 cm long segment of thickened stenotic distal common bile duct. There were no intraluminal growths or mass lesion surrounding the bile duct. On microscopic examination, the bile duct was lined by high-grade dysplastic biliary epithelium (Bil IN 3) with focal erosion associated with acute inflammation. The tumor cells invaded into the wall forming cribriform and irregular glands, diagnostic for adenocarcinoma. Perineural and pancreatic invasion were present (Figure 3). All of the eight lymph nodes removed were negative for carcinoma. Additionally, there was no evidence of intra- or extra-hepatic recurrence of PSC. Based on this, her stage T3, N0, MX cholangiocarcinoma was believed to be completely resected. Follow-up CT of the chest was unremarkable and she is currently scheduled for adjuvant abdominal radiation therapy with continuous 5-FU infusion.

## DISCUSSION

Primary sclerosing cholangitis-associated cholangiocarcinoma can develop at any time throughout the course of PSC and is difficult to diagnose. This is because there is substantial overlap in histological, radiological, biochemical, and clinical profiles of

patients with biliary strictures from cholangiocarcinoma, PSC (including recurrent disease post-OLT) and post-OLT complications. Post-OLT complications include; ischemia from hepatic artery thrombosis or prolonged cold preservation, immune-mediated ABO-incompatibility with allografts, chronic ductopenic rejection, and biliary infection.<sup>7,11,13-15</sup>

The most dreaded complication of PSC is cholangiocarcinoma. Previously, patients with known cholangiocarcinoma or who were diagnosed at the time of OLT (incidental cholangiocarcinoma) were considered inappropriate candidates for OLT given the dismal predicted outcome.<sup>1,14</sup> In a 12-year retrospective review of 127 patients who underwent OLT for PSC, Goss, *et al.* confirmed that patients with a known diagnosis of cholangiocarcinoma prior to OLT had significantly worse 1-, 2-, and 5-year survival rates of 33%, 33%, and 0% as compared to patients without known cholangiocarcinoma.<sup>14</sup> However, Goss, *et al.* did find 10 patients (8%) in his retrospective review who were incidentally diagnosed with cholangiocarcinoma during OLT but had a survival rate similar to those patients undergoing OLT without previously diagnosed cholangiocarcinoma.<sup>16</sup> These studies suggest that the diagnosis of incidental cholangiocarcinoma during OLT may not have a negative impact on outcome, whereas the diagnosis of cholangiocarcinoma prior to OLT is more likely to have an adverse outcome. Therefore, the presence of cholangiocarcinoma, except for incidental cholangiocarcinoma, has traditionally been deemed as a contraindication to OLT as the survival of these patients is dismal.<sup>16</sup> However, in a study by the Mayo Clinic, favorable survival outcomes were found in carefully selected patients with known cholangiocarcinoma at the time of OLT who underwent preoperative irradiation and chemotherapy.<sup>16</sup>

Currently, there is a paucity of clinical studies on cholangiocarcinoma development post-OLT. To our knowledge, there is only one case report of de-novo cholangiocarcinoma eight years post-OLT in a patient with recurrent PSC.<sup>10</sup> In that case, the patient had undergone Roux-hepaticojejunostomy and had a history of an anastomotic stricture necessitating revision of the hepaticojejunostomy. Our case differs and is even more unusual in that there was no evidence of PSC recurrence in the donor liver or biliary system and a choledochocholedochostomy biliary anastomosis was performed. The ERCP image (Figure 1) illustrates that the donor intra hepatic biliary ducts and extrahepatic duct had no evidence of stricturing. The long segment of narrowing was in the native common bile

duct near the pancreatic head from which the biopsies revealed cholangiocarcinoma.

In general, Roux-en-Y hepaticojejunostomy is preferred over choledochocholedochostomy biliary anastomosis for patients undergoing OLT for PSC. One study concluded that Roux-en-Y hepaticojejunostomy was preferred for cases of small donor bile duct size, where there is a significant size disparity between donor and recipient ducts, biliary atresia, re-OLT, PSC, and cholangiocarcinoma.<sup>15</sup> In addition, a large retrospective analysis by Sheng, *et al.*, showed anastomotic stricturing of the hepaticojejunostomy in PSC patients occurred at the same rate as patients transplanted for non-PSC indications.<sup>11</sup> Roux-en-Y hepaticojejunostomy, however, has been associated with more frequent complications such as perforation, recurrent cholangitis secondary to obstruction or reflux, and stasis.<sup>15</sup> On the other hand, choledochocholedochostomy allows easier access to the biliary tree, preservation of the physiologic anatomy, and possibly less morbidity and mortality.<sup>7</sup> In our case, a choledochocholedochostomy biliary reconstruction was performed.

Choledochocholedochostomy biliary reconstruction following OLT for PSC has been found to be safe and efficacious unless the distal common bile duct has disease involvement.<sup>7,12</sup> Nonetheless, although hepaticojejunostomy has a higher potential for early post-operative complications, it may be preferable over choledochocholedochostomy for patients with PSC as it removes all but a stump of the common bile duct, hopefully reducing the risk of strictures and de-novo cholangiocarcinoma in the native common bile duct. To our knowledge, there has not been a report in the literature of cholangiocarcinoma developing in the remnant common bile duct stump in a PSC patient who underwent OLT with Roux-en-Y hepaticojejunostomy anastomosis. Since de-novo cholangiocarcinoma is possible in the common bile duct remnant, as demonstrated by our case, only the combination of OLT with a Whipple procedure can completely eliminate the risk of cholangiocarcinoma in the native biliary ducts since both the liver and the common bile duct would be entirely removed. Further investigation on biliary reconstruction approaches in PSC patients undergoing OLT are needed to verify if there is indeed a difference in the rate of PSC recurrence, stricture formation, or the development of cholangiocarcinoma. It can be speculated that a choledochocholedochostomy versus a hepaticojejunostomy anastomosis may confer a higher risk for developing cholangiocarcinoma in post-OLT PSC patients because a signifi-

cant greater length of the native common bile duct is left behind with a choledochocholedochostomy as compared with a hepaticojejunostomy anastomosis. Furthermore, the recipient common bile duct may have dysplastic or pre-dysplastic changes that may not be evident at the time of OLT and although, it remains to be proven, the risk of developing cholangiocarcinoma post-OLT may correlate with the amount of native biliary surface epithelium left behind. In fact, many experts consider PSC a premalignant condition.

The survival of PSC patients who develop cholangiocarcinoma is poor because of the current limitations in early detection. Therefore, the principal challenge lies in early detection of cholangiocarcinoma in the context of long-standing PSC or recurrent PSC post-OLT. To date, there are no good markers to detect early neoplastic changes.<sup>14</sup> Carbohydrate antigen 19-9 may be elevated but does not reliably predict cholangiocarcinoma in the setting of coexisting PSC.<sup>14,17</sup> In our case, the CA 19-9 was elevated consistent with the diagnosis of cholangiocarcinoma. Carcinoembryonic antigen (CEA) lacks adequate sensitivity and specificity. Some studies suggest that the combination of biliary cytology, CA19-9, and CEA may be helpful in supporting a diagnosis of cholangiocarcinoma in PSC, but are limited in power.<sup>18,19</sup> The sensitivity for detecting early cholangiocarcinoma with positron emission tomography scanning has been found to vary by the cholangiocarcinoma morphology type, nodular versus infiltrating as described by Anderson, *et al.* The authors found that the sensitivity was 85% for nodular morphology, but only 18% for infiltrating morphology. Another limitation of PET scanning is that false positive rates have been seen in patients with PSC and other inflammatory diseases.<sup>20</sup>

## CONCLUSION

Recurrence of PSC and development of cholangiocarcinoma are difficult to distinguish from other biliary strictures. Cholangiocarcinoma can occur de-novo in the native common bile duct remnant. Therefore, there is a risk of developing cholangiocarcinoma in the common bile duct remnant regardless of which biliary anastomosis surgical approach is chosen at the time of OLT, and in theory, a choledochocholedochostomy may confer a higher risk. Only a combination of OLT with a Whipple procedure can eliminate the risk of developing cholangiocarcinoma in the absence of PSC recurrence.

## ACKNOWLEDGEMENTS

We would like to thank our colleagues from the University of California, Los Angeles, Department of Pathology, Dr. Galen Cortina and Ananya Manuyakorn for their expertise and assistance in providing the images used in this case report.

## ABBREVIATIONS

- **PSC:** Primary sclerosing cholangitis.
- **OLT:** Orthotopic liver transplantation.
- **ERCP:** Endoscopic retrograde cholangiopancreatographies.
- **MRCP:** Magnetic resonance cholangiopancreatogram.
- **CA 19-9:** Carbohydrate antigen 19-9.
- **CEA:** Carcinoembryonic antigen.

## REFERENCES

1. Farrant JM, Hayllar KM, Wilkinson ML, Karani J, Portmann BC, Westaby D, et al. Natural history and prognostic variables in primary sclerosing cholangitis. *Gastroenterology* 1991; 100(6) :1710-7.
2. Tischendorf JJ, Hecker H, Krüger M, Manns MP, Meier PN. Characterization, outcome, and prognosis in 273 patients with primary sclerosing cholangitis: a single center study. *Am J Gastroenterol* 2007; 102(1): 107-14.
3. Lee YM, Kaplan MM. Primary sclerosing cholangitis. *N Engl J Med* 1995; 332(14): 924-33.
4. Bergquist A, Ekblom A, Olsson R, Kornfeldt D, Lööf L, Danielsson A, Hultcrantz R, Lindgren S, Prytz H, Sandberg-Gertzén H, Almer S, Granath F, Broomé U. Hepatic and extrahepatic malignancies in primary sclerosing cholangitis. *J Hepatol* 2002; 36(3): 321-7.
5. Graziadei IW. Recurrence of Primary Sclerosing Cholangitis After Liver Transplantation. *Liver Transpl* 2002; 8(7): 575-81.
6. Wiesner RH. Liver transplantation for primary sclerosing cholangitis: timing, outcome, impact of inflammatory bowel disease and recurrence of disease. *Best Pract Res Clin Gastroenterol* 2001; 15(4): 667-80.
7. Distant V, Farouk M, Kurzwinski TR, Ahmed SW, Burroughs AK, Davidson BR, Rolles K. Duct-to-duct biliary reconstruction following liver transplantation for primary sclerosing cholangitis. *Transpl Int* 1996; 9(2): 126-30.
8. Hiatt JR, Quinones-Baldrich WJ, Ramming KP, Brems J, Bussittil RW. Operations upon the biliary tract during transplantation of the liver. *Surg Gynecol Obstet* 1987; 165(1): 89-93.
9. Neuhaus P, Blumhardt G, Bechstein WO, Steffen R, Platz KP, Keck H. Technique and results of biliary reconstruction using side-to-side choledochocholedochostomy in 300 orthotopic liver transplants. *Ann Surg* 1994; 219(4): 426-34.
10. Heneghan MA, Tuttle-Newhall JE, Suhocki PV, Muir AJ, Morse M, Bornstein JD, Sylvestre PB, Collins B, Kuo PC, Rockey DC. De-novo cholangiocarcinoma in the setting of recurrent primary sclerosing cholangitis following liver transplant. *Am J Transplant* 2003; 3(5): 634-8.
11. Sheng R, Zajko AB, Campbell WL, Abu-Elmagd K. Biliary strictures in hepatic transplants: prevalence and types in patients with primary sclerosing cholangitis vs. those with other liver diseases. *AJR Am J Roentgenol* 1993; 161(2): 297-300.
12. Heffron TG, Smallwood GA, Ramcharan T, Davis L, Connor K, Martinez E, Stieber AC. Duct-to-duct biliary anastomosis for patients with sclerosing cholangitis undergoing liver transplantation. *Transplant Proc* 2003; 35(8): 3006-7.
13. Sanchez-Urdazpal L, Gores GJ, Ward EM, Maus TP, Buckel EG, Steers JL. Diagnostic features and clinical outcome of ischemic-type biliary complications after transplantation. *Hepatology* 1993; 17: 605-9.
14. Goss JA, Shackleton CR, Farmer DG, Arnaout WS, Seu P, Markowitz JS, Martin P, Stripling RJ, Goldstein LI, Busuttill RW. Orthotopic liver transplantation for primary sclerosing cholangitis. A 12-year single center experience. *Ann Surg* 1997; 225(5): 472-81.
15. Maguire D, Rela M, Heaton N. Biliary Complications After Orthotopic Liver Transplantation. *Transplantation Reviews* 2002; 16(4): 220-40.
16. De Vreede I, Steers JL, Burch PA, Rosen CB, Gunderson LL, et al. Prolonged disease-free survival after orthotopic liver transplantation plus adjuvant chemoradiation for cholangiocarcinoma. *Liver Transpl* 2000; 6(3): 309-16.
17. Fisher A, Theise ND, Min A, Mor E, Emre S, Pearl A, et al. CA19-9 does not predict cholangiocarcinoma in patients with primary sclerosing cholangitis undergoing liver transplantation. *Liver Transpl Surg* 1995; 1(2): 94-8.
18. Nakeeb A, Lipsett PA, Lillemoe KD, Fox-Talbot MK, et al. Biliary carcinoembryonic antigen levels are a marker for cholangiocarcinoma. *Am J Surg* 1996; 171(1): 147-52.
19. Bergquist A, Broome U. Hepatobiliary and extra-hepatic malignancies in primary sclerosing cholangitis. *Best Pract & Research Clin Gastroenterol* 2001; 15: 643-56.
20. Anderson CD, Rice MH, Pinson CW, Chapman WC, Chari RS, Delbeke D. Fluorodeoxyglucose PET imaging in the evaluation of gallbladder carcinoma and cholangiocarcinoma. *J Gastrointest Surg* 2004; 8: 90-7.