



Case Report

Spontaneous partial regression of hepatocellular carcinoma in a cirrhotic patient

Judith Meza-Junco;¹ Aldo J. Montaña-Loza;² Braulio Martínez-Benítez;³ Tatiana Cabrera-Aleksandrova⁴

Abstract

Spontaneous regression of a malignant tumor is an exceptional phenomenon. A 56-year-old woman with liver cirrhosis related to chronic hepatitis C presented with a liver tumor. Partial regression of a hepatocellular carcinoma was diagnosed by imaging studies that showed progressive diminution of the size of the tumor and changes in the tumor markers. However, because of the persistence of the tumor and uncertainty in the diagnosis we recommended surgery. A hepatectomy was performed and a hepatocellular carcinoma moderately differentiated was found. The patient is now doing well and without any evidence of recurrence at 25 months after surgery. We found 61 case reports that have been published from 1982 to September 2006, with apparently spontaneous regression of hepatocellular carcinoma. The precise mechanism regarding the spontaneous regression of this tumor is not fully understood, either ischemia due to rapid growth of the neoplasia or particular inflammatory and immunologic mechanisms may be involved in the regression of the hepatocellular carcinoma.

Key words: Spontaneous regression, hepatocellular carcinoma, cirrhosis.

¹ Department of Oncology.

² Gastroenterology.

³ Pathology.

⁴ Radiology.

Instituto Nacional de Ciencias Médicas y Nutrición, Salvador Zubirán, Mexico City.

Address for correspondence:
Judith Meza-Junco, M.D.
INCMNSZ
Vasco de Quiroga 15
Tlalpan, Mexico City
16000
Telephone: 5487-0900
E-mail: judith_mj@hotmail.com

Manuscript received and accepted: 11 December 2006 and 3 January 2007

Introduction

The hepatocellular carcinoma (HCC) is the most common primary malignant tumor of the liver worldwide, and it is within the first ten cancers most common.¹ In Mexico, the HCC (and the bile neoplasm), has an incidence of 1 in 100,000 habitants, and it is considered the fifth cancer most common and the fourth like cancer related deaths.²

The epidemiologic characteristics, clinical manifestations and survival are different between geographic areas; although, in general, the diagnosis of HCC, implies a poor prognosis.^{3,4} In Mexico, it has been reported that patients without treatment had a survival time of 1.7-11 months, and patients who received treatment had a survival time of 16-25.3 months, while, the survival time in patients who received surgery was 26-38 months. Currently, the most common cause of HCC is hepatitis C virus (HCV) infection; follow up by alcohol consumption and hepatitis B virus (HBV) infection.^{4,5}

Spontaneous regression of cancer is an uncommon phenomenon; even in patients with HCC is rarely described. Using the data bases «Pubmed» and «Medline» in a review until September of 2006, and using key words such as «hepatocarcinoma», «hepatocellular carcinoma» and «spontaneous regression», we found 61 described cases; and no one of these, has been reported in Mexico.

We herein present the case of a Mexican woman with liver cirrhosis due to HCV infection who had a partial spontaneous regression of HCC, and discuss the features of cases with a spontaneous regression of HCC reported in medical literature.

Case report

A 56-year-old woman with liver cirrhosis due to HCV infection was taken care in our hospital in February 2004. At accession she was in stage A of the Child-Pugh classification, and an abdominal ultrasound detected a liver tumor, that was confirmed with a magnetic resonance image (MRI), showing a tumor of 6 vs 5 cm of diameter in the segment V of the liver, suggestive of HCC (*Figure 1*); the level of alpha-fetoprotein (AFP) was 195 ng/dL. The patient did not receive treatment until six months after, in

this evaluation, the tumor had been diminished, its dimension were 3 cm vs 2.5 cm (Figure 2) and AFP level was 7.6 ng/dL. Finally, in August of the same year, the tumor was surgically removed with the segments V and VIII of the liver. The pathology report was of a hepatocellular carcinoma moderately differentiated of 2.8 vs 2.6 cm, margins were clear of tumor, there was important necrosis around the tumor, and it also has macronodular cirrhosis with intense activity (Figure 3). The patient did not receive adjuvant treatment, and after 25 months of surgery she is doing well, with no evidence of tumor recurrence at CT scan and the AFP level is still within the normal range.

Discussion

The present case, had criteria for a partial spontaneous regression of a hepatocellular carcinoma evidence by tu-

mor involution in a MRI and fall in serum AFP in the absence of treatment. Interestingly, there was evident necrosis surrounding the tumor in the absence of linfocitary infiltration in the microscopic analysis; therefore, the main mechanism of tumor regression in our case may be related to a disturbance of the blood supply on the peripheral side, such as the formation of a thick capsule, that may prevent the nutrient blood supply from reaching the tumor through the feeding arteries.

Spontaneous regression of cancers has been described in almost all kind of tumors, the frequency of this phenomenon is not well established; and it seems to be rarer than previously believed. The incidence may be one in every 140,000 cases of cancer rather one per 60,000 to 100,000 cancer cases as early thought (6). Almost half of the reported cases are renal cell carcinoma, melanoma and neuroblastoma; being the most representative the re-

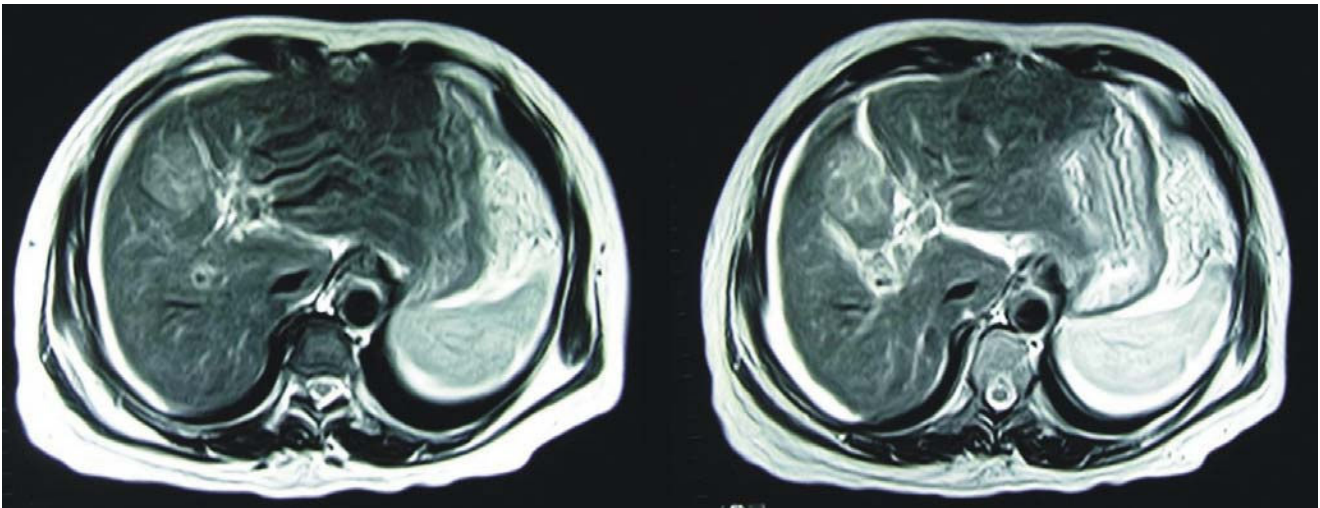


Figure 1. Magnetic Resonance Imaging showed a hypointense lesion in T1 sequences that enhances in T2 sequences as a hepatocellular carcinoma of 6 vs 5 cm. **S**

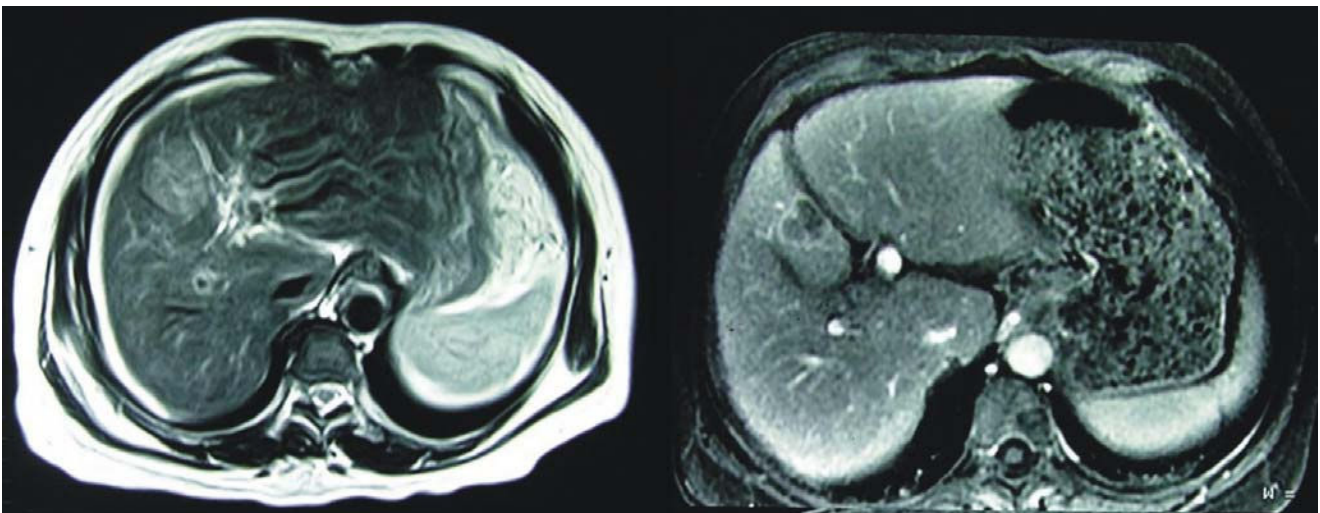


Figure 2. Magnetic Resonance Image showed diminishes in size tumor to 2.5 cm.

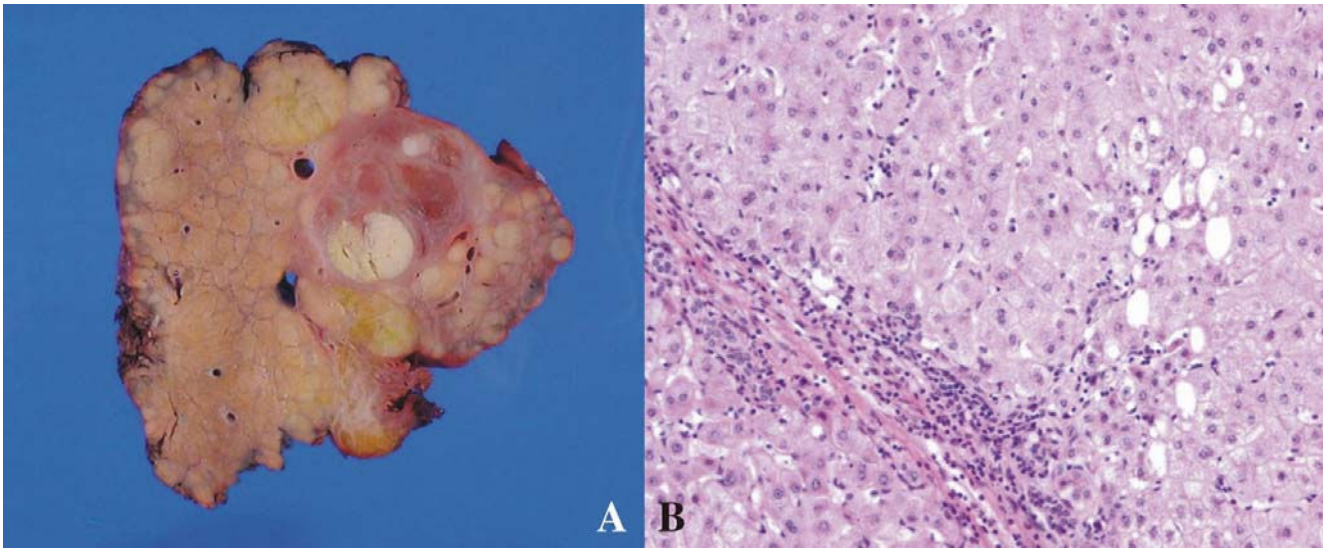


Figure 3. A) Macroscopic findings of the resected liver showing a well demarcated and encapsulated tumor measuring 2.8 vs 2.6 cm with subcapsular crescent necrosis. B) Microscopic findings showing a moderately differentiated hepatocellular carcinoma.

nal carcinoma accompanied by spontaneous regression of primary and/or the metastasis.

Meanwhile, spontaneous regression of HCC defined as a partial or complete involution of tumor in the absence of treatment is exceptional and only 61 cases have been documented in the medical literature. The mechanisms underlying this process are unknown and several factors have been proposed such as abstinence from alcohol consumption, herbal medicine consumption, vitamin K administration, gastrointestinal bleeding, high fever, subintimal vascular injury by angiographic procedures and the tumor's rapid growth. Hormonal influence, specially androgen and anti-estrogen therapy, and disruption of blood supply that may cause tumor necrosis could explain this process. In addition, there is a fascinating hypothesis that various biologically effective factors may act as stimulants to the immune system in association with spontaneous regression⁷⁻¹⁰

Othani et al¹¹ recently, analyzed in detail 40 cases with spontaneous regression of hepatocellular carcinoma, in 26 of these, either radiologically or histological complete regression were reported, whereas 14 cases showed partial spontaneous regression; since, cancer cells remained in a part of the tumor of the resected specimen or complete radiological disappearance was not seen. They had a relatively good prognosis, 31 of 40 patients were alive between 1-20 years of follow-up, and 5 of 40 cases showed recurrence after spontaneous regression.

We found 21 cases more published before September of 2006, which were not included in the Othani's report. Four of these cases were considered as partial spontaneous regression of non metastatic HCC,¹²⁻¹⁵ and one metastatic HCC to chest wall.¹⁶ Nine cases were reported as complete spontaneous regression in metastatic HCC

(lungs, bone, peritoneal, or cervical lymph nodes),¹⁷⁻²¹ and 7 patients developed complete spontaneous regression in non metastatic HCC.²²⁻²⁸

Spontaneous tumor regression is an interesting phenomenon, but its mechanism remains uncertain. We expect that in the future, further accumulation and discussion of such cases will help to elucidate the etiology and treatment of this event.

References

1. Seeff LB, Hoofnagle JH. Epidemiology of hepatocellular carcinoma in areas of low hepatitis B and hepatitis C endemicity. *Oncogene* 2006; 26: 3771-7.
2. Register of Malignant Neoplasm in Mexico. Available at: <http://www.dgepi.salud.gob.mx/diveent/RHNM.htm>. Accessed December 7, 2006.
3. Poenaru D, Szilagy A, Zabed F, Lamoureux E, Lough JO. Hepatocellular carcinoma: comparison of clinical features among ethnic groups in an area of low prevalence. *Am J Gastroenterol* 1991; 86: 487-94.
4. Meza-Junco J, Montano-Loza A, Candelaria Myrna. Treatment modalities in patients with hepatocellular carcinoma: a retrospective series in a single institution in Mexico. *Gastroenterolo Hepatol* 2004; 27: 11-7.
5. Mondragon-Sanchez R, Garduno-Lopez AL, Hernandez-Castillo E, Gomez-Gomez E, Ruiz-Molina JM. Hepatocellular carcinoma and hepatitis C in Mexico. *Hepatogastroenterology* 2005; 52:1159-62.
6. Chang WY. Complete spontaneous regression of cancer: four case reports, review of literature, and discussion of possible mechanisms involved. *Hawaii Med J* 2000; 59: 379-87.
7. Cole WH. Efforts to explain spontaneous regression of cancer. *J Surg Oncol* 1981; 17: 201-9.
8. Cole WH. Relationship of causative factors in spontaneous regression of cancer to immunologic factors possibly effective in cancer. *J Surg Oncol* 1976; 8: 391-441.
9. O'Beirne JP, Harrison PM. The role of the immune system in the control of hepatocellular carcinoma. *Eur J Gastroenterol Hepatol* 2004; 16: 1257-60.

10. Everson TC, Cole WH. Spontaneous Regression of Cancer: Preliminary Report. *Annals of Surgery* 1956; 144: 366-80.
11. Ohtani H, Yamazaki O, Matsuyama M, Horii K, Shimizu S, Oka H, Hebiki K, et al. Spontaneous Regression of Hepatocellular Carcinoma: Report of a Case. *Surg Today* 2005; 35:1081-86.
12. Yano Y, Yamashita F, Kuwaki K, Fukumori K, Kato O, Kiyomatsu K, Sakai T, et al. Partial spontaneous regression of hepatocellular carcinoma: a case with high concentrations of serum lens culinaris agglutinin-reactive alpha fetoprotein. *Kurume Med J* 2005; 52:97-103.
13. Blondon H, Fritsch L, Cherqui D. Two cases of spontaneous regression of multicentric hepatocellular carcinoma after intraperitoneal rupture: possible role of immune mechanisms. *Eur J Gastroenterol Hepatol* 2004; 16: 1355-9.
14. Kato H, Nakamura M, Muramatsu M, Orito E, Ueda R, Mizokami M. Spontaneous regression of hepatocellular carcinoma: two case reports and a literature review. *Hepatol Res* 2004; 29: 180-90.
15. Zimmermann A, Kappeler A, Friess H, Buchler MW. Hepatocellular carcinoma with an unusual medullary-like histology and signs of regression («medullary-like hepatocellular carcinoma»). *Dig Liver Dis* 2002; 34: 748-53.
16. Jeon SW, Lee MK, Lee YD, Seo HE, Cho CM, Tak WY, Kweon YO. Clear cell hepatocellular carcinoma with spontaneous regression of primary and metastatic lesions. *Korean J Intern Med* 2005; 20: 268-73.
17. Kojima H, Tanigawa N, Kariya S, Komemushi A, Shomura Y, Sawada S, Arai E, et al. A case of spontaneous regression of hepatocellular carcinoma with multiple lung metastases. *Radiat Med* 2006; 24: 139-42.
18. Nouse K, Uematsu S, Shiraga K, Okamoto R, Harada R, Takayama S, Kawai W, et al. Regression of hepatocellular carcinoma during vitamin K administration. *World J Gastroenterol* 2005; 14: 6722-4.
19. Ohta H, Sakamoto Y, Ojima H, Yamada Y, Hibi T, Takahashi Y, Sano T, et al. Spontaneous regression of hepatocellular carcinoma with complete necrosis: case report. *Abdom Imaging* 2005; 30: 734-7.
20. Nam SW, Han JY, Kim JI, Park SH, Cho SH, Han NI, Yang JM, et al. Spontaneous regression of a large hepatocellular carcinoma with skull metastasis. *J Gastroenterol Hepatol* 2005; 20: 488-92.
21. Abiru S, Kato Y, Hamasaki K, Nakao K, Nakata K, Eguchi K. Spontaneous regression of hepatocellular carcinoma associated with elevated levels of interleukin 18. *Am J Gastroenterol* 2002; 97: 774-5.
22. Feo CF, Marrosu A, Scanu AM, Ginesu GC, Fancellu A, Migaleddu V, Porcu A. Spontaneous regression of hepatocellular carcinoma: report of a case. *Eur J Gastroenterol Hepatol* 2004; 16: 933-6.
23. Lin TJ, Liao LY, Lin CL, Shih LS, Chang TA, Tu HY, Chen RC, et al. Spontaneous regression of hepatocellular carcinoma: a case report and literature review. *Hepatogastroenterology* 2004; 51: 579-82.
24. Morimoto Y, Tanaka Y, Itoh T, Yamamoto S, Mizuno H, Fushimi H. Spontaneous necrosis of hepatocellular carcinoma: a case report. *Dig Surg* 2002; 19: 413-8.
25. Iiai T, Sato Y, Nabatame N, Yamamoto S, Makino S, Hatakeyama K. Spontaneous complete regression of hepatocellular carcinoma with portal vein tumor thrombus. *Hepatogastroenterology* 2003; 50:1628-30.
26. Jozuka H, Jozuka E, Suzuki M, Takeuchi S, Takatsu Y. Psycho-neuro-immunological treatment of hepatocellular carcinoma with major depression-a single case report. *Curr Med Res Opin* 2003; 19: 59-63.
27. Li AJ, Wu MC, Cong WM, Shen F, Yi B. Spontaneous complete necrosis of hepatocellular carcinoma: a case report. *Hepatobiliary Pancreat Dis Int* 2003; 2: 152-4.
28. Garrido SA, Guerrero IFJ, Lepe J JA, Palomo GS. Spontaneous regression of hepatocellular carcinoma in a cirrhotic patient. *Gastroenterol Hepatol* 2001; 24: 503-5.

S

:

V

A

AC