



Original article

EPA plus DHA improves survival related to a decrease of injury after extended liver ischemia in Sprague-Dawley rats

Nicole Céspedes^a, Andrea Tamayo^a, Maria Jose Rodriguez^{a,b}, Jessica Zúñiga-Hernández^{a,*}^a Pharmacology Unit, Medical Research Laboratory, School of Medicine, University of Talca, Talca, Maule, Chile^b Doctorate Program in Research and Development of Bioactive Products, Universidad de Talca, Talca, Maule, Chile

ARTICLE INFO

Article history:

Received 15 November 2018

Accepted 6 September 2019

Available online 23 October 2019

Keywords:

Omega-3

Liver injury

Survival rates

Preconditioning

Inflammation

ABSTRACT

Introduction and objectives: The omega-3 fatty acids (ω 3), EPA and DHA, have been described for their beneficial effects on metabolism and inflammation. In addition, they are interesting tools in the treatment of acute liver disease. This investigation was conducted to assess the effect of EPA + DHA administration before partial ischemia (IR) on survival and liver injury.

Materials and methods: Male Sprague-Dawley rats were supplemented for 7 days with ω 3 [EPA (270 mg/kg) and DHA (180 mg/kg)]; controls received saline solution. After EPA + DHA supplementation, liver IR was induced by temporarily occluding the blood supply for 1 h, followed up by 48 h of reperfusion. Control animals were subjected to sham laparotomy.

Results: Previous to IR, the EPA + DHA administration improved the rate and prolonged the survival time by decreasing the AST and ALT levels and improving liver degenerative changes generated by the IR, which decreased TNF- α and IL-1 β . In addition, IL-10 increased at 20 h with a tendency to normalize at 48 h. The IR group had no differences in the IL-10 levels compared to controls.

Conclusions: The ω 3 supplementation could prevent and promote the restoration of the liver tissue and significantly improve the survival rate in rats at 48 h.

© 2019 Fundación Clínica Médica Sur, A.C. Published by Elsevier España, S.L.U. This is an open access article under the CC BY-NC-ND license (<http://creativecommons.org/licenses/by-nc-nd/4.0/>).

1. Introduction

Omega-3 fatty acids (ω 3) are essential fatty acids not synthesized *de novo* by humans. Fish oil and flaxseed as well as some nuts are known as highly rich sources of ω 3. Among ω 3, eicosapentaenoic acid (EPA, 20:5n-3) and docosahexaenoic acid (DHA, 22:6n-3) have been mainly found in seafood [1]. In humans, they are indirectly derived from these sources by dietary intake [2]. The dietary supplementation with EPA and DHA can reduce/regulate the production of proinflammatory cytokines such as interleukin (IL)-1, IL-6, IL-8, and TNF- α , which are released when macrophages (M Φ s) and monocytes are activated [1,2].

Ischemia–reperfusion (IR) occurs during major liver resection with temporary vascular exclusion or during liver transplantation and is a major risk factor that affects liver function and increases morbidity and mortality [3]. The failure of microcirculatory perfusion after reperfusion may be due to sinusoidal occlusion triggered

by endothelial cell swelling, vasoconstriction, platelet aggregation, neutrophil infiltration and lymphocyte activation [4]. Also, oxidative stress causes cell death through apoptosis or necrosis, which contributes to increased microcirculatory disturbances, cell dysfunction and inflammation [5,6].

EPA and DHA administration have well-established beneficial effects on human health. Scientific evidence has shown that ω 3 provides beneficial effects on cancer, cardiovascular diseases, metabolic syndromes, inflammatory diseases, psychiatric and/or neurodegenerative diseases, renal diseases, liver diseases, among others [1]. In addition, ω 3 attenuated fibrosis, which could be an interesting strategy for non-alcoholic liver disease (NAFLD) [7]. Previous studies investigated the role of these fatty acids on hepatic IR, showing alterations in the innate immune response [8]. However, few studies have investigated the role of EPA and DHA administration in hepatic IR and the mechanisms that explain their positive effect [7,8]. Previously, our group has reported that combined administration of ω 3 [EPA + DHA (270 mg/kg and 180 mg/kg, respectively)] has a protective effect over liver IR between 3 and 20 h of reperfusion, evidenced by the normalization of transaminases, TNF- α , IL-1 β and IL-10 levels and the return to oxidative

* Corresponding author.

E-mail address: Jezuniga@utalca.cl (J. Zúñiga-Hernández).

equilibrium (GSH/GSSG and F2-isoprostanes). All of these are related to the activation of PPAR α and the sequester of NF κ Bp65 in a PPAR α /NF κ Bp65 complex with the consequent of a decrease of NF κ Bp65 DNA-binding union return [4,9]. With the evidence presented, the aim of this study was to evaluate the role of EPA + DHA over prolonged liver IR damage and their effect on the survival of rats subjected to liver IR model.

2. Materials and methods

2.1. Animals

Male Sprague–Dawley rats (160–180 g) (Animals facilities, Universidad de Talca) received food and water *ad libitum* and were housed on a 12 h light/dark cycle at 25 °C. Animal care and experimental protocols of this study were approved by the Animals Bioethical Committee of the Universidad de Talca and conducted in accordance with the recommendations of the European Union regarding animal experimentation (Directive of the European Council 86/609/EC).

2.2. Experimental groups and partial liver ischemia–reperfusion surgery

The rats were orally supplemented for 7 days with EPA (270 mg/kg) plus DHA (180 mg/kg) (General Nutrition Corp., Pittsburgh, PA). Control groups received isovolumetric amounts of saline solution. On day 8 after supplementation, rats were anaesthetized with an intraperitoneal injection (ketamine 15 mg/kg, xylazine 3 mg/kg and acepromazine 2.5 mg/kg). IR was induced by temporarily occluding the blood supply to the liver by means of a Schwartz clip (Fine Science Tools, Vancouver, Canada) for 1 h as previously described [9]. This was followed by up to 48 h of reperfusion. Control animals were subjected to anesthesia and sham laparotomy. Four experimental groups were designed: (a) Control-Sham, (b) Control-IR, (c) ω 3-Sham and (d) ω 3-IR. Two sets of animals were evaluated: (a) survival analysis (9 animals for each experimental group), during the performance of the experimental protocol, the animals were supervised for physiological functions (external appearance, nutritional conditions, behavior and abnormality of feces) by a veterinarian. All animals were weighed daily from the beginning to the end of the experiment. From the standpoint of animal welfare, the rats that had poor health conditions were euthanized. For all groups, the final point was 48 h post ischemia; (b) cellular and molecular analysis (7–9 animals for each experimental group), to evaluate the action of EPA + DHA, blood samples were obtained by cardiac puncture for serum AST, ALT, 8-isoprostane and cytokine assessments. At the same time, liver samples were extracted from the medial lobes, frozen in liquid nitrogen, stored at –80 °C and cut in two pieces. One half was fixed by 10% formalin and used for histopathological analysis, embedded in paraffin and stained with hematoxylin–eosin (morphology assessment) or Masson's Trichrome (connective tissue deposit) stain. The histological necrosis was evaluated using the Korourian score (percentage areas) [10] and the liver fibrosis was analyzed by the modified Ishak score [11]. The other halves were stored at –80 °C for biochemical analysis.

2.3. Determination of serum transaminases and 8-isoprostanes

ALT and AST were quantified in plasma through the detection of NADH at 340 nm by commercially available kits (Spinreact, Gerona, Spain). 8-isoprostanes were measured in plasma with the 8-isoprostane EIA Kit (Cayman Chemical, MI, USA) through a

Table 1

Oligonucleotide sequences for quantitative real-time polymerase chain reaction.

Gene symbol	Forward primer	Reverse primer
<i>GAPDH</i>	5'-TTGTGAAGCTCATTTCCTGGTA-3'	5'-GGCCTCTCTTGCTCTCAGTA-3'
<i>TNFα</i>	5'-GGTTCGCTCCCTCTCATACA-3'	5'-AGACACCCCTGGAGTTCT-3'
<i>IL-6</i>	5'-AGTTGCCTTCTGGGACTGA-3'	5'-ACTGCTCTGTTGGGTGGT-3'
<i>IL-10</i>	5'-TGGAGTGAAGACCAGCAAAG-3'	5'-GGCAACCCAAGTAACCTTA-3'
<i>IL-1β</i>	5'-GCTGTGGCAGTACCTATGCTTG-3'	5'-AGGTCGTCATCATCCCA CGAG-3'

Table 2

Summary of the mortality and survival rates at the end of the IR study.

	Control	IR	ω 3-sham	ω 3-IR
Number of animals used	9	9	9	9
Number of death	0	5	0	1
Survival rate (%)	100	47	100	88

competitive ELISA measurement at a wavelength between 405 and 420 nm according to the manufacturer's instructions.

2.4. Quantitative real-time PCR

The cytokines were analyzed by quantitative RT–qPCR. Before PCR, total RNA was processed with RNase-free DNase (AMBION-Turbo DNA-free kit, Life Technologies, CA, USA). After quantitation in Nanodrop (Thermo Fisher Scientific, MA, USA) RNA was reverse-transcribed using Revert Aid Reverse Transcriptase (Thermo Scientific, Waltham, MA, USA) and qPCR was performed for TNF- α , IL-6, IL-1 β and IL-10 genes with GAPDH as a housekeeping gene (Table 1). The assay was performed in a Stratagene Mx3000P (Agilent Technologies, CA, USA) thermo cycler. The thermal cycle conditions were: 95 °C for 5 min, 40 cycles of 95 °C for 15 s, 60 °C for 45 s and finally, a dissociation cycle. Efficiency of every primer set was calculated through a serial dilution of a cDNA sample from 10⁻¹ to 10⁻⁸ in a final reaction volume of 20 μ L. Gene expression level was measured on a standard curve. Additionally, relative change was calculated using 2^{- $\Delta\Delta$ Ct} methods and normalized to GAPDH.

2.5. Statistical analysis

Sample size was determined by G*Power 3.1 software (Allgemeine Psychologie und Arbeitspsychologie, Heinrich Heine, Universität Düsseldorf, Germany). The power analyses used α = 0.05 and β = 0.2 in a two-sided test. Nine subjects were necessary to assume a standard deviation (SD) of 0.7 and a drop-out rate of 10% was anticipated. The survival analysis was estimated by Kaplan–Meier (product limit estimator) and graphed. The low-rank test for trend (Mantel–Cox) was performed to evaluate survival functions (level of significance: 0.05). For the other experimental analyses, values represent the mean \pm SD for each separate experiment. Comparisons between groups were performed by analysis by one-way ANOVA. Additionally, Newman–Keuls test was used as a *post hoc* to assess differences between the means of the different groups. A *p*-value of less than 0.05 was considered significant. Statistical analyses were performed using GraphPad Prism 6.0 software (GraphPad Software Inc., CA, USA).

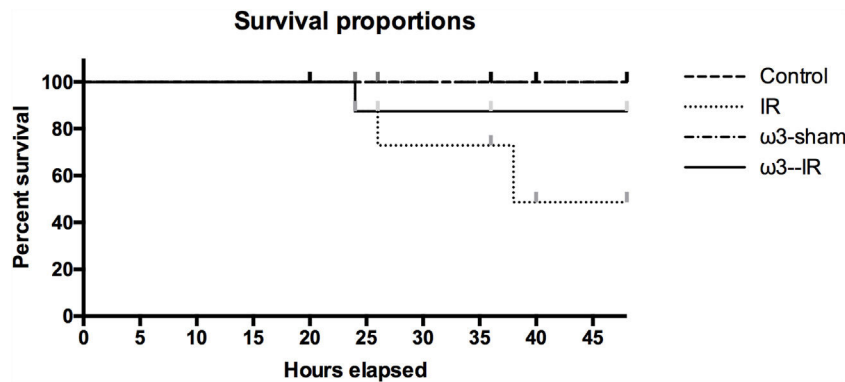


Fig. 1. Kaplan–Meier curve for the survival rate after ischemia surgery. Values were analyzed for statistical significance of differences with Kaplan–Meier survival analysis. All $p > 0.05$ compared with control values.

3. Results

The number of animals that died and the survival rate at the end of study (48 h) is summarized in Table 2. There were no significant differences in the survival rate between the control and the $\omega 3$ groups with a 100%, 100% and 88%, respectively ($p < 3.41$, Fig. 1). Statistical significance was observed between the control and IR (100% and 48%, respectively, $p < 0.0333$). $\omega 3$ administration was innocuous for rats ($\omega 3$ -sham). The cause of death (including sacrifices by mercy) was estimated from clinical observation and histopathological examination. All deaths were related to IR causes and any other cause of death was excluded.

In agreement with our previous studies [4,9], the histological assessment showed normal liver histology in control and $\omega 3$ -sham groups from 20 to 48 h (Fig. 2a), whereas substantial liver necrosis, altered architecture and degenerative changes were observed in the non-supplemented IR animal group (Fig. 2a). Masson's Trichrome staining (Fig. 2b) revealed an exacerbation in extracellular matrix (ECM) deposits in the IR group. This resulted in the formation of some continuous fibrotic septa at 48 h of reperfusion. In comparison, the $\omega 3$ -IR showed normal architecture with less necrotic areas compared to the IR group (Fig. 3a). The IR group showed 27.5%, 25.5% and 27.5% necrotic areas at 20, 24 and 48 h, respectively. In comparison, $\omega 3$ -IR has 12.5%, 12.5% and 7.5% necrotic areas at the same assayed times (differences among the groups: $p < 0.005$ for 20 h; $p < 0.001$ for 24 h and $p < 0.01$ for 48 h). When the fibrotic index was analyzed, the $\omega 3$ -IR group showed minimal connective deposit in the tissue compared with the IR group at 24 and 48 h (Fig. 2b). The IR group showed an increase of fibrotic areas (Fig. 3) over time with a peak at 48 h in comparison with all the other groups, with a mean fibrotic score of 3.5 ($p < 0.001$); $\omega 3$ -IR had a mean score of two and the control group a score near 0.

ALT and AST levels were significantly increased in the IR group after liver reperfusion at 3–24 h (Fig. 3c and d, respectively). This effect was suppressed by $\omega 3$ over the 48 h ($p < 0.01$). ALT values were normalized at 48 h in all the groups, but AST remained elevated in the IR animals (mean of $302 \text{ UI/L} \pm 23.5$, $p < 0.01$). Plasma 8-isoprostane levels in the control and $\omega 3$ -sham were comparable throughout the entire experiment (Fig. 4). Isoprostanes showed an elevation at 3 h of reperfusion in the $\omega 3$ -IR group ($p < 0.01$), which later declined until reaching control values at 20 h. Isoprostane levels in the IR group were elevated after 3 h and maintained until the end of study.

The cytokine tissue levels were evaluated by RT-qPCR. TNF- α (Fig. 5a) and IL-1 β (Fig. 5b) increased at 20 and 48 h in the IR group compared to the control. The EPA + DHA administration reduced these effects. IL-10 (Fig. 5c) showed a significant increase in the

$\omega 3$ -IR group at 20 h with a normalization of the IL-10 values at the end of the study. The IR group had no statistical differences with the control in all the assayed times.

4. Discussion

In this study, the main idea was to assess the beneficial effect of omega-3 fatty acids on survival in IR liver injury in an animal model. In order to estimate the potentially harmful effect of liver IR on survival, the animals were divided into four groups. Then, they were analyzed until 48 h after ischemia. The survival rates are directly related with the damage caused by IR. IR is a process associated to the initial damage caused to tissue when oxygen blood flow and nutrient delivery are deficient. In the liver, the IR injury occurs in medical-surgery situations like vascular exclusion, hepatic trauma and clamping during hepatectomy [4,14]. It was previously reported that supravisceral aortic clamping, intestinal cold ischemia, and fatty liver plus IR generated a decreased survival rate due to surgical damage [12,13,15]. In this study, it was found that $\omega 3$ attenuates the IR and organ damage, resulting in an increased survival rate, mitigating the effects of hepatic injury induced by long-stage reperfusion.

The mechanism for the $\omega 3$ -improved survival was related to the inhibition of the inflammatory response with an anti-inflammatory compensatory effect. This indicated a primary inflammation deactivation response with a possible return to homeostasis, which is a situation that apparently fails in the non-supplemented animals. This shows an exacerbation of TNF- α and IL-1 β with death as a final result. IL-10 is one of the most effective anti-inflammatory cytokines with important counterbalancing hyperactive immune responses to protect body cells and organ damage [16,17]. Through histological findings, pre-treatment with $\omega 3$ resulted in less tissue damage related to an early expression of IL-10 and a decrease in TNF- α leading to a reduction of hepatotoxicity and a modulation of the inflammatory cascade [18–20]. The suppression of inflammation by $\omega 3$ is complex; $\omega 3$ suppresses inflammation by (a) competing with $\omega 6$ for cyclooxygenase and lipoxygenase-mediated inflammatory eicosanoid production; (b) forming COX-generated $\omega 3$ eicosanoids that bind weakly to eicosanoid receptors; and (c) forming anti-inflammatory/pro-resolving $\omega 3$ derived oxylipins, e.g., resolvins, protectins [7].

The immune response observed in this study would be directly related with K upffer cells' activity, which are specialized M Fs located in the liver. Activation and functions of these M Fs are down-regulated by several factors including the tumor growth factor (TGF)- β , IL-4, IL-13, and IL-10. This last one appears to exert the most important effects [21]. It has been reported that IL-10 can also down-regulate the expression of NF- κ B, inhibiting the

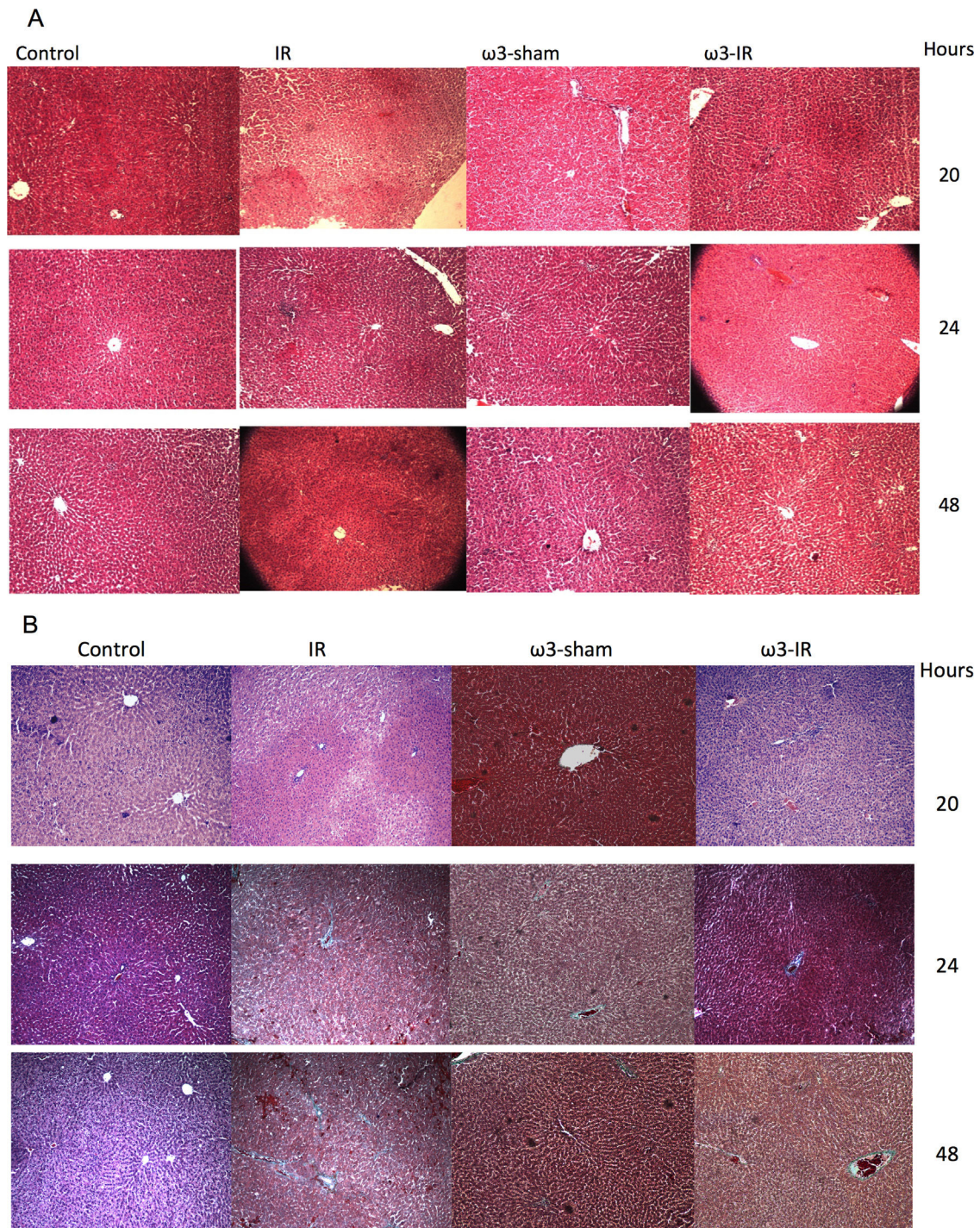


Fig. 2. EPA plus DHA inhibited ischemia–reperfusion liver injury in Sprague-Dawley rats. Representative micrographs of H&E (a) and Masson's Trichrome (b) staining. Representative images. Magnification at 400x.

proinflammatory cytokine synthesis [22]. Also, TGF- β and IL-10 have induced the activation of a subtype of M Φ s (M2, a phenotype associated to anti-inflammation) that mediates (Th1/Th2) immune responses [23]. Several lines of evidence show that M1 Kupffer cells induce liver damage for their ability to secrete proinflammatory factors (e.g., TNF- α , IL-6), reactive oxygen species (ROS) and inducible oxide nitric synthase [24]. Furthermore, it has been reported that the M1 M Φ s phenotype can aggravate liver injury [25]. Recently, studies have shown that mice with a depletion of M2 Kupffer cell pathways had delayed repair in liver injury because IL-10 was not released [26]. Moreover, M2 Kupffer cells interplay

with bona fide stem cells or progenitor cells to contribute to liver repair [27]. According to our data, we can postulate that EPA + DHA generates a polarization of Kupffer cells towards the M2 phenotype, resolving the inflammatory response and promoting tissue repair.

The resolution of inflammation involves the termination of neutrophil recruitment, counter-regulation of proinflammatory mediators, stimulation of M Φ s-mediated clearance, and tissue remodeling. In other words, they actively dismantle the inflammatory cascade, leading the “come back” to homeostasis and tissue function [28,29]. Serhan and Chiang [30] postulate that the resolution of inflammation is related to DHA/EPA lipid mediators, coined

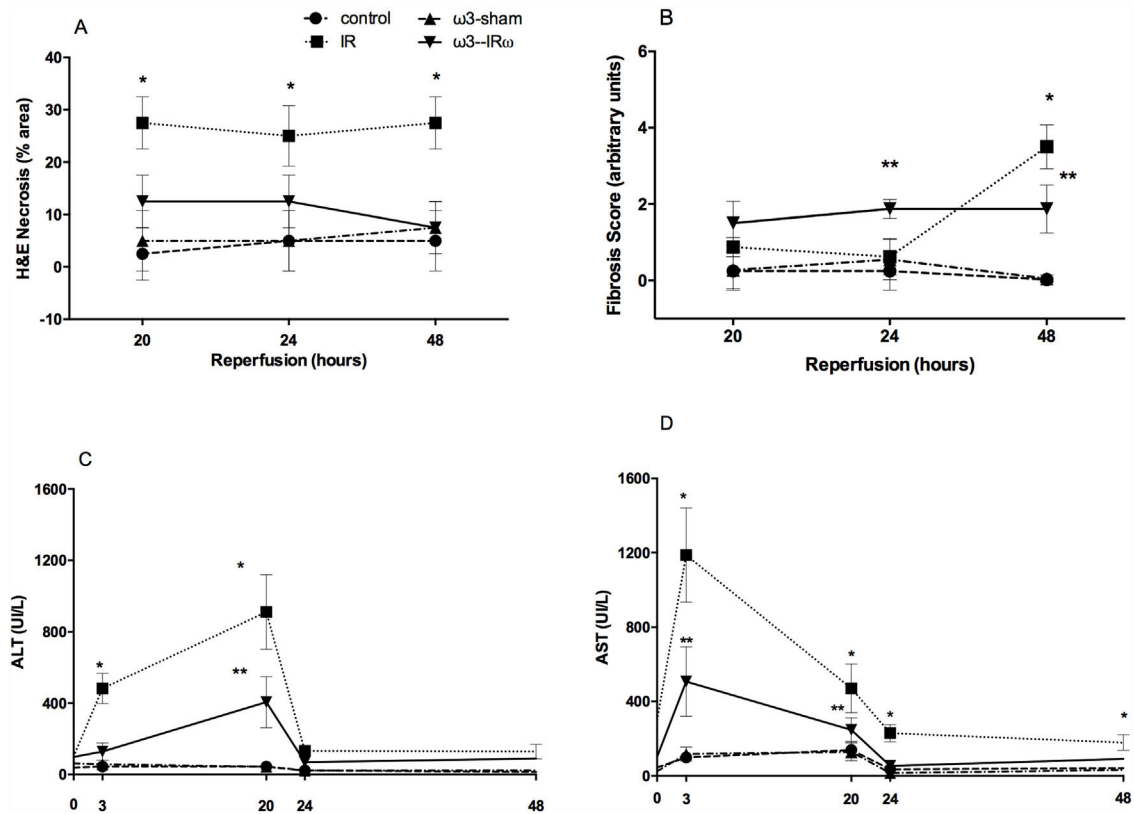


Fig. 3. Necrosis area analysis of the H&E and fibrosis Ishak score of Masson's Trichrome stain micrographs (a and b) and the change of serum ALT (c) and AST (d) levels. Data are expressed as means \pm SD ($n = 7-9$ per experimental group). All statistical analyses were done by one-way ANOVA followed by the Newman-Keuls' test. *,** $p < 0.05$, where * significance of IR group and ** significance of ω3-IR group.

resolvin, protectins and maresins. They have the ability to stimulate the resolution of inflammation without immune suppression [30], limiting PMN infiltration and stimulating phagocytosis and the uptake of apoptotic cells [31–33]. Moreover, Maresin 1, a DHA lipid derivative, mitigates acute carbon tetrachloride-induced liver injury in mice with the depletion of ROS activity and enhances IL-10 [34]. The presence of these lipid derivatives could explain the positive effects observed by the EPA + DHA administration in this study.

In addition, histopathological changes in connective tissue deposits undergoing IR were analyzed. An accumulation of connective tissue was observed, which resulted in the formation of some continuous fibrotic septa by collagen ECM deposit, necrosis and alterations in the central vein. This situation was not exhibited when ω3 was supplemented. ECM regulates various cellular functions, such as differentiation, proliferation, and survival. A deregulation of ECM production and proteolysis is often associated with the development of a liver pathology, associated to a persistent inflammatory response and an increased accumulation of ECM. This deregulation progressively replaces the liver parenchyma by scar fibrotic tissue [35]. Additionally, it has been described that animals that gradually increase hepatic ECM is associated with a progressive systemic derangement, splanchnic hemodynamic changes and altered serum concentration of transaminases, similar to events observed in humans [36].

Recent data has shown that EPA and/or DHA have beneficial effects on the liver in several aspects but the number of studies focusing on the effects on liver regeneration is relatively few. Firat et al., demonstrated that ω3 alleviates the oxidative stress that resulted during the regeneration process of the liver and propose that the suppression of IL-1 and TNF- α are in part responsible for the retardation in liver regeneration [37]. The data reported here

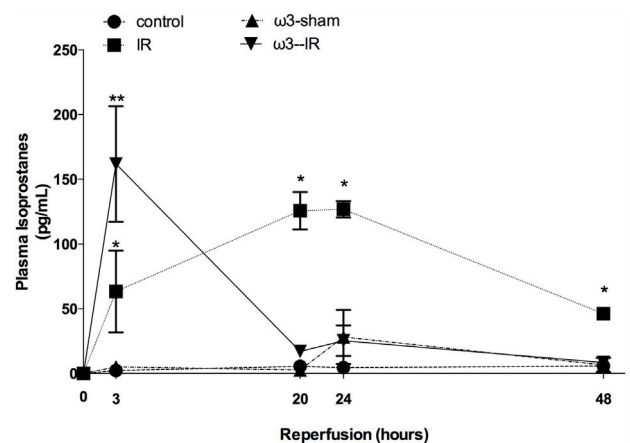


Fig. 4. Effect of ω3 supplementation on the plasma levels of 8-isoprostanes after hepatic IR, as a function of the reperfusion time. Data are expressed as means \pm SD ($n = 7-9$ per experimental group). $p < 0.05$ versus values at time 0, 20, 24 and 48 h of reperfusion. All statistical analyses were done by one-way ANOVA followed by the Newman-Keuls' test. * $p < 0.05$.

supports the role of ω3 in the prevention of extended stages of IR. The ω3 administration prevented and promoted the restoration of the liver tissue of the animals subjected to liver injury, observed by recovering the liver architecture and depleting inflammation. The effects in this study may be due to the return to homeostasis that was mediated by the production of ω3 lipid derivatives. These derivatives reduce proinflammatory cytokines with an increase in IL-10, probably by promoting a M2 over M1 Kupffer cells phenotype.

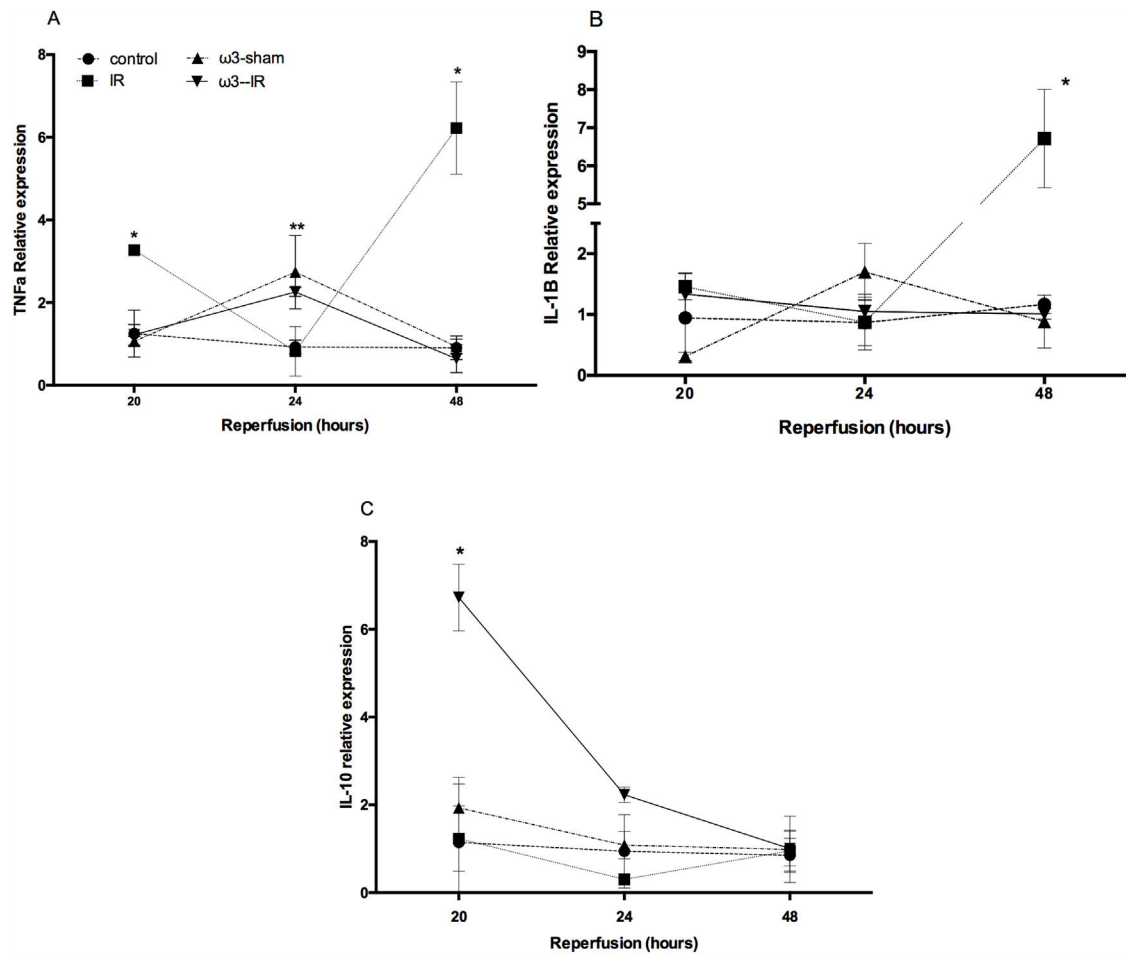


Fig. 5. Effect of ω3 supplementation on liver TNF-α, IL-1β and IL-10 mRNA relative expression by RT-qPCR analysis after IR. (a) TNF-α; (b) IL-1β and (c) IL-10. GAPDH was used as housekeeping. Data are expressed as means ± SD (n = 7–9 per experimental group). All statistical analyses were done by one-way ANOVA and the Newman–Keuls’ test. *p < 0.05.

Abbreviations

- ALT alanine aminotransferase
- AST aspartate aminotransferase
- DHA docosahexaenoic acid
- EPA eicosapentaenoic acid
- GAPDH glyceraldehyde-3-phosphate dehydrogenase
- IR ischemia–reperfusion
- KC K upffer cells
- MΦs macrophages
- NADH nicotinamide adenine dinucleotide
- NAFLD non-alcoholic liver disease
- ROS reactive oxygen species
- RT-qPCR real time quantitative polymerase chain reaction
- TGF-β tumor growth factor beta
- TNF-α tumor necrosis factor
- ω3 the omega-3 fatty acids

Author contributions

Conceived and designed the experiments: NC, JZH. Performed the experiments: NC, AT, JZH. Analysis of data: NC, MJR, JZH. Contributed reagents/materials/analysis tools: JZH. Wrote the paper: NC, MJR, JZH.

Conceived and designed the experiments: NC, JZH. Performed the experiments: NC, AT, JZH. Analysis of data: NC, MJR, JZH. Contributed reagents/materials/analysis tools: JZH. Wrote the paper: NC, MJR, JZH.

Financial support

Investigation Internal Project I002974 (Direcci n de Investigaci n, Universidad de Talca).

Conflicts of interest

The authors have no conflicts of interest to declare.

Acknowledgement

This work was supported by grant I002974 from the Direcci n de Investigaci n, Universidad de Talca, Chile.

References

- [1] de Oliveira M, Nabavi SF, Nabavi SM, Jardim F. Omega-3 polyunsaturated fatty acids and mitochondria, back to the future. *Trends Food Sci Technol* 2017;67:76–92.
- [2] Yates CM, Calder PC, Ed Rainger G. Pharmacology and therapeutics of omega-3 polyunsaturated fatty acids in chronic inflammatory disease. *Pharmacol Ther* 2014;141:272–82.
- [3] Ruess DA, Probst M, Marjanovic G, Wittel UA, Hopt UT, Keck T, et al. HDACi valproic acid (VPA) and suberoylanilide hydroxamic acid (SAHA) delay but fail to protect against warm hepatic ischemia–reperfusion injury. *PLOS ONE* 2016;11:e0161233.
- [4] Z niga J, Cancino M, Medina F, Varela P, Vargas R, Tapia G, et al. N-3 PUFA supplementation triggers PPAR-α activation and PPAR-α/NF-κB interaction: anti-inflammatory implications in liver ischemia–reperfusion injury. *PLoS One* 2011;6:e28502.

- [5] Guicciardi ME, Malhi H, Mott JL, Gores GJ. Apoptosis and necrosis in the liver. *Compr Physiol* 2013;3:977–1010.
- [6] Hong JM, Kim SJ, Lee SM. Role of necroptosis in autophagy signaling during hepatic ischemia and reperfusion. *Toxicol Appl Pharmacol* 2016;308:1–10.
- [7] Jump D, Lytle K, Depner C, Tripathy S. Omega-3 polyunsaturated fatty acids as a treatment strategy for nonalcoholic fatty liver disease. *Pharmacol Ther* 2017;17:30187–90.
- [8] Kim K, Jung N, Lee K, Choi J, Kim S, Jun J, et al. Dietary omega-3 polyunsaturated fatty acids attenuate hepatic ischemia/reperfusion injury in rats by modulating toll-like receptor recruitment into lipid rafts. *Clin Nutr* 2013;32:855–62.
- [9] Zúñiga J, Venegas F, Villarreal M, Núñez D, Chandía M, Valenzuela R, et al. Protection against in vivo liver ischemia–reperfusion injury by n-3 long-chain polyunsaturated fatty acids in the rat. *Free Radic Res* 2010;44:854–63.
- [10] Korourian S, Hakkak R, Ronis MJ, Shelnutt SR, Waldron J, Ingelman-Sundberg M, et al. Diet and risk of ethanol-induced hepatotoxicity: carbohydrate–fat relationships in rats. *Toxicol Sci* 1999;47:110–7.
- [11] Sun Y, Zhou J, Wang L, Wu X, Chen Y, Piao H, et al. New classification of liver biopsy assessment for fibrosis in chronic hepatitis B patients before and after treatment. *Hepatology* 2017;65:1438–50.
- [12] Fujimura N, Obara H, Suda K, Takeuchi H, Miyasho T, Kawasako K, et al. Neutrophil elastase inhibitor improves survival rate after ischemia reperfusion injury caused by supravisceral aortic clamping in rats. *J Surg Res* 2013;180:e31–6.
- [13] Lausada N, Stringa P, Cabanne A, Ramisch D, Machuca M, Galvao F, et al. Impacto de las lesiones por isquemia–reperfusion en la supervivencia alejada de ratas con trasplante intestinal. *Acta Gastroenterol Latinoam* 2011;41:129–36.
- [14] Papadopoulos D, Siempis T, Theodorakou E, Tsoulfas G. Hepatic ischemia and reperfusion injury and trauma: current concepts. *Arch Trauma Res* 2013;2:63–70.
- [15] Kimura K, Shirabe K, Yoshizumi T, Takeishi K, Itoh S, Harimoto N, et al. Ischemia–reperfusion injury in fatty liver is mediated by activated NADPH oxidase 2 in rats. *Transplantation* 2016;100:791–800.
- [16] Hammerich L, Tacke F. Interleukins in chronic liver disease: lessons learned from experimental mouse models. *Clin Exp Gastroenterol* 2014;7:297–306.
- [17] Bliss SK, Alcaraz A, Appleton JA. IL-10 prevents liver necrosis during murine infection with *Trichinella spiralis*. *J Immunol* 2003;171:3142–7.
- [18] Louis H, Van Laethem JL, Wu W, Quertinmont E, Degraef C, Van den Berg K, et al. Interleukin-10 controls neutrophilic infiltration, hepatocyte proliferation, and liver fibrosis induced by carbon tetrachloride in mice. *Hepatology* 1998;28:1607–15.
- [19] Arai T, Hiromatsu K, Kobayashi N, Takano M, Ishida H, Nimura Y, et al. IL-10 is involved in the protective effect of dibutylryl cyclic adenosine monophosphate on endotoxin-induced inflammatory liver injury. *J Immunol* 1995;155:5743–9.
- [20] Louis H, Le Moine O, Peny M, Quertinmont E, Fokan D, Goldman M, et al. Production and role of interleukin-10 in concanavalin A-induced hepatitis in mice. *Hepatology* 1997;25:1382–9.
- [21] Thompson K, Maltby J, Fallowfield J, McAulay M, Millward-Sadler H, Sheron N. Interleukin-10 expression and function in experimental murine liver inflammation and fibrosis. *Hepatology* 1998;28:1597–606.
- [22] Moore KW, O'garra A, Malefyt RDW, Vieira P, Mosmann TR. Interleukin-10. *Annu Rev Immunol* 1993;11:165–90.
- [23] Ramachandran P, Pellicoro A, Vernon MA, Boulter L, Aucott RL, Ali A, et al. Differential Ly-6C expression identifies the recruited macrophage phenotype, which orchestrates the regression of murine liver fibrosis. *Proc Natl Acad Sci* 2012;109:E3186–95.
- [24] Dey A, Allen J, Hankey-Giblin PA. Ontogeny and polarization of macrophages in inflammation: blood monocytes versus tissue macrophages. *Front Immunol* 2015;22:683–715.
- [25] Lee J, French B, Morgan T, French SW. The liver is populated by a broad spectrum of markers for macrophages. In alcoholic hepatitis the macrophages are M1 and M2. *Exp Mol Pathol* 2014;96:118–25.
- [26] Antoniadis CG, Quaglia A, Taams LS, Mitry RR, Hussain M, Abeles R, et al. Source and characterization of hepatic macrophages in acetaminophen-induced acute liver failure in humans. *Hepatology* 2012;56:735–46.
- [27] Melgar-Lesmes P, Edelman ER. Monocyte–endothelial cell interactions in the regulation of vascular sprouting and liver regeneration in mouse. *J Hepatol* 2015;63:917–25.
- [28] Dalli J, Colas R, Serhan CN. Novel n-3 immunoresolvents: structures and actions. *Sci Rep* 2013;3:1–13.
- [29] Spite M, Clària J, Serhan CN. Resolvins, specialized proresolving lipid mediators, and their potential roles in metabolic diseases. *Cell Metab* 2014;19:21–36.
- [30] Serhan CN, Chiang N. Resolution phase lipid mediators of inflammation: agonist of resolution. *Curr Opin Pharmacol* 2013;13:632–40.
- [31] Serhan CN. Systems approach to inflammation–resolution: identification of novel anti-inflammatory and pro-resolving mediators. *J Thromb Haemost* 2009;7:44–8.
- [32] Serhan CN, Yang R, Martinod K, Kasuga K, Pillai P, Sungwhan P, et al. Maresins: novel macrophage mediators with potent anti-inflammatory and pro-resolving actions. *J Exp Med* 2009;16:15–23.
- [33] Buckley C, Gilroy D, Serhan CN. Proresolving lipid mediators and mechanisms in the resolution of acute inflammation. *Immunity* 2014;40:315–27.
- [34] Li R, Wang Y, Zhao E, Wu K, Li W, Shi L, et al. Maresin 1, a proresolving lipid mediator, mitigates carbon tetrachloride-induced liver injury in mice. *Oxid Med Cell Longev* 2016;2016:9203716.
- [35] Duarte S, Baber J, Fujii T, Coito AJ. Matrix metalloproteinases in liver injury, repair and fibrosis. *Matrix Biol* 2015;44–46:147–56.
- [36] Marfà S, Morales-Ruiz M, Oró D, Ribera J, Fernández-Varo G, Jiménez W. Sipa111 is an early biomarker of liver fibrosis in CCl4-treated rats. *Biol Open* 2016;5:858–65.
- [37] Firat O, Makay O, Yeniay L, Gokce G, Yenisey C, Coker A. Omega-3 fatty acids inhibit oxidative stress in a rat model of liver regeneration. *Ann Surg Treat Res* 2017;93:1–10.