

series, being the last option of treatment, the portosystemic derivation, which has shown suboptimal results. There are no established guidelines for its management because the evidence of the different therapeutic options is insufficient.

**Conclusion:** Embolization of hemorrhoidal vessels with refractory bleeding is a good alternative for bleeding control in patients with liver cirrhosis.

**Funding:** The resources used in this study were from the hospital without any additional financing

**Declaration of interest:** The authors declare no potential conflicts of interest.

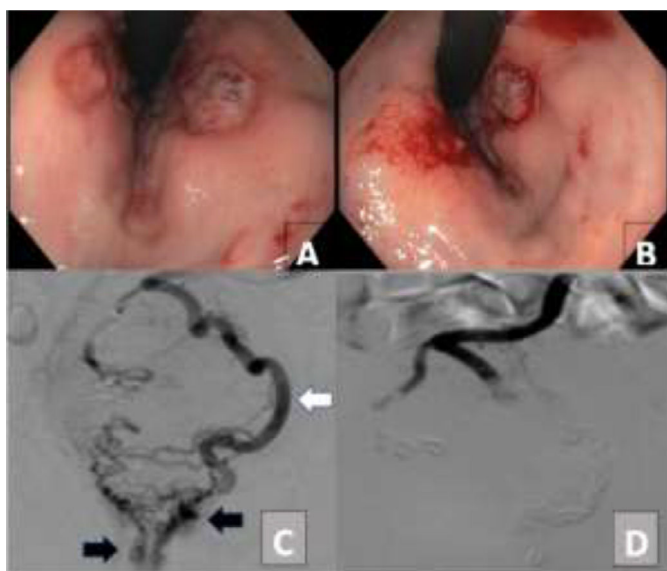


Figure 1. A Retroflexion colonoscopy shows post-ligation ulcers with active bleeding. 1.B Venography of superior hemorrhoidal veins with dilatation of left system (white arrow) and contrast leakage at distal rectum (black arrows). 1.C-D. Embolization with coils/Histoacryl, showing absence of distal contrast.

<https://doi.org/10.1016/j.aohep.2022.100798>

### Causes of decompensation of liver cirrhosis and predictors of in-hospital mortality in patients admitted to the gastroenterology service of the Regional Hospital Lic. Adolfo López Mateos in the years 2017 - 2018

M Velasco Gutiérrez, M Ortiz Aguirre, EG Salgado Parra

Regional Hospital "LIC. Adolfo López Mateos", ISSSTE, México.

**Introduction and Objectives:** Identify the main causes of liver cirrhosis decompensation and predictors of in-hospital mortality in patients admitted to the Gastroenterology service of the RH. Lic. Adolfo López Mateos in the years 2017 and 2018.

**Material and Methods:** Daily digital censuses from 2017 and 2018 were used, and patients diagnosed with decompensated cirrhosis and laboratory studies were included. The statistical software STATA V 16.0 was used, and the incremental model with  $p < 0.000$  and the VIF test and goodness of fit with the HOSMER-LEMESHOW test were performed.

**Results:** Two hundred fifty-five Patients were included, and the most frequent causes of decompensation were; ascites at 35%, encephalopathy at 34% and variceal hemorrhage at 22% (image 1).

The three variables that resulted in a risk for in-hospital mortality were: elevated creatinine levels, encephalopathy, and spontaneous bacterial peritonitis.

**Discussion:** Ascites as the first cause of liver cirrhosis decompensation is the same reported in international studies; a difference was observed in the second cause, which could be due to the fact that the sample of patients is small. Patients with any degree of encephalopathy, SBP and elevated creatinine levels had higher in-hospital deaths.

**Conclusions:** Ascites, followed by hepatic encephalopathy and variceal hemorrhage, were the most frequent causes of decompensation in patients with liver cirrhosis admitted to the Gastroenterology service of RH Lic. Adolfo López Mateos in the years 2017 and 2018. The early identification of poor prognosis factors and the initiation of targeted treatment could improve the prognosis of patients.

**Funding:** The resources used in this study were from the hospital without any additional financing

**Declaration of interest:** The authors declare no potential conflicts of interest.

<https://doi.org/10.1016/j.aohep.2022.100799>

### Hepatic hydrothorax resistant to diuretics treated with octreotide

S Teutli-Carrión, C Sánchez-Sánchez, E Medina-Ávalos, M Carmona-Castillo, C Dorantes-Nava, F Higuera-de la Tijera, JL Pérez-Hernández

General Hospital of Mexico "Dr. Eduardo Liceaga," Mexico City, Mexico

**Introduction and Objective:** Hepatic hydrothorax is the excessive accumulation of transudate in the pleural cavity, secondary to portal hypertension in cirrhotic patients without existing cardiopulmonary disease. Treatment includes a reduction in ascites production, prevention of ascites transfer to the pleural space, pleural fluid removal, pleural space obliteration, and liver transplantation. This study aimed to report a case of hepatic hydrothorax treated with Octreotide.

**Case Summary:** A 63-year-old man with liver cirrhosis due to alcohol. It began with edema in the pelvic limbs, increased abdominal perimeter, MRC II dyspnea, orthopnea, and chest pain radiating to the back. EF: scleral jaundice, 60% left pleural effusion. Gii ascites, MPI edema (+). He was classified as Child-Pugh C (12 points), Hb 6.2, Leu 2.2, Plts 37,000, INR 2.1, chest X-ray: 100% left pleural effusion. A 1200 cc cytological/cytochemical thoracentesis was performed: transudate according to Light's criteria, GASA >1.1, BNP 87 mg/dl; spironolactone was started up to 200/80 mg, persists with 100% pleural effusion. Octreotide 100mcg is started for five days. He showed improvement at the end of treatment.

**Discussion:** In hepatic hydrothorax, sodium restriction as a treatment is insufficient; the use of diuretics is necessary; up to 30-40% do not respond; the placement of chest tubes is associated with high morbidity, clinical deterioration, TIPS, urgent HT or death. Octreotide, a somatostatin analog, directly inhibits RAAS, improving the efficiency of renal plasma flow and natriuresis.

**Conclusions:** Octreotide can be a useful alternative in hepatic hydrothorax.

**Funding:** The resources used in this study were from the hospital without any additional financing

**Declaration of interest:** The authors declare no potential conflicts of interest.

<https://doi.org/10.1016/j.aohep.2022.100800>