

Declaration of interest: The authors declare no potential conflicts of interest.

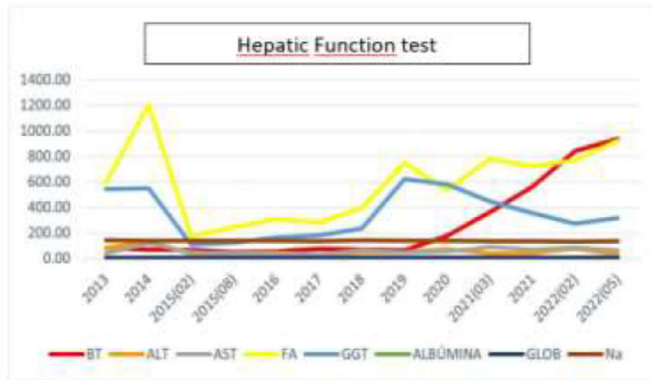


Figure 1. Enzyme evolution

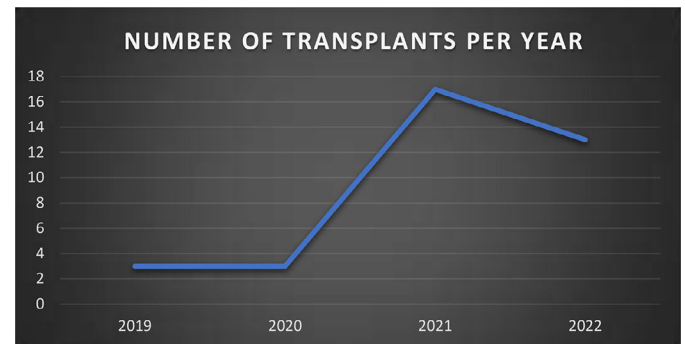


Figure 1.

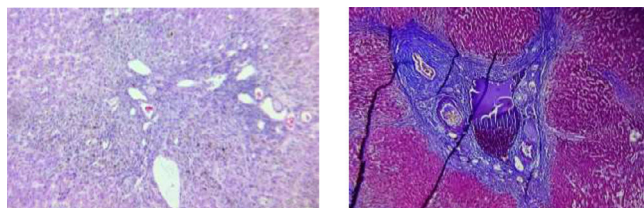


Fig. 2.

<https://doi.org/10.1016/j.aohep.2022.100870>

Liver transplantation, experience at the general hospital of Mexico during the last four years

FI García Juárez, I García-Espinosa,
DF Abendaó Rivera, EJ Medina Avalos,
VM Páez-Zayas, A Sánchez-Cedillo,
MF Higuera-de-la Tijera, JL Pérez Hernández

General Hospital of México “Dr. Eduardo Liceaga”.
México City, México

Introduction and Objectives: Liver disease is increasingly prevalent in the world and in our country, the need for liver transplantation is increasing; In our country, there are more and more centers that perform liver transplantation. This study aimed to report the results of the liver transplant program at the Hospital General of México “Dr. Eduardo Liceaga” (HGM) during the last four years.

Materials and Methods: Retrospective, observational study. The records of all patients who received transplants in the last four years at the HGM were reviewed, documenting age, etiology, transplant indication, survival, and mortality. Descriptive statistics were performed.

Results: For four years, 36 patients were transplanted, 22 men (61.1%) and 14 women (38.9%) aged 51 ± 10.2 years, the most frequent etiology is alcohol consumption (33%), followed by autoimmune hepatitis (17%), and liver disease associated with metabolic dysfunction (14%). Three deaths have been reported. Figures 1 and 2.

Discussion: The experience in liver transplantation in the HGM has increased, although, in the pandemic, there was a global decrease; since they were restarted, the number of transplant patients is increasingly important, already competing with the rest of the centers in the country. The main cause for transplantation is alcohol consumption, which is a very frequent pathology in our country.

Conclusions: The HGM liver transplant program has grown, the main cause of transplantation is alcohol consumption, and mortality is very low.

Funding: The resources used in this study were from the hospital without any additional financing

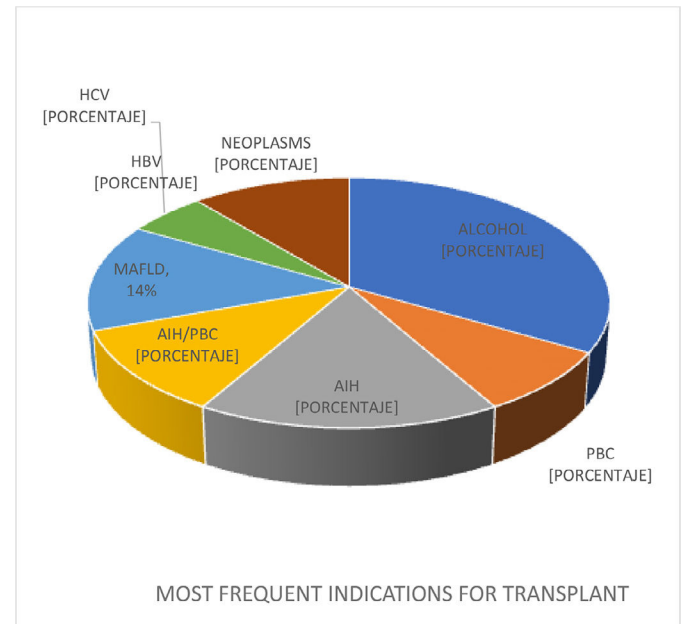


Figure 2.

<https://doi.org/10.1016/j.aohep.2022.100871>

Jejunal lymphoma of large cell high grade B monomorphic in a patient with hepatic transplant

AD Trujillo Lejía¹, M Castillo Barradas¹,
SA García Gutierrez², IM Montoya Fuentes²,
SE Romero Ramos³

¹ Department of Gastroenterology. HE CMN La Raza. IMSS. México City. México

² Pathology Service. HE CMN La Raza. IMSS. México City. México

³ Instituto Mexicano del Seguro Social. México City. Mexico

Introduction and Objective: High-grade monomorphic B-cell jejunal lymphoma in a post-liver transplant patient: the post-transplant lymphoproliferative disease (PTLD) hepatic has an incidence of 3%, 85% for B cells and 15% for T cells. The incidence increases in rich organs with B cells, like the small intestine. The Epstein-Barr virus (EBV) is crucial in the pathogenesis. Up next is the case of a patient post-liver transplant (PLT) with proximal jejunal stenosis for lymphoma. This study aimed to report a case of jejunal lymphoma in a patient with PLTD.