



## Original article

# The contribution of the cingulate cortex: treating depressive symptoms in first-episode drug naïve schizophrenia

Haoran Shen<sup>a,c</sup>, Likun Ge<sup>a,c</sup>, Bo Cao<sup>d</sup>, Gao-Xia Wei<sup>a,c,\*</sup>, Xiangyang Zhang<sup>b,c,\*</sup>

<sup>a</sup> CAS Key Laboratory of Behavioral Science, Institute of Psychology, Chinese Academy of Sciences, Beijing, China

<sup>b</sup> CAS Key Laboratory of Mental Health, Institute of Psychology, Chinese Academy of Sciences, Beijing, China

<sup>c</sup> Department of Psychology, University of Chinese Academy of Sciences, Beijing, China

<sup>d</sup> Department of Psychiatry, Faculty of Medicine & Dentistry, University of Alberta, Alberta, Canada



## ARTICLE INFO

## Keywords:

Schizophrenia

Depression

Treatment

Rostral anterior cingulate cortex

## ABSTRACT

**Background:** Our previous study has shown the cingulate cortex abnormalities in first-episode drug naïve (FEDN) schizophrenia patients with comorbid depressive symptoms. However, it remains largely unknown whether anti-psychotics may induce morphometric change in cingulate cortex and its relationship with depressive symptoms. The purpose of this study was to further clarify the important role of cingulate cortex in the treatment on depressive symptoms in FEDN schizophrenia patients.

**Method:** In this study, 42 FEDN schizophrenia patients were assigned into depressed patients group (DP,  $n = 24$ ) and non-depressed patients group (NDP,  $n = 18$ ) measured by the 24-item Hamilton Depression Rating Scale (HAMD). Clinical assessments and anatomical images were obtained from all patients before and after 12-week treatment with risperidone.

**Results:** Although risperidone alleviated psychotic symptoms in all patients, depressive symptoms were decreased only in DP. Significant group by time interaction effects were found in the right rostral anterior cingulate cortex (rACC) and other subcortical regions in the left hemisphere. After risperidone treatment, the right rACC were increased in DP. Further, the increasing volume of right rACC was negatively associated with improvement in depressive symptoms.

**Conclusion:** These findings suggested that the abnormality of the rACC is the typical characteristics in schizophrenia with depressive symptoms. It's likely key region contributing to the neural mechanisms underlying the effects of risperidone treatment on depressive symptoms in schizophrenia.

## Introduction

Depression is a common concomitant symptom of schizophrenia and can occur at all stages of the illness. A recent meta-analysis of observational studies showed that the prevalence of comorbid depression in patients with schizophrenia was 28.6% (Li et al., 2020). In the Chinese population, the prevalence of depressive symptoms in patients with FEDN schizophrenia is as high as about 50%, with significant age and gender differences (Dai et al., 2017). Depressive symptoms in patients with schizophrenia increase the risk of relapse, suicide, frequency and duration of hospitalization, and decrease social and occupational functioning. Notably, depressive symptoms represent a core component of schizophrenia in first-episode drug-free (FEDN) individuals (Addington et al., 1998; Buckley et al., 2009; Heriman et al., 2021). However, this has not translated into a proportionate clinical understanding or resolution of uncertainty in treatment approaches.

According to the World Federation of Biological Psychiatry Societies Guidelines, second-generation antipsychotics, such as risperidone, have shown beneficial efficacy in reducing depressive symptoms in schizophrenia (Alkomiet et al., 2012; Kasper et al., 2015; Kjølby et al., 2011). Although some comparative studies have found that risperidone is more effective than haloperidol or olanzapine in treating depression in schizophrenia (Conley & Mahmoud, 2001; Peuskens et al., 2000), the clinical efficacy of risperidone treatment remains inconsistent, particularly in treatment-resistant schizophrenia (Roya et al., 2017). Such heterogeneous results may be due to two key confounding factors: the mixing of patients with and without depressive symptoms in studies of treatment response, which reduces the clinical efficacy of risperidone; and the participation of patients with chronic symptoms in treatment studies, whose effects may be influenced by the interplay between the duration and stage of illness and the effects of long-term medication (Piet et al., 2006). Therefore, in order to study the effect of risperidone on depressive symptoms, only schizophrenic patients with

\* Corresponding authors.

E-mail addresses: [weigx@psych.ac.cn](mailto:weigx@psych.ac.cn) (G.-X. Wei), [zhangxy@psych.ac.cn](mailto:zhangxy@psych.ac.cn) (X. Zhang).

FEDN with comorbid depressive symptoms had to be recruited, which undoubtedly excluded the effect of the common confounding variables mentioned above.

Currently, only a few studies have examined the morphological characteristics of schizophrenia patients with depression. An earlier study observed that depressed patients (DP) showed reduced metabolism of the left-sided anterior cingulate cortex (ACC) relative to non-depressed patients (NDP) (Kohler et al., 1998). More recently, our group detected a larger surface area and gray matter volume in the left cingulate cortex of DP (Wei et al., 2020). Although the ACC is a functionally heterogeneous region involved in different cognitive and affective processes, most studies have found that abnormalities in this brain region may underlie the neurobiology of many clinical manifestations of schizophrenia (Fornito et al., 2009). Furthermore, previous studies have identified the ACC as an important region associated with the response to antidepressant treatment. For example, a resting MRI study observed that 12 weeks of antidepressant treatment normalized functional connectivity between the Distal ACC and the left dorsolateral prefrontal cortex, contributing to the prediction of clinical outcomes, suggesting that the damaged ACC can be partially restored after antidepressant treatment (Zhang et al., 2021). Even 8 weeks of antidepressant treatment induced a faster rate of symptoms improvement, which was closely associated with a larger gray matter volume in the ACC (Chen et al., 2007). These findings suggest that the ACC may also be involved in the structural changes induced by antidepressant treatment in schizophrenia. However, no studies have yet examined whether the abnormal structure underpins the treatment response of risperidone in schizophrenia with comorbid depression.

Given the available evidence, we hypothesized that FEDN schizophrenia patients with comorbid depression may exhibit morphological changes after treatment with risperidone, particularly in the ACC, which may predict improvement in depressive symptoms in response to antipsychotic treatment. In this study, we aimed to compare DP and NDP in FEDN patients to detect alterations in brain structure associated with depressive symptoms. In addition, we sought to establish a correlation between abnormalities in brain gray matter structure and clinical symptoms in DP of FEDN patients to explore the neural correlates of the effect of risperidone treatment on depressive symptoms in schizophrenia.

## Methods

### Patients

Forty-two patients (23 females, 19 males) with FEDN schizophrenia were recruited from Beijing Huilongguan Hospital, with an age range of 18-45 years (mean age:  $28.62 \pm 10.18$  years). All participants had no history of concomitant psychotropic medication use. Diagnostic and clinical characteristics were assessed by trained psychiatrists using the structured clinical interview of the DSM-IV, and patients were followed up for approximately 3 months to confirm the diagnosis. Inclusion criteria included 1) meeting DSM-IV criteria for acute schizophrenia, 2) duration of illness not exceeding 60 months, and 3) not receiving antipsychotics or any other medication. Patients were excluded if they had history of head trauma, neurological disorders, and uncontrolled major medical conditions.

Ethical clearance was granted by the Institutional Review Board of Beijing Huilongguan Hospital in accordance with the Declaration of Helsinki guidelines, and written informed consent was obtained from all participants.

### Clinical assessments and treatment

All 42 patients were clinically assessed at baseline and at the end of 12 weeks of risperidone treatment. The Positive and Negative Syndrome Scale (PANSS) was used to assess their psychiatric symptoms (Kay et al.,

1987). Depressive symptoms were assessed by the 24-item Hamilton Depression Scale (HAMD). The HAMD was used to assess the severity of patients' depressive symptoms (Hamilton, 1960). In the present study, patients were divided into two groups using 8 as the cut-off point:  $<8$  for non-depressed patients and  $\geq 8$  for depressed patients (Seon-Cheol et al., 2017).

Risperidone treatment lasted for 12 weeks. During the first week of dosing, the dose was increased from 1 mg to 3-6 mg per day and maintained at these levels until the end of the clinical study. Concomitant medications included chloral hydrate or lorazepam for insomnia and benzhexol hydrochloride as an antiparkinsonian drug for extrapyramidal symptoms as needed. No other concomitant psychotropic medications were used during the study period.

### MRI data acquisition and preprocessing

Structural MRI scans of all patients were acquired with a GE 3 Tesla MRI scanner (GE Healthcare, Buckinghamshire, United Kingdom) in a spoiled gradient echo (SPGR) sequence. Three-dimensional high-resolution T1-weighted images were obtained with the following parameters: repetition time (TR) = 6.2 ms, echo time (TE) = 2.8 ms, flip angle =  $8^\circ$ , field of view (FOV) = 240 mm, slice thickness = 1.2 mm, matrix size =  $256 \times 256$  and slices = 142. During the scan, each subject was lying in a supine position on the scanner bed and was asked to remain stationary for the duration of the imaging time. A foam head frame and cushion were placed around the subject's head.

All scans were visually inspected for validity and then cortical and subcortical reconstruction and volume segmentation were performed using the open source FreeSurfer pipeline (software version 5.3, <http://surfer.nmr.mgh.harvard.edu>). The technical details of these procedures are described elsewhere (Desikan et al., 2006; Fischl et al., 2002; Reuter et al., 2012). The whole procedure consists mainly of motion correction, intensity normalization, automatic topology correction and automatic segmentation of cortical and subcortical regions in the Desikan-Killiany atlas (Desikan et al., 2006; Di Biase et al., 2020; Ghosh et al., 2022; McKenna et al., 2019).

### Statistical analysis

The statistical analysis process was performed by SPSS 26.0 (IBM Corporation, Armonk, NY, USA). First, t-tests or chi-square tests were used to examine group differences in demographic information between DP and NDP. Then, one-way analysis of variance (ANOVA) was used to examine group differences in baseline clinical symptoms by controlling for age, gender, and education. Then, a 2 (group: DP, NDP)  $\times$  2 (time point: baseline, follow-up) repeated measures ANOVA was performed to explore the effect of risperidone treatment on psychotic symptoms and depressive symptoms in DP and NDP by controlling for age, gender, and education.

As for differences in brain volume, changes in regional volume were assessed using a permutation-based nonparametric test with 5000 random permutations. A family-wise error (FWE) correction value (to correct for multiple comparisons in different spaces) of  $p < 0.05$  was considered significant using the no-threshold clustering enhancement method (Smith & Nichols, 2009). Volume values of brain regions showing morphological differences were extracted. A 2 (group: DP, NDP)  $\times$  2 (time point: baseline, follow-up) repeated measures ANOVA was used to analyze the volume changes after DP and NDP treatment.

Finally, partial correlation method was used to analyze the relationship between structural brain changes (follow-up minus baseline) and clinical improvement (follow-up minus baseline) was analyzed by controlling for age, sex, education, and intracranial volume. Statistical significance was defined as  $p < 0.05$ .

**Results**

*Participant characteristics and clinical symptoms*

A total of 24 patients with DP and 18 patients with NDP underwent baseline assessment and were included. As shown in Table 1, there were no significant differences between DP and NDP in terms of age ( $t = 0.17, p > 0.05$ ) and education ( $t = 1.68, p > 0.05$ ), but there was a difference in gender ( $\chi^2 = 5.51, p < 0.05$ ). Compared to NDP, DP scored significantly higher on PANSS total score ( $F = 2.82, p < 0.01$ ), positive symptoms ( $F = 2.50, p < 0.05$ ) and general psychopathology scores ( $F = 3.54, p < 0.001$ ).

*Improvement in clinical symptoms after treatment*

Repeated-measures ANOVA showed a significant interaction between the groups by over time in total scores for PANSS ( $F = 5.60, p < 0.05$ ), general psychopathology ( $F = 8.26, p < 0.01$ ) and HAMD ( $F = 11.50, p < 0.01$ ). For DP, PANSS total score ( $t = -6.30, p < 0.001$ ), general psychopathology ( $t = -6.91, p < 0.001$ ), and HAMD ( $t = -3.89, p = 0.001$ ); for NDP, PANSS total score ( $t = -4.99, p < 0.001$ ) and general psychopathology ( $t = -3.98, p < 0.01$ ) There was a significant improvement, while the improvement for HAMD ( $t = 0.25, p = 0.81$ ) was not significant (Fig. 1).

Main effects analysis of time showed that all clinical symptoms improved after risperidone treatment, including total PANSS score

( $F = 59.63, p < 0.001$ ), positive symptoms ( $F = 57.16, p < 0.001$ ), negative symptoms ( $F = 6.37, p < 0.05$ ), general psychopathology ( $F = 59.16, p < 0.001$ ) and HAMD ( $F = 10.61, p < 0.01$ ) scores. Compared with NDP, DP showed better improvements in PANSS total score ( $F = 4.65, p < 0.05$ ), general psychopathology ( $F = 9.21, p < 0.01$ ) and HAMD scores ( $F = 16.97, p < 0.001$ ).

*Structural changes in gray matter after treatment*

A 2 (time)\*2 (group) ANOVA revealed significant effects in the following brain structures: right rostral anterior cingulate (rACC) ( $F = 5.30, p < 0.05$ ), left pallidum ( $F = 8.34, p < 0.01$ ), left pars orbitalis ( $F = 4.46, p < 0.05$ ), left thalamus ( $F = 4.76, p < 0.05$ ) and left accumbens ( $F = 5.06, p < 0.05$ ) (Table S1, Fig. 1). Further, paired-samples t-tests showed a significant increase in the volume of the rACC ( $t = 2.36, p < 0.05$ ) and left pallidum ( $t = 4.35, p < 0.001$ ) in the DP after treatment compared to baseline. In NDP, brain volumes in the left pars orbitalis ( $t = -5.49, p < 0.001$ ) and left accumbens ( $t = -3.35, p < 0.01$ ) decreased significantly after treatment (Table S1, Fig. 2).

Main effects of time showed that all patients showed increased volumes of the left middle temporal ( $F = 4.90, p < 0.05$ ) and the left pallidum ( $F = 8.00, p < 0.01$ ) after treatment. However, no main effect of group was observed in either DP or NDP. The alteration in right ACC was greater in DP than in NDP ( $F = 7.24, p < 0.01$ ).

*Brain morphological alterations and clinical response*

After controlling for age, sex, education, and intracranial volume, the relationship between structural brain changes and improvement in clinical symptoms was analyzed by partial correlation in the DP and NDP groups, respectively. Results showed that in DP, an increase in right rACC volume was negatively correlated with improvement in HAMD score ( $r = -0.68, p < 0.05$ ); an increase in left pallidum volume was inversely correlated with improvement in PANSS total score ( $r = -0.59, p < 0.05$ ) and general psychopathology score ( $r = -0.68, p < 0.01$ ), respectively. In the NDP, a reduction in left pars orbitalis volume was negatively correlated with improvement in general psychopathology ( $r = -0.74, p < 0.01$ ), and a reduction in left accumbens volume was negatively correlated with improvement in general psychopathology ( $r = -0.66, p < 0.05$ ) (Fig. 3).

In addition, general linear regression analysis was performed to calculate the predictive effect of baseline brain structure on symptoms improvement, and baseline volume of the right rACC was found to be a negative predictor of improvement in depressive symptoms at the trend level ( $R^2 = 0.13, F = 3.57, p = 0.08, \beta = -0.43$ ).

**Table 1**  
Demographic and clinical characteristics in patients at baseline.

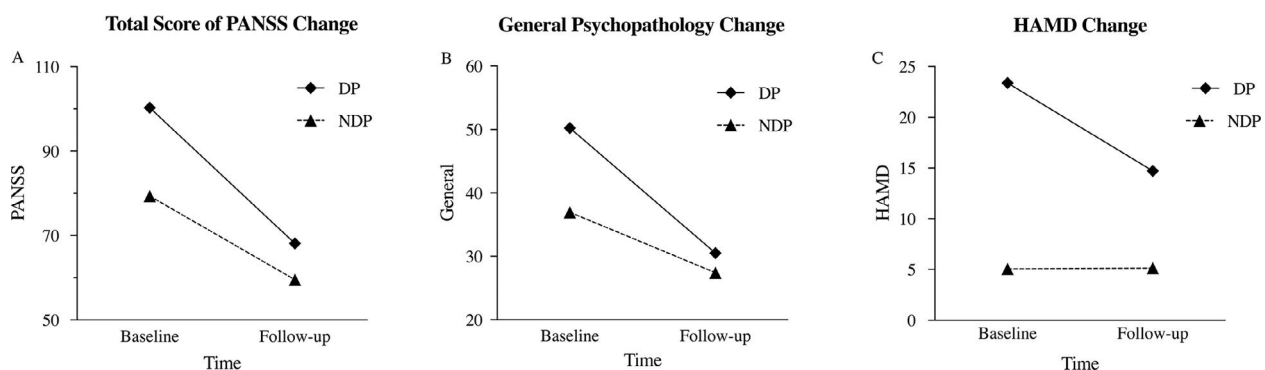
	DP(n = 24)	NDP(n = 18)	$t/\chi^2/F$
Sex(F/M)	10/14	13/5	5.51*
Age(y)	28.35±10.66	28.82±10.15	0.17
Education	11.30±2.51	18.18±19.03	1.68
PANSS			
Total score	100.30±26.41	79.35±17.95	2.82**
Positive symptom	27.17±6.68	22.12±5.83	2.50*
Negative symptom	22.30±11.46	20.59±5.56	0.63
General psychopathology	50.26±14.24	36.76±9.57	3.54**
HAMD	23.86±14.62	5.06±2.11	6.00***

Abbreviations: DP, depressive patients; NDP non-depressive patients; PANSS, Positive and Negative Syndrome Scale; HAMD, Hamilton Depression Scale.

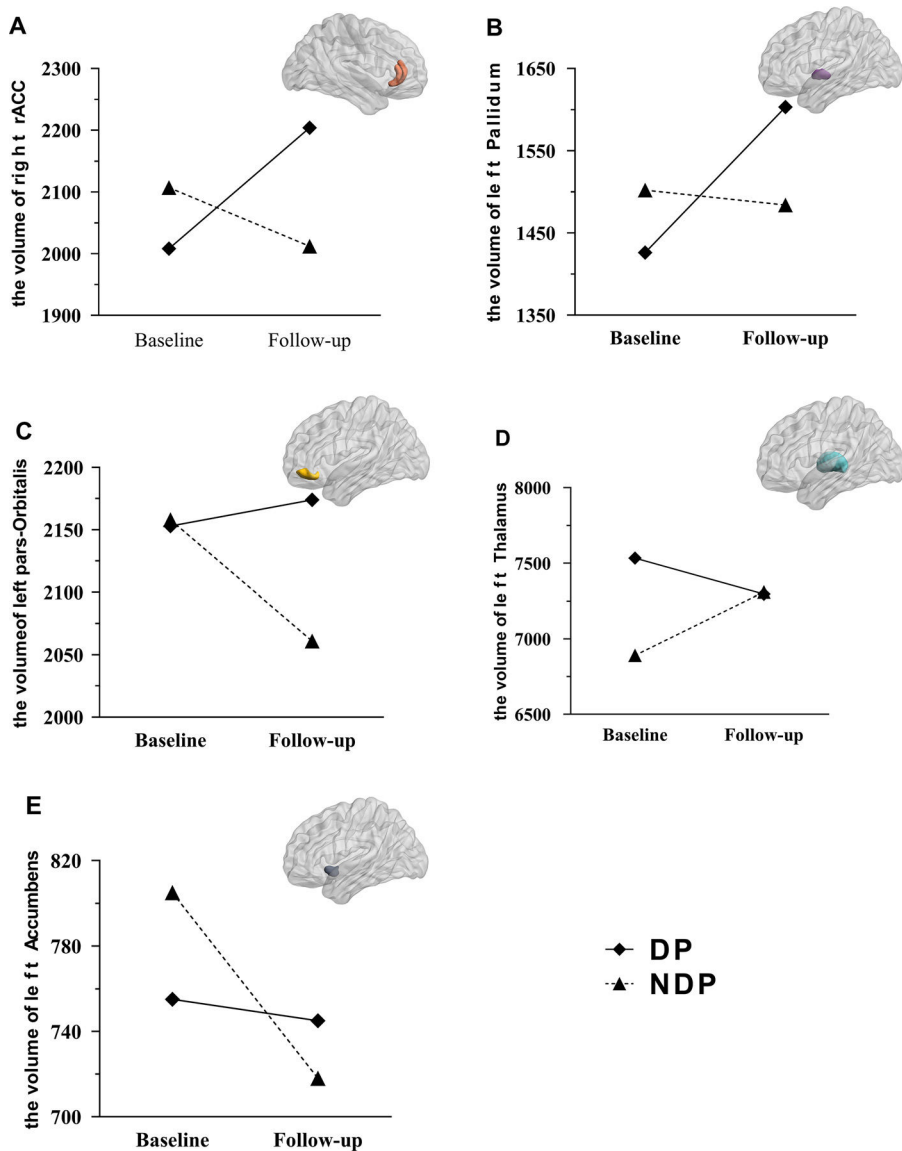
\*\*\*  $p < 0.001$ ,

\*\*  $p < 0.01$ ,

\*  $p < 0.05$ .



**Fig. 1.** Clinical symptoms changes after treatment in DP and NDP. Significant interaction effects of groups by time in total score of PANSS (A), general psychopathology (B) and HAMD (C) were found in clinical symptoms changes after treatment.

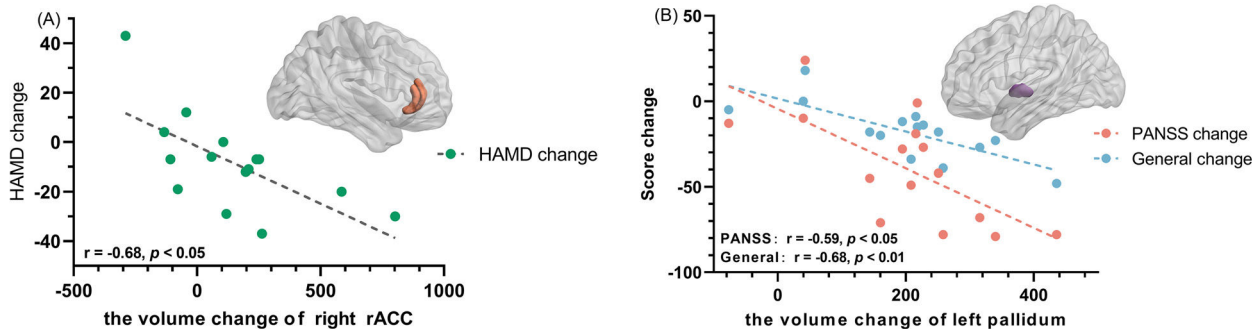


**Fig. 2.** Volume alterations after risperidone treatment. Significant interaction effects of groups by time in the right rostral anterior cingulate (A), left pallidum (B), left pars orbitalis (C), left thalamus (D) and left accumbens (E) were found in volume alterations after treatment.

**Discussion**

To our knowledge, this is the first study to examine the specific effects of risperidone treatment on brain structures associated with depressive symptoms in schizophrenia. In this study, we recruited only patients with first-episode drug naïve schizophrenia to minimize the

potential effects of confounding factors. To examine neural correlates associated with depressive symptoms after risperidone treatment, we divided DP and NDP in this sample to compare their differences in brain structure induced after 12 weeks of risperidone treatment. Consistent with the hypothesis, depressive symptoms were significantly reduced in DP after risperidone treatment, whereas they were not significantly



**Fig. 3.** Relationship between symptoms change and structure volume alteration in DP. Left) the right rACC volume increasing was negatively related to HAMD improvements; Right) the left pallidum volume increasing was negatively related to PANSS total improvements and general psychopathology improvements.

changed in NDP, suggesting a specific effect of risperidone treatment on depressive symptoms in schizophrenia patients with comorbid depression. After risperidone treatment, the volume of the right rACC and left pallidum increased in DP, whereas the brain volume of the left pars orbitalis and left accumbens decreased in NDP. Interestingly, improvements in depressive symptoms were negatively correlated with increases in right rACC volume, whereas improvements in psychotic symptoms were negatively correlated with increases in left pallidum volume, suggesting that the rACC may be a key brain region contributing to the neural mechanisms underlying the effects of risperidone treatment on depressive symptoms in schizophrenia. Furthermore, DP and NDP exhibited different volume changes in subcortical regions after risperidone treatment. These interesting results support our prediction of a role for the cingulate cortex, which may provide meaningful insights for considering the unique diagnosis and treatment of depression in schizophrenia.

#### *Effect of risperidone on improvement of depressive symptoms*

The present study observed the effect of risperidone on the alleviation of depressive symptoms in patients with FEDN schizophrenia, which is consistent with previous studies. The effects of atypical medications, including risperidone, have been reported to be effective in alleviating depressive symptoms in FEDN schizophrenia (Karlıdere et al., 2015). Another study comparing the effects of risperidone and haloperidol observed that risperidone not only improved depressive symptoms in schizophrenia, but its effects were more pronounced than those of haloperidol and placebo. The antidepressant effect of risperidone was evident in those with more severe depressive symptoms (Peuskens et al., 2000). Risperidone is a mixed 5-hydroxytryptamine (5-HT<sub>2</sub>) and dopamine D<sub>2</sub> receptor antagonist that affects the monoaminergic system, including dopamine and 5-hydroxytryptamine (Goto et al., 2006). Antiseropteronic drugs are used clinically to treat depression (Goto et al., 2006), as depression is a mood disorder associated with a decrease in central serotonin turnover (Bernhard, 1997). Therefore, it has been suggested that risperidone may increase central serotonin turnover associated with  $\alpha$ 2-adrenergic receptor antagonism, thereby alleviating depressive symptoms in FEDN schizophrenia (Bernhard, 1997; Hertel et al., 1997). Our results also support the clinical efficacy of risperidone in improving depressive symptoms.

#### *Neural correlates of improvement in depressive symptoms in DP*

The most intriguing finding was that a significant increase in right rACC volume in the DP after risperidone treatment was associated with improved depressive symptoms in the FEDN patients, suggesting a neural mechanism by which risperidone exerted its antidepressant effects by increasing rACC volume. rACC is part of the extended medial prefrontal network, anatomically interconnected with the amygdala and prefrontal cortex (Mayberg, 2003), and is responsible for emotion processing and regulation (Stevens et al., 2011). Over the last decade, both structural MRI and neuropathological findings have shown that abnormalities in the ACC are closely associated with negative symptoms of schizophrenia, including emotion processing (Fornito et al., 2009; Nelson et al., 2015). Only a few studies have used MRI to characterize alterations in this brain region in schizophrenia with comorbid depression. For example, an older study using MRI and 2-fluoro-2-deoxy-D-glucose-positron emission tomography (FDG-PET) showed reduced lateralized metabolism in the ACC in schizophrenia patients in the hyper-depressed group relative to the hypo-depressed group (Kohler et al., 1998). Recently, our group also observed that the volume and surface area of the left cingulate isthmus cortex was smaller in DP relative to NDP (Wei et al., 2020). Thus, the ACC may be an important brain region that is closely related to the psychopathological mechanisms of depressive symptoms in schizophrenia patients.

Although direct neurological evidence on the treatment response to depressive symptoms in schizophrenia is still lacking, most studies on

the treatment of major depression suggest a role for ACC in antidepressant treatment. An fMRI study comparing differences in task-evoked brain activation in patients with depression found increased ACC activity in responders relative to non-responders, suggesting a role for ACC as a promising predictor of antidepressant response (Godlewska et al., 2018). Another study measuring brain structure and function in 17 patients with major depression showed that 8 weeks of treatment significantly improved symptoms associated with greater gray matter volume in ACC (Chen et al., 2007). Recently, it was similarly observed that activation of the subgenual ACC to positive incentives was significantly reduced after rapid antidepressant efficacy in major depressive patients (Morris et al., 2020).

Regarding the cellular mechanisms underlying alterations in rACC volume after schizophrenia treatment, some investigators have suggested that this may be due in part to risperidone-induced alterations in the monoaminergic system. Serotonergic excess in the ACC and dorsolateral frontal lobes is thought to be the underlying cause of schizophrenia, as disruption of glutamatergic signaling by serotonergic excess leads to neuronal hypometabolism and ultimately to synaptic atrophy and gray matter loss (Eggers & Arnold, 2013). Therefore, these disruptions to serotonin and dopamine homeostasis modulate the structure and function of the ACC (Dhana et al., 2018; Simmons et al., 2009). Risperidone may act on the monoaminergic system to block the binding of serotonin and dopamine D<sub>2</sub> receptors (Gener et al., 2019), leading to an increase in rACC volume and improvement in depressive symptoms. In the present study, increased rACC volume after risperidone treatment was negatively correlated with improvement in depressive symptoms, suggesting that the right rACC may be a neural mechanism of depression improvement in schizophrenia patients.

#### *Increased pallidum volume was associated with psychotic symptoms in DP*

In this study, we also observed a greater volume of the left pallidum in DP after treatment relative to NDP, which was negatively correlated with improvement in psychotic symptoms. The pallidum is one of the components of the basal ganglia and is associated with the regulation of movements that occur at the subconscious level. It affects the synaptic neurotransmission of serotonin and dopamine and therefore plays an important role in the pathophysiology of psychosis and in the therapeutic response (Knowland et al., 2017). Many studies have reported volume changes in the pallidum in patients with schizophrenia (E.M. et al., 2016). Furthermore, a large sample imaging study with 884 patients and 1680 healthy individuals found a specific leftward asymmetry in pallidum volume in patients with schizophrenia (Okada N., 2016). Even early adolescents with subclinical psychotic experiences exhibit laterality of pallidal volume to the left in individuals aged 10-13 years (Okada et al., 2018). These results suggest that the pallidum is associated with abnormal functioning of neural pathways and connectivity patterns in patients with schizophrenia. Similar results have been confirmed in major depression patients (Duhameau et al., 2010). Alterations in pallidum volume have also been observed in studies treated with antipsychotic or antidepressant medications. For example, pallidum volumes were larger in patients with long-term treatment compared to those with FEDN schizophrenia (Lang et al., 2001), suggesting that larger pallidum volumes may be related to medication. Another cross-sectional study of clinically high-risk patients with first-episode psychosis found that antidepressant treatment increased the volume of the pallidum (Oleg et al., 2019). Overall, these findings suggest that the pallidum may be a co-occurring structure that contributes to the pathophysiology of comorbid depression in schizophrenia.

#### *Neurological evidence for unique efficacy of risperidone on depressive symptoms in schizophrenia patients*

DP and NDP exhibit different volumetric changes after treatment, suggesting an independent neurological mechanism for the effects of

risperidone on schizophrenia with comorbid depressive symptoms. The vast majority of patients have been reported to have clinically significant depressive episodes at 1 or more time points in the early stages, up to 80%. Schizophrenia patients with depression are more likely to relapse, have more medication-related problems, and report poorer life satisfaction, psychiatric functioning, and medication adherence (Conley et al., 2007). In view of the prevalence, it is suggested that depression is more than comorbidity, which suggest there might be a different pathway to understand its occurrence of depression in schizophrenia. A stress-inflammation-brain structural change pathway has been proposed (Upthegrove et al., 2017), which demonstrated that ACC involving in the pathophysiology of depression is an important brain region to be affected by inflammation. The overactivation of microglial cells might lead to impairment of emotional regulation (Han & Ham, 2021). Thus, it is plausible that indicated that risperidone treatment changed the pathway related to depression via altering rACC volume in DP. Although distinguishing depressive symptoms from schizophrenia is controversial, more evidence from clinical treatment and brain imaging is emerging to demonstrate the unique entity of comorbid with depression in schizophrenia patients (Ceskova, 2020).

### Limitations

This study had several limitations. First, the sample size was relatively small due to the difficulty of recruiting FEDN schizophrenia patients, especially considering the comparison between DP and NDP groups. Moreover, schizophrenia patients were recruited from only one hospital in Beijing, so these results should be replicated with caution. Second, in this study, there was no material control population, which is one of the methodological limitations. Due to lack of control group, effects from aging itself may not be known. According to what is known in the literature, there is progressive changes over time even in the absence of known pathology unique to aging (Schnack et al., 2016). Therefore, there may be age, or other related atrophy or network changes in ROI-regions of interest over time based on literature review for brain structures (Mann et al., 2011; Touroutoglou & Dickerson, 2019). In the future study, a healthy control group will be recruited to remedy this limitation. Third, we did not collect evidence of subclinical seizure(s) or other biological processes that could account for progressive volumetric changes in any brain structure(s) over time, or other confounding process. In future study, these confounding factors should be collected and adjusted to rule out their effects on possible progressive changes in brain structures over time. Forth, for the assessment of depressive symptoms, a more specific measure of the level of depressive symptoms in schizophrenia patients should be used, such as the Calgary Depression Scale for Schizophrenia (CDSS), which is a more specific instrument (Martin-Reyes et al., 2011). Finally, there was a significant difference in gender ratio between DP and NDP groups. Previous studies have found significant gender differences in the prevalence of comorbid depression in large samples of FEDN schizophrenia patients (Yang et al., 2019). Although gender was controlled as a covariate in the following statistical analysis, caution should be taken in drawing conclusions.

### Conclusion

The present study is the first to examine the neural mechanisms of depressive symptoms in FEDN schizophrenia patients treated with risperidone using whole brain morphometry. We found heterogeneous effects on subcortical brain volume in patients with and without depressive symptoms after risperidone treatment. In those schizophrenia patients with depressive symptoms, brain volume changes were evident in rACC, which was also associated with improvement of depressive symptoms. The present results suggest that special attention should be paid to the cingulate cortex, as structural differences in this brain region have been found in schizophrenia patients with depressive symptoms both before and after treatment. Furthermore, these findings may

expand the current understanding of the neural mechanisms underlying depressive symptoms in schizophrenia patients and provide insight into unique entities for the treatment of schizophrenia complicated by depression.

### Contributors

Xiangyang Zhang was responsible for conceptualization, data curation, and formal analysis. Gao-Xia Wei was responsible for funding acquisition. Gao-Xia Wei and Xiangyang Zhang were responsible for investigation, methodology, project administration, resources. Bo Cao and Likun Ge was responsible for software, supervision and validation. Haoran Shen and Likun Ge were responsible for visualization. Haoran Shen was responsible for writing - original draft. Gao-Xia Wei and Xiangyang Zhang were responsible for writing - review & editing.

### Declaration of Competing Interest

All authors declare no conflict of interests.

### Acknowledgements

Dr. Cao was supported in part by Alberta Innovates, the Canada Research Chairs program, NARSAD Young Investigator Grant of The Brain & Behavior Research Foundation, MITACS Accelerate program, Simon & Martina Sochatsky Fund for Mental Health, the Alberta Synergies in Alzheimer's and Related Disorders (SynAD) Program, and University of Alberta Hospital Foundation.

### Funding

This work was supported by the National Natural Science Foundation of China [31671163], Scientific Foundation of Institute of Psychology, Chinese Academy of Sciences [E2CX3815CX].

### Supplementary materials

Supplementary material associated with this article can be found, in the online version, at doi:10.1016/j.ijchp.2023.100372.

### References

- Addington, D., Addington, J., & Patten, S. (1998). Depression in people with first-episode schizophrenia. *The British Journal of Psychiatry*, 172(33), 90–92 Supplement.
- Alkomiet, H., Peter, F., Thomas, W., Jeffrey, L., Birte, G., F. G. W., Florence, T., & Hans-Jürgen, M. (2012). World Federation of Societies of Biological Psychiatry (WFSBP) Guidelines for Biological Treatment of Schizophrenia, part 1: update 2012 on the acute treatment of schizophrenia and the management of treatment resistance. *The World Journal Of Biological Psychiatry: The Official Journal of the World Federation of Societies of Biological Psychiatry*, 13(5), 318–378.
- Bernhard, R. (1997). Can risperidone be antidepressive and also inhibit aggression? *Journal of Neuropsychiatry & Clinical Neurosciences*, 9(4), 627–628.
- Buckley, P. F., Miller, B. J., Lehrer, D. S., & Castle, D. J. (2009). Psychiatric comorbidities and schizophrenia. *Schizophrenia Bulletin*, 35(2), 383–402. doi:10.1093/schbul/sbn135.
- Ceskova, E. (2020). Pharmacological strategies for the management of comorbid depression and schizophrenia. *Electronic*, 1744–7666.
- Chen, C.-H., Ridler, K., Suckling, J., Williams, S., Fu, C. H. Y., Merlo-Pich, E., & Bullmore, E. T. (2007). Brain imaging correlates of depressive symptom severity and predictors of symptom improvement after antidepressant treatment. *Biological Psychiatry*, 62(5), 407–414. doi:10.1016/j.biopsych.2006.09.018.
- Conley, R. R., Ascher-Svanum, H., Zhu, B., Faries, D. E., & Kinon, B. J. (2007). The burden of depressive symptoms in the long-term treatment of patients with schizophrenia. *Schizophrenia Research*, 90(1-3), 186–197.
- Conley, R. R., & Mahmoud, R. (2001). A randomized double-blind study of risperidone and olanzapine in the treatment of schizophrenia or Schizoaffective disorder. *American Journal of Psychiatry*, 158(5), 765–774.
- Dai, J., Du, X., Yin, G., Zhang, Y., Xia, H., Li, X., Cassidy, R., et al. (2017). Prevalence, demographic and clinical features of comorbid depressive symptoms in drug naive patients with schizophrenia presenting with first episode psychosis. *Schizophrenia Research* S0920996417303699.
- Desikan, R. S., Ségonne, F., Fischl, B., Quinn, B. T., Dickerson, B. C., Blacker, D., et al. (2006). An automated labeling system for subdividing the human

- cerebral cortex on MRI scans into gyral based regions of interest. *Neuroimage*, 31(3), 968–980.
- Dhana, Wolf, Martin, Klasen, Patrick, Eisner, Florian, D., Zepf, & Mikhail (2018). Central serotonin modulates neural responses to virtual violent actions in emotion regulation networks. *Brain Structure & Function*, 224(9), 3409.
- Di Biase, M. A., Zhang, F., Lyall, A., Kubicki, M., Mandl, R. C. W., Sommer, I. E., & Pasternak, O. (2020). Neuroimaging auditory verbal hallucinations in schizophrenia patient and healthy populations [Article]. *Psychological Medicine*, 50(3), 403–412. doi:10.1017/S0033291719000205 Article Pii s0033291719000205.
- Duhamel, B., Ferre, J.-C., Jannin, P., Gauvrit, J.-Y., Verin, M., Millet, B., & Drapier, D. (2010). Chronic and treatment-resistant depression: A study using arterial spin labeling perfusion MRI at 3 Tesla. *Psychiatry Research-Neuroimaging*, 182(2), 111–116. doi:10.1016/j.psychres.2010.01.009.
- EM, N., Schnack, H. G., Koevoets, M., Cahn, W., Pol, H. E. H., & Kahn, R. S (2016). Trajectories of subcortical volume change in schizophrenia: A 5-year follow-up. *Schizophrenia Research*, 173(3), 140–145.
- Eggers, & Arnold, E (2013). A serotonin hypothesis of schizophrenia. *Medical Hypotheses*, 80(6), 791–794.
- Fischl, B., Salat, D. H., Busa, E., Albert, M., & Dale, A. M. (2002). Whole brain segmentation: automated labeling of neuroanatomical structures in the human brain. *Neuron*, 33(3), 341–355.
- Fornito, A., Yücel, M., Dean, B., Wood, S. J., & Pantelis, C. (2009). Anatomical abnormalities of the anterior cingulate cortex in schizophrenia: bridging the gap between neuroimaging and neuropathology. *Schizophr Bull*, 35(5), 973–993.
- Gener, T., Tauste Campo, A., Alemany-Gonzalez, M., Nebot, P., Delgado-Sallent, C., Chanovas, J., & Victoria Puig, M. (2019). Serotonin 5-HT1A, 5-HT2A and dopamine D2 receptors strongly influence prefronto-hippocampal neural networks in alert mice: Contribution to the actions of risperidone. *Neuropharmacology*, 158, 107743–107778.
- Ghosh, A., Kaur, S., Shah, R., Oomer, F., Avasthi, A., Ahuja, C. K., et al. (2022). Surface-based brain morphometry in schizophrenia vs. cannabis-induced psychosis: A controlled comparison [Article]. *Journal of Psychiatric Research*, 155, 286–294. doi:10.1016/j.jpsychires.2022.09.034.
- Godlewska, B. R., Browning, M., Norbury, R., Igoumenou, A., Cowen, P. J., & Harmer, C. J. (2018). Predicting treatment response in depression: the role of anterior cingulate cortex. *The International Journal of Neuropsychopharmacology*, 21(11), 988–996.
- Goto, M., Yoshimura, R., Kakiyama, S., Shinkai, K., Yamada, Y., Kaji, K., Ueda, N., & Nakamura, J. (2006). Risperidone in the treatment of psychotic depression. *Progress in Neuropsychopharmacology & Biological Psychiatry*, 23(6), 335–337.
- Hamilton, M. (1960). A Rating Scale for Depression. *Journal of Neurology, Neurosurgery & Psychiatry*, 23(1), 56–62.
- Han, K. M., & Ham, B. J. (2021). How inflammation affects the brain in depression: A Review of functional and structural MRI studies. *Journal of Clinical Neurology*, 17(4), 503–515. doi:10.3988/jcn.2021.17.4.503.
- Herniman, S. E., Phillips, L. J., Wood, S. J., Cotton, S. M., Liemburg, E. J., & Allott, K. A. (2021). Interrelationships between depressive symptoms and positive and negative symptoms of recent onset schizophrenia spectrum disorders: A network analytical approach. *Journal of Psychiatric Research*, 140(1), 373–380. doi:10.1016/j.jpsychires.2021.05.038.
- Hertel, P., Sc, B., Nomikos, Schilström, B., Sc, M, Arborelius, L., Ph., D., & Svensson, T. H. (1997). Risperidone dose-dependently increases extracellular concentrations of serotonin in the rat frontal cortex: Role of  $\alpha$ 2-adrenoceptor antagonism. 17(1), 44–55.
- Karlıdere, Uzun, & Balıkcı (2015). Depressive symptoms in first episode schizophrenia patients under treatment: One-year follow-up comparison of classical and atypical antipsychotics. *Anadolu Psikiyatri Dergisi*, 16(1), 7–13.
- Kasper, S., Montagnani, G., Trespi, G., & Fiorino, M. D. (2015). Treatment of depressive symptoms in patients with schizophrenia: a randomized, open-label, parallel-group, flexible-dose subgroup analysis of patients treated with extended-release quetiapine fumarate or risperidone. *International Clinical Psychopharmacology*, 30(1), 14–22.
- Kay, Fiszbein, & Opler (1987). The positive and negative syndrome scale (PANSS) for schizophrenia. *Schizophrenia bulletin*, 13(2).
- Kjelby, E., Jørgensen, H. A., Kroken, R. A., Løberg, E.-M., & Johnsen, E. (2011). Anti-depressive effectiveness of olanzapine, quetiapine, risperidone and ziprasidone: a pragmatic, randomized trial. *BMC Psychiatry*, 11(1), 145–155.
- Knowland, D., Lilascharoen, V., Pacia, C. P., Shin, S., Wang, E. H.-J., & Lim, B. K. (2017). Distinct ventral pallidal neural populations mediate separate symptoms of depression. *Cell*, 170(2), 284–297.
- Kohler, C., Swanson, C. L., Gur, R. C., Mozley, L. H., & Gur, R. E. (1998). Depression in schizophrenia: II. MRI and PET findings. *Biological Psychiatry*, 43(3), 173–180.
- Lang, D. J., Kopala, L. C., Vandorpe, R. A., Rui, Q., Smith, G. N., Goghari, V. M., & Honer, W. G. (2001). An MRI study of basal ganglia volumes in first-episode schizophrenia patients treated with risperidone. *American Journal of Psychiatry*, 158(4), 625–631.
- Li, W., Yang, Y., An, F. R., Zhang, L., & Xiang, Y. T. (2020). Prevalence of comorbid depression in schizophrenia: a meta-analysis of observational studies. *Journal of Affective Disorders*.
- Mann, S. L., Hazlett, E. A., Byne, W., Hof, P. R., Buchsbaum, M. S., Cohen, B. H., Goldstein, K. E., Haznedar, M. M., Mitsis, E. M., Siever, L. J., & Chu, K.-W. (2011). Anterior and posterior cingulate cortex volume in healthy adults: Effects of aging and gender differences [Article]. *Brain Research*, 1401, 18–29. doi:10.1016/j.brainres.2011.05.050.
- Martin-Reyes, M., Mendoza, R., Dominguez, M., Caballero, A., Marta Bravo, T., Diaz, T., Gerra, S., Ibanez, A., & Linares, A. R (2011). Depressive symptoms evaluated by the Calgary Depression Scale for Schizophrenia (CDSS): Genetic vulnerability and sex effects. *Psychiatry Research*, 189(1), 55–61. doi:10.1016/j.psychres.2010.11.026.
- Mayberg, H. S. (2003). Modulating dysfunctional limbic-cortical circuits in depression: towards development of brain-based algorithms for diagnosis and optimised treatment. *British Medical Bulletin*, 65(1), 193–207.
- McKenna, F. F., Miles, L., Babb, J. S., Goff, D. C., & Lazar, M. (2019). Diffusion kurtosis imaging of gray matter in schizophrenia. *Cortex*, 121, 201–224. doi:10.1016/j.cortex.2019.08.013.
- Morris, L. S., Costi, S., Tan, A., Stern, E. R., Charney, D. S., & Murrrough, J. W. (2020). Ketamine normalizes subgenual cingulate cortex hyper-activity in depression. *Neuropsychopharmacology*, 45(6), 975–981. doi:10.1038/s41386-019-0591-5.
- Nelson, B. D., Bjorkquist, O. A., Olsen, E. K., & Herbener, E. S. (2015). Schizophrenia symptom and functional correlates of anterior cingulate cortex activation to emotion stimuli: An fMRI investigation. *Psychiatry Research*, 234(3), 285–291.
- Okada, N, F, M., Yamashita, F, Koshiyama, D, Yamamori, H, Ohi, K, Yasuda, Y, Fujimoto, M., et al. (2016). Abnormal asymmetries in subcortical brain volume in schizophrenia. *Molecular Psychiatry*, 21(10), 1460–1466. doi:10.1038/mp.2015.209.
- Okada, N., Yahata, N., Koshiyama, D., Morita, K., Sawada, K., Kanata, S., et al. (2018). Abnormal asymmetries in subcortical brain volume in early adolescents with subclinical psychotic experiences. *Translational Psychiatry*, 8(1), 254.
- Oleg, B., Fabienne, H., André, S., Renata, S., J. H. D., Laura, E., Anita, R.-R., Paolo, F.-P., G. H. C., E. L. U., Christina, A., & Stefan, B (2019). Association of antidepressants with brain morphology in early stages of psychosis: an imaging genomics approach. *Scientific Reports*, 9(1), 1–11.
- Peuskens, J., Baelen, B. V., Smedt, C. D., & Lemmens, P. (2000). Effects of risperidone on affective symptoms in patients with schizophrenia. *International Clinical Psychopharmacology*, 15(6), 343–349.
- Piet, O., Robin, E., Dana, N., Liezl, K., & Bonga, C. (2006). The relationships between depression and remission in first-episode psychosis. *World Psychiatry : Official Journal of the World Psychiatric Association (WPA)*, 5(3), 172–176.
- Reuter, M., Schmansky, N. J., Rosas, H. D., & Fischl, B. (2012). Within-subject template estimation for unbiased longitudinal image analysis. *Neuroimage*, 61(4), 1402–1418.
- Roya, S., Susan, S., Reza, D., Shervin, A., & Akhoundpour, M. A. (2017). Efficacy of risperidone augmentation with ondansetron in the treatment of negative and depressive symptoms in schizophrenia: a randomized clinical trial. *Iranian Journal of Medical Sciences*, 42(1), 14–23.
- Schnack, H. G., van Haren, N. E. M., Nieuwenhuis, M., Pol, H. E. H., Cahn, W., & Kahn, R. S. (2016). Accelerated brain aging in schizophrenia: A longitudinal pattern recognition study [article]. *American Journal of Psychiatry*, 173(6), 607–616. doi:10.1176/appi.ajp.2015.15070922.
- Seon-Cheol, P., Jae-Min, K., Tae-Young, J., Min-Soo, L., Jung-Bum, K., Hyeon-Woo, Y., & Chon, P. Y. (2017). How many different symptom combinations fulfil the diagnostic criteria for major depressive disorder? Results from the CRESCEND study. *Nordic Journal of Psychiatry*, 71(3), 217–222.
- Simmons, A. N., Estibaliz, A., Lovero, K. L., Stein, M. B., & Paulus, M. P. (2009). Sub-chronic SSRI administration reduces insula response during affective anticipation in healthy volunteers. *International Journal of Neuropsychopharmacology*, (8), 1009.
- Smith, S. M., & Nichols, T. E. (2009). Threshold-free cluster enhancement: addressing problems of smoothing, threshold dependence and localisation in cluster inference. *Neuroimage*, 44(1), 83–98. doi:10.1016/j.neuroimage.2008.03.061.
- Stevens, F. L., Hurlley, R. A., & Taber, K. H. (2011). Anterior cingulate cortex: Unique role in cognition and emotion. *The Journal of Neuropsychiatry and Clinical Neurosciences*, 23(2), 121–125.
- Touroutoglou, A., & Dickerson, B. C. (2019). Cingulate-centered large-scale networks: Normal functions, aging, and neurodegenerative disease [Review]. *Handbook of Clinical Neurology*, 166, 113–127. doi:10.1016/b978-0-444-64196-0.00008-x.
- Upthegrove, R., Marwaha, S., & Birchwood, M. (2017). Depression and schizophrenia: Cause, consequence, or trans-diagnostic issue? *Schizophrenia Bulletin*, 43(2), 240–244. doi:10.1093/schbul/sbw097.
- Wei, G., Ge, L., Chen, L., Cao, B., & Zhang, X. (2020). Structural abnormalities of cingulate cortex in patients with first-episode drug-naïve schizophrenia comorbid with depressive symptoms. *Human Brain Mapping*, 42(6), 1617–1625.
- Yang, W., Zhang, G., Jia, Q., Qian, Z. K., & Zhang, X. (2019). Prevalence and clinical profiles of comorbid anxiety in first episode and drug naïve patients with major depressive disorder. *Journal of Affective Disorders*, 257(1), 200–206.
- Zhang, Y. J., Shao, J. N., Wang, X. Y., Chen, Z. L., Liu, H. Y., Pei, C., Zhang, S. Q., Yao, Z. J., & Lu, Q. (2021). Functional impairment-based segmentation of anterior cingulate cortex in depression and its relationship with treatment effects. *Human Brain Mapping*, 42(12), 4035–4047. doi:10.1002/hbm.25537.