

The renoprotective effects of Heme Oxygenase-1 during contrast-induced acute kidney injury in pre-clinical diabetic models

Cassiane Dezoti da Fonseca^{1,III,*} Mirian Watanabe^{1,II} Sheila Marques Fernandes Couto^{1,III} Alef Aragão Carneiro dos Santos^{1,IV} Fernanda Teixeira Borges^{1,IV,V} Maria de Fatima Fernandes Vattimo^{1,III}

¹Escola Paulista de Enfermagem, Universidade Federal de Sao Paulo, Sao Paulo, SP, BR. ^{II}Centro Universitario das Faculdades Metropolitanas Unidas (FMU), Sao Paulo, SP, BR. ^{III}Laboratorio Experimental de Modelos Animais (LEMA), Escola de Enfermagem, Universidade de Sao Paulo, Sao Paulo, SP, BR. ^{IV}Programa de Pos-graduacao Interdisciplinar em Ciencias da Saude, Universidade Cruzeiro do Sul, Sao Paulo SP, BR. ^VDivisao de Nefrologia, Universidade Federal de Sao Paulo, Sao Paulo, SP, BR.

Fonseca CD, Watanabe M, Couto SMF, Santos AAC, Borges FT, Vattimo MFF. The renoprotective effects of Heme Oxygenase-1 during contrast-induced acute kidney injury in preclinical diabetic models. *Clinics* (Sao Paulo). 2021;76:e3002

*Corresponding author. E-mail: cassiane.dezoti@unifesp.br

OBJECTIVES: Contrast-induced acute kidney injury (CI-AKI) is an important clinical problem that can be aggravated by diabetes mellitus, a major risk factor. However, heme oxygenase-1 (HO-1), a promising therapeutic target, can exert antioxidant effects against CI-AKI. Thus, we investigated the role of HO-1 in CI-AKI in the presence of diabetes mellitus.

METHODS: Twenty-eight male Wistar rats weighing 250–300g were subjected to left uninephrectomy, and concomitantly, diabetes induced by streptozotocin (65 mg/kg). After 12 weeks, iodinated contrast (meglumine ioxithalamate, 6 mL/kg) and hemin (HO-1 inducer-10 mg/kg) were administered 60 min before iodinated contrast treatment. The rats were randomly divided into four groups: control, diabetes mellitus (DM), DM iodinated contrast (DMIC), and DMIC hemin (DMICH). Kidney function, albuminuria, oxidative profile, and histology were assessed. All experimental data were subjected to statistical analyses.

RESULTS: CI-AKI in preclinical diabetic models decreased creatinine clearance and increased urinary neutrophil gelatinase-associated lipocalin (NGAL) levels and the degree of albuminuria. Additionally, the levels of oxidative and nitrosative stress metabolites (urinary peroxides, thiobarbituric acid-reactive substances, and NO) were elevated, while thiol levels in kidney tissue were reduced. Kidney histology showed tubular cell vacuolization and edema. HO-1 inducer treatment improved kidney function and reduced urinary the NGAL levels. The oxidative profile showed an increase in the endogenous thiol-based antioxidant levels. Additionally, the tubular injury score was reduced following HO-1 treatment.

CONCLUSIONS: Our findings highlight the renoprotective effects of HO-1 in CI-AKI and preclinical diabetic models. Therefore, HO-1 ameliorates kidney dysfunction, reduces oxidative stress, and prevents cell necrosis.

KEYWORDS: Heme Oxygenase-1; Nephrotoxicity; Oxidative Stress; Diabetes Mellitus; Iodinated Contrast.

INTRODUCTION

Contrast-induced acute kidney injury (CI-AKI) is an iatrogenic syndrome that arises after iodinated contrast (IC) administration, which is used to perform diagnostic imaging tests such as cardiac catheterization (1,2). Its incidence varies from 3% to 19%, but risk factors such as chronic kidney disease, advanced age, and diabetes mellitus (DM) can increase it to 26% (3-5). In this context, DM is associated with

microvascular comorbidities such as nephropathy, a chronic condition that exacerbates kidney vulnerability to toxic agents such as IC (6-8).

CI-AKI is clinically characterized as kidney dysfunction, with elevated serum creatinine greater than or equal to 0.5 mg/dL or less than 25% of baseline between 48 and 72 hours after IC injection, associated with anuria, or oliguria and electrolyte imbalance (5,9). Chronic hyperglycemia can intensify hypoxic, nitrosative, and oxidative stress following IC administration (4,8,10).

The pathophysiology of CI-AKI is poorly understood. Hypoxia is the main mechanism underlying CI-AKI and is caused by prolonged vasoconstriction that induces adhesion molecule expression, leukocyte-endothelium interaction, and activation of inflammatory mediators such as cytokines and eicosanoids (2,8-10). Nevertheless, high osmolality and viscosity of IC may enhance its toxic effect in the kidney tubules by increasing intratubular pressure and reducing kidney blood flow (KBF) and glomerular filtration rate

Copyright © 2021 CLINICS – This is an Open Access article distributed under the terms of the Creative Commons License (<http://creativecommons.org/licenses/by/4.0/>) which permits unrestricted use, distribution, and reproduction in any medium or format, provided the original work is properly cited.

No potential conflict of interest was reported.

Received for publication on March 30, 2021. **Accepted for publication on** September 14, 2021

DOI: 10.6061/clinics/2021/e3002



(GFR). *In vivo* and *in vitro* studies corroborate this hypothesis (5,9,11). Additionally, direct tubular toxicity caused by IC can stimulate the production of reactive oxygen species (ROS), which affect mitochondrial and nuclear DNA, lipid membranes, and cellular proteins, leading to cell apoptosis and necrosis (12-16).

Heme oxygenase 1 (HO-1) is an inducible enzyme with potent antioxidant, anti-inflammatory, and anti-apoptotic properties. HO-1 activity occurs via heme breakdown and generation of protective products such as carbon monoxide (CO) and biliverdin, with the subsequent formation of bilirubin and ferritin via iron release from the heme moiety (17). Numerous studies conducted with animals have highlighted the promising effects of HO-1 induction, showing its antioxidant and anti-inflammatory properties in kidney diseases (18-20).

The explosion of therapeutic and diagnostic interventions, especially cardiac procedures that require IC, can contribute to the unfavorable epidemiology of CI-AKI, as well as complications in diabetic patients. We hypothesized that chronic hyperglycemia, which confers a predisposition to the occurrence of CI-AKI and HO-1 induction via hemin, could protect the kidney due to vasodilation, anti-inflammatory, antioxidant, and antiapoptotic effects. In this study, we aimed to investigate the protective effects of HO-1 on CI-AKI in diabetic rats by analyzing metabolic functions, oxidative profile, and histopathological staining.

■ MATERIALS AND METHODS

Ethics: All procedures in this study were approved by the Committee on Animal Research and Ethics of the University of São Paulo (Protocol 060/128/022012) and were conducted in accordance with international standards for the care and use of laboratory animals.

Animals: Twenty-eight adult male Wistar rats weighing 280–390 g were used in this study. They were housed in a temperature-controlled room (25°C/77°F), with 12-hour light-dark cycles and had free access to water and rat chow (Nuvilab CR-1, Nuvital, Brazil).

Procedures and timing

The animals were randomly divided into four groups: (1) citrate-control group (C): left unilateral nephrectomy was performed on day 1, and on day 20, citrate buffer was administered (0.01 M (pH 4.2); in the caudal vein, intravenous - i.v.), being housed under controlled conditions during 12 weeks; (2) DM: DM was induced by streptozotocin (STZ) administration (65 mg/kg, diluted in 0.01 M citrate buffer (pH 4.2), i.v.) on day 20, and the animals stayed under controlled conditions during 12 weeks (21); (3) DM + IC (DMIC): DM animals received 6 mL/kg meglumine ioxithalamate, i.p. on day 85 (10); (4) DM + IC + H (DMICH): DM animals received IC and hemin (HO-1 inducer, 10 mg/kg i.p. 60 minutes before IC) on day 85 (22).

The blood glucose levels of the animals used to establish the diabetic model were assessed 48h after the induction of diabetes, using Advantage urine reagent strips (Advantage, Roche[®], Brazil). The animals with blood glucose levels above 250 mg/dL were considered diabetic. All diabetic animals had their body weight assessed, and their blood glucose was monitored once a week for 12 weeks (85 days). Metabolic cages were used for the urine sample collection. On day 85, immediately after the last injection, the rats were

placed in metabolic cages for a 24-hour urinary volume measurement and urine sample collection.

Blood sample collection

The animals were anesthetized with a ketamine/xylazine mixture (75 mg/kg/10 mg/kg; Anasedan[®], Vetbrands) via intraperitoneal injection to collect blood samples through abdominal aorta puncture. During the procedure, they were kept on a surface heated to 38°C to avoid hypothermia. Euthanasia was performed by exsanguination, a physical method, according to the ethical standards for animal use in research laboratories (23).

Tissue sample collection/preparation

The left and right kidneys were prepared for the measurement of the levels of antioxidant enzymes and histological analysis.

Kidney function

According to well-established methods (24), serum and creatinine concentrations in the urine were measured using the Jaffe method, and creatinine clearance was calculated based on the following formula: creatinine clearance=[urine creatinine concentration (mg/dL) × 24-hour urinary volume (mL/min)]/serum creatinine concentration (mg/dL). The calculated creatinine clearance rate (mL/min) was normalized to the weight of the rats (25).

Urinary neutrophil gelatinase-associated lipocalin (NGAL)

Urine NGAL levels were analyzed using the Rat-NGAL ELISA kit, BioVendor, research, and diagnostic products (11).

Urinary albumin

Albumin concentrations in 24-hour urine samples were assessed using commercially available enzyme-linked immunosorbent assays (ELISA) (Bethyl Laboratories, USA). The optical density of each sample was determined using an Ultra Microplate Reader (EL808; Bio-Tek Instruments, Winooski, VT, USA) and expressed as ng/24 h for urine concentrations (26).

Oxidative profile

As described previously (24), (i) urinary peroxides were determined based on version 2 of the ferrous oxidation-xylenol orange (FOX-2) method. Xylenol orange shows a high selectivity for Fe³⁺, producing a blue/purple complex ($A=4.3 \times 10^4 \text{ M}^{-1} \text{ cm}^{-1}$). Values were corrected for urine creatinine content (in grams) and were expressed as nmol/g creatinine (27). (ii) Non-protein soluble thiols in the kidney were assessed by tissue homogenization in 1 mL of a solution containing 10 mM sodium acetate, 0.5% Tween 20, and 100 μM DTPA (pH 6.5). The first aliquot was reserved for the immediate measurement of total protein content. The second aliquot was precipitated with 20% trichloroacetic acid (1:1) to measure the total thiol content. Deproteinized samples were homogenized in 100 μL of a solution containing 100 mM Tris buffer (pH 8.0). After 10 min at room temperature, the quantity of thiols was determined based on the mean absorbance at 412 nm ($A=13.6 \times 10^3 \text{ M}^{-1} \text{ cm}^{-1}$). The concentration of soluble thiols was corrected for the total protein content and expressed as nmol/mg total protein (28). (iii) Lipid peroxidation levels of malondialdehyde (MDA)



were determined by measuring the levels of thiobarbituric acid-reactive substances (TBARS). For peroxidation quantification, 0.4 mL of a urine sample mixed with 0.6 mL water was added to a reaction mixture consisting of 1.0 mL 17.5% trichloroacetic acid (TCA) and 1.0 mL 0.6% thiobarbituric acid. This mixture was heated in a water bath at 95°C for 20 min, removed, cooled on ice, and subsequently mixed with 1.0 mL 70% TCA. The solution was homogenized and incubated for 20 min. Finally, the solution was read in a spectrophotometer at 535 nm ($A=1.56 \times 10^5 \text{ M}^{-1} \text{ cm}^{-1}$). Values are expressed as nmol/g creatinine (29). (iv). Nitric oxide (NO) was determined in urine samples using the Griess method. Briefly, a mixture of 1% sulfanilamide in 5% H_3PO_4 and 0.1% naphthylethylenediamine solution (Sigma-Aldrich, Saint Louis, USA) was added to the samples, which were read in a spectrophotometer at 546 nm. The levels of nitrite, a stable NO metabolite, was estimated from a standard curve constructed using NaNO_2 . Creatinine level assessment in the urine was performed as previously described and was used to normalize the results (30,31).

Histological analysis

According to well-established methods (24), slices of the left kidney were immersed in Bouin's solution for 4 h. Subsequently, kidney tissues were placed in a series of baths of 70% alcohol for picric acid elimination, dehydrated, and embedded in paraffin. Paraffin sections of perfused/fixed kidneys were stained with hematoxylin and eosin for histological analysis via light microscopy. Tubulointerstitial changes were defined as the presence of epithelial cell edema, vacuolar degeneration, necrosis, and desquamation of tubular cells. Tubular injury quantification was scored as follows: 0=less than 5% of the focal areas; 1=involvement of less than 5–25% of the kidney cortex; 2=involvement of less than 25–50% of the kidney cortex; 3=involvement of 50–75% of the kidney cortex; and 4=involvement of more than 75% of the kidney cortex. The slides were read using an optical microscope Axioskop 40 (Carl Zeiss, Jena, Germany) (32,33).

Statistical analysis

All quantitative data are expressed as the mean \pm SEM. Analysis of variance (ANOVA) was performed along with confidence intervals around the means and pairwise comparisons using the Newman-Keuls post hoc test. Non-continuous variables were available in non-parametric Kruskal-Wallis, following the Dunn test. All statistical

analyses were performed using the Graph-Pad Prism version-7 for Windows[®]. Statistical significance was defined as $p < 0.05$.

RESULTS

The effects of HO-1 on physiological parameters and kidney function

As shown in Table 1, physiological parameters confirm the establishment of the diabetic model, which presents hyperglycemia, polydipsia, polyphagia, and polyuria, indicated by increased food intake, water intake, blood glucose, and urine output elevation, respectively. The animals in the DM group presented with kidney hypertrophy and increased urinary albumin ($p < 0.001$), as demonstrated by the elevation of kidney/animal weight ratio and urinary volume. Interestingly, the highest ratio was observed in the animals that received IC. Furthermore, urinary albumin levels increased in the animals from the DM group. Treatment with hemin prevented the decrease in GFR, demonstrating the renoprotective action of HO-1 in the DMICH group, compared to the case for the control DMIC group. Urinary NGAL levels were lower in the DMICH group than in the DMIC group.

The effects of HO-1 on oxidative stress

The levels of urinary peroxides (UP, Figure 1A) and urinary TBARS (Figure 1B) in the DM and DMIC groups showed a significant increase (UP: DM: $46.2 \pm 21.8 \text{ nmol/g cr}$; DMIC: $45.4 \pm 10.2 \text{ nmol/g cr}$ versus C: $9.2 \pm 2.7 \text{ nmol/g cr}$; TBARS: DM: $2.22 \pm 0.61 \text{ nmol/g cr}$; DMIC: $4.20 \pm 1.04 \text{ nmol/g cr}$ versus C: $0.26 \pm 0.07 \text{ nmol/g cr}$, $p < 0.05$). Treatment with hemin reduced the production of oxidative metabolites (UP: DMICH: $26.1 \pm 13.1 \text{ nmol/g cr}$ versus DM: $46.2 \pm 21.8 \text{ nmol/g cr}$ and DMIC: $45.4 \pm 10.2 \text{ nmol/g cr}$; TBARS: DMICH: $1.61 \pm 0.26 \text{ nmol/g cr}$ versus DM: $2.22 \pm 0.61 \text{ nmol/g cr}$ and DMIC: $4.20 \pm 1.04 \text{ nmol/g cr}$, $p < 0.05$).

On the other hand, the thiol levels (Figure 1C) showed a reduction in the DM and DMIC groups (DM: $7.4 \pm 2.9 \text{ nmol/mg pr}$, DMIC: $5.5 \pm 1.9 \text{ nmol/mg pr}$ versus C: 12.4 ± 4.6 , $p < 0.05$). Nevertheless, when the HO-1 inducer was administered, the thiol levels were restored (DMICH: $14.9 \pm 3.7 \text{ nmol/mg pr}$ versus DM: $7.4 \pm 2.9 \text{ nmol/mg pr}$, DMIC: $5.5 \pm 1.9 \text{ nmol/mg pr}$, $p < 0.05$).

Urinary NO (Figure 1D) is associated with nitrosative stress in the urinary system, mainly in the kidneys. The elevation of this parameter was observed in the DM and

Table 1 - Physiological parameters and kidney function.

Variable	C	DM	DMIC	DMICH
Water intake (mL/24 h)	24 \pm 6	113 \pm 35*	198 \pm 39*†	169 \pm 21*†
Food intake (g/24 h)	13 \pm 5	25 \pm 8*	36 \pm 8*†	31 \pm 3*
Body glucose (mg/dL)	110 \pm 12	549 \pm 32*	567 \pm 48*	588 \pm 43*
KW/BW ($\times 10^{-3}$)	0.52 \pm 0.13	0.78 \pm 0.07*	0.91 \pm 0.08*†	1.12 \pm 0.26*†
Urinary output (mL/min)	0.01 \pm 0.02	0.06 \pm 0.01*	0.09 \pm 0.01*†	0.10 \pm 0.01*†
Urinary creatinine (mg/dL)	69.2 \pm 7.6	12.2 \pm 2.7*	6.8 \pm 2.0*†	5.8 \pm 1.0*†
Serum creatinine (mg/dL)	0.29 \pm 0.04	0.64 \pm 0.05*	0.87 \pm 0.16*†	0.63 \pm 0.16*‡
Creatinine clearance (mL/min/100 g)	0.51 \pm 0.08	0.32 \pm 0.05*	0.19 \pm 0.03*†	0.40 \pm 0.07*‡
Urinary NGAL (pg/mL)	130.9 \pm 50.3	141.8 \pm 42.7	327.2 \pm 61.1*†	152.4 \pm 57.8 ‡
Urinary albumin (ng/24 h)	0.54 \pm 0.30	3.02 \pm 0.95*	4.03 \pm 0.87*	3.29 \pm 0.40*

KW, kidney weight; BW, body weight $n=7$ /group. Data are shown as the mean \pm SEM for each group. Statistical significance was set at $p < 0.05$. * $p < 0.05$ versus C, † $p < 0.05$ versus DM, ‡ $p < 0.05$ versus DMIC.



DMIC groups (DM: 133.5 ± 23.7 nM/mg cr U, DMIC: 222.2 ± 33.8 nM/mg cr U versus C: 26.5 ± 10.9 nM/mg cr U, $p < 0.05$). Treatment with hemin significantly reversed the increase in nitrate excretion, resulting in the stabilization of NO metabolism (DMICH: 86.5 ± 17.4 nM/mg cr U versus DM: 133.5 ± 23.7 nM/mg cr U; DMIC: 222.2 ± 33.8 nM/mg cr U, $p < 0.05$).

The effects of HO-1 treatment on kidney tissues

Figure 2 shows the histological parameters of the kidneys. Tubulointerstitial lesions accounted for less than 5% of the focal areas. Tubular vacuolar degeneration, edema, cell casts, and hyaline casts were observed. There was an increased infiltration of polymorphonuclear cells (Figure 2C), and the tubular injury score (0–4) was DMIC: 0.50 ± 0.03 versus C:

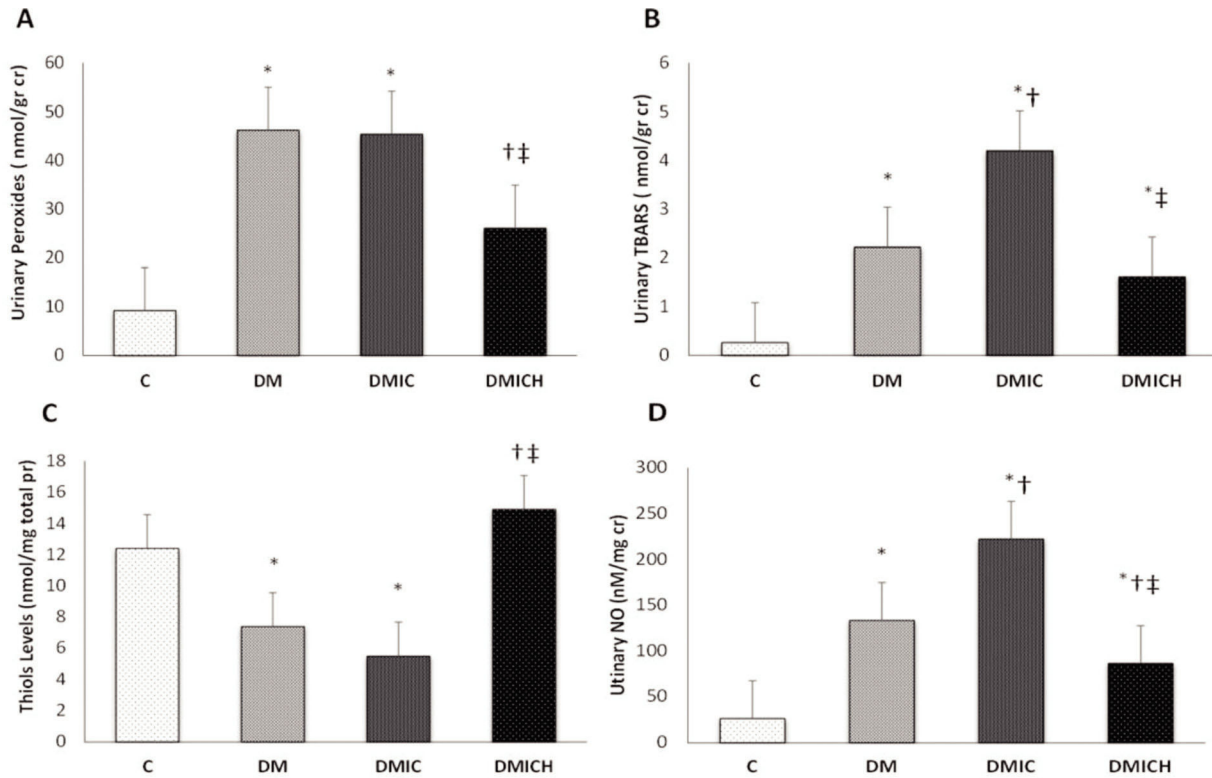


Figure 1 - Oxidative and nitrosative profiles of the rats from the control and diabetic groups. (A) Urinary peroxide levels (nmol/g cr), (B) urinary TBARS levels (nmol/g cr), (C) thiol levels (nmol/mg total pr), and (D) urinary NO levels (nM/mg cr). Cr: creatinine. Pr: protein. NO: nitric oxide. Data are shown as the mean \pm SEM for each group (n=7). Statistical significance was set at $p < 0.05$. * $p < 0.05$ versus C, † $p < 0.05$ versus DM, ‡ $p < 0.05$ versus DMIC.

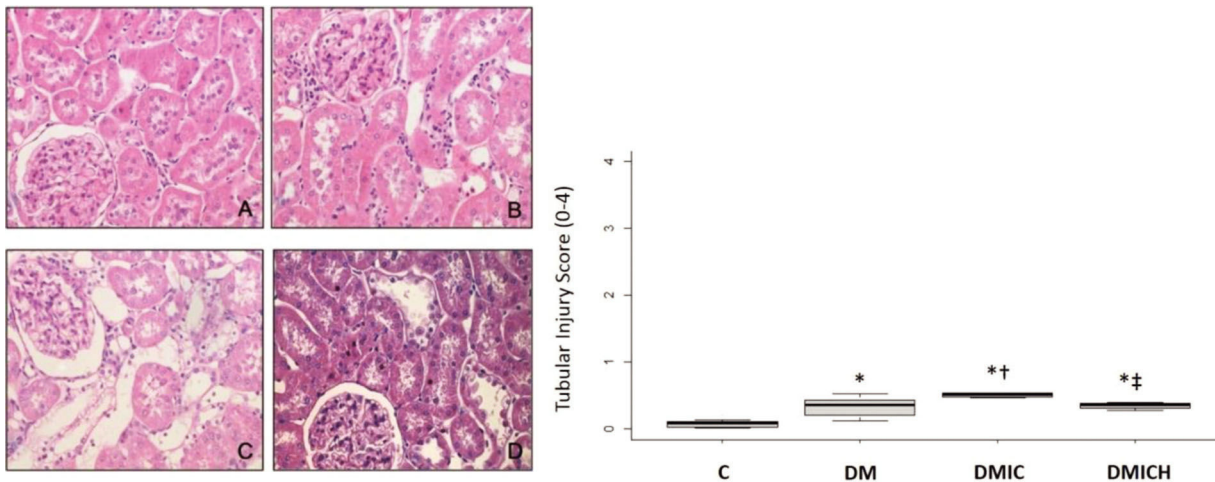


Figure 2 - Mean (\pm SEM) of histological images and tubular injury score from the control and diabetic groups. Representative images of hematoxylin and eosin staining at $400\times$ magnification. n=5–6 per each group. C (A), DM (B), DMIC (C), and DMICH (D). * $p < 0.05$ versus C, † $p < 0.05$ versus DM, ‡ $p < 0.05$ versus DMIC.



0.08 ± 0.10 , DM: 0.33 ± 0.15 , $p < 0.05$. Treatment with HO-1 restored the kidney histologic alterations and reduced the tubular injury score (DMICH: 0.34 ± 0.05 versus DMIC: 0.50 ± 0.03 , $p < 0.05$).

■ DISCUSSION

CI-AKI is a serious iatrogenic complication in clinical practice. Cardiac hemodynamic procedures are responsible for a large proportion of these adverse events. DM is considered a major risk factor for CI-AKI. Hyperglycemia has been linked to high CI-AKI prevalence, demonstrating increased short- and long-term mortality. In this context, several agents are being investigated because of their possible renoprotective action against DM-associated CI-AKI, especially in preclinical and clinical models (5,10,34-38).

This study demonstrates, for the first time, that HO-1 can be an innovative strategy to prevent and treat CI-AKI by mitigating the increase in the levels of kidney injury biomarkers and improving kidney function, ameliorating oxidative stress, and normalizing the histological parameters in a preclinical diabetic risk factor model.

The exact pathogenesis of CI-AKI is not completely understood. Kidney vasoconstriction and direct nephrotoxicity are associated with kidney parenchymal hypoxia, generation of reactive oxygen species, and inflammatory processes, all of which play pivotal roles in kidney damage. In addition, the predisposition of diabetic kidneys to CI-AKI may be related to chronic hyperglycemia due to increased levels of NADPH oxidase and mitochondrial protein glycation in favor of oxidative stress, resulting in a state of glucose toxicity (2,6,8,10).

In the current study, we observed a significant increase in the levels of kidney injury biomarkers, creatinine clearance, urinary NGAL, and urinary albumin in diabetic rats that received contrast media. A previous study demonstrated that contrast media reduced serum creatinine and BUN levels in diabetic rats (39). Han et al. showed an increase of at least 25% in serum creatinine levels in diabetic patients after IC exposure (40). Fernandes et al. demonstrated a significant decrease in GFR (assessed by a gold standard method, inulin clearance) and increased levels of urinary NGAL in preclinical CI-AKI models in association with diabetic and chronic kidney disease (11). Albuminuria is closely related to glomerular changes in DM, such as basal glomerular thickening. Ptilovanciv et al. demonstrated the elevation of urinary albumin levels in diabetic rats (26), corroborating our data. HO-1 induction in this study prevented a decrease in GFR and restored the levels of kidney biomarkers. NGAL is a stress protein that is upregulated in residual viable kidney cells and is highly sensitive for the early detection of AKI (41,42). In kidney injuries, overexpression of NGAL could be related to an intensive oxidative stress mechanism. Some studies have demonstrated that HO-1 activity decreases NGAL levels (43,44).

Additionally, this study demonstrated an important increase in the levels of urinary peroxides, TBARS, and NO and a decrease in thiol levels by glutathione peroxidase consumption, resulting in oxidative stress in diabetic rats with CI-AKI. There is a synergic adverse event associated with IC administration and diabetes in the kidney in favor of oxidative stress. The mechanism underlying ROS formation can be related to deregulated kidney hemodynamics and endothelial dysfunction. Oxygen consumption affects

mitochondrial and nuclear DNA, lipid membranes, and cellular proteins with accumulation of hypoxia-inducible factors (HIFs). Renal medullary hypoxic injury is characterized by apoptosis and necrosis. Moreover, metal cations (such as Fe^{+2} and Cu^{+1}) in various redox-sensitive compounds, disconnected from their protein envelopes, may trigger the generation of ROS and catalyze the formation of highly toxic hydroxyl radicals from hydrogen peroxide and superoxide (9,12).

Endothelial nitric oxide synthase (eNOS) overproduction can combine to form peroxynitrite in association with superoxide by uncoupling tetrahydrobiopterin or arginine, which perpetuates oxidative stress (45). Pereira et al. demonstrated an important increase in TBARS levels in rats subjected to contrast agent administration (46). Hou et al. also showed a significant increase in the levels of oxidative stress markers, such as superoxide dismutase (SOD), MDA, and glutathione peroxidase (GSHPX) (39). In agreement with previous studies, it has been demonstrated that HO-1 induction has an antioxidant effect. Thus, this work is the first to demonstrate the effects of HO-1 in CI-AKI in a DM experimental model. HO-1 activity contributes to the scavenging of free radicals, such as peroxynitrite, by the overexpression of bile pigments, ultimately inhibiting lipid peroxidation. Additionally, the cyclic interconversion of biliverdin to bilirubin mitigates oxidative stress through the sequestration of hydrogen peroxide during the reaction (17,46). Fonseca et al. demonstrated that HO-1 induction increased the catalase and thiol levels and reduced the levels of oxidative metabolites in rats subjected to polymyxin B-induced nephrotoxicity (47). Studies with CI-AKI models suggest that several agents with antioxidant properties grant protection against oxidative stress through the modulation of HO-1 expression and activity (48,49).

From a histological perspective, the samples showed tubular epithelial vacuolization, luminal congestion, edema, and epithelial cell flattening, with the formation of intratubular casts and the presence of interstitial infiltrate in kidney cell structure in approximately 5% of kidney tubular cells. A recent clinical study demonstrated an increase in the serum creatine and cystatin C levels in diabetic patients exposed to contrast media (37). Similar to HO-1, an insulin-sensitizing hormone, AdipoRon, restored the kidney morphological parameters in a preclinical model of nephropathy established by the administration of the contrast agent iopromide (50).

From a translational perspective, DM could be a predictor of CI-AKI due to the strong association between contrast media imaging techniques and the presence of vascular disease, such as that observed in nephropathy. It should be noted that the incidence of CI-AKI is greater (almost 50%) in diabetic patients than in normoglycemic patients. Therefore, treatment with antioxidant substances and application of a risk prediction score need to be considered in all diabetic patients exposed to contrast media (1-3,5).

■ CONCLUSION

In conclusion, this study showed that HO-1 inducer administration can reverse the decrease in GFR and prevent oxidative stress in diabetic rats after IC exposure. Thus, owing to its antioxidant effects, HO-1 represents a therapeutic alternative for treating patients at a risk of CI-AKI.



Further experiments and randomized clinical trials are required to determine its protective role.

ACKNOWLEDGMENTS

The authors are grateful to the São Paulo Research Foundation (FAPESP) (grant numbers 2013/26560-2 and 2011/24028-6) and was financed in part by the Coordenação de Aperfeiçoamento de Pessoal de Nível Superior-Brasil (CAPES) – Finance Code 001.

AUTHOR CONTRIBUTIONS

Fonseca CD, Watanabe M, Couto SMF and Vattimo MFF conceived and designed the experiments. Fonseca CD, Watanabe M, Couto SMF and Santos AAC performed the experiments. Fonseca CD and Couto SMF analyzed the data. Fonseca CD, Borges FT, Couto SMF and Santos AAC contributed reagents/materials/analysis tools. Fonseca CD, Borges FT and Vattimo MFF wrote the manuscript.

REFERENCES

1. Mehran R, Dangas GD, Weisbord SD. Contrast-Associated Acute Kidney Injury. *N Engl J Med.* 2019;380(22):2146-55. <https://doi.org/10.1056/NEJMr1805256>
2. Ronco F, Tarantini G, McCullough PA. Contrast induced acute kidney injury in interventional cardiology: an update and key guidance for clinicians. *Rev Cardiovasc Med.* 2020;21(1):9-23. <https://doi.org/10.31083/j.rcm.2020.01.44>
3. Tsai TT, Patel UD, Chang TI, Kennedy KF, Masoudi FA, Matheny ME, et al. Contemporary incidence, predictors, and outcomes of acute kidney injury in patients undergoing percutaneous coronary interventions: insights from the NCDR Cath-PCI registry. *JACC Cardiovasc Interv.* 2014;7(1):1-9. <https://doi.org/10.1016/j.jcin.2013.06.016>
4. Rudnick MR, Leonberg-Yoo AK, Litt HI, Cohen RM, Hilton S, Reese PP. The Controversy of Contrast-Induced Nephropathy With Intravenous Contrast: What Is the Risk? *Am J Kidney Dis.* 2020;75(1):105-13. <https://doi.org/10.1053/j.ajkd.2019.05.022>
5. Azzalini L, Candilio L, McCullough PA, Colombo A. Current Risk of Contrast-Induced Acute Kidney Injury After Coronary Angiography and Intervention: A Reappraisal of the Literature. *Can J Cardiol.* 2017;33(10):1225-8. <https://doi.org/10.1016/j.cjca.2017.07.482>
6. Teodoro JS, Nunes S, Rolo AP, Reis F, Palmeira CM. Therapeutic Options Targeting Oxidative Stress, Mitochondrial Dysfunction and Inflammation to Hinder the Progression of Vascular Complications of Diabetes. *Front Physiol.* 2019;9:1857. <https://doi.org/10.3389/fphys.2018.01857>
7. Lee PG, Halter JB. The Pathophysiology of Hyperglycemia in Older Adults: Clinical Considerations. *Diabetes Care.* 2017;40(4):444-52. <https://doi.org/10.2337/dc16-1732>
8. McCullough PA, Adam A, Becker CR, Davidson C, Lameire N, Stacul F, et al. Risk prediction of contrast-induced nephropathy. *Am J Cardiol.* 2006;98(6A):27K-36K. <https://doi.org/10.1016/j.amjcard.2006.01.022>
9. Zhang F, Lu Z, Wang F. Advances in the pathogenesis and prevention of contrast-induced nephropathy. *Life Sci.* 2020;259:118379. <https://doi.org/10.1016/j.lfs.2020.118379>
10. Heyman SN, Rosenberger C, Rosen S, Khamaisi M. Why is diabetes mellitus a risk factor for contrast-induced nephropathy? *Biomed Res Int.* 2013;2013:123589. <https://doi.org/10.1155/2013/123589>
11. Fernandes SM, Martins DM, da Fonseca CD, Watanabe M, Vattimo Mde F. Impact of Iodinated Contrast on Renal Function and Hemodynamics in Rats with Chronic Hyperglycemia and Chronic Kidney Disease. *Biomed Res Int.* 2016;2016:3019410. <https://doi.org/10.1155/2016/3019410>
12. Heyman SN, Rosen S, Rosenberger C. Renal parenchymal hypoxia, hypoxia adaptation, and the pathogenesis of radiocontrast nephropathy. *Clin J Am Soc Nephrol.* 2008;3(1):288-96. <https://doi.org/10.2215/CJN.02600607>
13. Heyman SN, Rosen S, Khamaisi M, Idée JM, Rosenberger C. Reactive oxygen species and the pathogenesis of radiocontrast-induced nephropathy. *Invest Radiol.* 2010;45(4):188-95. <https://doi.org/10.1097/RLL.0b013e3181d2eed8>
14. Onk D, Onk OA, Turkmen K, Erol HS, Ayazoglu TA, Keles ON, et al. Melatonin Attenuates Contrast-Induced Nephropathy in Diabetic Rats: The Role of Interleukin-33 and Oxidative Stress. *Mediators Inflamm.* 2016;2016:9050828. <https://doi.org/10.1155/2016/9050828>
15. Hussien NI, Sorour SM, El-Kerdasy HI, Abdelrahman BA. The glucagon-like peptide-1 receptor agonist Exendin-4, ameliorates contrast-induced nephropathy through suppression of oxidative stress, vascular dysfunction and apoptosis independent of glycaemia. *Clin Exp Pharmacol Physiol.* 2018;45(8):808-18. <https://doi.org/10.1111/1440-1681.12944>
16. Khaleel SA, Alzokaky AA, Raslan NA, Alwakeel AI, Abd El-Aziz HG, Abd-Allah AR. Lansoprazole halts contrast induced nephropathy through

- activation of Nrf2 pathway in rats. *Chem Biol Interact.* 2017;270:33-40. <https://doi.org/10.1016/j.cbi.2017.04.010>
17. Bolisetty S, Zarjou A, Agarwal A. Heme Oxygenase 1 as a Therapeutic Target in Acute Kidney Injury. *Am J Kidney Dis.* 2017;69(4):531-45. <https://doi.org/10.1053/j.ajkd.2016.10.037>
18. Goodman AI, Olszanecki R, Yang LM, Quan S, Li M, Omura S, et al. Heme oxygenase-1 protects against radiocontrast-induced acute kidney injury by regulating anti-apoptotic proteins. *Kidney Int.* 2007;72(8):945-53. <https://doi.org/10.1038/sj.ki.5002447>
19. Shi S, Lei S, Tang C, Wang K, Xia Z. Melatonin attenuates acute kidney ischemia/reperfusion injury in diabetic rats by activation of the SIRT1/Nrf2/HO-1 signaling pathway. *Biosci Rep.* 2019;39(1):BSR20181614. <https://doi.org/10.1042/BSR20181614>
20. Behiry S, Rabie A, Kora M, Ismail W, Sabry D, Zahran A. Effect of combination sildenafil and gemfibrozil on cisplatin-induced nephrotoxicity; role of heme oxygenase-1. *Ren Fail.* 2018;40(1):371-8. <https://doi.org/10.1080/0886022X.2018.1455596>
21. Fernandes SM, Cordeiro PM, Watanabe M, Fonseca CD, Vattimo MF. The role of oxidative stress in streptozotocin-induced diabetic nephropathy in rats. *Arch Endocrinol Metab.* 2016;60(5):443-9. <https://doi.org/10.1590/2359-3997000000188>
22. Watanabe M, de Moura Neiva LB, da Costa Santos CX, Martins Laurindo FR, de Fatima Fernandes Vattimo M. Isoflavone and the heme oxygenase system in ischemic acute kidney injury in rats. *Food Chem Toxicol.* 2007;45(12):2366-71. <https://doi.org/10.1016/j.fct.2007.06.013>
23. American Veterinary Medical Association. AVMA guidelines on euthanasia, 2013 update. Available from: http://www.avma.org/issues/animal_welfare/euthanasia.pdf [Accessed February 1st, 2019]
24. Vattimo Mde F, Watanabe M, da Fonseca CD, Neiva LB, Pessoa EA, Borges FT. Polymyxin B Nephrotoxicity: From Organ to Cell Damage. *PLoS One.* 2016;11(8):e0161057. <https://doi.org/10.1371/journal.pone.0161057>
25. Dórea EL, Yu L, De Castro I, Campos SB, Ori M, Vaccari EM, et al. Nephrotoxicity of amphotericin B is attenuated by solubilizing with lipid emulsion. *J Am Soc Nephrol.* 1997;8(9):1415-22. <https://doi.org/10.1681/ASN.V891415>
26. Ptilovanciv EO, Fernandes GS, Teixeira LC, Reis LA, Pessoa EA, Convento MB, et al. Heme oxygenase 1 improves glucose metabolism and kidney histological alterations in diabetic rats. *Diabetol Metab Syndr.* 2013;5(1):3. <https://doi.org/10.1186/1758-5996-5-3>
27. Halliwell B, Long LH, Yee TP, Lim S, Kelly R. Establishing biomarkers of oxidative stress: the measurement of hydrogen peroxide in human urine. *Curr Med Chem.* 2004;11(9):1085-92. <https://doi.org/10.2174/0929867043365404>
28. Akerboom TP, Sies H. Assay of glutathione, glutathione disulfide, and glutathione mixed disulfides in biological samples. *Methods Enzymol.* 1981;77:373-82. [https://doi.org/10.1016/S0076-6879\(81\)77050-2](https://doi.org/10.1016/S0076-6879(81)77050-2)
29. Beuge JA, Aust SD. The thiobarbituric acid assay. *Methods Enzymol.* 1978;52:306-7.
30. Green LC, Wagner DA, Glogowski J, Skipper PL, Wishnok JS, Tannenbaum SR. Analysis of nitrate, nitrite, and [15N]nitrate in biological fluids. *Anal Biochem.* 1982;126(1):131-8. [https://doi.org/10.1016/0003-2697\(82\)90118-X](https://doi.org/10.1016/0003-2697(82)90118-X)
31. Convento MB, Pessoa EA, Cruz E, da Glória MA, Schor N, Borges FT. Calcium oxalate crystals and oxalate induce an epithelial-to-mesenchymal transition in the proximal tubular epithelial cells: Contribution to oxalate kidney injury. *Sci Rep.* 2017;7:45740. <https://doi.org/10.1038/srep45740>
32. Miyaji T, Kato A, Yasuda H, Fujigaki Y, Hishida A. Role of increase in p21 in cisplatin-induced acute renal failure in rats. *J Am Soc Nephrol.* 2001;12(5):900-8. <https://doi.org/10.1681/ASN.V125900>
33. Luchi WM, Shimizu MH, Canale D, Gois PH, de Bragança AC, Volpini RA, et al. Vitamin D deficiency is a potential risk factor for contrast-induced nephropathy. *Am J Physiol Regul Integr Comp Physiol.* 2015;309(3):R215-22. <https://doi.org/10.1152/ajpregu.00526.2014>
34. Rundback JH, Nahl D, Yoo V. Contrast-induced nephropathy. *J Vasc Surg.* 2011;54(2):575-9. <https://doi.org/10.1016/j.jvs.2011.04.047>
35. Zhang W, Wu K, Lin H, Zhang J, Chen S. Effect of Trimetazidine on Preventing Contrast-Induced Acute Kidney Injury in Patients with Diabetes. *Am J Med Sci.* 2018;356(6):576-7. <https://doi.org/10.1016/j.amjms.2018.06.011>
36. Deng J, Wu G, Yang C, Li Y, Jing Q, Han Y. Rosuvastatin attenuates contrast-induced nephropathy through modulation of nitric oxide, inflammatory responses, oxidative stress and apoptosis in diabetic male rats. *J Transl Med.* 2015;13:53. <https://doi.org/10.1186/s12967-015-0416-1>
37. Aslanbadi N, Afsar Gharebagh R, Moharramzadeh S, Entezari-Maleki T. Pentoxifylline for the prevention of contrast-induced nephropathy in diabetic patients undergoing angioplasty: a randomized controlled trial. *Int Urol Nephrol.* 2019;51(4):699-705. <https://doi.org/10.1007/s11255-019-02104-6>
38. Kang X, Hu DY, Li CB, Ai ZS, Peng A. N-acetylcysteine for the prevention of contrast-induced nephropathy in patients with pre-existing renal insufficiency or diabetes: a systematic review and meta-analysis. *Ren Fail.* 2015;37(10):297-303. <https://doi.org/10.3109/0886022X.2015.1012985>



39. Hou J, Yan G, Liu B, Zhu B, Qiao Y, Wang D, et al. The Protective Effects of Enalapril Maleate and Folic Acid Tablets against Contrast-Induced Nephropathy in Diabetic Rats. *Biomed Res Int.* 2018;2018:4609750. <https://doi.org/10.1155/2018/4609750>
40. Han XF, Zhang XX, Liu KM, Tan H, Zhang Q. Contrast-induced nephropathy in patients with diabetes mellitus between iso- and low-osmolar contrast media: A meta-analysis of full-text prospective, randomized controlled trials. *PLoS One.* 2018;13(3):e0194330. <https://doi.org/10.1371/journal.pone.0194330>
41. Andress DL, Coll B, Pritchett Y, Brennan J, Molitch M, Kohan DE. Clinical efficacy of the selective endothelin A receptor antagonist, atrasentan, in patients with diabetes and chronic kidney disease (CKD). *Life Sci.* 2012;91(13-14):739-42. <https://doi.org/10.1016/j.lfs.2012.01.011>
42. Watanabe M, Silva GF, Fonseca CD, Vattimo Mde F. Urinary NGAL in patients with and without acute kidney injury in a cardiology intensive care unit. *Rev Bras Ter Intensiva.* 2014;26(4):347-54. <https://doi.org/10.5935/0103-507X.20140053>
43. Sharawy MH, Abdelrahman RS, El-Kashef DH. Agmatine attenuates rhabdomyolysis-induced acute kidney injury in rats in a dose dependent manner. *Life Sci.* 2018;208:79-86. <https://doi.org/10.1016/j.lfs.2018.07.019>
44. Ozturk S, Ustebay S, Eroglu HA, Gunay M, Adali Y, Donmez I, et al. An experimental study of ascorbic acid effects in acute renal failure under general anesthesia. *Acta Cir. Bras.* 2017;32(10):853-61. <https://doi.org/10.1590/s0102-86502017010000007>
45. Sharma K. Obesity and Diabetic Kidney Disease: Role of Oxidant Stress and Redox Balance. *Antioxid Redox Signal.* 2016;25(4):208-16. <https://doi.org/10.1089/ars.2016.6696>
46. Pereira LV, Shimizu MH, Rodrigues LP, Leite CC, Andrade L, Seguro AC. N-acetylcysteine protects rats with chronic renal failure from gadolinium-chelate nephrotoxicity. *PLoS One.* 2012;7(7):e39528. <https://doi.org/10.1371/journal.pone.0039528>
47. Dezoti Fonseca C, Watanabe M, Vattimo Mde F. Role of heme oxygenase-1 in polymyxin B-induced nephrotoxicity in rats. *Antimicrob Agents Chemother.* 2012;56(10):5082-7. <https://doi.org/10.1128/AAC.00925-12>
48. Zhao Z, Liao G, Zhou Q, Lv D, Holthfer H, Zou H. Sulforaphane Attenuates Contrast-Induced Nephropathy in Rats via Nrf2/HO-1 Pathway. *Oxid Med Cell Longev.* 2016;2016:9825623. <https://doi.org/10.1159/000489688>
49. Liang R, Zhao Q, Jian G, Cheng D, Wang N, Zhang G, et al. Tanshinone IIA Attenuates Contrast-Induced Nephropathy via Nrf2 Activation in Rats. *Cell Physiol Biochem.* 2018;46(6):2616-23. <https://doi.org/10.1159/000489688>
50. Gu D, Shi Y, Gong Z, Xia T, Ren H, He D, et al. AdipoRon, an adiponectin receptor agonist, protects contrast-induced nephropathy by suppressing oxidative stress and inflammation via activation of the AMPK pathway. *Clin Exp Nephrol.* 2020;24(11):989-98. <https://doi.org/10.1007/s10157-020-01944-2>