

## CASE REPORT

# Abdominal pain, arthritis, and nephrotic syndrome in a Syrian patient

Bruno Eduardo P. Balbo,<sup>1</sup> André Albuquerque Silva,<sup>1</sup> Andressa Godoy Amaral,<sup>1</sup> Denise M. A. C. Malheiros,<sup>1</sup> Luiz Fernando Onuchic,<sup>1</sup> Rui Toledo Barros<sup>1</sup>

<sup>1</sup>Faculdade de Medicina da Universidade de São Paulo, Department of Medicine, Division of Nephrology, São Paulo/SP, Brazil. <sup>11</sup>Faculdade de Medicina da Universidade de São Paulo, Department of Pathology, São Paulo/SP, Brazil.

Email: lonuchic@usp.br  
Tel.: 55 11 3061-8399

## INTRODUCTION

Familial Mediterranean fever (FMF) is an autosomal recessive disorder that is characterized by sporadic paroxysmal attacks of fever and serosal inflammation. Although it occurs primarily in ethnic groups originating in the Mediterranean region, FMF is not restricted to these groups and is still underdiagnosed in nephrology settings in non-Mediterranean countries (1).

The disease morbidity is largely associated with recurrent attacks of pain and fever, and mortality is mainly associated with amyloidosis and kidney disease (1). The discovery of colchicine in 1972 led to an effective treatment for FMF in the prevention of acute attacks and secondary amyloidosis, significantly increasing the importance of an accurate and early diagnosis (2). The clinical criteria proposed by Livneh et al. (3) in 1997 continue to be the gold standard for diagnosis. However, limitations arise in atypical cases and in patients of non-Mediterranean origin.

The gene mutated in FMF, *MEFV* (*Mediterranean fever*), was cloned in 1997, shedding light on the disease pathogenesis and improving the tools for diagnosis (4). In this scenario, genotype-phenotype correlation studies revealed specific alleles that were associated with amyloidosis and kidney disease, and mutation-based analysis, particularly directed toward hot spots, emerged as an essential approach for diagnosis in atypical cases (5).

## CASE DESCRIPTION

A 31-year-old female who emigrated from Syria to Brazil was admitted due to recurrent episodes of abdominal pain and fever during the prior four months. Initially ascribed to pyelonephritis, she received several cycles of antibiotics without a clinical response. One month prior to admission, she developed frothy urine and anasarca.

The patient reported a history of episodes of large-joint arthritis and fever beginning in childhood and acute abdominal pain that prompted a negative exploratory laparotomy at age 14. At 16 years old, she entered partial

remission, with mild and less frequent crises of myalgia and fever. Her family history included consanguinity at the parent and grandparent levels, episodes of abdominal pain, fever, and arthritis in two cousins and the paternal grandfather, and a maternal uncle with similar symptoms who was on dialysis.

She presented with pallor, anasarca, hypotension, and a painful abdomen, with palpable liver and spleen. Blood tests revealed hemoglobin levels of 9.2 g/dL, creatinine levels of 2.2 mg/dL, albumin levels of 1.6 g/dL and C-reactive protein levels of 68 mg/L. Antinuclear antibodies were negative. Complement, liver enzymes and liver function were normal. Urine and blood cultures and serum and urine immunofixation electrophoreses were negative, as was serology for infectious hepatitis and HIV. Urine analyses showed nephrotic proteinuria (14 g/24 h), granular casts and no hematuria.

A CT scan revealed enlarged kidneys and hepatosplenomegaly. A kidney biopsy was performed and showed secondary amyloidosis as the main finding, which was associated with signs of acute tubular necrosis and interstitial nephritis (Figures 1 and 2).

In this case, chronic inflammation with abdominal and joint symptoms and nephrotic syndrome due to secondary amyloidosis in an Arab patient raised the hypothesis of FMF, even in the setting of quick renal function decline. Acute kidney injury may have occurred due to marked proteinuria, hypoalbuminemia and severe renal hypoperfusion, although in this case, antibiotic toxicity and acute interstitial nephritis may also have contributed.

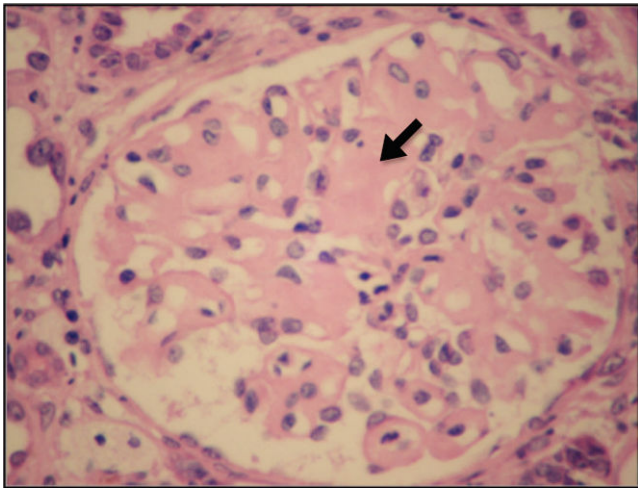
The diagnosis of FMF was based on clinical criteria (3) (Table 1) and further refined by demonstration of M694V allele homozygosity in the *MEFV* gene (Figure 3). The patient received a short course of corticosteroid therapy and was maintained on colchicine. She showed dramatic improvement of symptoms and inflammation. The long period without treatment, however, did not allow for renal improvement, as determined by a continuous increase in serum creatinine and the need for renal replacement therapy six weeks after admission.

## DISCUSSION

FMF is prevalent among Arabs and other Mediterranean ethnicities, but it is rare in the rest of the world. Its presentation includes crises of self-limiting fever bouts and elevated acute phase reactants accompanied by arthritis,

This is an Open Access article distributed under the terms of the Creative Commons Attribution Non-Commercial License (<http://creativecommons.org/licenses/by-nc/3.0/>) which permits unrestricted noncommercial use, distribution, and reproduction in any medium, provided the original work is properly cited.

No potential conflict of interest was reported.

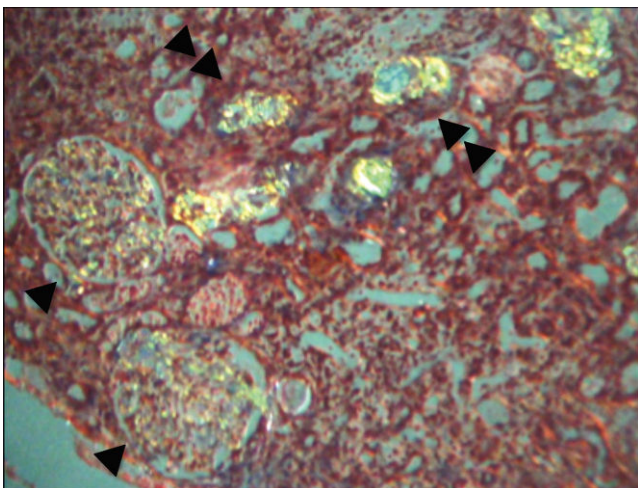


**Figure 1** - Kidney biopsy, hematoxylin-eosin, and light microscopy. Enlarged hypocellular glomerulus with deposits of amorphous material (arrow). Magnification 300x.

sterile peritonitis, pleurisy, and/or skin rash. The frequency of episodes varies from once a week to several times a year, with attacks subsiding spontaneously within one to three days.

*MEFV* maps to chromosome 16p13.3, comprises 10 exons and encodes pyrin/marenostrin, a protein expressed in granulocytes, monocytes, dendritic cells, and synovial fibroblasts (6). Pyrin regulates the innate inflammatory response through its cleavage by caspase-1 followed by NF- $\kappa$ B activation (7) and interleukin-1 $\beta$  production (8).

Amyloidosis and chronic kidney disease, as detected in our patient, are less common in FMF and are associated with a prolonged untreated disease course (5). Continuous and early treatment with colchicine tends to improve the attack frequency, duration and intensity and prevents the development of secondary amyloidosis. Colchicine is so effective that unresponsiveness prompts evaluation for compliance or for an alternative diagnosis. Noncompliant



**Figure 2** - Congo red staining shows apple-green birefringence on glomeruli (arrowheads) and tubules (double arrowheads). Not shown: tubules with degenerative changes, focal areas of necrosis and areas of interstitial nephritis. Normal blood vessels.

**Table 1** - Criteria for the diagnosis of FMF (3).

**Requirements for diagnosis of FMF:**  $\geq 1$  major criteria, or  $\geq 2$  minor criteria, or 1 minor criterion plus  $\geq 5$  supportive criteria, or 1 minor criterion plus  $\geq 4$  of the first 5 supportive criteria.

**Major criteria**

**Typical attacks**

1. Peritonitis (generalized)
2. Pleuritic (unilateral) or pericarditis
3. Monoarthritis (hip, knee, ankle)
4. Fever alone

**Minor criteria**

1-4. **Incomplete** attacks involving 1 or more of the following sites:

1. Abdomen
2. Chest
3. Joint
4. Exertional leg pain

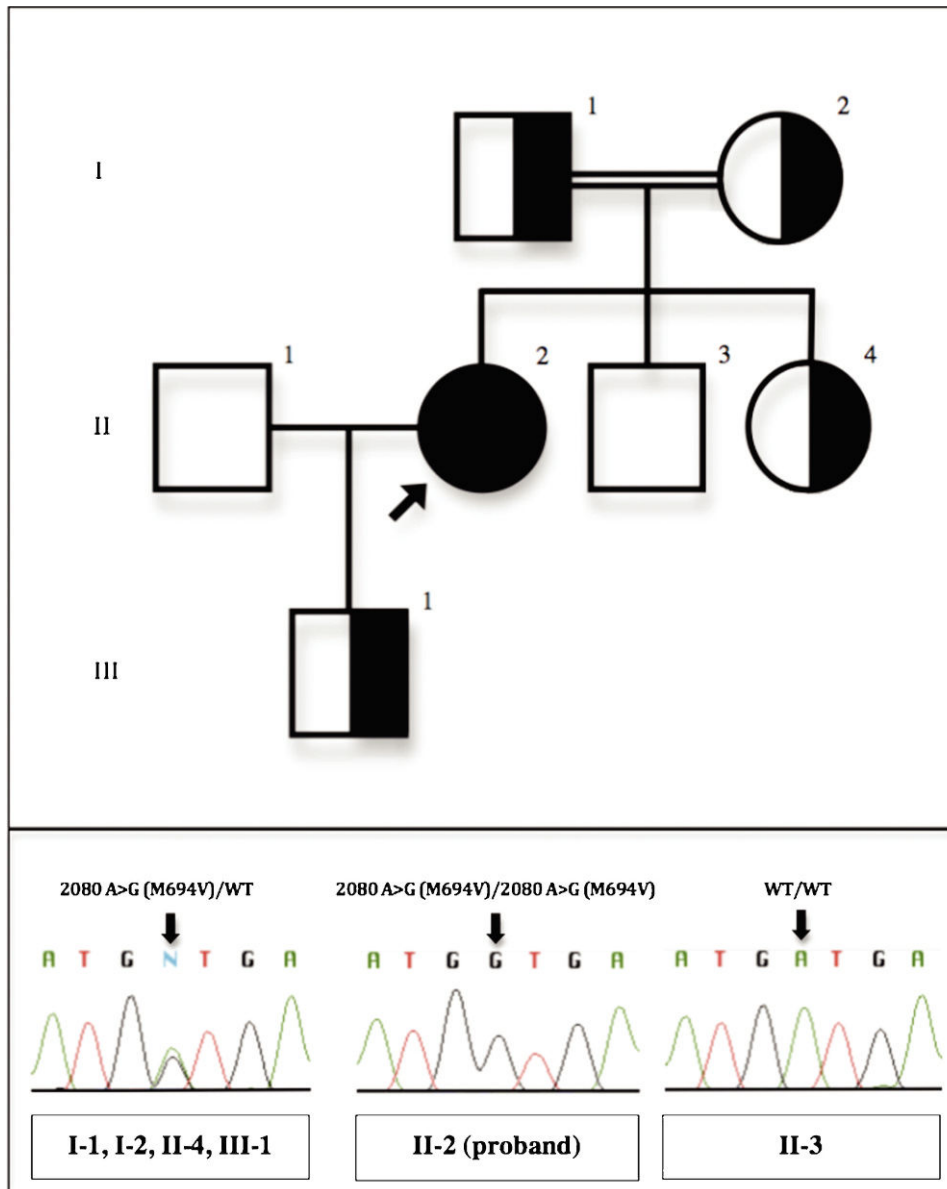
**Supportive criteria**

1. Family history of FMF
2. Appropriate ethnic origin
3. Age <20 years at disease onset
- 4-7: Features of the attacks
4. Severe, requiring bed rest
5. Spontaneous remission
6. Symptom-free interval
7. Transient inflammatory response, with one or more abnormal test result(s) for the white blood cell count, erythrocyte sedimentation rate, serum amyloid A, and/or fibrinogen
8. Episodic proteinuria/hematuria
9. Unproductive laparotomy or removal of white appendix
10. Consanguinity of parents

patients represent ~50% of patients who apparently do not respond to therapy (9). When compliance is assured, other hereditary autoinflammatory diseases that mimic FMF should be considered, such as TRAPS (TNF-associated periodic fever syndrome) and hyperimmunoglobulin D syndrome, neither of which respond to colchicine (10). There is no consensus on the treatment of patients who are true colchicine nonresponders; small series and case reports have described the potential role of interferon-alpha (11), thalidomide (12), etanercept (12), infliximab (13) and interleukin-1 receptor antagonists (14).

FMF manifestations are associated with the nature of *MEFV* mutations in different ethnic groups. Five main mutations (M680I, M694V, M694I and V726A in exon 10 and E148Q in exon 2) are responsible for more than 85% of FMF cases in the Mediterranean (1,15). Interestingly, homozygosity may not correlate with disease, and some patients who fulfill clinical criteria do not always have detectable mutations in *MEFV*. Our patient was shown to be homozygous for M694V (Figure 3). In fact, when disease is present, patients with M694V are more severely affected than those with other mutated alleles, particularly in the homozygous state, which correlates with amyloidosis and unfavorable renal prognosis (5,16). The detection of a single mutation in *MEFV*, however, is sufficient for diagnostic and therapeutic purposes when a minimal set of clinical manifestations is present (17).

The presented case, therefore, underscores the importance of considering the diagnosis of FMF in regions of the world where this disease is uncommon, such as Latin America, the importance of family history for diagnosis, the risks of missing the diagnosis because of non-renal manifestations, the potential correlation between genotype and the development of end-stage renal disease, the potential consequences of the long-term absence of appropriate therapy,



**Figure 3** - Top: Family pedigree. Bottom: Individual genotypes and corresponding DNA sequence chromatograms. The nucleotide position refers to the MEFV mRNA sequence, with the A of the start codon designated as nucleotide 1. WT: wild type. Individual II-1 was not evaluated.

and the key role that molecular diagnosis may play, particularly in equivocal and atypical cases.

**AUTHOR CONTRIBUTIONS**

Balbo BE worked on the case, analyzed the data and wrote the manuscript. Silva AA and Amaral AG worked on the case. Malheiros DM performed the pathological analysis. Onuchic LF analyzed the data and wrote the manuscript. Barros RT worked on the case and analyzed the data.

**REFERENCES**

1. Ben-Chetrit E, Touitou I. Familial Mediterranean Fever in the World. *Arthritis Rheum-Arthr*. 2009;61(10):1447-53, <http://dx.doi.org/10.1002/art.24458>.
2. Goldfinger SE. Colchicine for familial Mediterranean fever. *The New England journal of medicine*. 1972;287(25):1302.
3. Livneh A, Langevitz P, Zemer D, Zaks N, Kees S, Lidar T, et al. Criteria for the diagnosis of familial Mediterranean fever. *Arthritis Rheum*. 1997;40(10):1879-85, <http://dx.doi.org/10.1002/art.1780401023>.
4. Ancient missense mutations in a new member of the RoRet gene family are likely to cause familial Mediterranean fever. The International FMF Consortium. *Cell*. 1997;90(4):797-807.
5. Cazeneuve C, Sarkisian T, Pecheux C, Dervichian M, Nedelec B, Reinert P, et al. MEFV-gene analysis in Armenian patients with familial Mediterranean fever: Diagnostic value and unfavorable renal prognosis of the M694V homozygous genotype - Genetic and therapeutic implications. *Am J Hum Genet*. 1999;65(1):88-97, <http://dx.doi.org/10.1086/302459>.
6. Tidow N, Chen XG, Muller C, Kawano S, Gombart AF, Fischel-Ghodsian N, et al. Hematopoietic-specific expression of MEFV, the gene mutated in familial Mediterranean fever, and subcellular localization of its corresponding protein, pyrin. *Blood*. 2000;95(4):1451-5.
7. Chae JJ, Wood G, Richard K, Jaffe H, Colburn NT, Masters SL, et al. The familial Mediterranean fever protein, pyrin, is cleaved by caspase-1 and activates NF-kappa B through its N-terminal fragment. *Blood*. 2008;112(5):1794-803, <http://dx.doi.org/10.1182/blood-2008-01-134932>.
8. Seshadri S, Duncan MD, Hart JM, Gavrilin MA, Wewers MD. Pyrin levels in human monocytes and monocyte-derived macrophages regulate IL-1 beta processing and release. *J Immunol*. 2007;179(2):1274-81.

9. Peters RS. Non-response to daily colchicine attack suppression in familial Mediterranean fever. Proceedings, 1<sup>st</sup> International Conference on FMF, Jerusalem, Israel 1997. p.8.
10. Drenth JPH, van der Meer JWM. Medical progress: Hereditary periodic fever. *New Engl J Med*. 2001;345(24):1748-57, <http://dx.doi.org/10.1056/NEJMra010200>.
11. Tunca M, Tankurt E, Akpınar HA, Akar S, Hizli N, Gonen O. The efficacy of interferon alpha on colchicine-resistant familial Mediterranean fever attacks: A pilot study. *British journal of rheumatology*. 1997;36(9):1005-8, <http://dx.doi.org/10.1093/rheumatology/36.9.1005>.
12. Seyahi E, Ozdogan H, Celik S, Ugurlu S, Yazici H. Treatment options in colchicine resistant familial Mediterranean fever patients: Thalidomide and etanercept as adjunctive agents. *Clin Exp Rheumatol*. 2006;24(5):S99-S103.
13. Ozgocmen S, Ozcakar L, Ardicoglu O, Kocakoc E, Kaya A, Kiris A. Familial Mediterranean fever responds well to infliximab: single case experience. *Clinical rheumatology*. 2006;25(1):83-7, <http://dx.doi.org/10.1007/s10067-005-1122-9>.
14. Belkhir R, Moulouguet-Doleris L, Hachulla E, Prinseau J, Baglin A, Hanslik T. Treatment of familial Mediterranean fever with anakinra. *Ann Intern Med*. 2007;146(11):825-6.
15. Touitou I. The spectrum of Familial Mediterranean Fever (FMF) mutations. *Eur J Hum Genet*. 2001;9(7):473-83, <http://dx.doi.org/10.1038/sj.ejhg.5200658>.
16. Soylemezoglu O, Arga M, Fidan K, Gonen S, Emeksiz HC, Hasanoglu E, et al. Unresponsiveness to Colchicine Therapy in Patients with Familial Mediterranean Fever Homozygous for the M694V Mutation. *J Rheumatol*. 2010;37(1):182-9, <http://dx.doi.org/10.3899/jrheum.090273>.
17. Booty MG, Chae JJ, Masters SL, Remmers EF, Barham B, Le JM, et al. Familial Mediterranean Fever With a Single MEFV Mutation Where Is the Second Hit? *Arthritis Rheum-U.S.* 2009;60(6):1851-61, <http://dx.doi.org/10.1002/art.24569>.