

CASE REPORT

Laparoendoscopic single-site (LESS) repair of lumbar hernia: initial case report

Marcos Tobias-Machado,¹ Felipe Brandão Corrêa de Araújo,¹ Oseas Castro-Neves,¹ Walter Fernandes Correa,¹ Anuar Ibrahim Mitre,¹¹ Antonio Carlos Lima Pompeo¹

¹Faculdade de Medicina do ABC, Urology, Santo André/SP, Brazil. ¹¹Hospital das Clínicas da Faculdade de Medicina da Universidade de São Paulo, Urology, São Paulo/SP, Brazil.

Email: felipebcaraujo@yahoo.com.br
Tel.: 55 81 9113-7181

INTRODUCTION

Less than 300 repairs of lumbar hernias have been reported (1). The condition may derive from a congenital or acquired defect in the posterior-lateral abdominal wall (2). Primary lumbar hernia is a congenital defect, which typically arises in two areas of weakness: the superior (Grynfelt's) triangle and the inferior (Petit's) triangle. Acquired lumbar hernias are usually caused by previous lumbar trauma or surgery (3).

Lumbar hernias are usually corrected by open surgery performed with large incisions and consequent morbidity. Laparoscopic techniques typically used for inguinal hernioplasty have been applied successfully for repair of lumbar hernias and have become the standard of care in some centers (4-10). Recently, the feasibility of laparoendoscopic single-site surgery (LESS) has developed to the point that it can be considered equivalent to conventional laparoscopic surgery for several indications (11).

Few reports have been published on the use of LESS in the context of treatment of incisional or inguinal hernias (12). The aim of this study is to report one case of lumbar hernia repaired by laparoendoscopic single-site surgery (LESS).

CASE REPORT

A 62-year-old woman was treated via flank incision for a left pielolithotomy two years ago. Painless bulging at the surgical site appeared six months after the surgery. Upon physical examination, bulging in the left lumbar region was observed below the twelfth rib when the patient was in the upright position. Palpation revealed an 8-cm hernia ring. A clinical diagnosis of lumbar hernia was established and a computerized tomography (CT scan) was performed for confirmation. The CT scan showed herniation of the colon through the defect in the abdominal wall. A laparoscopic surgical approach was chosen for treatment of the patient. Antibiotic prophylaxis was performed with cephalothin. The patient was placed in the right flank position, with the table tilted at 60°. A 4-cm umbilical incision was created to insert a

single-port device (Gelport, Applied Medical Research, Rancho Santa Margarita, CA). Pneumoperitoneum with CO₂ was maintained at a pressure of 15 mmHg and a 0° camera was introduced. The abdominal cavity was examined and the hernia ring was easily identified. A 5-mm port and a 12-mm port were inserted at the Gelport, establishing triangulation among the instruments (Figure 1).

Conventional laparoscopic instruments were used for the procedure. The hernia contents were dissected and brought back into the peritoneal cavity (Figure 2). To plan the hernia defect repair, transillumination was performed at the herniation area through the peritoneal cavity to assess the size of the non-absorbable polypropylene mesh (Proceed Surgical Mesh, Ethicon Endo-Surgery, Cincinnati, OH) that would be used. This mesh was 5-cm greater in diameter than the hernia ring. The mesh was introduced into the cavity through a 12-mm trocar and fixed on the wall with titanium staples two centimeters beyond the edges of the hernia defect (Figure 3). During this procedure, CO₂ pressure was reduced to 7-10 mmHg to help to fix the mesh. Finally, the cavity was revised, the single-ports removed and the incision was closed.

The total operative time was 100 minutes. No intraoperative event was observed, and bleeding was minimal. Analgesia was provided with only minor analgesics on the first postoperative day.

The patient was discharged the day after the surgery. She is asymptomatic at the six-month follow-up and happy with the esthetic aspect (Figure 4).

DISCUSSION

Lumbar hernia represents approximately 2% of all abdominal hernias (13). The flank incision for open renal surgery (lumbotomy) is associated with high rates of postoperative complications including muscular weakness, chronic incisional pain, and lumbar hernia. The prevalence of lumbar hernia after flank incision may reach as high as 20-30% (14-15).

Since the first reports in the late 1990s, the laparoscopic approach for repair of lumbar hernias has become the preference of many surgeons, mainly due to its effectiveness and the ability to perform the procedure at the same time as other intra-abdominal surgical procedures. Similar to the treatment of other hernia types, surgical repair of lumbar hernias has developed rapidly in recent years due to the use of minimally invasive techniques (6-9).

This is an Open Access article distributed under the terms of the Creative Commons Attribution Non-Commercial License (<http://creativecommons.org/licenses/by-nc/3.0/>) which permits unrestricted noncommercial use, distribution, and reproduction in any medium, provided the original work is properly cited.

No potential conflict of interest was reported.

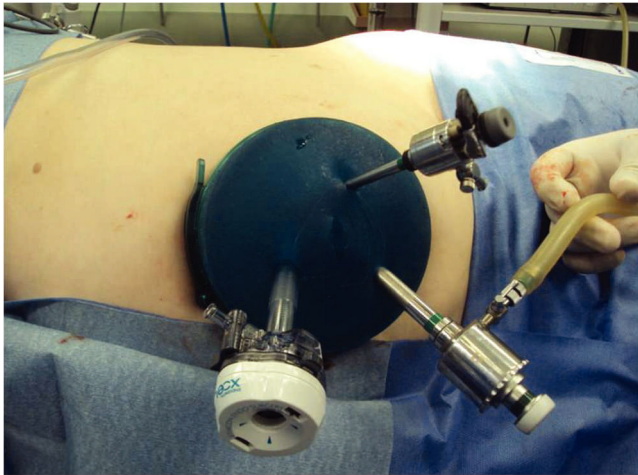


Figure 1 - Single-site access with the Gelport and triangulation of the Trocars.

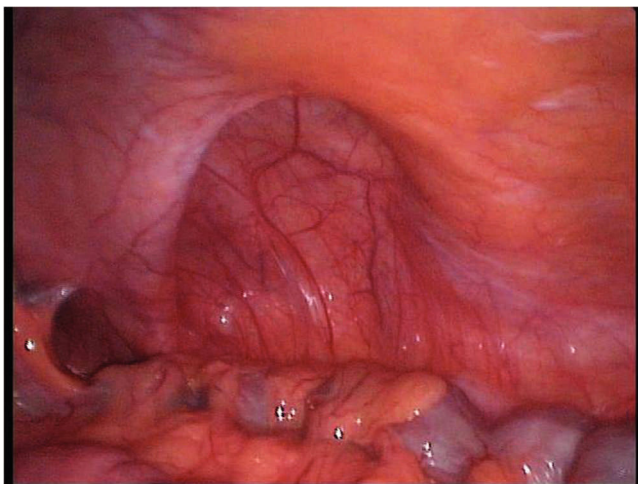


Figure 2 - Exposure of the entire hernia ring.

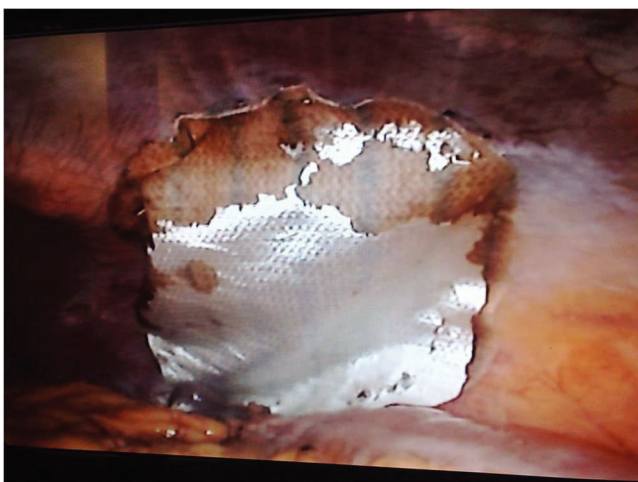

Figure 3 - Non-absorbable polypropylene mesh.

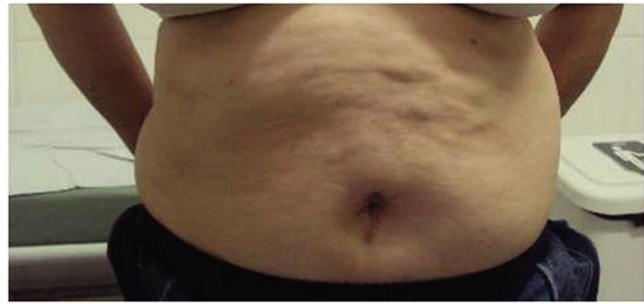


Figure 4 - Aesthetic aspect, six months post-operatively.

A natural progression has led to a reduction in the number of ports required to safely perform a laparoscopic procedure (11). Recently, Desai et al. described their initial 100 LESS procedures. Overall, they described surgical outcomes comparable to those achieved with conventional laparoscopic and open techniques (16). Bucher et al. reported 11 cases of LESS repair of primary and incisional ventral hernias with excellent results (12).

Compared to conventional laparoscopy, LESS procedures offer potential aesthetic benefits. However, other advantages of LESS, including operative morbidity, lower risk of incisional hernia, fewer narcotic requirements, shorter hospital stay, and faster return to work are controversial and require further validation (17-20).

Many technical challenges have been encountered during the transition from conventional laparoscopy to the LESS procedure (21). One inherent difficulty to the use of a common abdominal entry point is instrument crowding. This difficulty during the LESS procedure is due to the loss of instrument triangulation, which makes tissue manipulation more challenging. Similarly, the crowding of instruments leads to internal and external clashing and handling, which are often considered the most frustrating aspects of LESS procedures. In this case, conventional instruments were used and moved to the site of interest to facilitate expedient performance of the procedure.

Use of the GelPort as an access platform for the LESS procedure can help to provide adequate spacing, triangulation, port placement flexibility, and acceptable access to the surgical field using conventional instruments.

The procedure had an operative time comparable to conventional access, and no complications were observed. The functional results appear similar and the aesthetic aspects are superior to those observed with conventional laparoscopic approaches.

Laparoendoscopic single-site lumbar hernia repair is a feasible, efficient and safe technique that respects the principles of conventional laparoscopic repair. Further experience will be necessary to elucidate the additional potential applications of this procedure.

AUTHOR CONTRIBUTIONS

Tobias-Machado M conceived and designed the study. Araújo FBC was responsible for the drafting of the manuscript. Castro-Neves O and Correa WF were responsible for the acquisition of the data. Mitre AI and Pompeo ACL were responsible for the critical revision.

REFERENCES

1. Moreno-Egea A, Baena EG, Calle MC, Martínez JA, Albasini JL. Controversies in the current management of lumbar hernias. *Arch Surg.* 2007;142:82-8, doi: 10.1007/archsurg.142.1.82.
2. Stamatou D, Skandalakis JE, Skandalakis LJ, Mirilas P. Lumbar hernia: surgical anatomy, embryology, and technique of repair. *Am Surg.* 2009;75:202-7.
3. Cavallaro G, Sadighi A, Paparelli C, Miceli M, D'Ermo G, Polistena A, et al. Anatomical and surgical considerations on lumbar hernias. *Am Surg.* 2009;75:1238-41.
4. Arca MJ, Heniford BT, Pokorny R, Wilson MA, Mayes J, Gagner M. Laparoscopic repair of lumbar hernias. *J Am Coll Surg.* 1998;187:147-52, doi: 10.1016/S1072-7515(98)00124-0.
5. Saiz AA, Willis IH, Paul DK, Sivina M. Laparoscopic ventral hernia repair: a community hospital experience. *Am Surg.* 1996;62:336-8.
6. Heniford BT, Iannitti DA, Gagner M. Laparoscopic inferior and superior lumbar hernia repair. *Arch Surg.* 1997;132:1141-4.
7. Bickel A, Haj M, Eitan A. Laparoscopic management of lumbar hernia. *Surg Endosc.* 1997;11:1129-30, doi: 10.1007/s004649900547.
8. Tobias-Machado M, Rincon FJ, Lasmar MT, Zambon JP, Juliano RV, Wroclawski ER. Laparoscopic surgery for treatment of incisional lumbar hernia. *Int Braz J Urol.* 2005;31:309-14.
9. Habib E. Retroperitoneoscopic tension-free repair of lumbar hernia. *Hernia.* 2003;7:150-2, doi: 10.1007/s10029-002-0109-6.
10. Meinke AK. Totally extraperitoneal laparoendoscopic repair of lumbar hernia. *Surg Endosc.* 2003;17:734-7, doi: 10.1007/s00464-002-8557-8.
11. Kaouk JH, Autorino R, Kim FJ, Han DH, Lee SW, Yinghao S, et al. Laparoendoscopic Single-site Surgery in Urology: Worldwide Multi-institutional Analysis of 1076 Cases. *Eur Urol.* 2011 Jun 12. [Epub ahead of print].
12. Bucher P, Pugin F, Morel P. Single port laparoscopic repair of primary and incisional ventral hernia. *Hernia.* 2009;13(5):569-70, doi: 10.1007/s10029-009-0511-4.
13. Armstrong O, Hamel A, Grignon B, NDoye JM, Hamel O, Robert R, et al. Lumbar hernia: anatomical basis and clinical aspects. *Surg Radiol Anat.* 2008;30:533-7;discussion 609-10, doi: 10.1007/s00276-008-0361-2.
14. Hafner CD, Wylie JH, Jr., Brush BE. Petit's lumbar hernia: repair with Marlex mesh. *Arch Surg.* 1963;86:180-6.
15. Soto Delgado M, Garcia Urena MA, Velasco Garcia M, Pedrero Márquez G. Lumbar eventration as complication of the lumbotomy in the flank: review of our series. *Actas Urol Esp.* 2002;26:345-50.
16. Desai M, Berger AK, Brandina R, Aron M, Irwin BH, Canes D, et al. Laparoendoscopic single-site surgery: initial hundred patients. *Urology.* 2009;74(4):805-12, doi: 10.1016/j.urology.2009.02.083.
17. Raman JD, Bagrodia A, Cadeddu JA. Single-incision, umbilical laparoscopic versus conventional laparoscopic nephrectomy: a comparison of perioperative outcomes and short-term measures of convalescence. *Eur Urol.* 2009;55:1198-206, doi: 10.1016/j.eururo.2008.08.019.
18. Raakow R, Jacob DA. Initial experience in laparoscopic single-port appendectomy: a pilot study. *Dig Surg.* 2011;28(1):74-9. Epub 2011 Feb 4, doi: 10.1159/000322921.
19. Joseph S, Todd Moore B, Brent Sorensen G, Earley JW, Tang F, Jones P, Brown KM. Single-incision laparoscopic cholecystectomy: a comparison with the gold standard. *Surg Endosc.* 2011 Apr 13. [Epub ahead of print].
20. Gangl O, Hofer W, Tomaselli F, Sautner T, Függer R. Single incision laparoscopic cholecystectomy (SILC) versus laparoscopic cholecystectomy (LC)-a matched pair analysis. *Langenbecks Arch Surg.* 2011;396(6):819-24. Epub 2011 Jun 22.
21. Canes D, Desai MM, Aron M, Haber GP, Goel RK, Stein RJ, et al. Transumbilical single-port surgery: evolution and current status. *Eur Urol.* 2008;54:1020-30, doi: 10.1016/j.eururo.2008.07.009.